



**HAL**  
open science

## **Intramuscular capillary-type hemangioma: Diagnosis, treatment, and outcomes. A French multicentric retrospective study of 66 cases**

Jordan Orly, Annouk Bisdorff, Antoine Fraissenon, Aline Joly, Grégoire Boulouis, Laurent Guibaud, Elsa Tavernier, Stéphanie Mallet, Clément Marcelin, Juliette Miquel, et al.

### ► To cite this version:

Jordan Orly, Annouk Bisdorff, Antoine Fraissenon, Aline Joly, Grégoire Boulouis, et al.. Intramuscular capillary-type hemangioma: Diagnosis, treatment, and outcomes. A French multicentric retrospective study of 66 cases. *European Journal of Radiology*, 2023, 165, pp.110962. 10.1016/j.ejrad.2023.110962 . hal-04241422

**HAL Id: hal-04241422**

**<https://univ-rennes.hal.science/hal-04241422>**

Submitted on 28 Nov 2023

**HAL** is a multi-disciplinary open access archive for the deposit and dissemination of scientific research documents, whether they are published or not. The documents may come from teaching and research institutions in France or abroad, or from public or private research centers.

L'archive ouverte pluridisciplinaire **HAL**, est destinée au dépôt et à la diffusion de documents scientifiques de niveau recherche, publiés ou non, émanant des établissements d'enseignement et de recherche français ou étrangers, des laboratoires publics ou privés.



Distributed under a Creative Commons Attribution - NonCommercial 4.0 International License

**TITLE: Intramuscular capillary-type hemangioma: diagnosis, treatment, and outcomes. A French multicentric retrospective study of 66 cases**

**Authors and affiliations**

Jordan ORLY<sup>1,2\*</sup>, MD; Annouk BISSDORFF<sup>3\*</sup>, MD; Antoine FRAISSENON<sup>4,5,6</sup>, MD; Aline JOLY<sup>2,7</sup>, MD; Grégoire BOULOUIS<sup>2,8</sup>, MD, PhD; Laurent GUIBAUD<sup>4</sup>, MD, PhD; Elsa TAVERNIER<sup>9,10</sup>, PhD; Stéphanie MALLET<sup>11†</sup>, MD; Clément MARCELIN<sup>12</sup>, MD; Juliette MIQUEL<sup>13†</sup>, MD; Ludovic MARTIN<sup>14†</sup>, MD, PhD; Catherine DROITCOURT<sup>15†</sup>, MD, PhD; Laurence GUSDORF<sup>16†</sup>, MD; Claire ABASQ<sup>17†</sup>, MD; Ali DADBAN<sup>18†</sup>, MD; Christine CHIAVERINI<sup>19†</sup>, MD; Pierre VABRES<sup>20†</sup>, MD, PhD; Denis HERBRETEAU<sup>2,8</sup>, MD; Olivia BOCCARA<sup>21†</sup>, MD; Michel WASSEF<sup>22\*</sup>, MD; Annabel MARUANI<sup>1,2,9\*†</sup>, MD, PhD

*†On behalf of the Groupe de Recherche de la Société Française de Dermatologie Pédiatrique (GRSFDP)*

*\*These authors equally contributed to the manuscript*

<sup>1</sup>CHRU Tours, Department of Dermatology, Unit of Pediatric dermatology, Tours, France

<sup>2</sup>Reference center for genodermatoses and rare skin diseases (MAGEC-Tours), Tours, France

<sup>3</sup>Reference center for vascular anomalies FAVA-multi, University Hospital of Lariboisière; Coordinator of the constitutive center for superficial arteriovenous malformations in children and adults; AP-HP, Department of Neuroradiology, Paris, France

<sup>4</sup>Service d'Imagerie, Consultation Multidisciplinaire des Angiomes, Centre de Compétence National Malformations Vasculaires Superficielles, Hôpital Femme Mère Enfant, Université Claude Bernard Lyon 1, Lyon-Bron, France

<sup>5</sup>Service de Radiologie Mère-Enfant, Hôpital Nord, Saint-Etienne, France

<sup>6</sup>CREATIS, UMR 5220, U1294, Lyon, France

<sup>7</sup>CHRU Tours, Department of Maxillo-facial surgery, Tours, France

<sup>8</sup>CHRU Tours, Department of Neuroradiology and Interventional radiology, Tours, France

<sup>9</sup>University of Tours, University of Nantes, INSERM 1246-SPHERE, Tours, France

<sup>10</sup>CHRU Tours, Clinical Investigation Center INSERM 1415, Tours, France

<sup>11</sup>University Hospital Center of Marseille, Department of Dermatology, Marseille, France

<sup>12</sup>University Hospital Center of Bordeaux, Department of Radiology, Bordeaux, France

<sup>13</sup>University Hospital Center of La Réunion, Department of Pediatric Dermatology, Saint-Pierre, La Réunion, France

<sup>14</sup>University Hospital Center of Angers, Department of Dermatology, Angers, France

<sup>15</sup>University Hospital Center of Rennes, Department of Dermatology, Rennes, France

<sup>16</sup>University Hospital Center of Reims, Department of Dermatology, Reims, France

<sup>17</sup>University Hospital Center of Brest, Department of Dermatology, Brest, France

<sup>18</sup>University Hospital Center of Amiens, Department of Dermatology, Amiens, France

<sup>19</sup>University Hospital Center of Nice, Department of Dermatology, Nice, France

<sup>20</sup>University of Bourgogne, Reference center for genodermatoses and rare skin diseases (MAGEC), Dijon, France

<sup>21</sup>Department of Dermatology and Reference center for genodermatoses and rare skin diseases (MAGEC-Necker), University Hospital Necker-Enfants Malades, Paris, France

<sup>22</sup>University Hospital of Lariboisière, AP-HP, Department of Pathology, Paris, France

### **Corresponding author**

Pr Annabel Maruani

Department of Dermatology, CHRU Tours,

Avenue de la République, 37044 Tours Cedex 9, France

Tel: +33 2 47 47 90 80

Fax: +33 2 47 47 82 47

Email: [annabel.maruani@univ-tours.fr](mailto:annabel.maruani@univ-tours.fr)

**TITLE: Intramuscular capillary-type hemangioma: diagnosis, treatment, and outcomes. A French multicentric retrospective study of 66 cases**

**Funding sources:** None

**Conflict of interest:** None declared

**Article type:** Original article

**Manuscript word count:** 2 355

**Twenty-three references, 4 tables, 5 figures**

**ABSTRACT** (271 words)

**Purpose:** Intramuscular capillary-type hemangiomas (ICTHs) are rare entities, belonging to the group of intramuscular “hemangiomas.” The diagnosis remains challenging. We aimed to assess the diagnostic criteria, treatments and outcomes of ICTHs.

**Methods:** This retrospective study collected all cases of ICTH followed up in 9 French hospital centers, reviewed by an adjudication expert group.

**Results:** Among 133 patients screened, 66 with ICTH were included. The median age of patients at diagnosis was 28.0 years, interquartile range (21.0–36.0). The lesion, mainly presenting as a gradually increasing mass (83.9%), was painless (88.9%) and was located in the head and neck (42.4%). MRI (available in all cases) mainly revealed a well-delineated lesion, isointense to the muscle on T1-weighted images, with enhancement after contrast injection; hyperintense on T2-weighted images; and containing flow voids. Among the 66 cases, 59 exhibited typical ICTH features and 7 shared some imaging features with arteriovenous malformations. These latter were larger than typical ICTHs and more painful and appeared on imaging as less well delimited and more heterogeneous tissue masses, with larger tortuous afferent arteries, earlier draining vein opacification and mild arteriovenous shunting. We propose to name these lesions arteriovenous malformation (AVM)-like ICTH. Pathological reports were similar in typical and AVM-like ICTH, showing capillary proliferation with mainly small-size vessels, negative for GLUT-1 and positive for ERG, AML, CD31 and CD34, with low Ki67 proliferation index (< 10%), and adipose tissue. The most frequent treatment for ICTH was complete surgical resection (17/47, 36.2%), preceded in some cases by embolization, which led to complete remission.

**Conclusions:** ICTH can be diagnosed on MRI when it is typical. Biopsy or angiography are required for atypical forms.

**KEYWORDS:** Intramuscular hemangioma; Hemangioma of the skeletal muscle; Intramuscular capillary-type hemangioma; Intramuscular fast-flow vascular anomaly; Intramuscular vascular malformation; Extracranial arteriovenous malformation

**HIGHLIGHTS:**

- Intramuscular capillary-type hemangioma (ICTH) is a rare and not well-known entity that predominantly affects young adults.
- ICTH often presents as a gradually increasing painless mass, located in any skeletal muscle, most often in the head and neck muscles.
- MRI features coupled with clinical presentation allows for a diagnosis of ICTH in typical forms.
- A subgroup of ICTHs shares clinical and MRI features with arteriovenous malformations.

Journal Pre-proofs

## INTRODUCTION

Intramuscular capillary-type hemangiomas (ICTHs) belong to the group of intramuscular “hemangiomas”, a misnomer often used to name different types of intramuscular vascular malformations. ICTH has been reported under several names including intramuscular hemangioma (or angioma) small-vessel type or capillary-type and intramuscular infiltrating angiolipoma [1-4]. Its first description in 1972 by Allen and Enzinger, based on pathology, divided “hemangiomas of skeletal muscle” into 3 subgroups according to the predominant vessel size in the lesion: the small-vessel, large-vessel, and mixed types [1]. The small-vessel type, or ICTH, was then better identified with a recent description of specific MRI features [4,5], but its diagnosis remains challenging.

ICTH is a benign vascular anomaly of the skeletal muscle, consisting of an intramuscular solid mass that most often grows gradually, without pain, and mostly affects young people. Its evolution is poorly understood, but it does not regress spontaneously as does infantile hemangioma [4,5]. The term “hemangioma” for ICTH might be confusing, because it is used for infantile hemangioma and congenital hemangioma, 2 very different conditions of newborns and infants [6]. The main differential diagnoses of ICTH are other intramuscular vascular lesions, mainly intramuscular venous malformations, phosphatase and tensin homolog (PTEN)-related hamartomas of soft tissue (PHOSTs), and fibro-adipose vascular anomalies (FAVAs). These correspond to the large vessels and most of the mixed subtype hemangiomas of the skeletal muscles as described by Allen and Enzinger [1]. Venous malformations, often called “cavernous hemangiomas” or “venous hemangiomas” are slow-flow malformations that can be located in the muscles, often containing phleboliths, which induce pain. On MRI, they present as well-lobulated lesions with low signal intensity (SI) on T1-weighted images (WIs) and high SI on T2-WIs and delayed post-contrast images enhancement on T1-gadolinium sequences. Communication with the normal deep venous system throughout narrow tributaries can be seen. In some cases, thrombosed venous pouches or phleboliths may mimic signal voids [7,8]. PHOSTs are recently described vascular entities that often present as diffuse infiltrative intramuscular tumors referred to as *PTEN* hamartomas that may contain slow-flow and/or fast-flow vascular abnormal vessels. They might be isolated or associated with various systemic features of *PTEN* hamartoma tumor syndrome [9]. Radiologically, PHOSTS show a less clearly defined mass with high SI on T2-WIs and large flow voids due to arterial supply. The lesion might potentially involve surrounding tissues. More recently, FAVAs were described; these are additional rare vascular entities characterized by an infiltrating solid lesion that contains slow-flow vessels and a fatty component that usually involves muscular and neurovascular structures and is associated with severe pain and joint contracture [10,11]. On MRI, they can be recognized on T1-WIs, showing features of fatty and fibrous tissue components with striated multilayer features similar to fatty muscle infiltration. On T2-WIs, a hyper SI with “patchy spots” might be observed, with serpiginous structures (venous and lymphatic component) with low SI T2-WI foci (thrombi or phleboliths). Enhancement is moderate to marked after gadolinium injection.

ICTH is a fast-flow vascular entity (which is a key feature for diagnosis), with currently no gold standard for diagnosis. Somatic mutations of the *MAP2K1* and *KRAS* genes, also found in extracranial arteriovenous malformations (AVMs), were identified in a series of ICTH cases, which raises the question of the distinction between ICTH and intramuscular AVMs [12]. However, these molecular results still need to be confirmed in larger cohorts. The International Society for the Study of Vascular Anomalies, which classified ICTHs as “provisionally unclassified vascular anomalies” [6] without specifying whether they belong to

vascular tumors or vascular malformations, considered the possible overlap between ICTH and intramuscular AVMs, both belonging to a spectrum of fast-flow intramuscular lesions.

In this study, we aimed to collect all cases of ICTH followed up in 9 tertiary care centers for vascular anomalies in France and to assess the diagnostic criteria for better classification, treatments and outcomes.

## **MATERIAL AND METHODS**

### ***Design and setting***

This was a multicenter retrospective observational study of all ICTH cases followed up from January 1, 2000 to March 1, 2021 in France. The study was approved by the ethics committee of Tours (#2021 014).

### ***Participants and samples***

We included all patients with a lesion diagnosed by their hospital radiologist as an intramuscular hemangioma, with at least MRI images (T1, T2, T1-injected sequences) available. Because of no current gold standard for diagnosing ICTH, an adjudication group of experts was constituted to establish the diagnosis by taking into account a range of arguments (imaging and pathological data). All eligible cases were reviewed by the adjudication committee, consisting of a pathologist (MW), 2 radiologists (AB, GB), 1 surgeon (AJ) and 2 dermatologists (OB, AM) who reviewed US reports, MRI images, CT-scan and angiogram images when available and pathological reports. Criteria for inclusion in the final cohort of ICTH patients were that all experts agreed with the diagnosis of ICTH on the basis of data compatible with their knowledge and experience of the entity and agreed with one another. In case of disagreement or no consensus, the case was excluded, as were cases for which another diagnosis was established.

### ***Outcomes***

History, clinical, radiological, pathological and molecular data were analyzed.

### ***Diagnostic criteria***

Clinical characteristics that fit the diagnosis of ICTH were the occurrence of an intramuscular tissular mass without extension to the skin. Cases presenting skin necrosis, a port-wine stain, a bluish skin discoloration, a segmental overgrowth or any kind of hamartoma were excluded.

On MRI, lesions should be intramuscular lesions delineated or not by a fatty border, hyperintense on T2-weighted images and isointense to skeletal muscle on T1-weighted images, with or without an intralesional fatty component. On T1-weighted sequences, one should observe hypervascularization and homogeneous contrast enhancement after gadolinium injection. Cases have no calcifications (phleboliths), which suggests a venous malformation. When ultrasonography is performed, criteria are a non-compressible mass within the skeletal muscle, iso- or echogenic, and color and spectral Doppler ultrasonography showing arterial-type vascularization. When performed, angiography could show enlarged arterial feeder arteries with opacification of the tissue mass before any contrast appears in the draining veins and no arteriovenous nidus.

Pathological features that fit with a ICTH diagnosis were: presence of a proliferation of capillary-type vessels separating or infiltrating between the skeletal muscles, and absence of clusters of large ectatic vessels, calcifications (phleboliths), and bundles of smooth-muscle cells. Molecular data were not mandatory, although they were collected.

### *Statistical analyses*

Statistical analyses were mainly descriptive. Some data were missing because of the retrospective nature of the study. Categorical variables are expressed with number (percentages) and quantitative variables with median (interquartile range [IQR]). When comparison tests were performed, we considered  $p < 0.05$  as statistically significant. We used R v3.6.2 for analysis.

## RESULTS

Among 133 patients assessed for eligibility, with history obtained from 9 French centers, 66 were included (**Figure 1, flow chart**). The main reasons for exclusion were insufficient data collection to allow for a consensual diagnosis ( $n=23$ ), non-intramuscular lesion ( $n=10$ ), and other diagnoses ( $n=34$ ).

**Table 1** summarizes patient characteristics. The median age at the first signs was 28.0 years (IQR 21.0–36.0; range: birth to 58 years). The male/female ratio was 1.28. The median time to diagnosis was 12 months (IQR 5.0–22.0).

ICTH was most commonly a progressive increasing mass (83.9%), very rarely warm (3.1%), and with a firm consistency (83.3%); it was mostly painless (88.9%) (**Table 1**). A triggering factor was suggested in 8 (12.1%) cases, in particular pregnancy ( $n=4$ ) and local trauma ( $n=3$ ). ICTH could occur all over the body, but the most affected body regions were the head and neck area ( $n=28/66$ , 42.4%). Overall, among the 61 cases that included a description of the affected muscle(s), 31 muscles or muscle groups were affected (**Figure 2**). The most commonly affected muscle was the masseter ( $n=12$ ).

Imaging features are reported in **Table 2**. On MRI, the most common features were a well-delineated mass (87.8%) that was homogeneous (60.5%), isointense on T1-weighted images (63.6%), always displaying hypersignals on T2-weighted images, and after contrast enhancement, showing high and homogenous contrast enhancement (92.3%). Most cases (83.3%) showed flow voids. Angiography was performed in 13 (19.7%) cases, mostly describing a tissular blush with no nidus, inhomogeneous parenchymal staining without early draining or arteriovenous shunting. Ultrasonography was performed in 46 (69.7%) cases, describing mainly a hyperechogenic intramuscular lesion (87.5%) with a high resistance index (55.6%).

Biopsy or surgical excision was performed in 51 (77.3%) cases, was not performed in 12 cases and was unknown for 3 (**Table 1**). Descriptions mainly involved capillary proliferation (46.7%), with small-size and concomitant other-sized vessels in 86.1% of cases and presence of adipose tissue in 75.7% (**Figure 3**). A lobulated architecture was reported in 35.5% of cases and endothelial cells between muscle fibres in 17.9%. On immunostaining, when described, all cases were negative for GLUT-1 and positive for ERG, AML, CD31 and



CD34. The Ki67 proliferation index was < 10% in all cases. In one case, somatic mutations of the *MAP2K1* and *KRAS* genes was searched, with negative results.

Among the 66 ICTH cases, the consensus group identified 59 cases of typical ICTH and 7 atypical cases that showed features overlapping AVM and ICTH, which we called AVM-like ICTH. The latter were more voluminous than typical ICTH cases and could involve several muscles. They were located on the neck (n=1), trunk (n=2) and limbs (n=4) but not on the head, contrary to typical ICTH for which the face location was frequent (**Table 3**). The pathological description of both types was similar. MRI features of AVM-like ICTH were close to those of typical ICTH except that the lesions were larger, less well-delineated, and more heterogeneous, with constant flow voids in our cases and moderate to high contrast enhancement (**Figures 4 & 5**). Angiography revealed high vascularization with early venous return as in AVM and no nidus but global parenchymal vascularization such as in typical ICTH, with a feeding dysplastic artery and mild arteriovenous shunting.

The median post-treatment follow-up was 17.0 months (IQR 8.5-31.0). The main therapeutical procedure was surgical resection: 11/47 (23.4%) patients with available data underwent complete surgery alone and 6/47 (12.8%) underwent complete surgery after embolization, which was curative in all cases, with no recurrence (**Table 4**). Embolization alone (n=6, 12.8%) resulted in complete regression in one case. In 13/47 (27.7%) cases, clinical/imaging follow-up showed no spontaneous regression. Sirolimus, prescribed at 0.1 mg/day for 6 months in one patient was inefficient. Three serious adverse events occurred after treatment: major bleeding that required transfusion during partial surgical removal alone, bilateral cerebellar ischemia after embolization alone of a lesion located in the neck, and haemorrhagic shock during surgery the day after embolization. No patient died from disease, explorations or treatment.

## DISCUSSION

This retrospective multicenter French cohort of ICTH is the largest reported in the literature. The 66 cases included were mostly young adults and the lesions presented as a progressively enlarging firm and painless mass, mostly affecting the head and neck region (especially the masseter muscle) and limbs. Seven cases shared some imaging features with AVM (less well-delimited tissue mass, larger tortuous afferent arteries, more early draining-vein opacification, mild arteriovenous shunting) and could represent an intermediate lesion between ICTH and AVM. Clinically, these latter lesions tended to be larger, less frequently located on the face, and more painful and barely accessible for complete surgery. We propose to name them AVM-like ICTH. As compared with AVM-like ICTH, extracranial AVM might be apparent at birth; the lesions increase in size progressively, sometimes more suddenly during hormonal changes, and tend to recur after surgery [13]. The presence of rapid arteriovenous shunting, with early opacification of the veins before any tissue opacification, enlarged tortuous arterial feeders and multiple collateral supply are the main discriminating features for a positive diagnosis of extracranial AVM [14]. Goss et al., identifying same *KRAS* and *MAPK* somatic mutations in ICTH as in extracranial AVMs, need to be confirmed [12], because they would have potential impact, beyond the nosological aspect, on the future use of targeted therapies for non-operable mutated ICTH [15]. Only one case was investigated for these mutations in our cohort, with negative results. Further molecular investigations are needed of both typical and AVM-like ICTHs.

In the literature, intramuscular hemangioma is misnamed for actually describing different intramuscular lesions. In this cohort, about half of the cases screened were excluded because the committee of experts reclassified them as other entities, the most frequent being intramuscular venous malformations. These lesions are vascular anomalies that appear as heterogeneous masses on MRI, are not fast-flowing, and can contain phleboliths, a special type of organized thromboses [7,16-18]. Usually, they appear as well-delineated spherical hypointense areas on T1- and T2-weighted MRI images, which argues for a venous malformation. FAVAs and PHOSTs were other differential diagnoses. In FAVA, MRI reveals a heterogeneous lesion containing rounded areas with high signal spots associated with fibroadipose components, corresponding to large dysplastic veins, typical of this disease. PHOST often presents as irregularly shaped intramuscular lesions, showing T1-weighted contrast enhancement and T2-hyperintense signals, with dilated, serpiginous vascular components and small arteriovenous fistulae with dilated draining veins [9, 10, 19-21]. Both FAVA and PHOST correspond histologically to lesions described as “angiomatosis of soft-tissue” by Rao and Weiss [22].

ICTHs are benign lesions that mainly grow fast until becoming stable in growth. Eight of our 66 cases featured a potential triggering factor such as a trauma and/or pregnancy. Four additional cases reported in the literature occurred after pregnancy [5]. This observation might be fortuitous but needs to be kept in mind because trauma and hormonal changes are also potential triggering factors for extracranial AVMs [13,23]. Complete surgical resection, when possible, preceded or not by embolization, seems curative, with very low recurrence risk.

This study has some limitations, such as biases linked to its retrospective nature, which inevitably induces missing data.

In conclusion, clinical history and physical examination, associated with MRI images, allow for the diagnosis of ICTH in most cases. The most important characteristics of these lesions are that they are delineated masses presenting intralesional flow voids and early homogenous T1 gadolinium enhancement. In rare cases, a biopsy is required to exclude malignant soft tissue tumors. We identified a subgroup of large ICTH lesions displaying more heterogeneous MRI features that we called AVM-like ICTH. These lesions require angiography to distinguish them from extracranial AVMs.

## REFERENCES

- [1] P.W. Allen, F.M. Enzinger FM, Hemangioma of skeletal muscle, An analysis of 89 cases, *Cancer*. 29 (1972) 8–22. [https://doi: 10.1002/1097-0142\(197201\)29:1<8::aid-cncr2820290103>3.0.co;2-a](https://doi.org/10.1002/1097-0142(197201)29:1<8::aid-cncr2820290103>3.0.co;2-a).
- [2] C. Pribyl, S.W. Burke, J.M. Roberts, F. Mackenzie, C.E. Johnston 2<sup>nd</sup>, Infiltrating angiolipoma or intramuscular hemangioma? A report of five cases, *J. Pediatr. Orthop*. 6 (1986) 172–176. [https://doi: 10.1097/01241398-198603000-00010](https://doi.org/10.1097/01241398-198603000-00010).
- [3] A. Beham, C.D. Fletcher, Intramuscular angioma: a clinicopathological analysis of 74 cases, *Histopathology*. 18 (1991) 53–59. [https://doi: 10.1111/j.1365-2559.1991.tb00814.x](https://doi.org/10.1111/j.1365-2559.1991.tb00814.x).
- [4] S. Yilmaz, H.P. Kozakewich, A.I. Alomari, S.J. Fishman, J.B. Mulliken, G. Chaudry, Intramuscular capillary-type hemangioma: radiologic-pathologic correlation, *Pediatr. Radiol*.

44 (2014) 558–565. <https://doi.org/10.1007/s00247-014-2876-5>.

[5] J. Orly, A. Bisdorff, A. Joly, A.E. Edée, E. Tavernier, D. Herbreteau, O. Boccara, M. Wassef, A. Maruani, Characteristics, natural course and treatment of intramuscular capillary-type hemangioma: A systematic literature review, *Acta. Derm. Venereol.* 10 (2023) 103. <https://doi.org/10.2340/actadv.v103.4432>.

[6] M. Wassef, F. Blei, D. Adams, A. Alomari, E. Baselga, A. Berenstein, P. Burrows, I.J. Frieden, M.C. Garzon, J.C. Lopez-Gutierrez, D.J.E. Lord, S. Mitchel, J. Powell, J. Prendiville, M. Vikkula, ISSVA Board and Scientific Committee, Vascular anomalies classification: Recommendations from the International Society for the Study of Vascular Anomalies, *Pediatrics.* 136 (2015) e203–214. <https://doi.org/10.1542/peds.2014-3673>.

[7] K.D. Hein, J.B. Mulliken, H.P. Kozakewich, J. Upton, P.E. Burrows, Venous malformations of skeletal muscle. *Plast. Reconstr. Surg.* 110 (2002) 1625–1635. <https://doi.org/10.1097/01.PRS.0000033021.60657.74>.

[8] M.A. Eryilmaz, Y.K. Varsak, Z. Gül, A. Uğur, Intramuscular cavernous hemangioma of the temporalis muscle, *J. Craniofac. Surg.* 25 (2014) 1400–1401. <https://doi.org/10.1097/SCS.0000000000000927>.

[9] K.C. Kurek, E. Howard, L.B. Tennant, J. Upton, A.I. Alomari, P.E. Burrows, K. Chalache, D.J. Harris, C.C. Trenor 3rd, C. Eng, S.J. Fishman, J.B. Mulliken, A.R. Perez-Atayde, H.P. Kozakewich, PTEN hamartoma of soft tissue: a distinctive lesion in PTEN syndromes, *Am. J Surg. Pathol.* 36 (2012) 671–87. doi: 10.1097/PAS.0b013e31824dd86c.

[10] A.I. Alomari, S.A. Spencer, R.W. Arnold, G. Chaudry, J.R. Kasser, P.E. Burrows, P. Govender, H.M. Padua, B. Dillon, J. Upton, A.H. Taghinia, S.J. Fishman, J.B. Mulliken, R.D. Fevurly, A.K. Greene, M. Landrigan-Ossar, H.J. Paltiel, C.C. Trenor 3<sup>rd</sup>, H.P. Kozakewich. Fibro-adipose vascular anomaly: clinical-radiologic-pathologic features of a newly delineated disorder of the extremity, *Pediatr. Orthop.* 34 (2014) 9–17. <https://doi.org/10.1097/BPO.0b013e3182a1f0b8>.

[11] C. Lipede, D. Nikkhah, R. Ashton, G. Murphy, A.M. Barnacle, P.A. Patel, G.D. Smith, D.M. Eastwood, B. Sivakumar, Management of Fibro-adipose Vascular Anomalies (FAVA) in paediatric practice, *JPRAS. Open.* 29 (2021) 71–81. <https://doi.org/10.1016/j.jptra.2021.05.002>.

[12] J.A. Goss, D.J. Konczyk, P.J. Smits, H.P.W. Kozakewich, A.I. Alomari, A. Al-Ibraheemi, A.H. Taghinia, B.H. Dickie, D.M. Adams, S.J. Fishman, J.B. Mulliken, M.L. Warman, A.K. Greene, Intramuscular fast-flow vascular anomaly contains somatic MAP2K1 and KRAS mutations, *Angiogenesis.* 22 (2019) 547–552. <https://doi.org/10.1007/s10456-019-09678-w>.

[13] A.S. Liu, J.B. Mulliken, D. Zurakowski, S.J. Fishman, A.K. Greene, extracranial arteriovenous malformations: natural progression and recurrence after treatment, *Plast. Reconstr. Surg.* 125 (2010) 1185–1194. <https://doi.org/10.1097/PRS.0b013e3181d18070>.

[14] S. Geibprasert, N.F. Fanning, A. Pedroza, K.G. Terbrugge, Imaging characteristics of arteriovenous malformations simulating vascular tumors of the temporalis muscle: a report of two cases, *Int. J. Oral. Maxillofac. Surg.* 29 (2010) 402–406. <https://doi.org/10.1016/j.ijom.2009.12.009>.

- [15] C.L. Nicholson, S. Flanagan, M. Murati, C. Boull, E. McGough, R. Ameduri, B. Weigel, S. Maguiness, Successful management of an arteriovenous malformation with trametinib in a patient with capillary-malformation arteriovenous malformation syndrome and cardiac compromise, *Pediatr. Dermatol.* 39 (2022) 316–319. [https://doi: 10.1111/pde.14912](https://doi.org/10.1111/pde.14912).
- [16] C. Fowell, C. Vereá Linares, R. Jones, H. Nishikawa, A. Monaghan, Venous malformations of the head and neck: current concepts in management, *Br. J. Oral. Maxillofac. Surg.* 55 (2017) 3–9. [https://doi: 10.1016/j.bjoms.2016.10.023](https://doi.org/10.1016/j.bjoms.2016.10.023).
- [17] E. Seront, M. Vikkula, L.M. Boon, Venous malformations of the head and neck, *Otolaryngol. Clin. North. Am.* 51 (2018) 173–184. [https://doi: 10.1016/j.otc.2017.09.003](https://doi.org/10.1016/j.otc.2017.09.003).
- [18] A. Domp martin, A. Acher, P. Thibon, S. Tourbach, C. Hermans, V. Deneys, B. Pocock, A. Lequerrec, D. Labbé, M.T. Barrellier, R. Vanwijck, M. Vikkula, L.M. Boon, Association of localized intravascular coagulopathy with venous malformations, *Arch. Dermatol.* 144 (2008) 873–877. [https://doi: 10.1001/archderm.144.7.873](https://doi.org/10.1001/archderm.144.7.873).
- [19] E.F. Sheybani, E.P. Eutsler, O.M. Navarro, Fat-containing soft-tissue masses in children, *Pediatr. Radiol.* 46 (2016) 1760–1773. doi: 10.1007/s00247-016-3690-z.
- [20] R. Arnold, G. Chaudry, Diagnostic imaging of vascular anomalies, *Clin. Plast. Surg.* 38 (2011) 21–29. [https://doi: 10.1016/j.cps.2010.08.014](https://doi.org/10.1016/j.cps.2010.08.014).
- [21] N. Pattamapaspong, W.C. Peh, T.W. Shek, Imaging of intramuscular haemangiomas of the extremities, *Singapore. Med. J.* 61 (2020) 122–128. [https://doi: 10.11622/smedj.2020030](https://doi.org/10.11622/smedj.2020030).
- [22] V.K. Rao, S.W. Weiss, Angiomatosis of soft tissue. An analysis of the histologic features and clinical outcome in 51 cases, *Am. J. Surg. Pathol.* 16 (1992) 764–771. [https://doi: 10.1097/00000478-199208000-00004](https://doi.org/10.1097/00000478-199208000-00004).
- [23] K.A. Azis, K.L. Koh, W.A. Sulaiman, M.M.M. Al-Chalabi, Extracranial arteriovenous malformations rupture in pregnancy, *Cureus.* 14 (2022) e22798. [https://doi: 10.7759/cureus.22798](https://doi.org/10.7759/cureus.22798).

## TABLES

**Table 1. Clinical, pathological and molecular data for intramuscular capillary hemangioma (ICTH) (n=66 patients)**

Variable	Description	Missing data
<b>PATIENT CHARACTERISTICS</b>		
Sex, n (%)		0
Females	29 (43.9)	
Males	37 (56.1)	
Age at first signs, years, median [IQR]	28.0 [21.0-36.0]	13
Age at diagnosis, years, median [IQR]	29.7 [23.0-37.9]	0
Diagnostic delay, months, median [IQR]	12.0 [5.0-22.0]	13
<b>CLINICAL DATA</b>		
Lesion size		37
Area (mm <sup>2</sup> ), median [IQR]	1950.0 [1125.0, 4225.0]	
Largest diameter (mm), median [IQR]	60.0 [40.0, 74.0]	
Pain, n (%)	7 (11.1)	3
Reported discomfort, n (%)	9 (14.3)	3
Topography, n (%)		0
Head	18 (27.3)	
Neck	10 (15.2)	
Trunk	10 (15.2)	
Lower limb	15 (22.7)	
Upper limb	13 (19.7)	

Progressive increase, n (%)	52 (83.9)	4
Rapid increase, n (%)	8 (12.9)	
No increase, n (%)	2 (3.2)	
Warmth, n (%)	2 (3.1)	2
Firm consistency, n (%)	5 (83.3)	60
Soft consistency, n (%)	1 (16.7)	
Identified triggering factor, n (%)	8 (12.1)	26
Pregnancy	4	
Trauma	3	
Erythema migrans on tick bite	1	
<b>PATHOLOGY AND MOLECULAR DATA</b>		
<b>Biopsy or excision performed, n (%)</b>	51 (77.3)	15
Presence of adipose tissue, n (%)	28 (75.7)	
Description of the vessel size, n (%)	36 (54.5)	
Small vessels only	5 (13.9)	
Small and larger vessels	31 (86.1)	
Lobulated architecture, n (%)	11 (35.5)	
Enlarged capillaries, n (%)	3 (10.7)	
Endothelial cells between muscle fibres, n (%)	5 (17.9)	
Capillary proliferation, n (%)	14 (46.7)	
Immunostaining, n (%)		
GLUT-1-negative	9 (100.0)	
ERG-positive	3 (100.0)	
CD31-positive	8 (100.0)	
CD34-positive	9 (100.0)	
D2-40-negative	3 (37.5)	

D2-40-slightly positive	5 (62.5)	
AML-positive	2 (100.0)	
KI67 <10%	3 (100.0)	
Search for somatic mutations, n	2	
<i>MAP2K1</i> and <i>KRAS</i> negative	1	
<i>PTEN</i> and <i>PIK3CA</i> negative	1	

IQR, interquartile range

Journal Pre-proofs

**Table 2. Imaging data for ICTH (n=66 patients)**

<b>Variable</b>	<b>Description</b>
<b>MRI, n (%)</b>	66 (100)
Description of the mass	
No consensus on delineation	17
Well-delineated mass	43 (87.8)
Heterogeneous mass	17 (39.5)
Homogeneous mass	26 (60.5)
No consensus on homogeneity	23
T1-weighted sequence description (n=22)	
Missing data	44
Hyperintense signals	3 (13.6)
Hypointense signals	5 (22.7)
Isointense signal	14 (63.6)
T2-weighted sequence description (n=58)	
Missing data	8
Hyperintense signals	58 (100)
Contrast enhancement (n=39)	
Missing data	27
High contrast	36 (92.3)
High and homogeneous contrast	13
Moderate contrast	3 (7.7)
Flow voids (n=54)	
Missing data	12
<b>CT scan, n (%)</b>	15 (22.7)
<b>Angiography, n (%)</b>	13 (19.7)



<b>Echo Doppler ultrasonography, n (%)</b>	<b>46 (69.7)</b>
Echogenicity (n=16)	
Missing data	50
Hyperechogenic	14 (87.5)
Isoechogenic	1 (6.2)
Hypoechoogenic	1 (6.2)
Heterogeneity/homogeneity of signals (n=4)	
Missing data	62
Heterogeneous signals	3 (75.0)
Resistance index (n=9)	
Missing data	57
High resistance index	5 (55.6)
Intermediate resistance index	3 (33.3)
Low resistance index	1 (11.1)

ICTH, intramuscular capillary hemangioma

**Table 3. Comparison of clinical and imaging data between typical intramuscular capillary-type hemangioma (ICTH) and AVM-like ICTH**

	Typical ICTH (n=59)	AVM-like ICTH (n=7)	Missing Data	p
<b>PATIENT CHARACTERISTICS</b>				
Sex, n (%)			0	-
Females	29 (43.9)	3 (42.9)		
Males	37 (56.1)	4 (57.1)		
Age at first signs, years, median [IQR]	28.17 [22.3, 36]	19.0 [6.75, 33.5]	13	0.361
Age at diagnosis, years, median [IQR]	30 [23.9, 38.5]	21 [11.1, 31.2]	0	0.148
Diagnostic delay, months, median [IQR]	12.0 [6.0, 22.5]	6.0 [1.2, 16.0]	13	0.231
<b>CLINICAL DATA</b>				
Lesion size			37	0.464
Area (mm <sup>2</sup> ), median [IQR]	1950.0 [1080.5- 4212.5]	3675.0 [2812.5- 4537.5]		
Pain, n (%)	4 (7.1)	3 (42.9)	3	<b>0.025</b>
Reported discomfort, n (%)	7 (12.3)	2 (33.3)	3	0.201
Topography, n (%)			0	0.350
Head and neck	27 (45.8)	1 (14.3)		
Trunk	8 (13.6)	2 (28.6)		
Lower limb	12 (20.3)	2 (28.6)		
Upper limb	12 (20.3)	2 (28.6)		
Progressive increase, n (%)	48 (87.3)	4 (57.1)	29	0.062

Rapid increase, n (%)	6 (10.9)	2 (28.6)		
No increase, n (%)	1 (1.8)	1 (14.3)		
Warmth, n (%)	2 (3.5)	0 (0.0)	2	1.000
Firm consistency, n (%)	5 (83.3)	-	60	-
Soft consistency, n (%)	1 (16.7)			
Identified triggering factor, n (%)	7 (11.9)	1 (14.3)	0	1.000
<b>IMAGING DATA</b>				
<b>MRI, n (%)</b>				
Description of the mass				
Well-delineated mass	40 (90.9)	3 (60.0)	17	0.107
Heterogeneous mass	13 (35.1)	4 (66.7)	23	0.193
T1-weighted sequence description			44	0.303
Hyperintense signals	2 (10.0)	1 (50.0)		
Hypointense signals	5 (25.0)	0 (0.0)		
Isointense signal	13 (65.0)	1 (50.0)		
T2-weighted sequence description			8	1.000
Hyperintense signals	54 (100)	4 (100)		
Contrast enhancement				
High contrast	14 (38.9)	1 (33.3)	27	<b>0.012</b>
Moderate	1 (2.8)	2 (66.7)		
Flow voids	41 (82.0)	4 (100.0)		1.000

IQR, interquartile range

**Table 4. Management and outcomes of ICTH (n=47 patients)**

Therapy, n (%)	Outcome, n (%)					
	Total regression	Partial regression	Stabilisation	Increase	Missing data	Serious adverse event
Complete surgical resection alone, n=11 (23.4)	4	0	0	0	7	0
Embolization followed by complete surgical resection, n=6 (12.8)	5	0	0	0	1	1 haemorrhagic shock
Partial surgical resection alone, n=7 (14.9)	0	2	1	2	2	1 major bleeding requiring transfusion
Embolization alone, n=6 (12.8)	1	3	2	0	0	1 bilateral cerebellar ischemia
Sclerotherapy, n=1 (2.1)	0	0	1	0	0	0
Cryosurgery followed by embolization, n=1 (2.1)	0	0	1	0	0	0
Medical care, n=2 (4.3)					0	
- Propranolol	0	1	0	0		0
- Sirolimus	0	0	0	1		0
Therapeutic abstention and follow-up, n=13 (27.7)	0	0	10 (76.9)	3 (23.1)	0	0

ICTH, intratumoural capillary hemangioma

## FIGURE LEGENDS

**Figure 1.** Flow chart of the 66 participants in the study

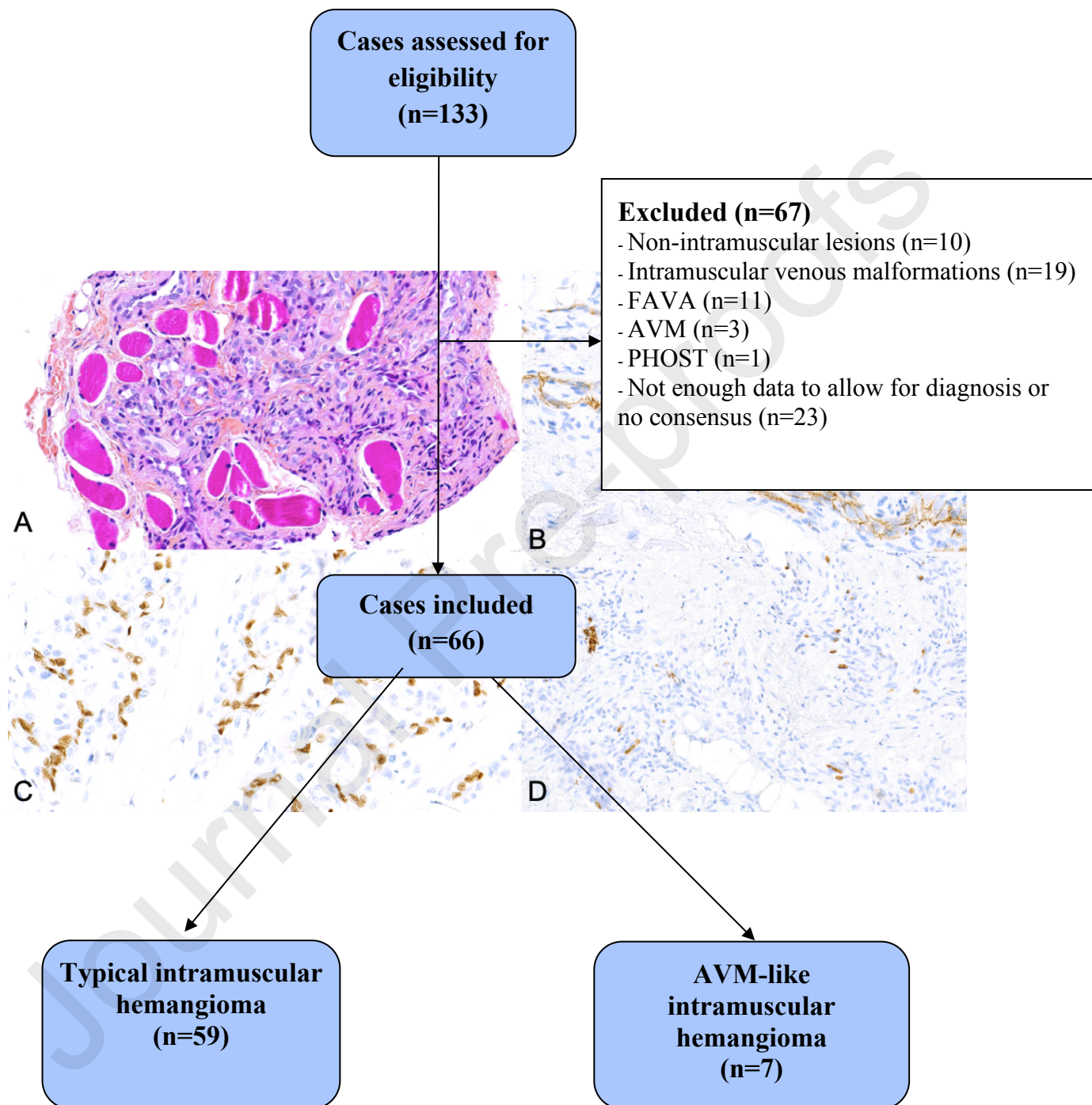
**Figure 2. (A) (B).** Muscles affected by intramuscular capillary-type hemangioma (ICTH)

**Figure 3.** Pathological examination of ICTH, showing proliferation of endothelial cells within skeletal muscles and adipose tissue, with small-size capillary vessels **(A)**, positive for CD31 **(B)** and ERG **(C)** and negative for GLUT-1 **(D)**.

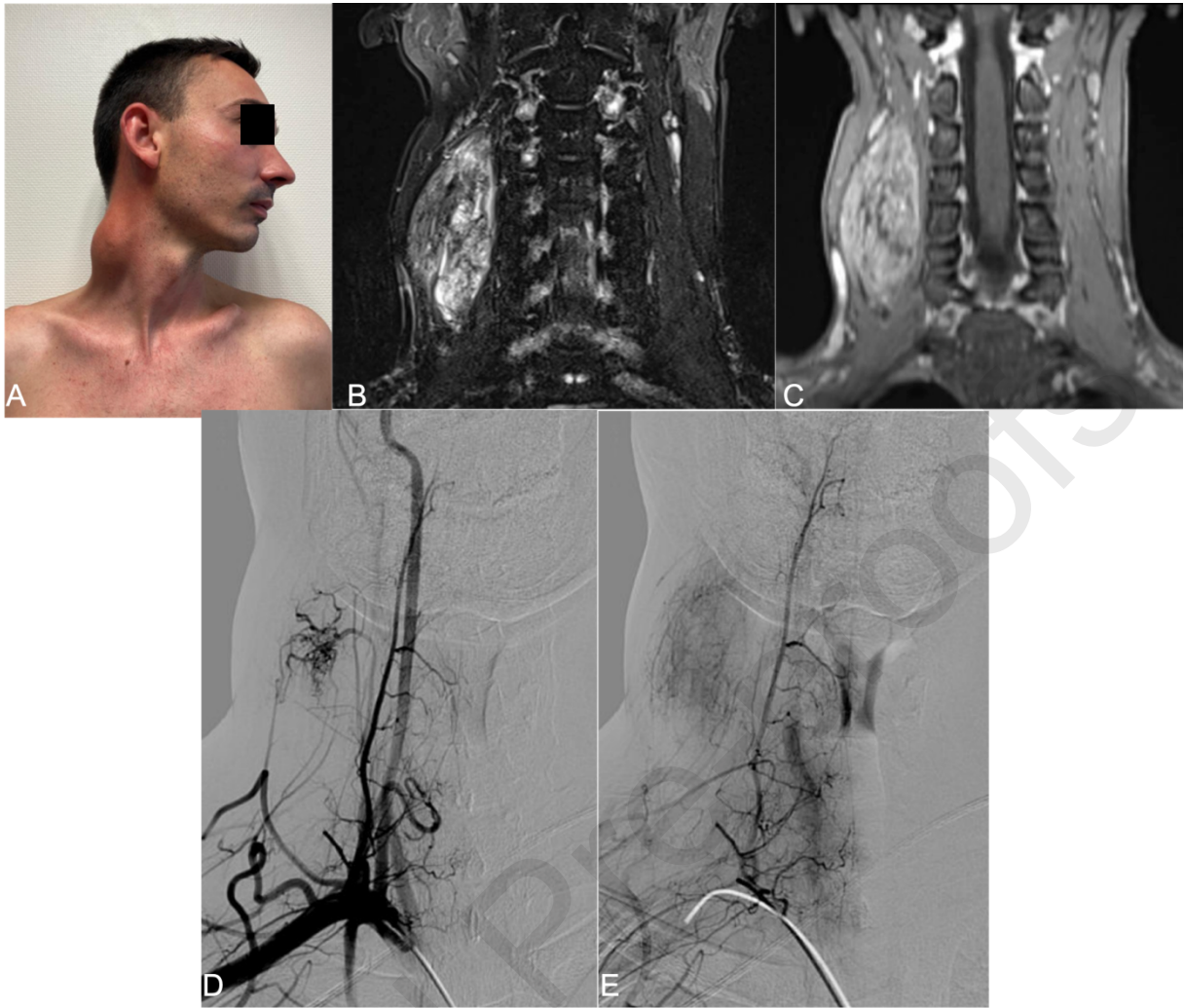**Figure 4.** Typical intramuscular capillary hemangioma of the scalene muscle in a 25-year-old patient: **(A)** Firm intramuscular mass underlying a normal skin; **(B-C)** MRI showing a well-limited homogeneous T2-weighted hyperintense signal **(B)** on a coronal T2 sequence with fat suppression and strong and homogenous enhancement following gadolinium injection **(C)** as seen on a T1-weighted-sequence with fat suppression. On a digital subtraction angiography with bolus injection in the ascending cervical artery, the lesion is seen as an early blush **(D)** demonstrating its richly vascularized nature; at the intermediate phase **(E)**, the lesion shows a pseudo-mesh appearance with vascular thickening along the main axis of muscular fibers.

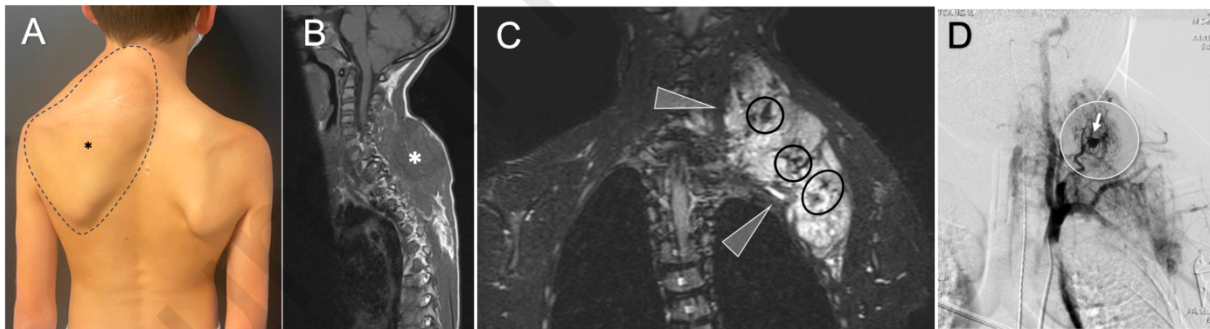
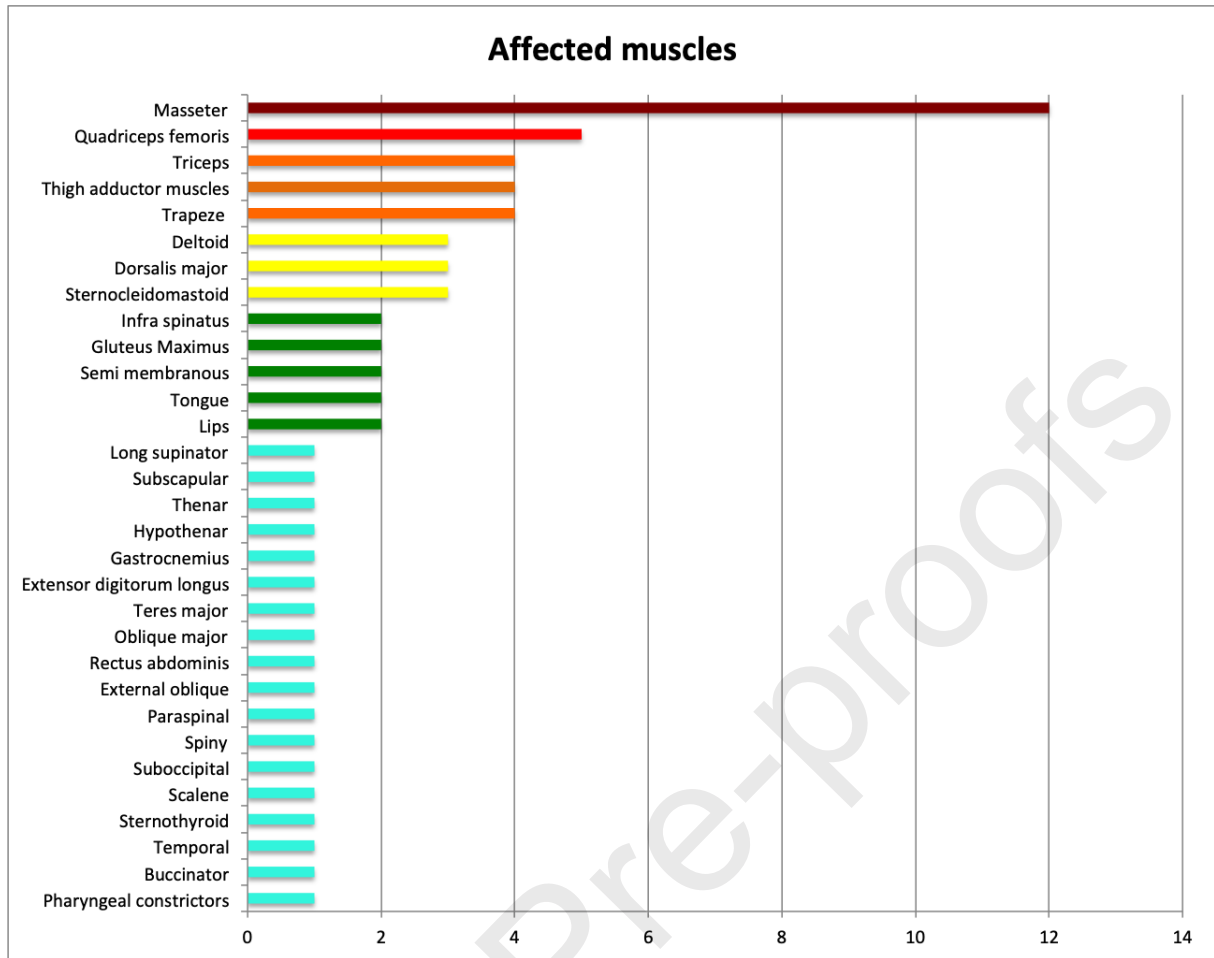
**Figure 5.** Arteriovenous malformation (AVM)-like intramuscular capillary hemangioma: Clinically evident as a **(A)** large firm mass of the scapulae area underlying a normal skin; **(B-D)** MRI images showing the lesion with a T1 signal isointense to that of adjacent paravertebral muscle **(B)**; T2 hyperintense lobulated lesion within the paravertebral muscles **(C, arrowheads)** and heterogenous intramuscular infiltrating enlargement with multiple hypointense pseudo-tubular areas, corresponding to high flow vessels (flow voids, **C, black circles**). **(D)**: A frontal projection of a digital subtraction angiography following left subclavian artery injection shows an early arterial intralesional blush; in an ascending branch of the costo-cervical trunk **(D, inset)** a (possibly flow-related) arterial aneurysm (white arrow) upstream of the lesion parenchyma.

Figure 1. Flow chart



*FAVA: fibro-adipose vascular anomaly*  
*AVM: arteriovenous malformation*  
*PHOST: phosphatase and tensin homolog (PTEN) hamartoma of soft tissue*





### DECLARATION OF INTERESTS

This research received no external financial or non-financial support.

There are no additional relationships to disclose.

There are no patents do disclose.

There are non additional activities to disclose.