



**HAL**  
open science

**Dental care of Anne d'Alègre (1565–1619, Laval, France). Between therapeutic reason and aesthetic evidence, the place of the social and the medical in the care in modern period**

Rozenn Colleter, Antoine Galibourg, Jérôme Treguier, Mikaël Guiavarc'H, Éric Mare, Pierre-Jean Rigaud, Florent Destruhaut, Norbert Telmon, Delphine Maret

► **To cite this version:**

Rozenn Colleter, Antoine Galibourg, Jérôme Treguier, Mikaël Guiavarc'H, Éric Mare, et al.. Dental care of Anne d'Alègre (1565–1619, Laval, France). Between therapeutic reason and aesthetic evidence, the place of the social and the medical in the care in modern period. *Journal of Archaeological Science: Reports*, 2023, 48, pp.103794. 10.1016/j.jasrep.2022.103794 . hal-04037713

**HAL Id: hal-04037713**

**<https://univ-rennes.hal.science/hal-04037713>**

Submitted on 30 May 2023

**HAL** is a multi-disciplinary open access archive for the deposit and dissemination of scientific research documents, whether they are published or not. The documents may come from teaching and research institutions in France or abroad, or from public or private research centers.

L'archive ouverte pluridisciplinaire **HAL**, est destinée au dépôt et à la diffusion de documents scientifiques de niveau recherche, publiés ou non, émanant des établissements d'enseignement et de recherche français ou étrangers, des laboratoires publics ou privés.



Distributed under a Creative Commons Attribution 4.0 International License



Contents lists available at ScienceDirect

## Journal of Archaeological Science: Reports

journal homepage: [www.elsevier.com/locate/jasrep](http://www.elsevier.com/locate/jasrep)

## Dental care of Anne d'Alègre (1565–1619, Laval, France). Between therapeutic reason and aesthetic evidence, the place of the social and the medical in the care in modern period

Rozenn Colleter<sup>a,b,c,\*</sup>, Antoine Galibourg<sup>b,d,1</sup>, Jérôme Treguier<sup>e</sup>, Mikaël Guiavarc'h<sup>f</sup>,  
Éric Mare<sup>a</sup>, Pierre-Jean Rigaud<sup>g</sup>, Florent Destruhaut<sup>d,h</sup>, Norbert Telmon<sup>b,i</sup>,  
Delphine Maret<sup>b,d,i,\*</sup>

<sup>a</sup> INRAP (Institut National de Recherches Archéologiques Préventives), 37 rue du Bignon, 35577 Cesson-Sévigné, France

<sup>b</sup> CNRS, CAGT, UMR 5288, Université Paul Sabatier, 37 allées Jules Guesde, 31000 Toulouse, France

<sup>c</sup> Department of Archaeology, Simon Fraser University, Education Building 9635, 8888 University Dr., Burnaby, BC V5A 1S6, Canada

<sup>d</sup> Faculté de Chirurgie Dentaire, Université Paul Sabatier, Centre Hospitalier Universitaire, 3 chemin des Maraichers, 31062 Toulouse, France

<sup>e</sup> Musée des sciences, 21 Rue du Douanier Rousseau, 53000 Laval, France

<sup>f</sup> CNRS, Université de Rennes, UMR6566 CReAAH, Campus de Beaulieu, bâtiment 24/25, 35042 Rennes, France

<sup>g</sup> Laboratoire d'Anatomie Anthropologique et de Paléopathologie de Lyon, Lyon, France

<sup>h</sup> URU EvolSan, Rangueil Hospital Group, Université Paul Sabatier, 3 chemin des Maraichers, 31062 Toulouse, France

<sup>i</sup> Department of Forensic Medicine, Centre Hospitalier Universitaire de Toulouse, Université de Toulouse, 1 Av. du Professeur Jean Poulhès, 31400 Toulouse, France

## ARTICLE INFO

## Keywords:

Periodontal disease  
Dentistry  
Seventeenth century  
Dental prosthesis  
Dental care  
Tooth wear

## ABSTRACT

Analysis of the oral cavity of human archaeological remains can provide essential information on the general health status of the person. The objectives of this paper are (i) to highlight an analysis of the oral state of the embalmed body of a 17th century female aristocrat with modern techniques of periodontal diagnosis and (ii) to provide a description of the therapeutic and aesthetic management intended to limit the functional and aesthetic consequences of the loss of teeth related to this periodontal disease. This paper provides the first demonstration of a link between a diagnosis and a therapy on an identified individual using new digital technologies used in modern dentistry. We propose that the objective of the treatment was triple: therapeutic, aesthetic and social. Beyond the only therapeutic care and far from the only coquetry, this study shows also the importance of the appearance for aristocratic women submitted to strong social constraints (like stress or widowhood), the speech of the disfigured women being could be regarded as deprived.

## 1. Introduction

Reconstructing the anthropological characteristics and the living and health conditions of ancient humans is essential for archaeological and paleoanthropological research. Skeletal remains, notably of the oral cavity, are a significant source of information as oral health is closely related to systemic health and the oral state of human remains can provide an indication for the diagnosis of a specific pathology (Keenleyside et al., 2009; Meller et al., 2009; Benazzi et al., 2009; Cucina et al., 2019).

Tooth loss may be related to a trauma or the presence of oral pathology, notably periodontal disease, which is, perhaps, the most

common oral disease of humans (Papapanou, 1999; Raitapuro-Murray et al., 2014; Caton et al., 2018). It is the result of a chronic gingival inflammatory response due to the accumulation of dental plaque (Papapanou, 1999; Caton et al., 2018). The loss of attachment of the connective tissue and the destruction of the alveolar bone causes a progressive loss of attachment around the teeth concerned, eventually leading to increased mobility (Ericsson et al., 1993). Periodontal health is recognized as an important component of general well-being because of the impact of oral pathologies on general health (Papapanou, 1999; Caton et al., 2018). For decades, archaeologists and anthropologists have been interested in the periodontal status of ancient populations, and several studies have described periodontal disease in ancient

\* Corresponding authors at: CNRS, CAGT, UMR 5288, Université Paul Sabatier, 37 allées Jules Guesde, 31000 Toulouse, France.

E-mail addresses: [rozenn.colleter@inrap.fr](mailto:rozenn.colleter@inrap.fr) (R. Colleter), [delphine\\_maret@yahoo.fr](mailto:delphine_maret@yahoo.fr) (D. Maret).

<sup>1</sup> These authors contributed equally to this work.

<https://doi.org/10.1016/j.jasrep.2022.103794>

Received 9 May 2022; Received in revised form 23 November 2022; Accepted 10 December 2022

Available online 24 January 2023

2352-409X/© 2023 The Authors. Published by Elsevier Ltd. This is an open access article under the CC BY license (<http://creativecommons.org/licenses/by/4.0/>).

populations (Hildebolt and Molnar, 1991; Gonçalves et al., 2015; Willmann et al., 2018; Bertl et al., 2020; Al-Mutairi et al., 2022; Bagis and Camgoz, 2022).

Because of bone loss, periodontal destruction often leads to tooth hypermobility. Loose teeth lead to both discomfort and aesthetic inconvenience for the subject, but also negative functional consequences such as weakened teeth (Kathariya et al., 2016). Splinting loose teeth together allows them to distribute the forces of the mobile teeth, resulting in stronger teeth support. This prolongs the longevity of loose teeth, provides stability for the periodontium to reattach, and improves comfort, function and aesthetics (Kathariya et al., 2016; Serio, 1999). This symptomatic treatment of periodontal destruction by restraint is known since 2500 BCE in Ancient Egypt (Becker and Turfa, 2017). In archaeology, examples of prosthesis replacing incisors or canines have been described (Crubézy et al., 1998; Seguin et al., 2014; Delattre, 2018; Debouige and Delattre, 2021; Cunha et al., 2017). The question arises whether these prostheses were made during the individual's lifetime or after his death. There are cases, where prostheses were found implanted in the alveolar bone. The evaluation of the degree of osseointegration allows determining if the act was performed ante or post-mortem (Seguin et al., 2014).

Studies of past populations rely on the examination of collections of ancient skulls collections and pose some technical challenges. In particular, a diagnosis of their periodontal disease depends on the estimation of the loss of attachment from an examination of the hard or mummified tissues only (skeleton and organic), which is difficult to reconcile with the application of the standardized case definitions of disease used in studies today (Caton et al., 2018). Digital technologies have been developed that can complement, and often replace, direct anthropometric measurements (Heike et al., 2009; Omari et al., 2021; Barreau et al., 2022). These indirect methods include methods such as 3D imaging, surface scanning (Omari et al., 2021; Fourie et al., 2011). With indirect anthropometry, the images are obtained quickly and can be rotated, enlarged, and archived for later evaluation (Heike et al., 2009; Omari et al., 2021). In addition, it is non-invasive, which is particularly useful when the remains are sensitive or fragile because they can be studied without damage to the original sample (Omari et al., 2021; Garcia de Leon Valenzuela et al., 2014). Indeed, the preservation of data and the replicability of analyses are something crucial today in archaeological ethical issues (Barreau et al., 2022; Colleter and Adèle, 2019). The digital tools of modern dentistry (intra-oral 3D scanning, digital imaging) can provide a fast, accurate and non-invasive method of recording dental information (Rajshekar et al., 2017). Scanning, 3D printing techniques and digital scanners have been used to create virtual digital models that can be used in dentistry and other related fields.

Beyond the recognition of periodontal symptoms by imagery, the problem of archaeological contexts that are often poorly documented (Becker, 1999) is an obstacle to the study of therapeutic treatments over time. Therefore, the discovery of a lead coffin in a chapel of Laval Castle (Mayenne, France, GPS: 48.0684, -0.7706) during a preventive archaeological excavation in 1987 uncovered two well-preserved restraint prostheses on the jaw of a perfectly preserved woman by embalming and identified as Anne d'Alègre (1565–1619) (Colleter et al., 2011; Moisdon and Rigaud, 1992). This well-documented discovery (archaeology, anthropology, history) allows us to take stock of the dental prostheses of the modern era, from their manufacturing technique to their aesthetic and functional character.

The objective of this article is to present an original case of oral evaluation using the tools of digital technology used in current clinical practice. Beyond the technical skill of the dentists of the past, between therapeutic necessity and aesthetic intent, the socio-economic context of the subject treated also provides information about a practice reserved for the most privileged from the Modern era.

## 2. Materials

The subject studied here comes from the excavation of the chapel of the castle of Laval (Mayenne, France; Fig. 1A) (Mare, 1987). It concerns a woman died after age 60, and was buried in a lead coffin encased in a wooden plank coffin on which was placed a cardiograph, a coffin also in lead in the shape of a heart (Fig. 1B) (Colleter et al., 2011; Moisdon and Rigaud, 1992). The embalmed body with a combination of aromatic plants (thyme, oregano, and juniper as main components of the recipe) (Ruas, 1992) was wrapped and tied up in a linen shroud and was in perfect anatomical connection. From the urn, a desiccated amalgam moulded to the wall was extracted without further precision. It was undoubtedly a human heart, possibly embalmed with odoriferous and drying materials as the aristocratic tradition required (Corbineau et al., 2017) even if this was not always the rule (Mokrane et al., 2016).

From a paleopathological view, the skeleton shows numerous degenerative lesions linked to the advancing age. Therefore, almost all the joints show osteoarthritis and/or enthesopathy, lesions on the entheses which are necessarily due to age. Numerous sequelae of trauma ante-mortem are visible on the thoracic cage: ossification of the 10th left rib in the thoracic spine; sequelae of trauma on the sixth and eighth left ribs and a costovertebral dislocation accompanied by calcified and ossified hemorrhagic changes on thoracic vertebrae 9 to 12. A congenital malformation (*spina bifida*) is visible on the sacrum and on the first cervical vertebra, and a thoracic scoliosis is also noted. The skull included the upper and lower jaws, both with most of the teeth. Two prostheses or ligatures were visible on the maxilla, one of which contained a replacement for a central incisor (Fig. 2).

The proposed identification with Anne d'Alègre was based on the location of the tomb, the written records, the anthropobiological data (sex, age at death, dental care) and the funerary practices highlighted (embalming and burial in a lead coffin), characteristic of aristocratic burials of the Late Middle Ages and Modern Period (Fig. 1C) (Colleter et al., 2016).

## 3. Methods: Visual and radiological analyses

The dental study was based on the visual examination of the mandibular and maxillary pieces.

The type of data collected are presented in Table 1.

Concerning the assessment of periodontal disease, we used the new classification of periodontal and *peri*-implant diseases established by the American Academy of Periodontology (AAP) and the European Federation of Periodontology (EFP) in 2018 (Caton et al., 2018). The new classification serves as a diagnostic system and classifies periodontal disease according to stage and grade (Caton et al., 2018). It considers: the severity, the complexity of the treatment, the risk of progression and the expected response to treatment, and comprises 4 stages:

- Stage I: Early stages of attachment loss
- Stage II: Established periodontitis.
- Stage III: Significant damage to the attachment apparatus.
- Stage IV: Significant damage to periodontal support, leading to tooth loss and loss of masticatory function.

All stages of periodontitis are supplemented with information about the grade of the disease.

Grading is based on direct and indirect evidence of risk factors:

- Grade A: rate of periodontal disease progression is low.
- Grade B: called the expected progression with a moderate rate of progression.
- Grade C: high risk of periodontal disease progression.

The dental observation and the ligature were first studied with an Unitron EXAMET-4 Metallurgical Microscope Series 14,250 / 14,251 to

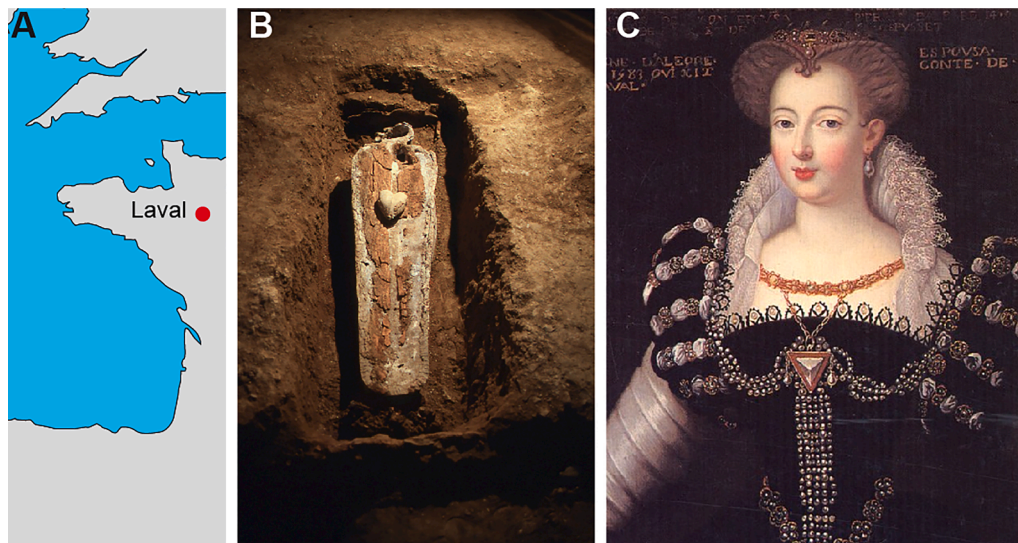


Fig. 1. A: Topographical location of Laval (France); B: View of the lead coffin when discovered; C: Oil on canvas representing the portrait of Anne d'Alègre after 1583.

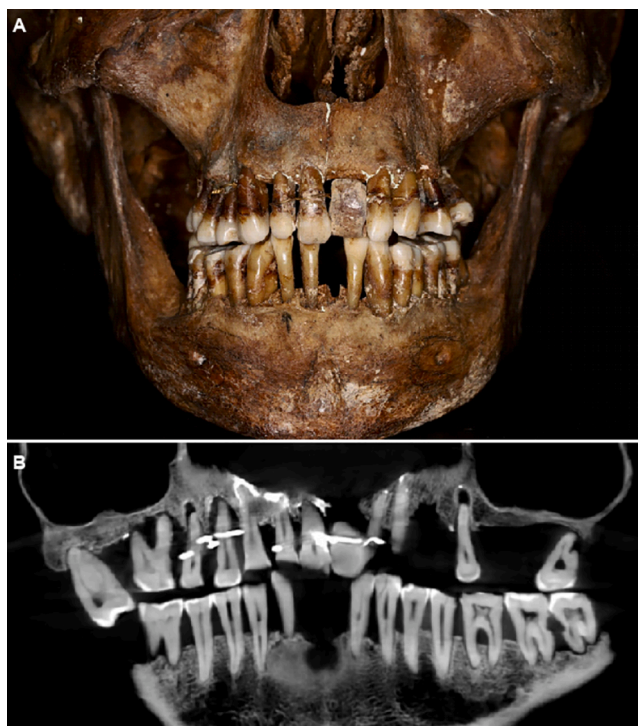

Fig. 2. Vestibular view of the maxilla and mandible. A: Photograph and B: Cone Beam Computed Tomography (CBCT).

determine the wear of the unit and the material used. Precise 2D views were realized and are shown in the results.

Additionally, X-ray examinations were performed using a Kodak 9600 Cone Beam Computed Tomography (CBCT) X-ray apparatus. Periodontal bone loss, osteolytic infectious lesions of endodontic origin, such as periapical granulomas or cysts, bone deformation due to residual periodontal cysts and intra bony cavities were analysed with CBCT. Dental abscesses were scored as present when maxillary or mandibular bone was destroyed by an infectious process, creating a rounded cavity in the spongy bone and a radiolucent lesion.

Ligatures were also described, both visually and with a surface analysis using an intraoral scanner (Planscan; Planmeca, Inc).

Table 1

Type of data and method or qualifying characteristics.

Type of Data	Method or qualifying characteristics
Teeth present	FDI World Dental Federation numbering system
Teeth lost ante / post-mortem (Seguin et al., 2014)	Visual and radiological appearance of the alveolar bone opposite the affected tooth
Dehiscences, fenestrations and developmental bony defects	Alveolar bone destroyed by infectious process, marked by rounded cavity in spongy bone and radiolucent lesion
Dental caries (Nyvad, 2004)	Evaluation by physical criteria of size, depth, and presence of cavitation.
Tooth wear (Chattah and Smith, 2006)	Located on the occlusal surfaces primarily, it is the result of various phenomena: abrasion, attrition, and erosion.
Estimated horizontal bone loss	Evaluation of the loss of bone height in relation to the amelodental junction
Dental calculus	Calcified dental plaque

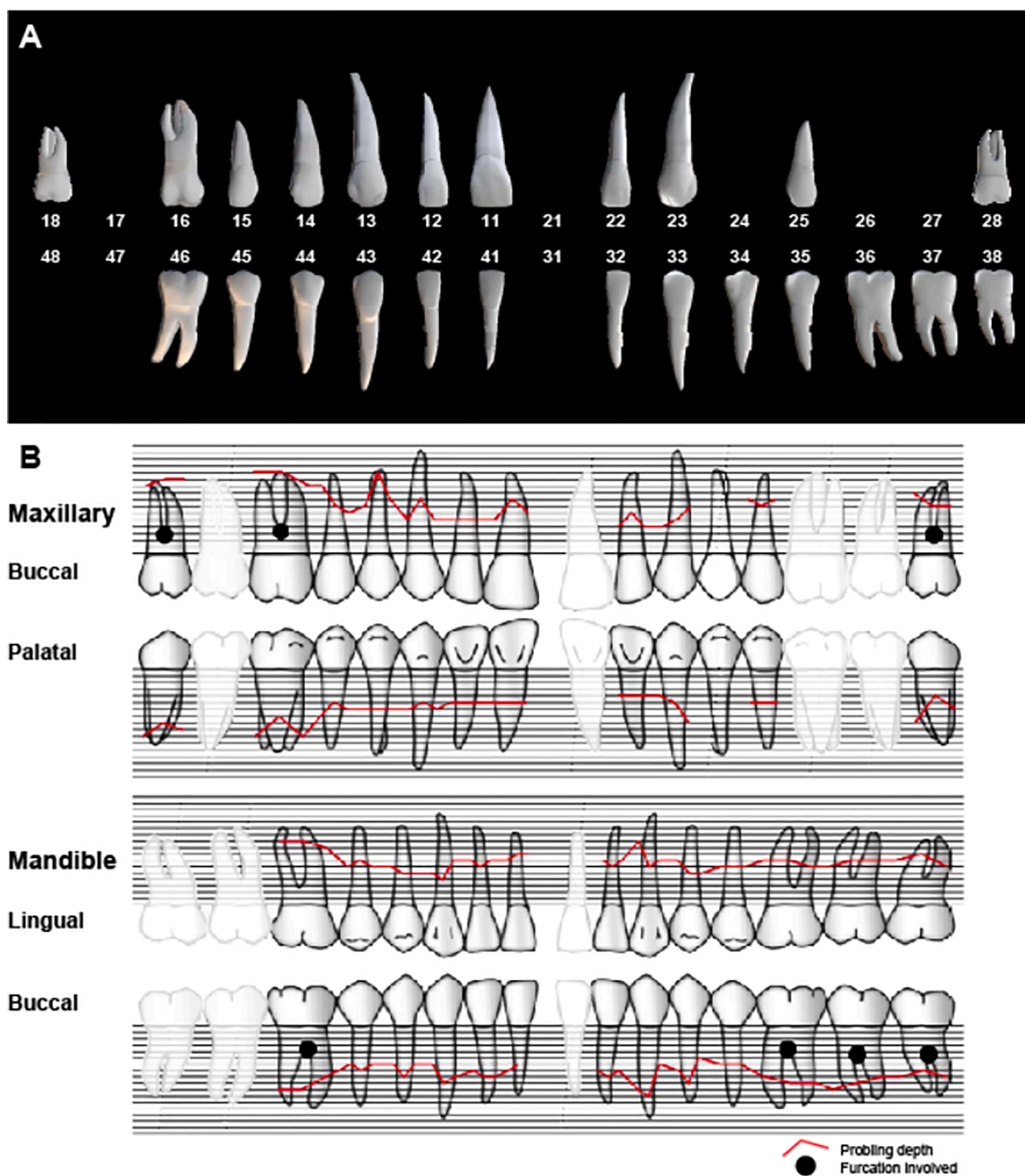
## 4. Results

### 4.1. Macroscopic and imaging analyses

The dental notation data according to the FDI classification recorded are shown in Fig. 3A. The CBCT panoramic view of the oral cavity allows the visualization of dental anomalies, including periodontal bone defects and tooth losses (Fig. 3B). Concerning the coronal anatomy, the presence of wear veneers was visible on all occlusal surfaces of the posterior teeth and on the free edge of the anterior teeth (Fig. 4). There was a post-mortem fracture of tooth 31, with a root remnant still present in the alveolus (Figs. 2, 4B). Dentin staining in the form of sclerotic dentin was present on all teeth. Fissures and tissue loss due to the process of post-mortem dehydration were noted (Fig. 5A). Coronal fissures were present.

At the edentulous sites, analysis of CBCT 3D imagery showed the following results:

- 16: old edentulous with version/regression of 18;
- 21: cortical bone present / bone volume present, suggesting loss of tooth ante-mortem due to traumatic or endoparodontal lesion (Fig. 6A). If a link between the loss of the central incisor and the sequelae of trauma observed on the subject's chest (multiple rib fractures) can be postulated, the attrition of the maxillary bone must



**Fig. 3.** A: Odontogram with FDI World Dental Federation numbering system; B: Periodontal charting representing the height of jawbone within millimeter in relation to the amelo-dentinal junction.

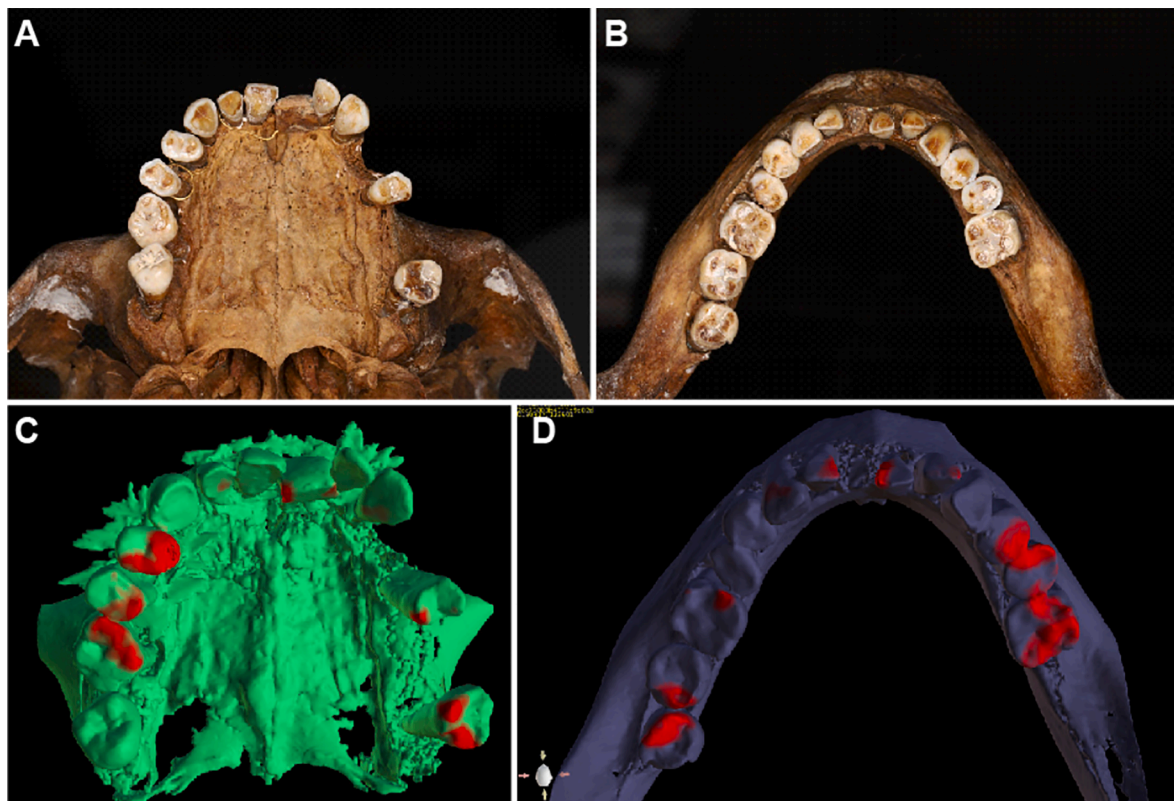
still be noted. Indeed, the periodontal damage is generalized. The alveolar bone has a cortical bone and the spongiosa is homogeneous at the site of this incisor (tooth 21), indicating an ante-mortem loss of more than 6 months. Traumatic etiology is possible with an expulsion without a bone fracture opposite. This seems to us to be the most likely scenario to explain the loss of this tooth, especially since other teeth are also missing and are part of a periodontal process;

- 24: absence of cortical bone with vestibular concavity (Fig. 6B and D); and 27: old edentulous;
- 31: presence of the apex in the alveolus, showing a postmortem fracture (Fig. 6C); and 48: old edentulous.

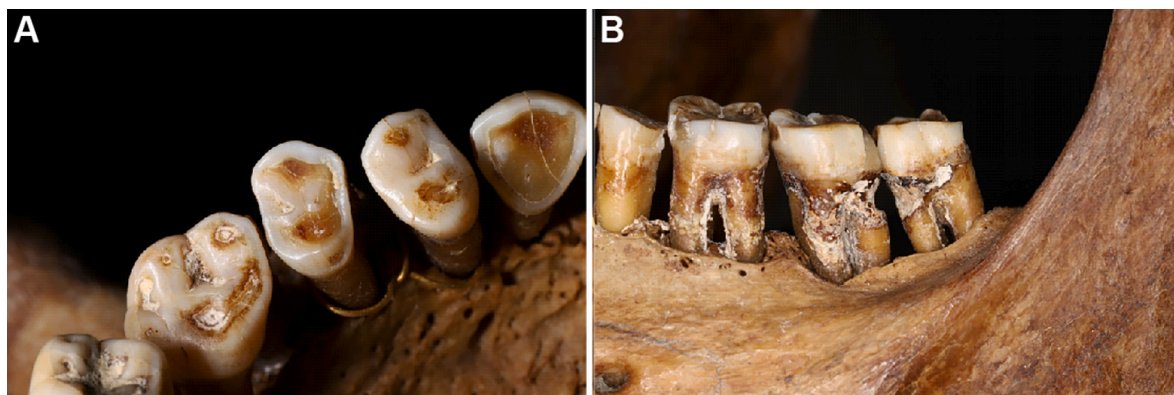
The use of the intra-oral scanner, a digital tool used in clinical practice, allows for a more detailed clinical examination in this

archaeological context (Fig. 7). After image registration, scanned surfaces revealed areas of wear such as retention wire and wear facets (Fig. 4C, 4D, 7A and 7B) Using the volume CBCT acquisition, the segmentation of the dental prosthesis allowed to model the 3D surface and to identify the retention and stabilization characteristics of this prosthesis (Fig. 6 and S11).

According to the new classification, the diagnosis of periodontal disease is classified as stage 5, grade C, generalized and unstable with potential risk factors (Immune system, possible diabetes, vitamin D, Scurvy). No nutritional deficiencies (*Cribra Orbitalia*, Linear Enamel Hypoplasia, rickets) or stress indicators are observed on the body to correlate to this diagnosis.



**Fig. 4.** Occlusal view of the maxilla (A, C) and mandible (B, D). A, B: Photograph and C, D: Cone Beam Computed Tomography (CBCT). The surfaces in red represent the occlusal contacts. The absence of a homogeneous distribution of contacts indicates a possible periodontal degradation posterior to the occlusal wear of the teeth. (For interpretation of the references to colour in this figure legend, the reader is referred to the web version of this article.)



**Fig. 5.** A: Macro-view of the right maxilla in detail; B: Vestibular macroscopic view of the three lower left molars.

#### 4.2. Oral pathologies

Concerning oral pathologies, interdental and root cavities were located on the mesial of the second (distal side) and third (mesial side) lower molars (Fig. 5B). The carious lesions extended into the vestibular area. With regard to the periodontal condition, generalized bone lysis showed at least 2/3 of the tooth roots on the arches and the visualization of 2/3 of the roots of all teeth present on both arches revealed generalized bone lysis. All teeth that were pluriradicate (molars) showed furcatory involvement. Calculus was present on all the roots (Fig. 5B).

Only tooth wear was present on the occlusal surfaces except for the upper left third molar (tooth 28) which was intact (Fig. 2B, 4). No chipping, notching or interproximal grooves were observed. Except from the upper left third molar, untouched and can thus serve as a witness, on each molar, premolar and incisor, tissue loss or tooth wear, occurs,

especially on the outer enamel layer. Enamel does not remodel over time, and macroscopic wear can be seen on many occlusal surfaces or free margins of maxillary and mandibular teeth (Lagan and Ehrlich, 2021). Occlusal examination of the triturating surfaces suggests three types of wear:

- i. Abrasion, especially on the molar and premolar areas, which may be related to the nature of the food consolidated at the time (Esclassan et al., 2009) and to the fact of the presence of silica particles and/or phytoliths (Romero et al., 2012; Reinhard and Danielson, 2005; Guan et al., 2022; Grine et al., 2012) or bruxism (Carlsson et al., 2003; Khan et al., 1998; Foley, 2020). This last hypothesis could be favored by the absence of wear of the right maxillary third molar, which has no antagonist or wear.

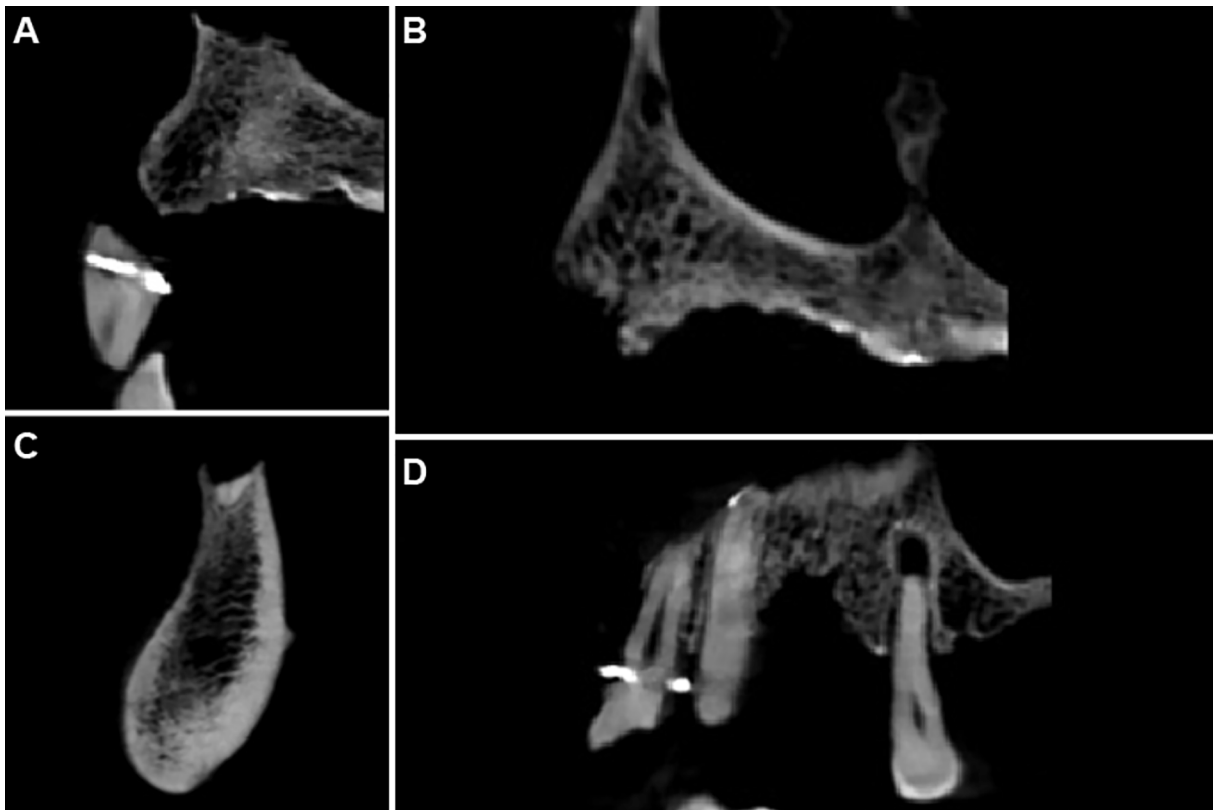


Fig. 6. 3D CBCT imaging analysis. A: Left upper central incisor (tooth 21); B and D: Left upper first premolar (tooth 24), absence of cortical bone; C: Left lower central incisor (tooth 31) apex in the alveolus, showing a post-mortem fracture.

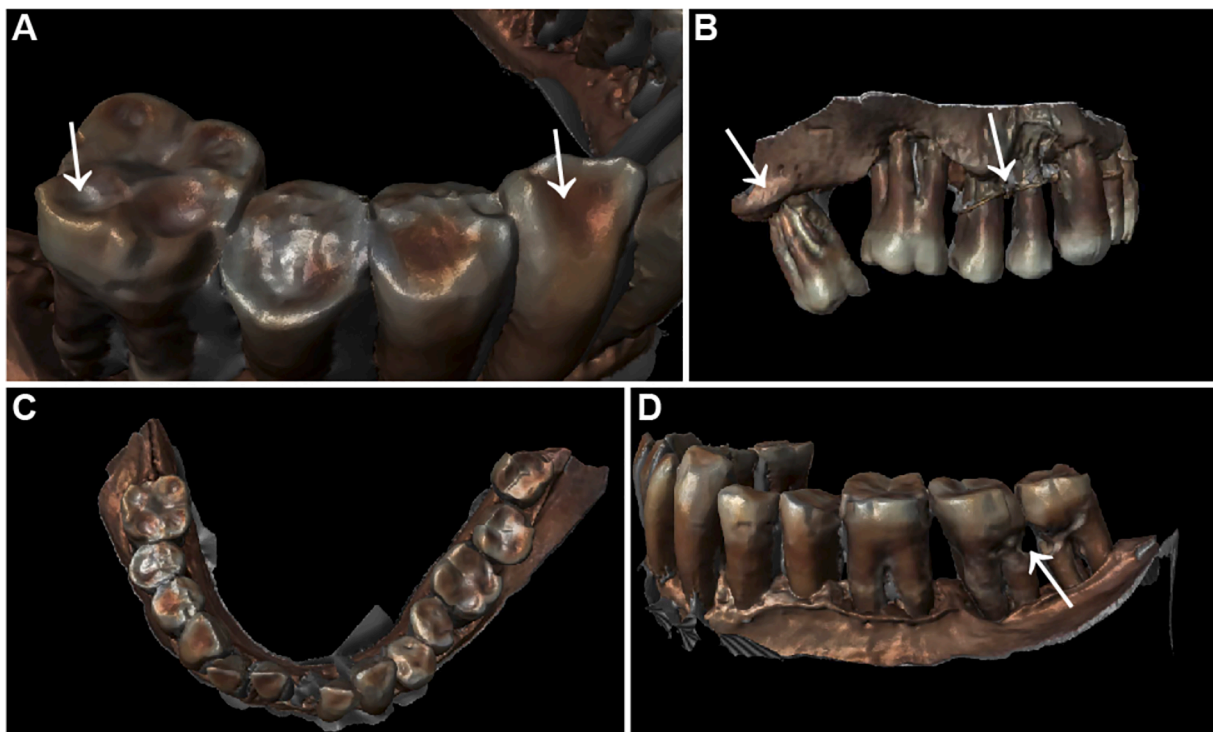


Fig. 7. Screenshots of the visualization of the maxillary and mandibular arch. A and C: Occlusal wear facets of the posterior teeth and the free edges and buccal surfaces wear facets of the anterior teeth. B: Loss of attachment of the molars, regression, and version of molar 18 and the retention bracket. D: Root caries of molars 37 and 38.

- ii. Attrition, especially on the anterior sectors, linked to a probable mandibular sagittal shift due to the loss of posterior teeth in connection with periodontopathy.
- iii. Secondary erosion with the presence of dentinal cups.

#### 4.3. Therapeutic elements

Concerning the therapeutic elements, the presence of a restraint ligature was observed in the form of a ladder ligature with a wire strand between 14 and 15 and mesial of 14 (Fig. 8A, C). This type of element is a ligature of the teeth with a 0.40 mm diameter gold wire. A first wire, the two ends of which are clamped by pliers and pushed back into the interdental space, surrounds the two teeth while a second wire tightens the whole between the teeth. Tooth 21 had been replaced by a prosthetic element made of ivory (Fig. 9). This element was held in place with a doubled wire passing through two tunnels (Fig. 10). The proximal surfaces were concave. These elements contributed to the stability of the prosthetic part (Figs. 8C, 10). The artificial tooth, rectangular, replaced the central right incisor, lost previously. Its macroscopic striated structure evokes the ivory used in modern dentistry, designated by the term Rohart by the famous king's physician Ambroise Paré, contemporary of our case (Paré, 1652.), even if hippopotamus dentin replaced it at the end of the 17th century until the discovery of vulcanite in the 1860 s (Philippe, 2013) (Fig. 9). This mobile tooth was pierced by two holes through which gold wires, finer (0.20 mm diameter) than for the retention prosthesis, were passed. The first wire passed through the tooth from one side to the other, and the other passed through a bucket handle tunnel on the posterior surface. The artificial tooth was thus held in place by the other incisors (Fig. 8A, C). A surface reconstruction of the prosthesis obtained by segmentation is available in STL format for download (Fig. S1).

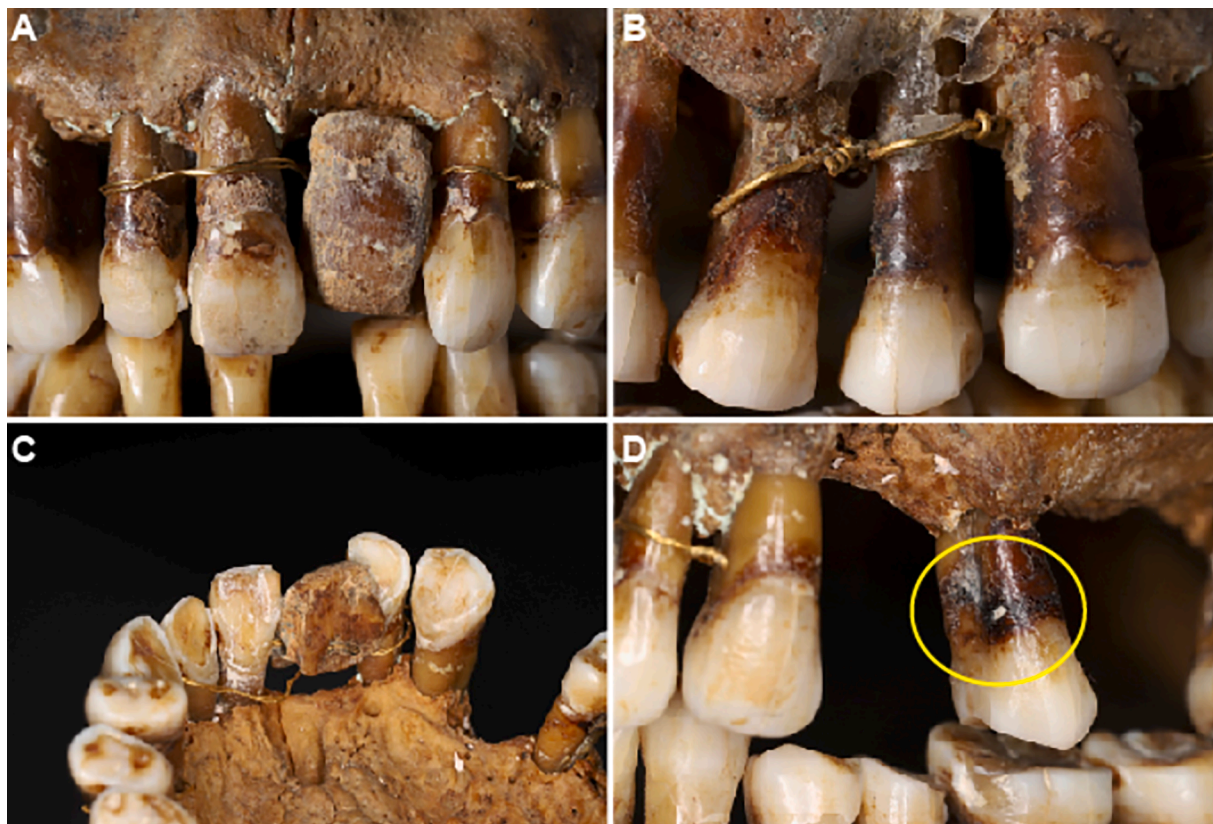
We also note the presence of a ladder ligature with a wire twisted between 14 and 15 and mesial to 14. The gold wire has the same characteristics as the one holding the prosthesis (0.4 mm diameter) (Figs. 2B, 4A, 8B). Symmetrically, traces of wear are visible on the cervical view of 25. They could come from another retention for the central bridge (another retention wire) or another missing prosthesis (Fig. 8D). These restraints were present for both left and right premolars as there are traces of wear on the neck of 25 on the CBCT. These traces of wear indicate the ante-mortem realization and are a sign of long-term use with the possibility of maintenance of these ligatures, such as tightening.

## 5. Discussion

Studies of periodontitis in past populations rely on the examination of collections of dried skulls and pose some technical challenges. A diagnosis of periodontal disease depends on the estimation of attachment levels achieved by examining the hard tissues only, a technique that is not really suitable for the application of standardized case definitions of disease used in current studies.


### 5.1. Analysis of the diagnosis of periodontal disease

To our knowledge, the new classification of periodontal and *peri-implant* diseases (Caton et al., 2018) has never been used in an archaeological context. It brings a new fundamental evaluation for the analysis of the oral condition of ancient populations: the notion of progression of periodontal disease. The interest of the new classification and particularly of its grading system is that it provides information on the progression of periodontitis and the potential impact on systemic health (Caton et al., 2018). This evaluation is made possible by associating



**Fig. 8.** Macroscopic view of the prosthetic element. A, B and D: Vestibular view; C: Occlusal view. B: Vestibular macroscopic view of the ligature between 14 and 15. Note the presence of glue used for the consolidation of the ligature after its discovery. D: Cervical wear of 25 indicating the presence of a ligature or a restraint similar to 14/15.





**Fig. 9.** Microscopic view with Metallurgical Microscope of the prosthetic element (occlusal [A] and apical [B] views) and comparison with hippopotamus dentin (C) and elephant ivory (D).



**Fig. 10.** Orthogonal views of the denture replacing the upper central incisor (tooth 21). The proximal surfaces are concave, which allowed for stabilization. Retention was ensured by a hole dug in the width to insert the retention wire.

visual and radiological examination.

The presence of little tartar on the upper part of the roots and the presence of tartar on the apical part indicate the possibility of the tooth and root surfaces having been brushed or cleaned. In fact, instruments for scaling already existed at that time. Even if the first mentions of dental hygiene were found in inscriptions from Mesopotamian clay tablets (Gurudath et al., 2012), the first toothbrushes would be Chinese and date from the late 15th century (Fischman, 1997). In Europe; the first mentions of brushes date from the early 18th century when the king’s physician, Dionis, recommended “rubbing your teeth with a small sponge every morning” (Philippe, 2016; Dionis, 2012). Before, the scaling technique is already explained by Abul Al-Qasim in the 11th

century and mentioned in the medieval and early modern medical treatises such as Ambroise Paré, contemporary of Anne of Alegre (Paré, 1652.; Philippe, 2014).

Given the loss of height of the jawbone of the maxilla and the mandibular, mobility of the teeth was very likely. Anne d’Alègre must have had difficulty eating hard food. Moreover, the presence of excessive wear of veneers indicates bruxism, pathology commonly associated with severe or chronic psychosocial stress (Foley, 2020; Rai, 2013). In this case, the occlusal instability and bruxism were prior to the periodontitis. Bruxism may even have aggravated the severity of the periodontitis or even possibly caused it. Then again, chronic stress and depression can lead to a general dysregulation of the immune system, both cellular and humoral pathways, which can contribute to pathogenic infection and concomitant destruction of periodontal tissue (Warren et al., 2014).

### 5.2. Restraint Analyses: medical, aesthetic and social implications

Tooth loss, whether accidental, broken or due to decay, leaves an empty space that must be filled to prevent oral imbalances and loosening of the peripheral teeth. However, generally, tooth loss, especially of premolars and molars, is considered a normal part of aging (Peterson, 2003), and the concern for their replacement is still limited to the

wealthiest people in the world's most industrialized countries. Indeed, the loss of teeth concerns globally more the poorest populations, who still benefit today from more rudimentary therapeutic treatments such as the extraction of the tooth because of a cavity (Costa et al., 2012). Also, given the technical complexity of the implementation of a restraint, it is a therapeutic means still largely reserved for the privileged socio-economic classes (Gilbert et al., 2003). Thus, the ability of our ancestors to make such prostheses still amazes us by their technicality and antiquity (Becker, 1999). In archaeology, the few known examples of osseointegrated prostheses and implants concern mostly mono-radicular teeth (incisor and canine) (Teschler-Nicola et al., 1998; Becker, 1999; Cunha et al., 2017), undoubtedly testifying to aesthetic rather than functional considerations (Crubézy et al., 1998). To our knowledge, no case of prosthesis worn on men has been found in archaeology, even if this remark must be temporized since these finds (mostly from Egypt or Etruscan collections) are often ancient or lost since their discovery (Becker and Turfa, 2017; Becker et al., 2003). This lack of documentation impedes an anthropobiological approach to these remains, putting the subject back at the center of the analysis. The case of the two young women from the Neolithic site of Nabla Playa in Egypt (Irish et al., 2003) or the Gallic one from "Le Chêne" in France (Seguin et al., 2014) reinforces this aesthetic prosthesis paradigm. Although the addition of these devices has been known since the Neolithic period (Irish et al., 2003; Irish, 2004; Granat, 1990; Vallois, 1954), their rarity implies an important selection of subjects fitted with them in elite populations. Some of these pieces may have been added after the death of the subject to perpetuate a physical integrity of the corpse (Seguin et al., 2014; Irish et al., 2003; Vallois, 1954; Bocquentin and Aoudia-Chouakri, 2009) or serve only as votive amulets (Becker, 1999). The discovery of compensatory devices also indicates the social status of the subjects, especially when they are purely aesthetic objects. The extent of peripheral wear to the restraints suggests the removal of several restraint threads over time. It implies a dental care budget for the medical follow-up of the patient. The position of the intrasulcular wire is probably the consequence of an aesthetic gesture. These ligatures aggravated the patient's periodontal disease. Indeed, this type of ligature which has the disadvantage of reintroducing dental plaque causes gingival inflammation. This is the experimental device for triggering periodontitis in animals (Bienengraber et al., 1973).

The state of corticalisation of an edentulous site informs us about the age of the edentulism. In contrast to the central incisor (tooth 21), whose bone is corticalized, the canine (tooth 24) is concave and irregular. This informs us that the incisor (tooth 21) had been missing for longer than the canine, and that 24 was lost less than a year before Anne d'Alègre's death. Moreover, the traces of wear left by the gold wires of the incisor prosthesis are similar to those observed on the maxillary premolars. This indicates that the prosthesis and the restraints were worn ante-mortem and for a long time.

The posterior restraints had to have a dual aesthetic and functional indication. In fact, the two contentions were intended to contain the first premolars. In 1557, Francisco Martinez, the dentist of Philip II's Spanish court, warned his readers who wanted to put on false teeth for aesthetic reasons. Therefore, he notes:

"To place a tooth, it must be attached to two others, and with the same force that is used to tighten it, and with the act of attaching and detaching it, either to clean it, or because the wire breaks, or because it moves, or because it is not well put in, inevitably the two to which it is attached will move and for the same reason will fall out; who has put on one, will want to put on three and if one has made two fall, three make more fall and so on. In this way, because she wanted to spend a year with a false tooth, she finds herself for life without her real teeth and with a thousand other sufferings that follow" (Martínez de Castrillo, 2010).

Despite these recommendations, placing a false tooth was probably not only for therapeutic or aesthetic purposes. We have noted that the

bruxism observed on Anne d'Alègre could be the sign of important stress states. Although the chronicles of the time presented her as being on the lookout for new and luxurious fashions, and "riding in carriages" to go to preach on Sundays. (Colleter et al., 2011). Her artificial teeth were probably not just a coquetry on her part. The various widowhood she experienced undoubtedly contributed to her anxiety, and few women in modern times choose the freedom that widowhood gives them (Colleter et al., 2021). She was married to Paul de Coligny from 1583 to 1586 and then to Guillaume IV d'Hautemere from 1599 to 1613. At the age of 48, when she was widowed a second time, she also lost her child, Guy XX de Laval, killed in a battle in Hungary.

Her periods of widowhood were undoubtedly complicated in a 17th century society where stereotypes and patriarchy were prevalent (Conroy and Women, 2015). Furthermore; it is important to remember that at that time, physical appearance was still considered to be related to a person's intrinsic qualities (Weeda, 2021). Therefore; in accordance with the Hippocratic theory of humors in vogue in post-renaissance medical circles, any imbalance threatens the health of the subject, which is itself linked to one's own sins (Wallis, 2010). The appearance of the person; moreover noble, is an essential social element. Ambroise Paré notes that if the patient remains toothless and disfigured, his speech also becomes depraved (Paré, 1652.). Beyond the only aesthetic aspects, the installation of a dental prosthesis, and despite the possible odontological complications and known at that time, perhaps allowed Anne d'Alègre to maintain a certain social rank in front of her detractors.

## 6. Conclusion

The tools of current clinical practice allow for further analysis of oral examinations of past populations. Here, with the new classification of periodontal and *peri*-implant diseases associated with digital tools (CBCT examination, intraoral CT scan), an innovative approach to oral assessment is presented. It also allows us to characterize privileged subjects who benefit from dental care. Putting the subject at the center of the paleopathological analysis, the study of Anne d'Alègre's dental care allows a better understanding of the modern society that surrounds her, her choices, beyond the only therapeutic or aesthetic considerations.

## Declaration of Competing Interest

The authors declare that they have no known competing financial interests or personal relationships that could have appeared to influence the work reported in this paper.

## Data availability

Data will be made available on request.

## Acknowledgments

The skeleton of Anne d'Alègre (ML-OST-A-0433 to ML-OST-A-0632) is preserved at the Museum of Sciences of Laval that we thank for its availability. This work was supported by the Fossil team (Forensic Sciences and the Study of Image Libraries) of the Centre for Anthropobiology and Genomics of Toulouse – UMR 5288 (CNRS/UT3) and the Marie Skłodowska-Curie individual fellowship, AIDE project for Rozenn Colleter (grant 897565). We also thank the anonymous reviewers who improved the quality of this paper with their constructive comments.

## Appendix A. Supplementary data

Supplementary data to this article can be found online at <https://doi.org/10.1016/j.jasrep.2022.103794>.

## References

- Al-Mutairi, R., Liversidge, H., Gillam, D.G., 2022. Prevalence of Moderate to Severe Periodontitis in an 18–19th Century Sample—St. Bride's Lower Churchyard (London, UK). *Dentistry J.* 10, 56. <https://doi.org/10.3390/dj10040056>.
- Bagis, N., Camgoz, M., 2022. Periodontal diseases in Antiquity. *Bull. Int. Assoc. Paleodentol.* 16, 22–27. <https://hrcaac.srce.hr/ojs/index.php/paleodontology/article/view/21075>.
- Barreau, J.-B., Gagnier, A., Gagne, R., Marchand, G., Gómez, J.C., Gouranton, V., Colleter, R., 2022. Use of Different Digitization Methods for the Analysis of Cut Marks on the Oldest Bone Found in Brittany (France). *Appl. Sci.* 12, 1381. <https://doi.org/10.3390/app12031381>.
- Becker, M.J., 1999. Etruscan Gold Dental Appliances: Three Newly “Discovered” Examples. *Am. J. Archaeol.* 103, 103–111. <https://doi.org/10.2307/506579>.
- Becker, M.J., 1999. Ancient “Dental Implants”: A Recently Proposed Example from France Evaluated with Other Spurious Examples. *Int. J. Oral Maxillofac. Implants* 14, 19–29.
- Becker, M.J., 2003. Etruscan Gold Dental Appliances: Evidence for Early Perting of Gold in Italy through the Study of Ancient Pontics, in: G. Tsoucaris, J. Lipkowski (Eds.), *Molecular and Structural Archaeology: Cosmetic and Therapeutic Chemicals*, NATO Science Series.
- Becker, M.J., Turfa, J.M., 2017. *The Etruscans and the History of Dentistry: The Golden Smile through the Ages*. Routledge.
- Benazzi, S., Orlandi, M., Gruppioni, G., 2009. Technical note: Virtual reconstruction of a fragmentary clavicle. *Am. J. Phys. Anthropol.* 138, 507–514. <http://onlinelibrary.wiley.com/doi/10.1002/ajpa.20997>.
- Bertl, K., Tangl, S., Rybaczek, T., Berger, B., Traindl-Prohazka, M., Schuller-Götzburg, P., Grossschmidt, K., 2020. Prevalence and severity of periodontal disease in a historical Austrian population. *J. Periodontol. Res.* 55, 931–945. <https://doi.org/10.1111/jre.12785>.
- Bienengraber, V., Sonnenburg, I., Wilken, J., 1973. *Clinical and animal experimental studies on the effect of wire splinting on the marginal periodontium*. Dtsch. Stomatol. 23, 86–94.
- Bocquentin, F., Aoudia-Chouakri, L., 2009. *Le crâne modifié et surmodélé de Faïd Souar II (Capsien, Algérie) Masque, trophée ou rite funéraire ?*, Cahier Des Thèmes Transversaux ArScAn. IX 171–178.
- Carlsson, G.E., Egermark, I., Magnusson, T., 2003. Predictors of bruxism, other oral parafunctions, and tooth wear over a 20-year follow-up period. *J. Orofac. Pain* 17, 50–57. <https://pubmed.ncbi.nlm.nih.gov/12756931/>.
- Caton, J.G., Armitage, G., Berglundh, T., Chapple, I.L.C., Jepsen, S., Kornman, K.S., Mealey, B.L., Papananou, P.N., Sanz, M., Tonetti, M.S., 2018. A new classification scheme for periodontal and peri-implant diseases and conditions - Introduction and key changes from the 1999 classification. *J. Clin. Periodontol.* 45 (Suppl 20), S1–S8. <https://doi.org/10.1111/jcpe.12935>.
- Chattah, N.-L.-T., Smith, P., 2006. Variation in occlusal dental wear of two Chalcolithic populations in the southern Levant. *Am. J. Phys. Anthropol.* 130, 471–479. <https://doi.org/10.1002/ajpa.20388>.
- Colleter, R., Adèle, P.-A., 2019. Les restes humains archéologiques en France : entre objets de science et sujets de droit. *Can. J. Bioethics/Revue Canadienne de Bioéthique.* 2, 97–108. <https://doi.org/10.7202/1066467ar>.
- Colleter, R., Charlier, P., Tréguier, J., 2011. *Les derniers jours des comtes de Laval. Étude ostéo-archéologique des restes de Guy XX et d'Anne d'Alègre*. In: Charlier, P. (Ed.), *Actes Du IIIe Colloque International De Pathographie*. De Boccard, Bourges, pp. 449–500.
- Colleter, R., Dedouit, F., Duchesne, S., Mokrane, F.-Z., Gendrot, V., Gérard, P., Dabernat, H., Crubézy, É., Telmon, N., 2016. Procedures and Frequencies of Embalming and Heart Extractions in Modern Period in Brittany. Contribution to the Evolution of Ritual Funerary in Europe. *PLOS ONE* 11, e0167988. <https://doi.org/10.1371/journal.pone.0167988>.
- Colleter, R., Pichot, D., Crubézy, É., 2021. *Louise de Quengo : une bretonne du XVIIe siècle*. Archéologie, anthropologie, histoire. Presses Universitaires de Rennes, Rennes.
- Conroy, D., Women, R., 2015. *Volume 1: Government, Virtue, and the Female Prince in Seventeenth-Century France*. Springer.
- Corbineau, R., Ruas, M.-P., Barbier-Pain, D., Fornaciari, G., Dupont, H., Colleter, R., 2017. Plants and aromatics for embalming in Late Middle Ages and modern period: a synthesis of written sources and archaeobotanical data (France, Italy). *Veg. Hist. Archaeobotany* 1–14. <https://doi.org/10.1007/s00334-017-0620-4>.
- Costa, S.M., Martins, C.C., Bonfim, M. de L.C., Zina, L.G., Paiva, S.M., Pordeus, I.A., Abreu, M.H.N.G., 2012. A systematic review of socioeconomic indicators and dental caries in adults. *Int. J. Environ. Res. Public Health.* 9 (2012) 3540–3574. [10.3390/ijerph9103540](https://doi.org/10.3390/ijerph9103540).
- Crubézy, É., Murail, P., Girard, L., Bernadou, J.-P., 1998. False teeth of the Roman world. *Nature* 391, 29. <https://doi.org/10.1038/34067>.
- Cucina, A., Herrera Atoche, R., Chatters, J.C., 2019. Oral health and diet of a young Late Pleistocene woman from Quintana Roo, Mexico. *Am. J. Phys. Anthropol.* 170, 246–259. <https://doi.org/10.1002/ajpa.23884>.
- Cunha, E., Leal, C., Munhós, M., Baptista, I.P., 2017. The gold nun: a case of a gold ligature from the 15th century and the origins of restorative dentistry in Europe. *Anthropologischer Anzeiger*, pp. 347–353.
- Debouige, P., Delattre, V., 2021. Un implant dentaire moderne (XVIème-XVIIIème siècle) mis au jour dans l'église des Billetes (Paris, 4ème arrondissement), Carnet Hypothèses Archéologie du handicap. <https://archohandi.hypotheses.org/588> (accessed September 12, 2022).
- Delattre, V., 2018. *Handicap : quand l'archéologie nous éclaire*. Universciences, Inrap, Éditions Le Pommier <https://www.editions-lepommier.fr/handicap-quand-larcheologie-nous-eclaire> (accessed June 29, 2020).
- Dionis, P., 2012. *L'anatomie de l'homme suivant la circulation du sang, & les dernières découvertes* (éd. 1690), Hachette Livre - BNF, 2012. <https://www.abebooks.fr/9782012565869/Lanatomie-lhomme-circulation-sang-derni%C3%AF%C2%BF%C2%BDres-2012565867/plp> (accessed September 14, 2022).
- Ericsson, I., Giargia, M., Lindhe, J., Neiderud, A.M., 1993. Progression of periodontal tissue destruction at splinted/non-splinted teeth. An experimental study in the dog. *J. Clin. Periodontol.* 20, 693–698. <https://doi.org/10.1111/j.1600-051x.1993.tb00693.x>.
- Esclarian, R., Grimoud, A.M., Ruas, M.P., Donat, R., Sevin, A., Astie, F., Lucas, S., Crubezy, E., 2009. Dental caries, tooth wear and diet in an adult medieval (12th–14th century) population from mediterranean France. *Arch. Oral Biol.* 54, 287–297. <https://doi.org/10.1016/j.archoralbio.2008.11.004>.
- Fischman, S.L., 1997. The history of oral hygiene products: how far have we come in 6000 years? *Periodontol* 2000 (15), 7–14. <https://doi.org/10.1111/j.1600-0757.1997.tb00099.x>.
- Foley, A.J., 2020. The daily grind: Assessing bruxism as a potential indicator of stress in archaeological human remains. *J. Archaeol. Sci.* 117, 105117. <https://doi.org/10.1016/j.jas.2020.105117>.
- Fourie, Z., Damstra, J., Gerrits, P.O., Ren, Y., 2011. Evaluation of anthropometric accuracy and reliability using different three-dimensional scanning systems. *Forensic Sci. Int.* 207, 127–134. <https://doi.org/10.1016/j.forsciint.2010.09.018>.
- Garcia de Leon Valenzuela, M.J., Julia, M., 2014. Three-dimensional image technology in forensic anthropology: assessing the validity of biological profiles derived from CT-3D images of the skeleton. <https://open.bu.edu/handle/2144/15358> (accessed March 11, 2022).
- Gilbert, G.H., Paul Duncan, R., Shelton, B.J., 2003. Social Determinants of Tooth Loss, *Health Serv Res.* 38, 1843–1862. [10.1111/j.1475-6773.2003.00205.x](https://doi.org/10.1111/j.1475-6773.2003.00205.x).
- Gonçalves, P.C.G., Griffiths, G., Rawlinson, A., 2015. A study of the periodontal state of a late Medieval United Kingdom population. *Arch. Oral Biol.* 60, 1797–1801. <https://doi.org/10.1016/j.archoralbio.2015.07.008>.
- Granat, J., 1990. *L'implantologie aurait-elle 7000 ans ? L'information Dentaire.* 22, 1959–1961.
- Grine, F.E., Sponheimer, M., Ungar, P.S., Lee-Thorp, J., Teaford, M.F., 2012. Dental microwear and stable isotopes inform the paleoecology of extinct hominins. *Am. J. Phys. Anthropol.* 148, 285–317. <https://doi.org/10.1002/ajpa.22086>.
- Guan, Y., Wang, C., Zhou, Z., Cheng, J., Cao, J., Ta, L., Xiong, Z., 2022. Evidence from plant starch residues of the function of early pottery and the plant diet of Neolithic inhabitants of Inner Mongolia, North China. *Quat. Int.* 608–609, 215–225. <https://doi.org/10.1016/j.quaint.2020.10.010>.
- Gurudath, G., Vijayakumar, K.V., Arun, M., 2012. *Oral hygiene practices: ancient historical review*. *J. Orofacial Res.* 2, 225–227.
- Heike, C.L., Cunningham, M.L., Hing, A.V., Stuhagy, E., Starr, J.R., 2009. Picture perfect? Reliability of craniofacial anthropometry using three-dimensional digital stereophotogrammetry. *Plast Reconstr Surg.* 124, 1261–1272. <https://doi.org/10.1097/PRS.0b013e3181b454bd>.
- Hildebolt, C., Molnar, S., 1991. Measurement and description of periodontal disease in anthropological studies, in: *Advances in Dental Anthropology*, Wiley-Liss, New York, pp. 225–240.
- Irish, J.D., 2004. A 5,500 year old artificial human tooth from Egypt: a historical note. *Int. J. Oral Maxillofac. Implants* 19, 645–647.
- Irish, J.D., Kobusiewicz, M., Schild, R., Wendorf, F., 2003. Neolithic Tooth Replacement in Two Disturbed Burials from Southern Egypt. *J. Archaeol. Sci.* 30, 281–285. <https://doi.org/10.1006/jasc.2002.0835>.
- Kathariya, R., Devanoorkar, A., Golani, R., Shetty, N., Vallakatta, V., Bhat, M.Y.S., 2016. To Splint or Not to Splint: The Current Status of Periodontal Splinting. *J. Int. Acad. Periodontol.* 18, 45–56. <https://pubmed.ncbi.nlm.nih.gov/27128157/>.
- Keenleyside, A., Schwarcz, H., Stirling, L., Ben Lazreg, N., 2009. Stable isotopic evidence for diet in a Roman and Late Roman population from Leptiminus, Tunisia. *J. Archaeol. Sci.* 36, 51–63. <https://doi.org/10.1016/j.jas.2008.07.008>.
- Khan, F., Young, W.G., Daley, T.J., 1998. Dental erosion and bruxism. A tooth wear analysis from South East Queensland, Australian. *Dental J.* 43, 117–127. <https://doi.org/10.1111/j.1834-7819.1998.tb06100.x>.
- Lagan, E.M., Ehrlich, D.E., 2021. An improved method for measuring molar wear. *Am. J. Phys. Anthropol.* 174, 832–838. <https://doi.org/10.1002/ajpa.24238>.
- Mare, E., 1987. *Chapelle du château de Laval (Mayenne)*, Direction des antiquités historiques des Pays de la Loire.
- Martínez de Castrillo, F., 2010. Coloquio breve y compendioso sobre la materia de la dentadura y maravillosa obra de la boca (1557), De Boccard. <https://www.leslibraires.fr/livre/1865154-coloquio-breve-y-compendioso-sobre-la-materia-d-francisco-martinez-de-castrillo-de-boccard> (accessed August 19, 2021).
- Meller, C., Urzua, I., Moncada, G., von Ohle, C., 2009. Prevalence of oral pathological findings in an ancient pre-Columbian archeological site in the Atacama Desert. *Oral Dis.* 15, 287–294. <https://doi.org/10.1111/j.1601-0825.2009.01524.x>.
- Moisdon, E., Rigaud, P.-J., 1992. Étude anthropologique du squelette présumé d'Anne d'Alègre, A la rencontre d'Anne d'Alègre, dame de Laval (v. 1565-1619), 53–78.
- Mokrane, F.Z., Colleter, R., Duchesne, S., Gerard, P., Savall, F., Crubézy, É., Guilbaud-Frugier, C., Moreno, R., Sewonu, A., Rousseau, H., Telmon, N., Dedouit, F., 2016. Old hearts for modern investigations: CT and MR for archaeological human hearts remains. *Forensic Sci. Int.* 14–24. <https://doi.org/10.1016/j.forsciint.2016.08.035>.
- Nyvad, B., 2004. Diagnosis versus detection of caries. *Caries Res.* 38, 192–198. <https://doi.org/10.1159/000077754>.
- Omari, R., Hunt, C., Coumbaros, J., Chapman, B., 2021. Virtual anthropology? Reliability of three-dimensional photogrammetry as a forensic anthropology

- measurement and documentation technique. *Int. J. Legal Med.* 135, 939–950. <https://doi.org/10.1007/s00414-020-02473-z>.
- Papapanou, P.N., 1999. Epidemiology of periodontal diseases: an update. *J. Int. Acad. Periodontol.* 1, 110–116. <https://pubmed.ncbi.nlm.nih.gov/12666955/>.
- Paré, A., 1652. Les oeuvres d'Ambroise Paré, conseiller et premier chirurgien du Roy, chez Pierre Rigaud, Lyon, <http://books.google.fr/books?id=n1NbuVL4VzkC&pg=PA294&lpg=PA294&dq=embaumement+ambroise+par%C3%A9&source=bl&ots=fBLNovZO7u&sig=7URcHRVx4uZasa5M2O7WR44UoQ&hl=fr&sa=X&ei=bBjzU8KXEMq30QW58oGQDw&ved=0CDAQ6AEwAA#v=onepage&q=embaumement%20ambroise%20par%C3%A9&f=true>.
- Peterson, P.E., 2003. The world oral health report 2003 : continuous improvement of oral health in the 21st century - the approach of the WHO Global Oral Health Programme, Geneva. <http://www.who.int/iris/handle/10665/68506> (accessed March 5, 2019).
- Philippe, J., 2013. L'hippopotame et la prothèse dentaire. *Actes Société Française d'histoire de l'art Dentaire.* 18, 57–60.
- Philippe, J., 2014. La chirurgie dentaire d'Ambroise Paré. *The dental surgery of Ambroise Paré, Actes de La Société Française d'histoire de l'art Dentaire.* 19, 63–65.
- Philippe, J., 2016. La chirurgie dentaire de Pierre Dionis (1643–1718). *The dental surgery of Pierre Dionis (1643–1718), Actes de La Société Française d'histoire de l'art Dentaire.* 21, 20–22.
- Rai, A., 2013. Richard III – the final act. *Br. Dent. J.* 214, 415–417. <https://doi.org/10.1038/sj.bdj.2013.378>.
- Raitapuro-Murray, T., Molleson, T.I., Hughes, F.J., 2014. The prevalence of periodontal disease in a Romano-British population c. 200–400 AD. *Br. Dent. J.* 217, 459–466. <https://doi.org/10.1038/sj.bdj.2014.908>.
- Rajshekar, M., Julian, R., Williams, A.-M., Tennant, M., Forrest, A., Walsh, L.J., Wilson, G., Blizzard, L., 2017. The reliability and validity of measurements of human dental casts made by an intra-oral 3D scanner, with conventional hand-held digital callipers as the comparison measure. *Forensic Sci. Int.* 278, 198–204. <https://doi.org/10.1016/j.forsciint.2017.07.009>.
- Reinhard, K.J., Danielson, D.R., 2005. Pervasiveness of phytoliths in prehistoric southwestern diet and implications for regional and temporal trends for dental microwear. *J. Archaeol. Sci.* 32, 981–988. <https://doi.org/10.1016/j.jas.2005.01.014>.
- Romero, A., Galbany, J., De Juan, J., Pérez-Pérez, A., 2012. Brief communication: Short- and long-term in vivo human buccal-dental microwear turnover. *Am. J. Phys. Anthropol.* 148, 467–472. <https://doi.org/10.1002/ajpa.22054>.
- Ruas, M.-P., 1992. Matière d'embaumement dans la sépulture du château de Laval : analyse des graines., A la rencontre d'Anne d'Alègre, dame de Laval (v. 1565-1619), 87–91.
- Seguin, G., d'Incau, E., Murail, P., Maureille, B., 2014. The earliest dental prosthesis in Celtic Gaul? The case of an Iron Age burial at Le Chêne, France. *Antiquity* 88, 488–500. <https://doi.org/10.1017/S0003598X00101139>.
- Serio, F.G., 1999. Clinical rationale for tooth stabilization and splinting. *Dent. Clin. N. Am.* 43, 1–6. <http://www.sciencedirect.com/science/article/abs/pii/S0011853222005031>.
- Teschler-Nicola, M., Kneissel, M., Brandstätter, F., Prossinger, H., 1998. A Recently Discovered Etruscan Dental Bridgework, in: K.W. Alt, F.W. Röding, M. Teschler-Nicola (Eds.), *Dental Anthropology. Fundamentals, Limits, and Prospects*, Springer-Verlag, Wien New York, pp. 57–68. [10.13140/RG.2.1.4666.8881](https://doi.org/10.13140/RG.2.1.4666.8881).
- Vallois, H.V., 1954. Le crâne trophée capsien de Faïd Souar II, Algérie (Fouilles Laplace). *L'Anthropologie.* 5–6 (1971), 397–414.
- Wallis, F., 2010. *Medieval Medicine: A Reader*. University of Toronto Press.
- Warren, K.R., Postolache, T.T., Groer, M.E., Pinjari, O., Kelly, D.L., Reynolds, M.A., 2014. Role of chronic stress and depression in periodontal diseases. *Periodontology 2000* (64), 127–138. <https://doi.org/10.1111/prd.12036>.
- Weeda, C., 2021. Ethnicity in Medieval Europe, 950–1250. *Power and Religion*, Boydell Press, York Medieval Press, Medicine <https://boydellandbrewer.com/9781914049019/ethnicity-in-medieval-europe-950-1250/> (accessed April 8, 2022).
- Willmann, C., Mata, X., Hanghoej, K., Tonasso, L., Tisseyre, L., Jeziorski, C., Cabot, E., Chevet, P., Crubézy, E., Orlando, L., Esclassan, R., Thèves, C., 2018. Oral health status in historic population: Macroscopic and metagenomic evidence. *PLoS One* 13, e0196482.