



HAL
open science

AGR2 protein expression in colorectal tumour epithelialcompartment

Eric Chevet, F Bassal, Stéphanie Beq, Benjamin Bonhomme, Emeric Boisteau, Julien Calloch, Dominique Cazals-Hatem, Frederic Delom, Delphine Fessart, Serge Evrard, et al.

► **To cite this version:**

Eric Chevet, F Bassal, Stéphanie Beq, Benjamin Bonhomme, Emeric Boisteau, et al.. AGR2 protein expression in colorectal tumour epithelialcompartment. Gut, 2022, pp.gutjnl-2022-328739. 10.1136/gutjnl-2022-328739 . hal-03930716

HAL Id: hal-03930716

<https://univ-rennes.hal.science/hal-03930716>

Submitted on 23 Jan 2023

HAL is a multi-disciplinary open access archive for the deposit and dissemination of scientific research documents, whether they are published or not. The documents may come from teaching and research institutions in France or abroad, or from public or private research centers.

L'archive ouverte pluridisciplinaire **HAL**, est destinée au dépôt et à la diffusion de documents scientifiques de niveau recherche, publiés ou non, émanant des établissements d'enseignement et de recherche français ou étrangers, des laboratoires publics ou privés.

AGR2 protein expression in colorectal tumour epithelial compartment

We read with great interest the manuscript by Tian *et al* published in *Gut*. Tian *et al* report that in colorectal cancer (CRC) at stages III/IV, the presence of extracellular AGR2 in the tumour environment is due to its secretion by tumour-associated neutrophils (TANs). This, in turn, promotes tumour cells migration and invasion. Although these findings are original and exciting, it is essential to put them in the context of the biology of anterior gradient (AGR) proteins.

AGR2 is the most studied member of the AGR family, which contains three proteins¹ and belongs to the superfamily of protein disulfide isomerases. AGR1-3 exhibit all the features of endoplasmic reticulum (ER) resident proteins by containing a signal peptide and an ER retention motif. AGR2 and AGR3 can be secreted in the extracellular milieu to trigger cell migration,² and for AGR2 only, epithelial-to-mesenchymal transition,³ chemoattraction of monocytes⁴ and myofibroblast activation.^{5,6} Moreover, AGR2 is strongly expressed in endoderm-derived organs (lung stomach, colon prostate, intestine) and as such, is almost exclusively expressed in mucosal epithelial cells.¹ Its overexpression has been associated with tumour aggressiveness in various cancers.¹

Tian *et al* claim that in CRC, AGR2 is only produced by tumour-infiltrating neutrophils (TANs) which impacts on the migration of CRC cells through the activation of signalling pathways depending on CD98hc-cCT and Rho GTPases. Although this result is interesting, it is surprising that no expression of AGR2 is detected in tumour epithelial cells. We aimed at further documenting the expression levels of AGR2 protein in TAN-infiltrated CRC. To do so, 21 CRC samples from our European institutions and covering 3 aetiologies including microsatellite stable (MSS) and mismatch repair and instable (MSI) adenocarcinomas (ADK) and CRC from patients with inflammatory bowel disease (IBD) associated with primary sclerosing cholangitis (IBD+PSC) or not (IBD-CRC) at stages III/IV. These samples were processed for immunohistochemistry with anti-AGR2 (anti-AGR2 (M03) 1C3, Abnova, 1/800) and anti-MPO antibody as a neutrophil marker (anti-MPO (MAB3174), R&D System, 1/1000) and the images quantified (figure 1A,B). We

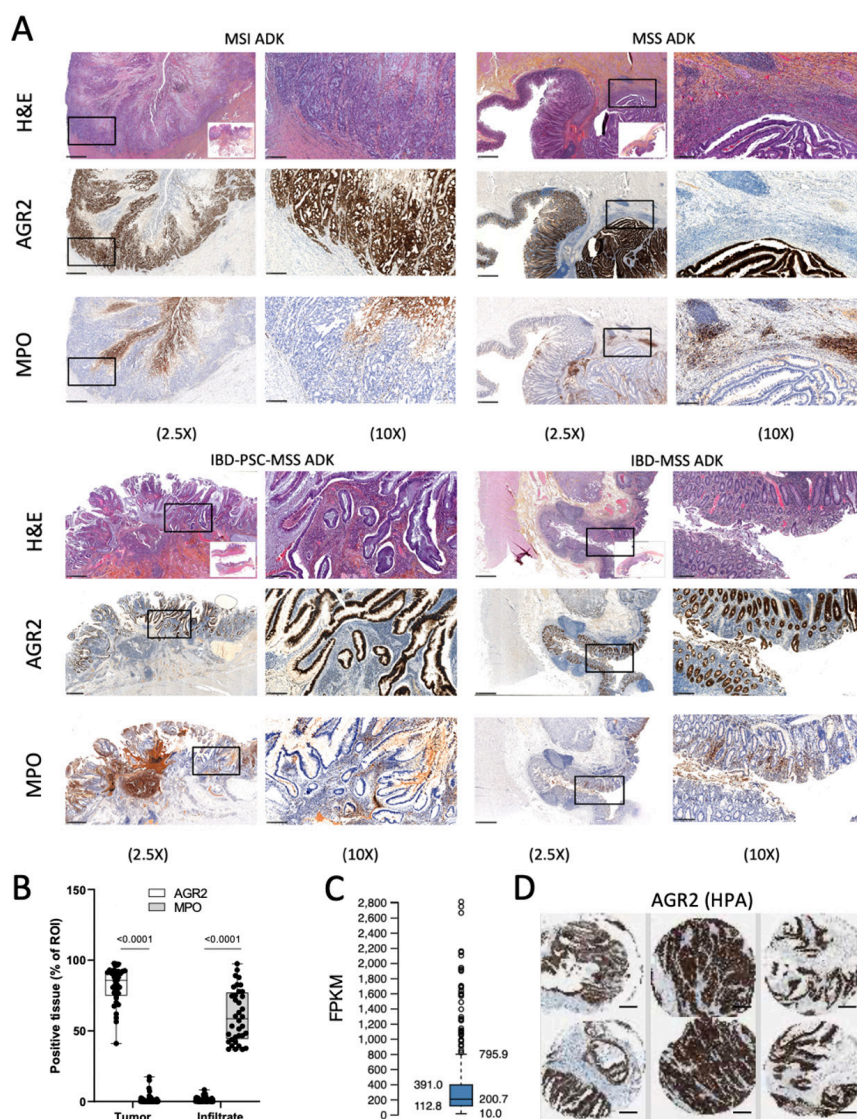


Figure 1 Colonic tumorous epithelial cells are the predominant cell type expressing AGR2 in infiltrated colorectal cancer (CRC). (A) Representative images of immunohistochemistry staining for AGR2 and myeloperoxidase (MPO) in CRC tissues from patients with colorectal cancer at stage III/IV and corresponding H&E-stained histological sections. IBD-PSC-MSS AdK, adenocarcinoma from patients with inflammatory bowel disease+primary sclerosing cholangitis; IBD-MSS AdK, adenocarcinoma from patients with IBD; MSI AdK, microsatellite instable adenocarcinoma; MSS AdK, microsatellite stable adenocarcinoma; (B) Semiquantitative analysis of AGR2 and MPO staining on CRC tumours. The expression of AGR2 and MPO is mutually exclusive in all infiltrated CRC—tumour cells express AGR2 whereas the infiltrate exclusively expresses MPO. (C) AGR2 mRNA expression measured by RNA-sequencing in 597 colorectal cancers (FPKM: fragment per kilobase million). (D) Examples of AGR2 protein expression in colorectal cancers. Data extracted from the human protein atlas (<https://www.proteinatlas.org/about/licence>).





also show data from the Human Protein Atlas⁷ (figure 1C,D).

Mutually exclusive staining of AGR2 and MPO in CRC stages III/IV from various aetiologies were found thereby indicating that if TAN do express AGR2, it is marginal (figure 1A). Riener *et al*⁸ showed that AGR2 expression is lost or decreased in the majority of left-sided CRC, and is significantly associated with reduced overall patient survival suggesting

that AGR2 might be a tumour suppressor. However, these results neither did correspond to the Tian *et al* article nor to their previous report⁹ in which results in discrepancies were speculated to come from variabilities in subjects or experimentalists. Hence one should rely on large international cohorts of patients with CRC to link AGR2 expression to specific aetiologies. Recent results from our laboratories did not confirm AGR2 loss of expression

in CRC but showed that high AGR2 expression correlated with longer patient survival, likely due to the high expression of AGR2 in MSI tumours that respond better to treatments/immunotherapies.¹⁰

To sum up, AGR2 is expressed in epithelial cells and overexpressed in CRC. Moreover, data compiled on more than 21 CRC samples with different aetiologies and from different centres show mutually exclusive staining of AGR2 (in tumour cells) and MPO in TANs. As such, the report by Tian *et al* is opposite to the general trend observed, and thus should be considered with careful attention before any definitive conclusion is raised.

Eric Chevet ^{1,2,3}, F Bassal,⁴ Stéphanie Beq,⁴ Benjamin Bonhomme ⁵, Emeric Boisteau,^{1,6} Julien Calloch,⁴ Dominique Cazals-Hatem,⁷ Frederic Delom ^{8,9}, Delphine Fessart,^{8,9} Serge Evrard,^{5,8} Roman Hrstka,¹⁰ ted hupp,¹¹ Astrid Lièvre,⁶ Edouard Louis,¹² Jeremie Mariau,⁴ Marie-Alice Meuwis,¹² Eric Ogier-Denis ^{1,2,3}, Valerie Paradis,¹³ Simon Pernot,⁵ R Pineau,^{1,2,3} Xavier Treton,¹⁴ Valerie Velasco,⁵ Sophie Vieujean¹²

¹U1242, INSERM, Rennes, France

²Centre de Lutte Contre le Cancer Eugene Marquis, Rennes, France

³University of Rennes, Rennes, France

⁴Thabor Therapeutics, Paris, France

⁵Institut Bergonié, Bordeaux, France

⁶Department of Gastroenterology, CHU Rennes, Rennes, France

⁷Gastroenterology, IBD and intestinal failure department, Beaujon Hospital, Clichy, France

⁸Bordeaux II University, Talence, France

⁹U1312, INSERM, Bordeaux, France

¹⁰Masaryk Memorial Cancer Institute, Brno, Czech Republic

¹¹University of Edinburgh, Edinburgh, UK

¹²Hepato-gastroenterology and digestive oncology, University Hospital CHU of Liège and laboratory of translational gastroenterology, GIGA institute, ULiège, Liège, Belgium

¹³Pathology, Assistance Publique-Hôpitaux de Paris (AP-HP), Clichy, France

¹⁴Gastroenterology Department, Hôpital Beaujon, MCI et Assistance Nutritive, APHP, Paris, France

Correspondence to Dr Eric Chevet, U1242, INSERM, Rennes, France; Eric.chevet@inserm.fr

Contributors All the authors contributed to the manuscript through several cycles of reading and corrections. DC-H, SE, BB, VV, VP, XT, EB, M-AM, AL analysed the immunostainings.

Funding This study was funded by Institut National Du Cancer (PLBIO).

Competing interests EC, EO-D and XT are founding members of Thabor Tx.

Patient consent for publication Consent obtained directly from patient(s).

Ethics approval This study was approved by our local Ethics Committee (NFS96900) and the French Ministry of Research (no 12.739) in accordance with the European legislation. Participants gave informed consent to participate in the study before taking part.

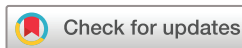Provenance and peer review Not commissioned; externally peer reviewed.



OPEN ACCESS

Open access This is an open access article distributed in accordance with the Creative Commons Attribution Non Commercial (CC BY-NC 4.0) license, which permits others to distribute, remix, adapt, build upon this work non-commercially, and license their derivative works on different terms, provided the original work is properly cited, appropriate credit is given, any changes made indicated, and the use is non-commercial. See: <http://creativecommons.org/licenses/by-nc/4.0/>.

© Author(s) (or their employer(s)) 2022. Re-use permitted under CC BY-NC. No commercial re-use. See rights and permissions. Published by BMJ.



To cite Chevet E, Bassal F, Beq S, *et al*. Gut Epub ahead of print: [please include Day Month Year]. doi:10.1136/gutjnl-2022-328739

Received 20 September 2022

Accepted 1 November 2022

Gut 2022;0:1–2. doi:10.1136/gutjnl-2022-328739

ORCID iDs

Eric Chevet <http://orcid.org/0000-0001-5855-4522>

Benjamin Bonhomme <http://orcid.org/0000-0002-5082-1347>

Frederic Delom <http://orcid.org/0000-0002-4600-7633>

Eric Ogier-Denis <http://orcid.org/0000-0002-0057-7593>

REFERENCES

- Boisteau E, Posseme C, Di Modugno F, *et al*. Anterior gradient proteins in gastrointestinal cancers: from cell biology to pathophysiology. *Oncogene* 2022;41:4673–85.
- Obacz J, Sommerova L, Sicari D, *et al*. Extracellular AGR3 regulates breast cancer cells migration via Src signaling. *Oncol Lett* 2019;18:4449–56.
- Fessart D, Domblides C, Avril T, *et al*. Secretion of protein disulphide isomerase AGR2 confers tumorigenic properties. *Elife* 2016;5:e13887.
- Maurel M, Obacz J, Avril T, *et al*. Control of anterior gradient 2 (AGR2) dimerization links endoplasmic reticulum proteostasis to inflammation. *EMBO Mol Med* 2019;11.
- Merugu SB, Zhou B, Mangukiya HB, *et al*. Extracellular AGR2 activates neighboring fibroblasts through endocytosis and direct binding to β -catenin that requires AGR2 dimerization and adhesion domains. *Biochem Biophys Res Commun* 2021;573:86–92.
- Vieujean S, Hu S, Bequet E, *et al*. Potential role of epithelial endoplasmic reticulum stress and anterior gradient protein 2 homologue in crohn's disease fibrosis. *J Crohns Colitis* 2021;15:1737–50.
- Uhlén M, Fagerberg L, Hallström BM, *et al*. Proteomics tissue-based map of the human proteome. *Science* 2015;347:1260419.
- Riener M-O, Thiesler T, Hellerbrand C, *et al*. Loss of anterior gradient-2 expression is an independent prognostic factor in colorectal carcinomas. *Eur J Cancer* 2014;50:1722–30.
- Tian S, Hu J, Tao K, *et al*. Secreted AGR2 promotes invasion of colorectal cancer cells via Wnt11-mediated non-canonical Wnt signaling. *Exp Cell Res* 2018;364:198–207.
- Fessart D, Mahouche I, Brouste V. Anterior gradient-2 (AGR2) is overexpressed in colon cancer and is a potential biomarker of microsatellite instability (MSI) tumors. *bioRxiv* 2022 <https://doi.org/10.1101/2021.09.07.459258>