



**HAL**  
open science

## **Robot-assisted laparoscopy repair of uterine isthmocele: A two-center observational study**

Claire Cardaillac, Caroline Salmon, Edouard Vaucel, Pauline Gueudry,  
Vincent Lavoue, Krystel Nyangoh Timoh, Thibault Thubert

### ► **To cite this version:**

Claire Cardaillac, Caroline Salmon, Edouard Vaucel, Pauline Gueudry, Vincent Lavoue, et al.. Robot-assisted laparoscopy repair of uterine isthmocele: A two-center observational study. *International Journal of Gynecology and Obstetrics*, 2023, 160 (1), pp.244 - 248. 10.1002/ijgo.14319 . hal-03903164

**HAL Id: hal-03903164**

**<https://univ-rennes.hal.science/hal-03903164>**

Submitted on 16 Dec 2022

**HAL** is a multi-disciplinary open access archive for the deposit and dissemination of scientific research documents, whether they are published or not. The documents may come from teaching and research institutions in France or abroad, or from public or private research centers.

L'archive ouverte pluridisciplinaire **HAL**, est destinée au dépôt et à la diffusion de documents scientifiques de niveau recherche, publiés ou non, émanant des établissements d'enseignement et de recherche français ou étrangers, des laboratoires publics ou privés.

# ROBOT-ASSISTED LAPAROSCOPY REPAIR OF UTERINE ISTHMOCELE: A TWO-CENTER OBSERVATIONAL STUDY.

Claire Cardaillac\*, MD, MSc <sup>1</sup>, Caroline Salmon\*, MD <sup>2</sup>, Edouard Vaucel, MD <sup>1</sup>,  
Pauline Gueudry, MD <sup>1</sup>, Vincent Lavoue, MD, PhD <sup>3</sup>, Krystel Nyangoh Timoh, MD,  
PhD <sup>3</sup> and Thibault Thubert, MD, PhD <sup>2</sup>

\*co-first author

<sup>1</sup> Department of Obstetrics and Gynecology and Reproductive Medicine, Nantes  
University Hospital, 44000 Nantes, France

<sup>2</sup> Department of Obstetrics and Gynecology, Cholet Hospital, 49300 Cholet, France

<sup>3</sup> Department of Obstetrics and Gynecology, Rennes University Hospital, 35000  
Rennes, France

Email address: [cardaillac.c@gmail.com](mailto:cardaillac.c@gmail.com), [caroline.salmon@chu-rennes.fr](mailto:caroline.salmon@chu-rennes.fr),  
[dr.evaucel@gmail.com](mailto:dr.evaucel@gmail.com), [\\_pauline.gueudry@gmail.com](mailto:_pauline.gueudry@gmail.com), [vincent.lavoue@chu-rennes.fr](mailto:vincent.lavoue@chu-rennes.fr),  
[krystel.nyangoh@chu-rennes.fr](mailto:krystel.nyangoh@chu-rennes.fr), [thibault.thubert@chu-nantes.fr](mailto:thibault.thubert@chu-nantes.fr).

\* Corresponding author: Thibault THUBERT, MD, PhD  
Department of Obstetrics and Gynecology  
Centre Hospitalier Universitaire  
44 000, NANTES, France.  
Tel.: +33 240083333  
E-mail address: [thibault.thubert@chu-nantes.fr](mailto:thibault.thubert@chu-nantes.fr)

This article has been accepted for publication and undergone full peer review but has not been through the copyediting, typesetting, pagination and proofreading process which may lead to differences between this version and the [Version of Record](#). Please cite this article as doi: [10.1002/ijgo.14319](https://doi.org/10.1002/ijgo.14319)

**Keywords:** cesarean scar; laparoscopic niche resection; surgical management; uterine niches; uterine scar defect.

**Synopsis:** Robot-assisted repair of an isthmocele, while not standardized, is a viable minimally invasive procedure for women with an isthmocele and symptoms and improves subfertility.

**Article type:** clinical study.

**Word count:** main text 1773 words.

**Abstract:**

**Objective:** To analyze outcomes and postoperative complications in patients undergoing robot-assisted isthmocele repair.

**Method:** This retrospective cohort study included 33 patients who had robot-assisted laparoscopic surgical management of an isthmocele between September 2013 and August 2020 in two French university hospitals. All charts were reviewed to identify patient characteristics, pre- and postoperative anatomical findings, complications, and postoperative fertility and symptoms. Patients who had undergone this procedure were asked to complete a telephone questionnaire about their treatment satisfaction and symptoms.

**Results:** The isthmocele was discovered most often due to subfertility (57.6%), but also due to ectopic pregnancy (18.2%), pelvic pain (15.2%), and postmenstrual bleeding (9.1%). Myometrial thickness improved significantly (1.55mm before surgery to 4.26mm afterwards (mean difference 2.71(95CI 1.91 to 3.51), P=.0005). Among the 20 patients who still desired a child after surgery, 15 became pregnant and 14 had full-term live births. Among the 9 patients who had surgery for disabling symptoms, 5 had no persistent symptoms, 3 reported global improvement, and 1 had the same gynecologic discomfort. Seventeen patients agreed to complete the questionnaires (51.5%); all stated that they would choose again to have this surgery.

**Conclusion:**

Robot-assisted repair of an isthmocele is a viable minimally invasive procedure .

## **Introduction:**

Uterine isthmocele is a pouchlike defect at the site of a cesarean scar. Due to the continuous increase in cesarean rates over the years and advances in medical imaging, its incidence is growing and is now estimated to range from 19.4% to 88% [1–4]. It may be asymptomatic but can also cause disabling symptoms. In particular, abnormal bleeding, especially post-menstrual spotting, is estimated in 28.9%–82% of women with this defect [3,5]. Pelvic pain, dyspareunia, and dysmenorrhea are also frequently described as secondary to it [3,5]. From an obstetric perspective, dehiscence of this scar can also lead to ectopic pregnancies [3,6,7] and especially infertility [5,8,9]. Several studies have shown a beneficial effect of surgical management of the isthmocele in reducing patients' symptoms and improving their obstetric prognosis. There are currently several different methods of surgical management: hysteroscopy [8], a vaginal approach [10–13], a standard [11,14–16] or robot-assisted [17,18] laparoscopy, or a combination of approaches [19]. The literature does not yet contain enough data to favor one approach over any other [20,21]. The robotic-assisted approach has been described quite sparsely, and only in case reports [17–19]. The objective of this study was to evaluate the anatomical results, surgical complications, operative time, obstetric prognosis, and postoperative symptoms of patients who had robot-assisted laparoscopy for an isthmocele. We also collected their satisfaction with this minimally invasive approach.

## **Materials and methods:**

A retrospective two-center observational study took place in the University Hospital Centers of Nantes and Rennes, in France. Patients were identified using the French national administrative database (PMSI), and by a search by keywords (“isthmocele”,

“laparoscopy”, “robot”) on the operating reports and in patient’s computer and paper files. Women who underwent robot-assisted laparoscopic surgical management of an isthmocele between September 2013 and August 2020 were eligible for enrolment in the study. The exclusion criteria were as follows: patient age less than 18 years, women deprived of liberty (under trusteeship, guardianship) and a poor understanding of the French language. All charts were reviewed retrospectively to identify patients’ demographic and clinical characteristics, pre- and postoperative anatomical findings, surgical procedure, complications, and postoperative fertility. An information letter was sent by post to all patients who had undergone this procedure. They were asked if they agreed to complete a telephone questionnaire. In case of acceptance, they were contacted by phone in December 2020. They were given verbal information about the purpose of the call. Then, she were asked to orally complete questionnaires on treatment satisfaction, quality of life (EQ5D-5L), and symptoms. Patients satisfaction was evaluated with two questions: “Would you do the same operation again ?” (YES/NO) and “Would you recommend this procedure to someone close ?” (YES/NO). The symptoms were assessed by the following questions: “Do you have any persistent discomfort or embarrassment since your surgery (YES/NO) ? If yes, which one ? (OPEN QUESTION), at what intensity (LOW/MODERATE/SEVERE) ?”. The study protocol did not require an Institutional review board. However, the protocol was approved by the Groupe Nantais d’Éthique dans le Domaine de la Santé (GNEDS).

Isthmoceles were diagnosed by vaginal ultrasound or hysteroscopy in women with pelvic symptoms or during a workup for secondary infertility. After a hysteroscopic diagnosis, physicians could choose to have the patient undergo an ultrasound or MRI to assess the isthmocele's characteristics. A surgical procedure was proposed for a

Accepted Article

symptomatic isthmocele: menometrorrhagia, chronic pelvic pain, dysmenorrhea, ectopic pregnancy, subfertility (period of more than one year with unwanted non-conception). When a large isthmocele ( $\geq 20$  mm) or a residual myometrium  $\leq 3$  mm was fortuitously discovered on pelvic imagery in women who desired pregnancy in the mid- or long term, we discussed a surgical procedure with her. Robot-assisted laparoscopy was performed by senior gynecologic surgeons from the university hospitals of Nantes and Rennes. The procedures were performed under general anesthesia in the gynecological and Trendelenburg positions. The bladder was emptied by an indwelling urinary catheter. Robot-assisted laparoscopy required the placement of two 8-mm trocars in addition to the optical trocar, and a 10-mm trocar for the assistant. The instruments used were grasping forceps, bipolar forceps, and monopolar scissors. The vesicouterine peritoneum was carefully opened and dissected until the niche was visible and an area of healthy tissue obtained around the dehiscence. All of the isthmocele's fibrotic tissue was resected. The wound was sutured as the operator chose with Monocryl™ 0 (Poliglecaprone 25 suture, undyed monofilament, ETHICON Somerville, NJ08876 USA) or Vicryl™ 1 (Polyglactin 910 suture, undyed braided, ETHICON Somerville, NJ08876 USA) X stitches. Cervical canal patency was systematically checked at the end of the procedure by using a hystrometer or a Hegar candle, and the urinary catheter was removed. Patients were monitored in an inpatient or outpatient care unit, according to physician preference. An ultrasound or MRI was performed at 3 months (Nantes Hospital) or 6 months (Rennes Hospital) after the surgery.

All data were anonymously reported in an Excel file and analyzed using Prism software version 9.4.0. All tests were two sided and a *P*-value  $< .05$  was considered statistically

Accepted Article

significant. The difference between patients' characteristics at baseline and follow-up were analyzed with the Wilcoxon signed rank test for related samples because the data are nonparametric. Fisher's exact test was used to compare categorical (qualitative) data.

## **Results:**

The study included 33 women (24 at Nantes and 9 at Rennes University Hospitals) with a mean age at surgery of  $32.6 \pm 3.2$  years. The baseline characteristics and symptoms that led to the diagnosis of isthmocele are presented in *Table 1*: subfertility for 19 women (57.6%), followed by ectopic pregnancy for 6 patients (18.2%), pelvic pain for 5 patients (15.2%), and postmenstrual bleeding for 3 patients (9.1%).

### *Surgical outcomes*

*Table 2* reports the surgical outcomes. The mean time from the last cesarean to surgery was approximately  $4.2 \pm 1.2$  years, and the mean operative time  $98 \pm 36$  minutes for robot-assisted laparoscopy. One conversion to laparotomy occurred (3%) because of vessel injury during the isthmocele resection. During the procedure, the other 32 patients (97%) had no complications. Postoperatively, 2 patients (6%) visited the emergency room visits for modification of their analgesic treatment. One procedure (3%) failed, with persistent symptoms requiring a second surgical step by laparotomy.

### *Reduction in reported symptoms*

Of the 9 patients (27.3%) who had surgery for disabling symptoms, none persisted for 5 (55.5%), while 3 (33.3%) reported global improvement, and 1 (11.1%) no change in the level of gynecologic discomfort.



### *Obstetric outcomes*

Obstetric data were unavailable for N=6 (18.2%) patients. All the women who had isthmocele surgery had sought to become pregnant before the surgery, and 16/27 (59.3%) were treated by a medically assisted reproduction team. Thereafter 7 patients reported changing their mind about pregnancy, either temporarily (6/27, 22.2%) or permanently (1/27, 3.7%). Among the 20 who still desired a child, 15 (75%) became pregnant, and 14 of them (93.3%) had a full-term live birth. Obstetric outcomes are reported in Table 3.

### *Anatomical characteristics*

MRI measurements before surgery assessed the residual myometrium for 27 patients (81.8%); the mean myometrial thickness was 1.5 mm. This measurement was repeated after robot-assisted treatment for 16 patients (48.5%) and their mean myometrial thickness had improved significantly, from 1.55 mm before surgery to 4.26 mm afterwards (mean difference 2.71(95CI 1.91 to 3.51),  $P=.0005$ ).

### *Quality of life and women's satisfaction*

Seventeen patients agreed to complete the questionnaires (51.5%), on average 29 months after the surgery. All of them reported that they would choose again to have this surgery, and 16 (94.1%) that they would recommend it to someone close in the same medical situation. All retained full mobility and autonomy. The surgery had no repercussions on daily activity or mood for 15 of them (88%). Moderate discomfort described as dysmenorrhea was reported by 7 patients (41,2%). Moreover, 3 patients (17.6%) reported esthetic embarrassment due to their surgical scars.

## Discussion:

To our knowledge, this is the first study to assess management of an isthmocele by a robot-assisted approach; its mean follow-up exceeded 24 months. We found encouraging results: gynecological symptoms decreased, fertility rose, and the width of the residual myometrial wall increased. Three case reports of isthmocele cured by a robot-assisted approach described the postoperative outcomes [17–19]. Yalcinkava et al. [17] treated 2 patients with a symptomatic isthmocele (spotting, pelvic discomfort, and secondary infertility). Repair of the defect resulted in improvement of symptoms as well as conception at 3 and 11 months postoperatively. In 2015, Mahmoud et al. [18] published a step-by-step video explaining the surgical procedure for robotic repair in a 40-year-old woman with a history of ectopic pregnancy on a cesarean scar. Recently, Guan et al. [19] described the management of an isthmocele in 2 patients with dysmenorrhea and menorrhagia by hysteroscopy-assisted robotic resection. The surgeries took 90 and 85 min respectively to obtain a residual myometrium of 2.3 and 2.8 mm; the second patient later became pregnant. In our series, 9 patients (27.3%) had abnormal bleeding, chronic pelvic pain, or dysmenorrhea before surgery. Improvement of these symptoms was reported in 8 patients (88.9%). Our results are particularly interesting for fertility: 75% of the patients (15/20) became pregnant, and 93.3% were carried to term. Most authors report lower pregnancy rates by laparoscopy, ranging from 23% to 44% [11,16,22,23]. The exception was Liu et al. [24] who found a rate of 90%. The time to conception after surgery among our patients was 10.2 +/- 6.3 months, concordant with previous publications.

Our study has several limitations. First, it is a retrospective study, with a fairly small number of participants and several missing data items. In addition, the 2 participating centers do not perform precisely the same pre-or postoperative investigations. Nonetheless, it is the largest cohort reported for the robot-assisted approach. Because relatively few patients reported gynecologic symptoms, we cannot reach a valid conclusion about the real improvement of these symptoms. The 2 hospitals perform postoperative evaluations at different points in follow-up (3 and 6 months). Some patients had this surgery more than 7 years ago and others less than a year ago. We can assume that there is a recall bias and an inequality with regard to their feelings and their quality of life postoperatively. Moreover, only half of the population agreed to participate at the telephone questionnaire.

In conclusion, there is currently no consensus on the best surgical management for isthmocele. Multiple techniques have been described for its repair, and the decision depends on the physician in consultation with the patient. The decision to treat depends on the symptoms, the presence of secondary infertility, and the desire for pregnancy. Our study shows that isthmocele repair by robot-assisted laparoscopy is an effective potential treatment, although further studies of this technique are still needed.

**Authors contributions:**

CS, TT, CC, EV, PG, VL and KN have participated to the study conception and design, the data analysis and interpretation. The patient recruitment was realized by EV, PG, VL, KN and TT. The data were collected by CS. The statistical analysis was performed

by CC, CS and TT. The manuscript was drafted by CC and TT and reviewed by all authors.

### **Conflicts of interest statement**

Declarations of interest: none.

## References:

- [1] Bij de Vaate AJM, van der Voet LF, Naji O, Witmer M, Veersema S, Brölmann H a. M, et al. Prevalence, potential risk factors for development and symptoms related to the presence of uterine niches following Cesarean section: systematic review. *Ultrasound Obstet Gynecol Off J Int Soc Ultrasound Obstet Gynecol* 2014;43:372–82.
- [2] Osser OV, Jokubkiene L, Valentin L. High prevalence of defects in Cesarean section scars at transvaginal ultrasound examination. *Ultrasound Obstet Gynecol Off J Int Soc Ultrasound Obstet Gynecol* 2009;34:90–7.
- [3] Tower AM, Frishman GN. Cesarean scar defects: an underrecognized cause of abnormal uterine bleeding and other gynecologic complications. *J Minim Invasive Gynecol* 2013;20:562–72. [4] Tulandi T, Cohen A. Emerging Manifestations of Cesarean Scar Defect in Reproductive-aged Women. *J Minim Invasive Gynecol* 2016;23:893–902.
- [5] Kremer TG, Ghiorzi IB, Dibi RP. Isthmocele: an overview of diagnosis and treatment. *Rev Assoc Medica Bras* 1992 2019;65:714–21.
- [6] Gonzalez N, Tulandi T. Cesarean Scar Pregnancy: A Systematic Review. *J Minim Invasive Gynecol* 2017;24:731–8.
- [7] Maheux-Lacroix S, Li F, Bujold E, Nesbitt-Hawes E, Deans R, Abbott J. Cesarean Scar Pregnancies: A Systematic Review of Treatment Options. *J Minim Invasive Gynecol* 2017;24:915–25.
- [8] Gubbini G, Casadio P, Marra E. Resectoscopic correction of the “isthmocele” in women with postmenstrual abnormal uterine bleeding and secondary infertility. *J Minim Invasive Gynecol* 2008;15:172–5. [9] Gubbini G, Centini G, Nascetti

D, Marra E, Moncini I, Bruni L, et al. Surgical hysteroscopic treatment of cesarean-induced isthmocele in restoring fertility: prospective study. *J Minim Invasive Gynecol* 2011;18:234–7.

- [10] Chang Y, Tsai EM, Long CY, Lee CL, Kay N. Resectoscopic treatment combined with sonohysterographic evaluation of women with postmenstrual bleeding as a result of previous cesarean delivery scar defects. *Am J Obstet Gynecol* 2009;200:370.e1-4. [11] Zhang Y. A Comparative Study of Transvaginal Repair and Laparoscopic Repair in the Management of Patients With Previous Cesarean Scar Defect. *J Minim Invasive Gynecol* 2016;23:535–41. [12] Zhang D, Liang S, Zhu L. Comparison of transvaginal repair versus laparoscopic repair of lower-segment cesarean scar defects. *Int J Gynaecol Obstet Off Organ Int Fed Gynaecol Obstet* 2019;145:199–204. [13] Wang C-J, Huang H-J, Chao A, Lin Y-P, Pan Y-J, Horng S-G. Challenges in the transvaginal management of abnormal uterine bleeding secondary to cesarean section scar defect. *Eur J Obstet Gynecol Reprod Biol* 2011;154:218–22.
- [14] Donnez O, Donnez J, Orellana R, Dolmans M-M. Gynecological and obstetrical outcomes after laparoscopic repair of a cesarean scar defect in a series of 38 women. *Fertil Steril* 2017;107:289-296.e2. .
- [15] Donnez O, Jadoul P, Squifflet J, Donnez J. Laparoscopic repair of wide and deep uterine scar dehiscence after cesarean section. *Fertil Steril* 2008;89:974–80. [16] Vervoort A, Vissers J, Hehenkamp W, Brölmann H, Huirne J. The effect of laparoscopic resection of large niches in the uterine caesarean scar on symptoms, ultrasound findings and quality of life: a prospective cohort study. *BJOG Int J Obstet Gynaecol* 2018;125:317–25. [17] Yalcinkaya TM, Akar ME, Kammire LD, Johnston-MacAnanny EB, Mertz HL. Robotic-assisted laparoscopic repair of

symptomatic cesarean scar defect: a report of two cases. *J Reprod Med* 2011;56:265–70.

- [18] Mahmoud MS, Nezhat FR. Robotic-assisted Laparoscopic Repair of a Cesarean Section Scar Defect. *J Minim Invasive Gynecol* 2015;22:1135–6. [19] Guan Z, Liu J, Bardawil E, Guan X. Surgical Management of Cesarean Scar Defect: The Hysteroscopic-Assisted Robotic Single-Site Technique. *J Minim Invasive Gynecol* 2020;27:24–5. [20] Mashiach R, Burke YZ. Optimal Isthmocele Management: Hysteroscopic, Laparoscopic, or Combination. *J Minim Invasive Gynecol* 2020.
- [21] Setubal A, Alves J, Osório F, Guerra A, Fernandes R, Albornoz J, et al. Treatment for Uterine Isthmocele, A Pouchlike Defect at the Site of a Cesarean Section Scar. *J Minim Invasive Gynecol* 2018;25:38–46. [22] Marotta M-L, Donnez J, Squifflet J, Jadoul P, Darii N, Donnez O. Laparoscopic repair of post-cesarean section uterine scar defects diagnosed in nonpregnant women. *J Minim Invasive Gynecol* 2013;20:386–91. [23] Delaine M, Lecointre L, Akladios CY, Hummel M, Host A, Garbin O. [Laparoscopic treatment of cesarean scar pouch - A case series study of 9 patients]. *Gynecol Obstet Fertil Senol* 2017;45:262–8.
- [24] Liu S-J, Lv W, Li W. Laparoscopic repair with hysteroscopy of cesarean scar diverticulum. *J Obstet Gynaecol Res* 2016;42:1719–23.

**Table 1:** Baseline characteristics

|  | N = 33     |
|--|------------|
| <b>AGE (YEARS), MEAN (SD)</b>                                    | 32.6 (3.2) |
| <b>BODY-MASS INDEX, MEAN (SD)</b>                                | 25.9 (4.6) |
| <b>OBESITY (BMI &gt; 30), NO./TOTAL (%)</b>                      | 7 (21.2)   |
| <b>TOBACCO USE, NO./TOTAL (%)</b>                                | 9 (27.3)   |
| <b>PRIMIPAROUS, NO./TOTAL (%)</b>                                | 23 (69.7)  |
| <b>NUMBER OF CESAREAN SECTIONS,</b>                              |            |
| 1, No./Total (%)   | 25 (75.8)  |
| 2, No./Total (%)   | 7 (21.2)   |
| 3, No./Total (%)   | 1 (3)      |
| <b>TIME BETWEEN LAST CESAREAN AND SURGERY (YEARS), MEAN (SD)</b> | 4.2 (1.2)  |
| <b>SYMPTOMS <sup>A</sup></b>                                     | 9 (27.3)   |
| Postmenstrual bleeding, No./Total (%)                            | 3 (9.1)    |
| Pelvic pain, No./Total (%)                                       | 5 (15.2)   |
| <b>ECTOPIC PREGNANCY, NO./TOTAL (%)</b>                          | 6 (18.2)   |
| <b>SUBFERTILITY <sup>B</sup>, NO./TOTAL (%)</b>                  | 19 (57.6)  |
| Isthmocele alone, No./infertility (%)                            | 10 (52.6)  |
| Polycystic ovarian syndrome, No./infertility (%)                 | 6 (31.6)   |
| Premature ovarian failure, No./infertility (%)                   | 2 (10.5)   |
| Male infertility, No./infertility (%)                            | 3 (15.8)   |
| <b>ACCIDENTAL DISCOVERY, NO./TOTAL (%)</b>                       | 2 (6.1)    |

<sup>A</sup> Symptoms reported by the patient as a reason for the surgery.

<sup>B</sup> Subfertility is define by a period of > 1 year with unwanted non-conception.



**Table 2:** Surgical outcomes:

|  |           |
|--|-----------|
| PARAMETERS   | N=33      |
| <b>MEDIAN OPERATING TIME (MINUTES), MEAN (SD)</b>    | 98 (36)   |
| <b>INTRAOPERATIVE COMPLICATIONS, NO./TOTAL (%)</b>   | 1 (3)     |
| Conversion to laparotomy due to vessel injury        | 1 (3)     |
| <b>POSTOPERATIVE COMPLICATIONS, NO./TOTAL (%)</b>    | 2 (6)     |
| Pelvic pain  | 2 (6)     |
| <b>POSTOPERATIVE HOSPITAL STAY (DAYS), MEAN (SD)</b> | 1.7 (1)   |
| Ambulatory surgery                                   | 8 (24.2%) |
| ≥ 3 days   | 4 (12.1%) |

**Table 3:** Obstetric outcomes:

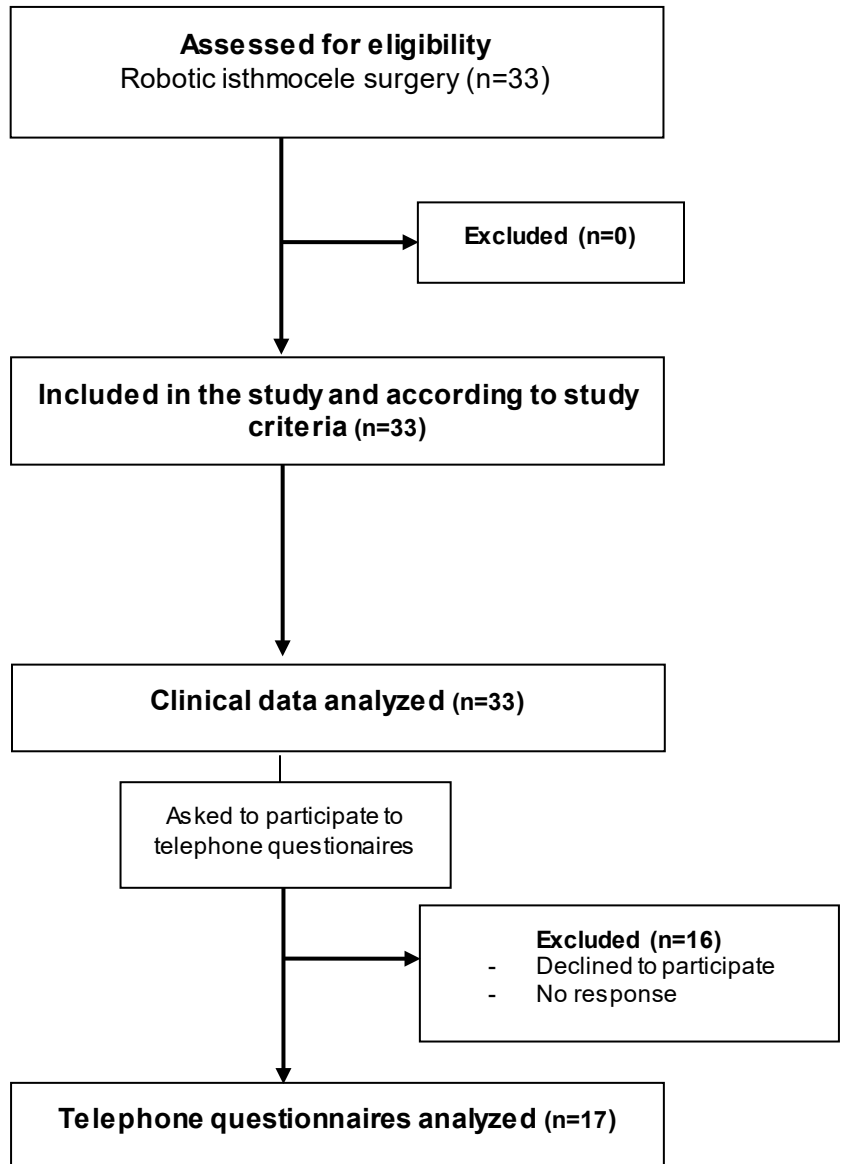
|   | N=27 <sup>A</sup> |
|---|-------------------|
| <b>PREGNANCY PROJECT TERMINATION, NO./TOTAL (%)</b>                       | 7/27 (25,9)       |
| Temporarily, No./total (%)  | 6/27 (22.2)       |
| Definitely, No./total (%)   | 1/27 (3.7)        |
| <b>PREGNANCY, NO. WOMEN/WOMEN DESIRING PREGNANCY (%)</b>                  | 15/20 (75)        |
| Women with spontaneous pregnancy, No./women desiring pregnancy (%)        | 9/20 (45)         |
| Women with medically assisted pregnancy, No./women desiring pregnancy (%) | 6/20 (30)         |
| Women with miscarriage, No./women desiring pregnancy (%)                  | 1/20 (5)          |
| Women with full-term live pregnancy, No./women desiring pregnancy (%)     | 14/20 (70)        |
| <b>TIME BETWEEN SURGERY AND CESAREAN MONTHS (SD)</b>                      | 19.2 (6.3)        |

<sup>A</sup> Obstetric data were unavailable for N=6 patients.

Identification

Inclusion

Analysis



**Figure 1** : Study enrollment flow-chart.