



## Comment on "Augmentation mammoplasty by superolateral thoracic flap: a case report"

Yanis Berkane, Nicolas Bertheuil

### ► To cite this version:

Yanis Berkane, Nicolas Bertheuil. Comment on "Augmentation mammoplasty by superolateral thoracic flap: a case report". Journal of Medical Case Reports, 2022, 16 (1), 10.1186/s13256-022-03602-5 . hal-03837048

**HAL Id: hal-03837048**

**<https://hal.science/hal-03837048>**

Submitted on 20 Jan 2023

**HAL** is a multi-disciplinary open access archive for the deposit and dissemination of scientific research documents, whether they are published or not. The documents may come from teaching and research institutions in France or abroad, or from public or private research centers.

L'archive ouverte pluridisciplinaire **HAL**, est destinée au dépôt et à la diffusion de documents scientifiques de niveau recherche, publiés ou non, émanant des établissements d'enseignement et de recherche français ou étrangers, des laboratoires publics ou privés.



Distributed under a Creative Commons Attribution 4.0 International License

LETTER TO THE EDITOR

Open Access



# Comment on “Augmentation mammoplasty by superolateral thoracic flap: a case report”

Yanis Berkane<sup>1,2\*</sup>  and Nicolas Bertheuil<sup>1,3,4</sup>

Dear Sir,

We read with great interest the report “Augmentation mammoplasty by superolateral thoracic flap: a case report” by Lupon *et al.* [1]. We congratulate the authors for this case report and the surgical result. We are familiar with the difficulty of performing breast surgery in a post-bariatric situation, and the complexity of the volume/weight ratio in view of the poor skin tone that leads to unpredictable results.

Lupon *et al.* clearly described their superolateral thoracic flap technique, which ensures viability by conserving the external mammary vascular network and by adequate burial of the flap, allowing its harmonious integration with the breast contour. They describe the basic postoperative results: discharge on day 1, no postoperative complications, and patient satisfaction with the cosmetic result. We would like to discuss some points that the authors raise, based on our experience and previous research.

First, we agree that alternative procedures to implants should be considered for patients who have undergone massive weight loss (MWL) because the skin laxity and lack of dermal thickness leads to rapid ptosis of the reconstructed breast and the risk of secondary implant malposition [2]. However, in selected patients who have

retained good-quality skin, the use of implants can be very effective, with good cosmetic results for several years [3]. Augmentation with implants remains the most predictable and suitable reconstruction of breasts following MWL, and numerous breast self-augmentation techniques with autologous tissue have been described for this population [4–7].

We described the use of lateral thoracic propeller perforator flaps buried under the mammary gland, which allows the restoration of good breast projection [6]. We proved that this technique is reproducible in nine patients, with the patients scoring the cosmetic results as  $3.8 \pm 0.8$  out of 5. This surgery was associated with bilateral brachioplasty, as part of a total reconstruction of the upper body (an upper body lift). We believe that this approach allows a more harmonious overall silhouette. With the technique of Lupon *et al.*, is possible to avoid excess skin and fat, such as that found in the axillary line (Fig. 7). However, the patient must accept the resulting scarring and the postoperative scar care required to improve it.

Moreover, Lupon *et al.* deplore the fact that their technique is difficult to associate with an inverted T-shaped scar. However, this patient population most often presents with significant breast ptosis that necessitates an inverted T scar. As we showed previously [6], self-augmentation with a classic inverted T scar can be performed if the perforating vessels of the lateral flap are skeletonized. The flap volume can be managed easily with an implant. The disadvantage is that this greatly increases the operating time, unlike the authors’ technique.

Finally, we would like to emphasize that the technique described by Hurwitz *et al.* [8], whose principles are rather similar to those of Lupon *et al.*, benefits from

This comment refers to the article available online at <https://doi.org/10.1186/s13256-021-03122-8>.

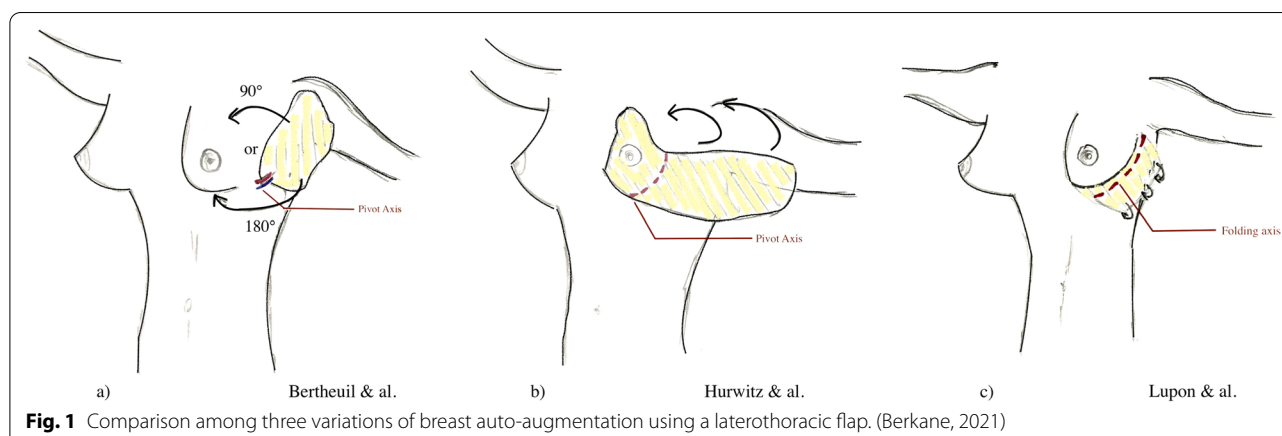
\*Correspondence: [yanis.berkane@chu-rennes.fr](mailto:yanis.berkane@chu-rennes.fr)

<sup>1</sup> Department of Plastic, Reconstructive and Aesthetic Surgery, Rennes University Hospital Center, Hospital Sud, University of Rennes 1, Rennes, France

Full list of author information is available at the end of the article



© The Author(s) 2022. **Open Access** This article is licensed under a Creative Commons Attribution 4.0 International License, which permits use, sharing, adaptation, distribution and reproduction in any medium or format, as long as you give appropriate credit to the original author(s) and the source, provide a link to the Creative Commons licence, and indicate if changes were made. The images or other third party material in this article are included in the article's Creative Commons licence, unless indicated otherwise in a credit line to the material. If material is not included in the article's Creative Commons licence and your intended use is not permitted by statutory regulation or exceeds the permitted use, you will need to obtain permission directly from the copyright holder. To view a copy of this licence, visit <http://creativecommons.org/licenses/by/4.0/>. The Creative Commons Public Domain Dedication waiver (<http://creativecommons.org/publicdomain/zero/1.0/>) applies to the data made available in this article, unless otherwise stated in a credit line to the data.



hindsight due to the large number of cases described, and the expertise of this distinguished surgeon with innovative contouring surgery in MWL patients. His technique, cited by Lupon *et al.*, ensures satisfactory results in terms of the projection, and is compatible with an inverted T-scar to correct the major ptosis frequently found in MWL patients. Again, integration with a full upper body lift seems preferable. Figure 1 summarizes the differences among the three variants of this technique.

In conclusion, we agree with Lupon *et al.* that autologous breast augmentation techniques should be promoted, and we find the discovery of new techniques and modifications of existing techniques interesting. We thank Lupon *et al.* for their contribution to post-bariatric breast reconstruction, and for this interesting case report. We believe that plastic surgeons must keep innovating to improve the outcomes for MWL patients for whom surgery is not just about comfort.

#### Acknowledgements

Not applicable.

#### Author contributions

YB: conception and drafting of the manuscript. Drawing the figure. NB: critically revising the manuscript. Both authors read and approved the final manuscript.

#### Funding

No specific funding was received in the context of this communication.

#### Availability of data and materials

All the data provided in this letter is available and can be provided to the editorial board if needed.

#### Declarations

##### Ethics approval and consent to participate

All clinical investigations adhered to all relevant tenets of the Declaration of Helsinki and were approved by our Committee for the Protection of Persons (CPP).

##### Consent for publication

Not applicable. No patient is involved in the content of this letter to editor.

#### Competing interests

No author has no financial and no competing interest to declare.

#### Author details

<sup>1</sup>Department of Plastic, Reconstructive and Aesthetic Surgery, Rennes University Hospital Center, Hospital Sud, University of Rennes 1, Rennes, France. <sup>2</sup>Vascularized Composite Allotransplantation Laboratory, Massachusetts General Hospital, Harvard Medical School, Boston, MA, USA. <sup>3</sup>INSERM U1236, University of Rennes 1, Rennes, France. <sup>4</sup>SITI Laboratory, Rennes University Hospital, Rennes, France.

Received: 13 January 2022 Accepted: 18 August 2022

Published online: 17 October 2022

#### References

- Lupon E, Chaput B, Meresse T. Augmentation mammoplasty by superolateral thoracic flap: a case report. *J Med Case Reports*. 2021. <https://doi.org/10.1186/s13256-021-03122-8>.
- Coombs DM, Srivastava U, Amar D, Rubin JP, Gusenoff JA. The challenges of augmentation mastopexy in the massive weight loss patient: technical considerations. *Plast Reconstr Surg*. 2017;139(5):1090–9. <https://doi.org/10.1097/PRS.0000000000003294>.
- Hurwitz DJ, Golla D. Breast reshaping after massive weight loss. *Semin Plast Surg*. 2004;18(3):179–87. <https://doi.org/10.1055/s-2004-831905>.
- Lipman K, Graw G, Nguyen D. Lateral intercostal artery perforator (LICAP) flap for breast volume augmentation: applications for oncoplastic and massive weight loss surgery. *JPRAS Open*. 2021;21(29):123–34. <https://doi.org/10.1016/j.jpra.2021.05.005>.
- Szychta P, Anderson WD. Island pedicled superior epigastric artery perforator flaps for bilateral breast augmentation with mastopexy after massive weight loss. *J Plast Reconstr Aesthet Surg*. 2011;64(12):1677–81. <https://doi.org/10.1016/j.bjps.2011.04.025>.
- Isola N, Herlin C, Chaput B, Aillet S, Watier E, Bertheuil N. Upper body lift and breast reshaping with lateral chest wall perforator propeller flap following massive weight loss. *Annales de Chirurgie Plastique Esthétique*. 2020;65:44–53. <https://doi.org/10.1016/j.anplas.2019.07.006>.
- Persichetti P, Tenna S, Brunetti B, Aveta A, Segreto F, Marangi GF. Anterior intercostal artery perforator flap autologous augmentation in bariatric mastopexy. *Plast Reconstr Surg*. 2012;130(4):917–25. <https://doi.org/10.1097/PRS.0b013e318262f38a>.
- Hurwitz DJ, Agha-Mohammadi S. Postbariatric surgery breast reshaping: the spiral flap. *Ann Plast Surg*. 2006;56(5):481–6. <https://doi.org/10.1097/01.sap.0000208935.28789.2d>.

#### Publisher's Note

Springer Nature remains neutral with regard to jurisdictional claims in published maps and institutional affiliations.