



Added value of high-resolution electrical source imaging of ictal activity in children with structural focal epilepsy

Marie Le Roux, Gaëlle Milon-Harnois, Matthieu Delion, Matthieu Labriffe, Josselin Démas, Isabelle Merlet, Patrick van Bogaert

► To cite this version:

Marie Le Roux, Gaëlle Milon-Harnois, Matthieu Delion, Matthieu Labriffe, Josselin Démas, et al.. Added value of high-resolution electrical source imaging of ictal activity in children with structural focal epilepsy. *Clinical Neurophysiology*, 2022, 140, pp.251-253. 10.1016/j.clinph.2022.05.016 . hal-03716319

HAL Id: hal-03716319

<https://hal.science/hal-03716319>

Submitted on 6 Oct 2022

HAL is a multi-disciplinary open access archive for the deposit and dissemination of scientific research documents, whether they are published or not. The documents may come from teaching and research institutions in France or abroad, or from public or private research centers.

L'archive ouverte pluridisciplinaire **HAL**, est destinée au dépôt et à la diffusion de documents scientifiques de niveau recherche, publiés ou non, émanant des établissements d'enseignement et de recherche français ou étrangers, des laboratoires publics ou privés.



Distributed under a Creative Commons Attribution - NonCommercial 4.0 International License

Added value of high-resolution electrical source imaging of ictal activity in children with structural focal epilepsy

Marie Le Roux^{1,2,*}, Gaëlle Milon-Harnois², Matthieu Delion¹, Matthieu Labriffe³, Josselin Démas^{2,4}, Isabelle Merlet⁵, Patrick Van Bogaert^{1,2}

¹ Service de Neurologie et Neurochirurgie Pédiatrique, CHU Angers, France

² Université d'Angers, Laboratoire Angevin de Recherche en Ingénierie des Systèmes (LARIS), Angers, France

³ Service de Radiologie, CHU Angers, France

⁴ Service de rééducation fonctionnelle, CH Laval, France

⁵ Univ Rennes, Inserm, LTSI - UMR 1099, Rennes, France

*** Corresponding author:**

Marie Le Roux

E-mail : marie.le-roux@chu-angers.fr

We read with great interest the paper "Source imaging of seizure onset predicts surgical outcome in pediatric epilepsy" by Ricci et al. (2021). Authors estimated the ictal onset sources from 35 children with refractory focal epilepsy who underwent surgery and concluded that ictal electrical source imaging (ESI) performed on low density scalp EEG can delineate the seizure-onset zone (SOZ) and predict outcome.

In the context of presurgical evaluation of pharmaco-resistant focal epilepsy, there is no unique method that can localize the epileptogenic zone (EZ), and a comprehensive multimodal workup is usually needed. ESI relies on the use of algorithms that compute the location of brain sources on patient's MRI. This approach is now widely used to reconstruct the sources of interictal epileptiform discharges (IEDs) from high-density scalp EEG (HD-EEG). Indeed, it is well-established that increasing the number of electrodes improves the spatial resolution of the technique and is of critical importance for ESI accuracy. Ictal studies from HD-EEG are rarely done considering that most of the nets of electrodes used for HD-EEG acquisitions are not designed to perform EEG recording during long periods of time.

We investigated the feasibility to perform long sessions of EEG recording with a 256-channels device in children with focal structural epilepsy in order to obtain ictal data, and to evaluate the added value of ictal HD-ESI using advanced distributed source localization methods based on Maximum Entropy of the Mean (Pellegrino et al., 2016).

We recorded during up to 24 hours 3 consecutive children aged 5.5 to 9 years admitted for presurgical evaluation of pharmaco-resistant structural epilepsy using 256 electrodes long-term Geodesic Sensor Nets and Net Amp GES 400 series amplifiers (Philips Neuro, Electrical Geodesic, Eugene, OR, U.S.A.). One patient had frontal lobe epilepsy and 2 had posterior cortex epilepsy. MRI showed a focal cortical dysplasia in all cases, including a case of Tuberous Sclerosis Complex (TSC). Artefact-free EEG epochs at ictal onset and IEDs clusters were visually selected. ESI derived from HD-EEG was computed on ictal events (ictal ESI) and on each averaged IEDs clusters (interictal ESI) using patient specific head models. For ictal ESI, the wavelet based

Maximum Entropy of the Mean (wMEM) method was used considering the frequency band calculated from the strongest power change captured around seizure onset. Anatomical sublobar concordances between ictal ESI, interictal ESI and the epileptogenic lesion (EL) were assessed and classified as fully concordant, partly concordant, or discordant (Rikir et al., 2014).

Eight ictal recordings and 7 interictal clusters of IEDs from the 3 patients were analyzed. As the interictal analysis provided more than one ESI localization due to the existence of multiple IEDs clusters in all patients, concordance was considered as present when observed from at least one IEDs cluster. The concordance between ictal ESI and EL was found fully concordant in 57% of seizures and partly in 43%. No discordant solution was found. Ictal and interictal ESI were fully concordant for all seizures for the first patient, and partially concordant for the second one. For the last patient, with TSC, ictal ESI was completely discordant with interictal ESI. The electro-clinical semiology of seizures in this patient suggested a frontal lobe epilepsy, and ictal ESI indicated a frontal source that was concordant with a frontal tuber, whereas interictal ESI indicated extra-frontal sources.

These data suggest that long-term 256-channel scalp EEG monitoring in order to record seizures is feasible in children and that advanced source localization methods of both ictal and interictal activity can provide non-redundant and clinically useful information. Indeed, our data strongly suggest that ictal ESI correctly localized the SOZ, as all ictal sources were found fully or partially concordant with EL, as well as reproducible across seizures for a same patient. The comparison of ictal and interictal ESI shows that localizing the EZ only with interictal ESI has limitations. First, selecting a dominant IEDs cluster can be misleading, even when clinical data are taken into account. Second, it may happen that no IEDs are recordable from the EZ. This was illustrated in our series by the patient suffering from TSC, who had seizures that started from the frontal region but had IEDs in 3 other distinct localizations (Figure 1).

We found only one published ictal ESI study from HD-EEG performed in a pediatric population. This study performed with 256-channel EEG included 6 children among a cohort of 14 patients

(Nemtsas et al., 2017). Data concerning SEEG and surgery outcomes were available for 2 of these 6 cases and showed good concordance between SEEG and ictal ESI.

We chose here to apply the wMEM method, a dynamic approach that is considered as the best approach for ictal oscillatory patterns. This approach recovers the spatial extent of ictal cortical sources and offers the possibility to study the spatiotemporal evolution of generators of ictal patterns in different frequency bands by applying a discrete wavelet transform of the data (Chowdhury et al., 2013).

We estimated the location EZ from the EL, which is a good approximation when the patient has a well-delineated EL. However, the EZ may extend beyond the EL. Therefore, the EZ is estimated from the SOZ delineated by SEEG in a lot of studies. However, SEEG has also limitations because its spatial sampling is always partial. The outcome after surgery is probably the best indicator to evaluate the accuracy of a particular method of localization, as it was done in the study of Ricci et al. (2021). Up to now, only one of our 3 patients was operated on and was seizure-free after 1 year.

In conclusion, ictal ESI based on HD-EEG using appropriate nets and an advanced source localization method is feasible in children and may be of significant help in locating ictal sources in challenging cases. Prospective studies in larger cohorts are required to confirm and extend these findings.

Conflict of interest

None of the authors have potential conflicts of interest to be disclosed.

References

Chowdhury RA, Lina JM, Kobayashi E, Grova C. MEG Source Localization of Spatially Extended Generators of Epileptic Activity: Comparing Entropic and Hierarchical Bayesian Approaches. *PLoS One*. 2013;8:e55969.

Nemtsas P, Birot G, Pittau F, Michel CM, Schaller K, Vulliemoz S, et al. Source localization of ictal epileptic activity based on high-density scalp EEG data. *Epilepsia*. 2017;58:1027-36.

Pellegrino G, Hedrich T, Chowdhury R, Hall JA, Lina JM, Dubeau F, et al. Source localization of the seizure onset zone from ictal EEG/MEG data: wMEM for Ictal Source Imaging. *Hum Brain Mapp*. 2016;37:2528-46.

Ricci L, Tamilia E, Alhilani M, Alter A, Scott Perry M, Madsen JR, et al. Source imaging of seizure onset predicts surgical outcome in pediatric epilepsy. *Clin Neurophysiol*. 2021;132:1622-35.

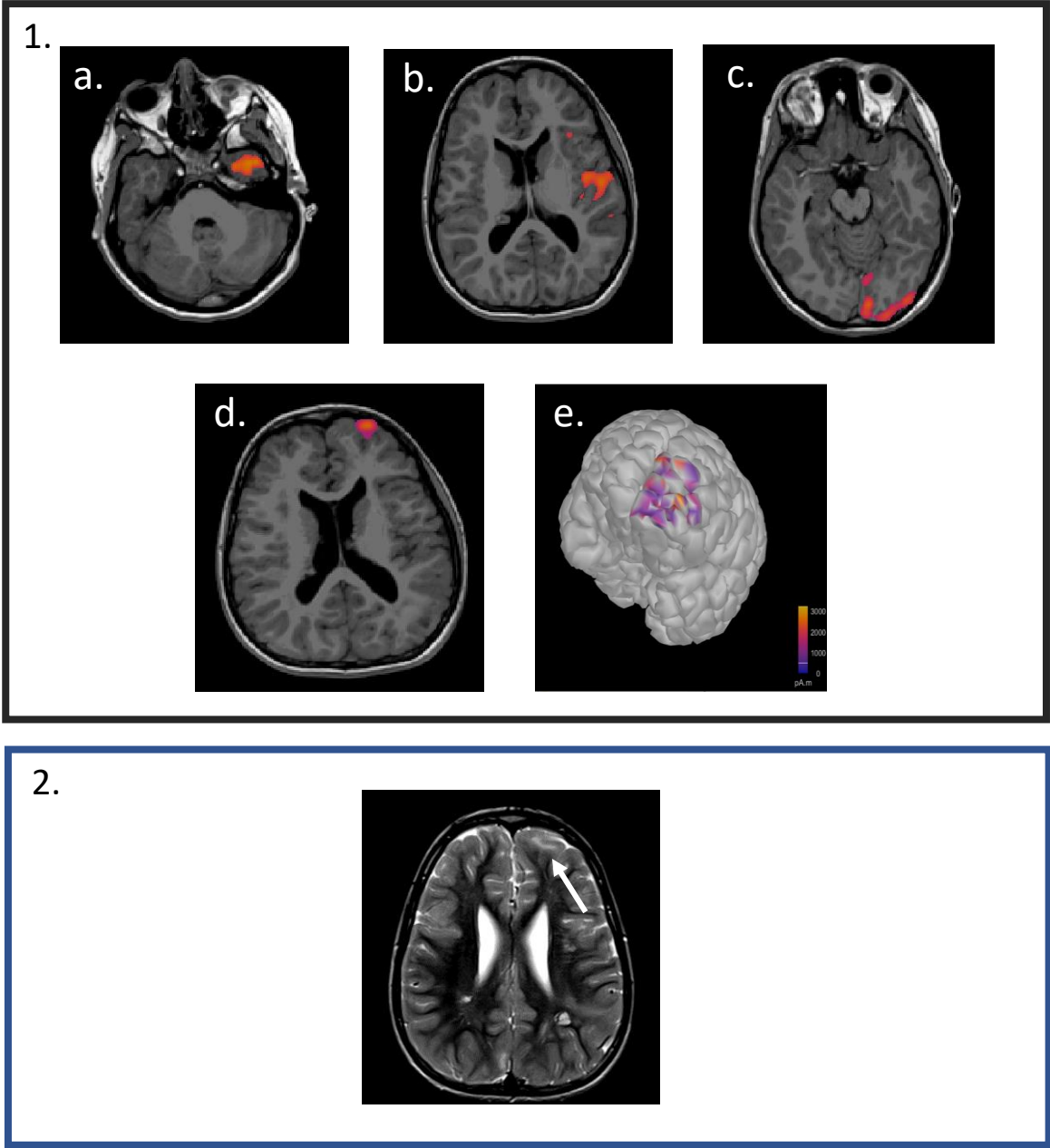
Rikir E, Koessler L, Gavaret M, Bartolomei F, Colnat-Coulbois S, Vignal JP, et al. Electrical source imaging in cortical malformation-related epilepsy: A prospective EEG-SEEG concordance study. *Epilepsia*. 2014;55:918-32.

Figure Legend

Figure 1. Illustration of a case.

Patient 3, a 9-year-old girl, had a Tuberous Sclerosis Complex and suffered from focal epilepsy since the age of 8. Her daily seizures were described as: intense motor restlessness, motor automatisms and vocalizations. She quickly became drug-resistant. Low density EEG showed 3 different IEDs foci: T3, Cz, O1. **1.** Source localization based on 256-channel EEG and obtained after co-registration of the interictal (**a-c**) and the ictal (**d,e**) ESI to the patient's MRI. Ictal ESI was performed using wMEM (applied on the averaged time window around the onset of seizure) and interictal ESI using cMEM on averaged spikes. **2.** T2 MRI showing a left fronto-lateral FCD. For **1.** and **2.**, the right side of the brain corresponds to the left side of the figure.

Abbreviations: IED: interictal epileptiform discharge; ESI: electrical source imaging; wMEM: wavelet maximum entropy of the mean; cMEM: coherent maximum entropy of the mean; FCD: focal cortical dysplasia.



AUTHOR CONCURRENCE FORM CLINICAL NEUROPHYSIOLOGY

Official Organ of the International Federation of Clinical Neurophysiology (IFCN)

<http://www.journals.elsevier.com/clinical-neurophysiology>

Prof. Ulf Ziemann
Editor-in-Chief

Instructions:

1. Each submission to Clinical Neurophysiology needs a filled out Author Concurrence Form. Please fill in the Title of the manuscript below.
2. Collect signatures from all authors.
- 3a. Scan the form and submit it together with the paper. The submission item is Author Agreement.
- 3b. If this is not an option, please fax the form to the Editorial Office: +31-20-485-3881.

Title of the Manuscript:

A signature below certifies compliance with the following statements.

Copyright Transfer: In consideration of the acceptance of the above manuscript for publication, the copyright is transferred to IFCN and administered by Elsevier. All proprietary rights other than copyright (such as patent rights) are reserved to the author(s), as well as the right to use original figures and tables in future works, provided full credit is given to the original publication. If the manuscript is work prepared by employee(s) of the United Kingdom or the United States government as part of their official duties, copyright cannot be fully transferred to the IFCN, and authors must check the appropriate box below.

- This manuscript was written in the course of employment by the United Kingdom and it is subject to Crown copyright.
- This manuscript was written in the course of employment by the United States Government and it is not subject to copyright in the United States.

Authorship Responsibility:

The submission is a truthful, original work without fabrication, fraud or plagiarism, and contains no libellous or unlawful statements.

It has not been published previously except in abstract form.

The manuscript is not under consideration for publication, nor will it be submitted for publication, elsewhere until a final decision has been made by this journal.

The undersigned certify that each author has participated sufficiently in the work to take responsibility for its truthfulness and validity, has read the complete manuscript, and concurs with its content.

Conflict of interest disclosure:

All funding sources supporting this work are acknowledged. The authors will disclose to the editor any pertinent financial interests associated with the manufacture of any drug or product described in this manuscript.

ALL AUTHORS MUST SIGN

Author LE ROUX Marie _____ Date 05/20/22 _____

Author MILON HARNOIS Gaelle _____ Date 05/20/22 _____

Author DEMAS Josselin _____ Date 05/20/22 _____

ACCEPTED MANUSCRIPT/ CLEAN COPY

Author _____DELION Matthieu_____ Date ____05/20/22_____

Author _____LABRIFFE Matthieu_____ _ Date ____05/20/22_____

Author _____MERLET Isabelle_____ Date __05/20/22_____

Author VAN BOGAERT Patrick Date 05/20/22