



Transcatheter Mitral Valve Replacement Guided by Echocardiographic-CT Scan Fusion Early Human Clinical Experience

Augustin Coisne, François Pontana, Thomas Modine, Arnaud Sudre, Patrizio Lancellotti, Rebecca T Hahn, Omar K Khalique, Juan F Granada, David Montaigne, Erwan Donal

► To cite this version:

Augustin Coisne, François Pontana, Thomas Modine, Arnaud Sudre, Patrizio Lancellotti, et al.. Transcatheter Mitral Valve Replacement Guided by Echocardiographic-CT Scan Fusion Early Human Clinical Experience. JACC: Cardiovascular Interventions, 2020, 13 (11), pp.1376-1378. 10.1016/j.jcin.2020.02.011 . hal-02798355

HAL Id: hal-02798355

<https://univ-rennes.hal.science/hal-02798355>

Submitted on 22 Aug 2022

HAL is a multi-disciplinary open access archive for the deposit and dissemination of scientific research documents, whether they are published or not. The documents may come from teaching and research institutions in France or abroad, or from public or private research centers.

L'archive ouverte pluridisciplinaire **HAL**, est destinée au dépôt et à la diffusion de documents scientifiques de niveau recherche, publiés ou non, émanant des établissements d'enseignement et de recherche français ou étrangers, des laboratoires publics ou privés.



Distributed under a Creative Commons Attribution - NonCommercial 4.0 International License

Transcatheter Mitral Valve Replacement Guided by Echocardiographic-CT Scan Fusion: Early Human Clinical Experience

Augustin Coisne, MD, PhD ^{a,b,c,d}; François Pontana, MD, PhD ^{b,c,d,e}; Thomas Modine, MD, PhD ^a; Arnaud Sudre, MD ^a; Patrizio Lancellotti ^{f,g}, MD, PhD; Rebecca T. Hahn, MD ^h; Omar K. Khalique, MD ^h; Juan F. Granada, MD ⁱ; David Montaigne, MD, PhD; ^{a,b,c,d}; Erwan Donal, MD, PhD ^j

Affiliations:

^aCHU Lille, Department of Clinical Physiology and Echocardiography – Heart Valve Center

^bUniv Lille, European Genomic Institute for Diabetes (E.G.I.D), FR 3508, F-59000, Lille, France

^cInserm UMR 1011, F-59000, Lille, France

^dInstitut Pasteur de Lille, F-59000, Lille, France

^eCHU Lille, Department of Cardiovascular Radiology, France

^fUniversity of Liège Hospital, GIGA Cardiovascular Sciences, Departments of Cardiology, Heart Valve Clinic, CHU Sart Tilman, Liège, Belgium

^gGruppo Villa Maria Care and Research, Anthea Hospital, Bari, Italy

^hCardiovascular Research Foundation, Columbia University Medical Center/ NY Presbyterian Hospital, New York, NY

ⁱCardiovascular Research Foundation, Columbia University Medical Center, NY

^jCardiologie, CHU Rennes, INSERM 1099, Université Rennes-1, Rennes, France

Address for Correspondence:

Dr. Augustin Coisne

CHU Lille

Department of Clinical Physiology and Echocardiography

Heart Valve Center

Lille, France

augustin.coisne@chru-lille.fr

Tweet/handle: @AugustinCoisne

Disclosures:

none

Word Count: 400

Both pre-operative planning and peri-procedural guidance of TMVR are based on the independent analysis of Trans-Esophageal Echocardiography (TEE) and *Computed Tomography Scanner (CT) images* (1). Echo-CT fusion (Vivid E95, GE Healthcare, Horten, Norway) (Figure 1, Video 1) is an innovative tool that allows the visualization of both images in the same visual perspective on the echo screen in the operating room through the fusion of the pre-operative CT and the peri-procedural live 3D TEE. Echo-CT fusion thus provides more comprehensive peri-procedural guidance and navigation by improving visualization and communication within the entire Heart Team.

In our experience, this is particularly beneficial in three steps during TMVR procedures: (i) catheter crossing of the annular plane avoiding the sub-valvular apparatus, (ii) position check of the delivery system before and during final deployment and (iii) LVOT impact after deployment of recapturable and retrievable prosthesis (Figures 2&3). Echo-CT Fusion seems therefore a promising live tool in perioperative imaging of TMVR.

REFERENCE

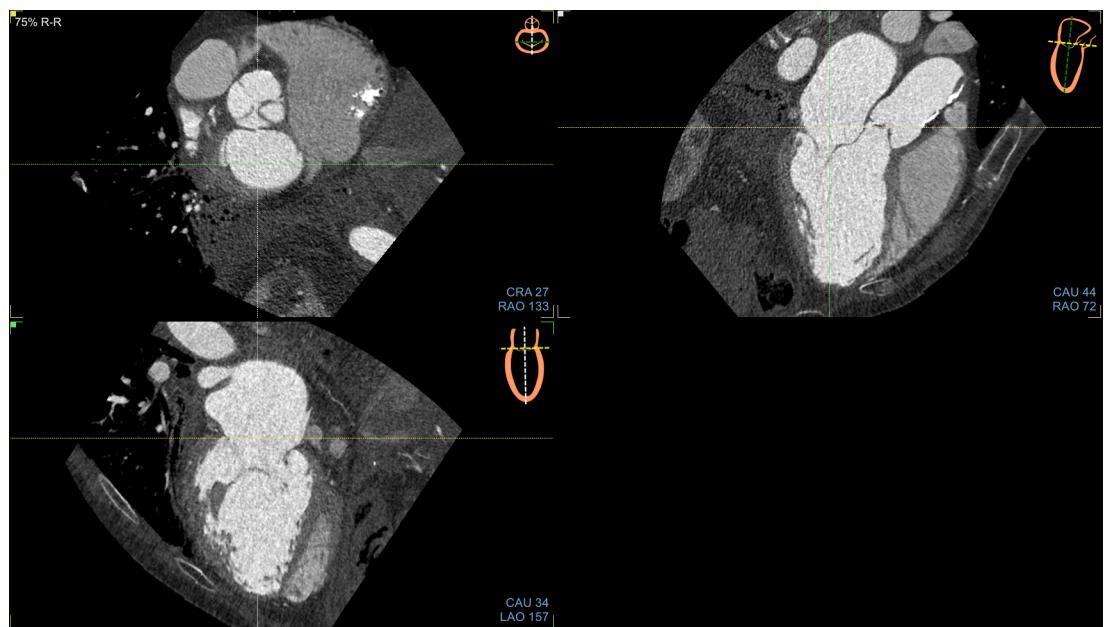1. Bax JJ, Debonnaire P, Lancellotti P, Ajmone Marsan N, Tops LF, Min JK, et al.
Transcatheter Interventions for Mitral Regurgitation: Multimodality Imaging for Patient
Selection and Procedural Guidance. JACC Cardiovasc Imaging. 2019 Oct;12(10):2029–48.

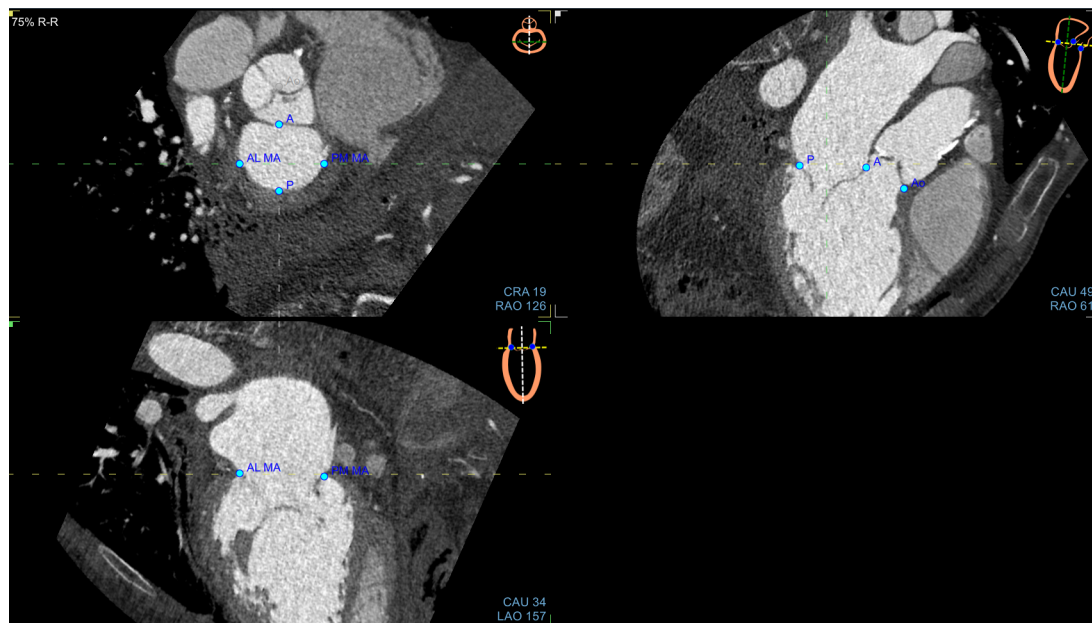
FIGURE LEGENDS

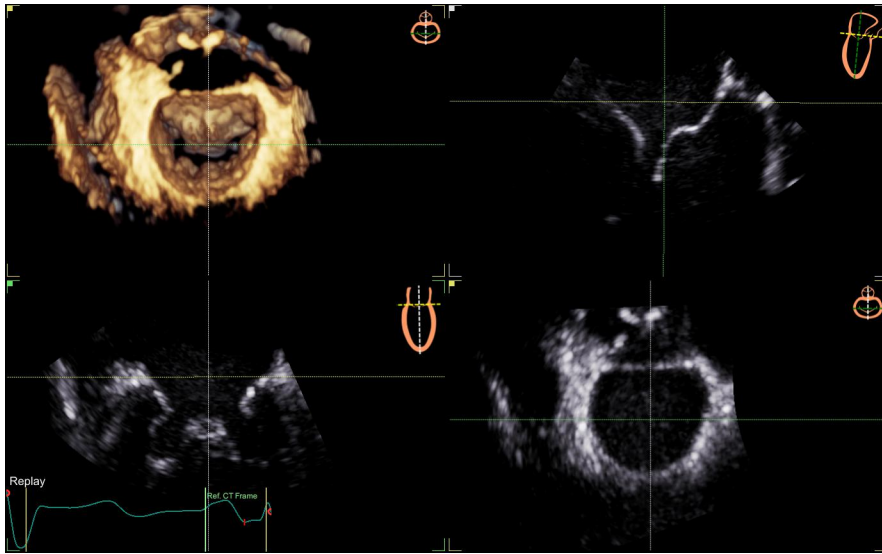Figure 1. Step-by-step Echo-CT Fusion overview. **A**, Alignment with CT acquisition is the first mandatory step to ensure standardized and expected views where vertical axis crosses through the center of the mitral valve while the horizontal axis is parallel to the mitral valve. **B**, 5 landmarks are then placed (two mitral annulus points, two anterior/posterior points plus the aorta point). **C**, An alignment step is then performed on a 3D volume of the mitral annulus set. **D**, Finally same landmarks are placed on the 3D TEE volume allowing **E**, Echo-CT fusion imaging

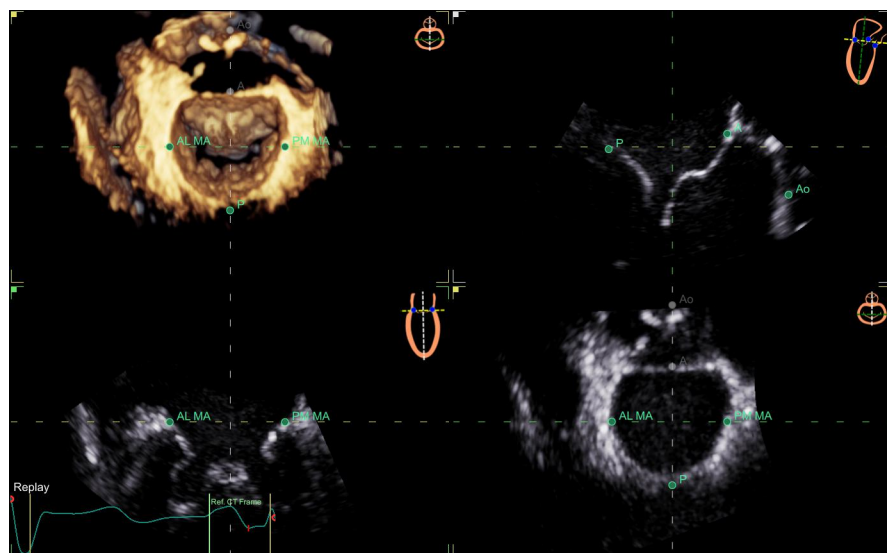Figure 2. Example of Echo-CT fusion with the Intrepid® prosthesis. Echo-CT fusion pre (A) and post (B) deployment of Intrepid® prosthesis and its utility to crossing the mitral annulus plan with the prosthetic system while avoiding the sub-valvular apparatus (red arrow)

Figure 3. Example of Echo-CT fusion to assess neo-LVOT after TMVR with the Tendyne® prosthesis. **A**. After the deployment, the amount of material and the shadowing of the device made difficult the assessment of the neo-left ventricular outflow tract (neo-LVOT). **B**, With Echo-CT fusion, the assessment of the neo-LVOT (red arrow) may be more accurate to assess LVOT obstruction. This could be very useful for Tendyne prosthesis which is fully recapturable and retrievable

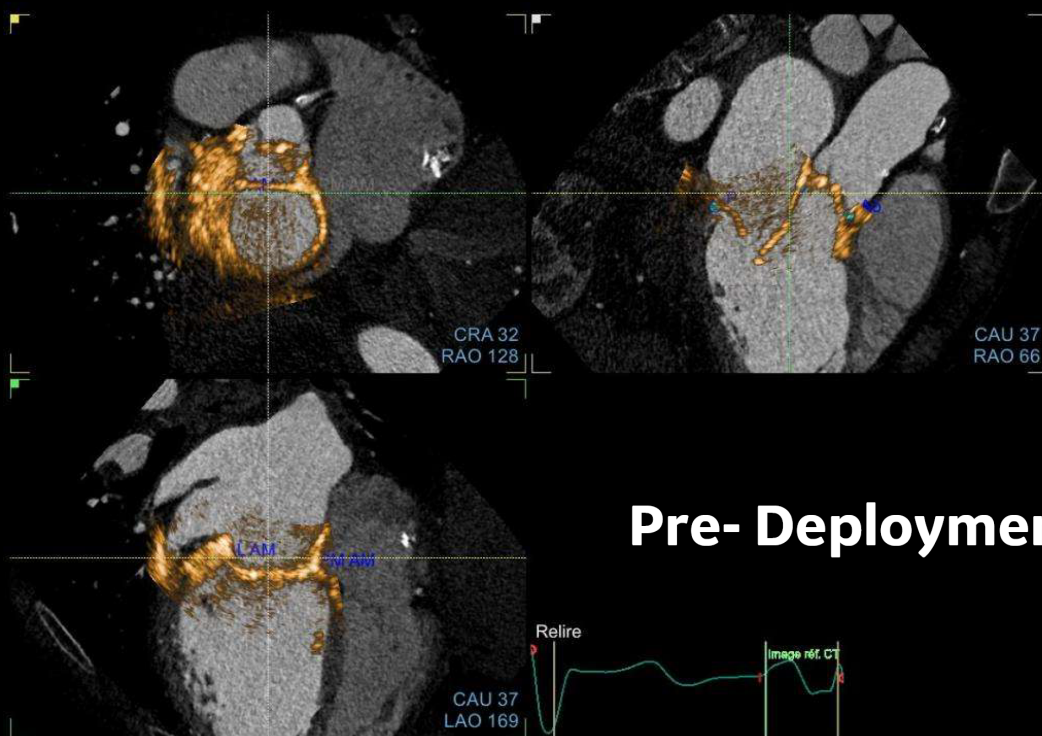




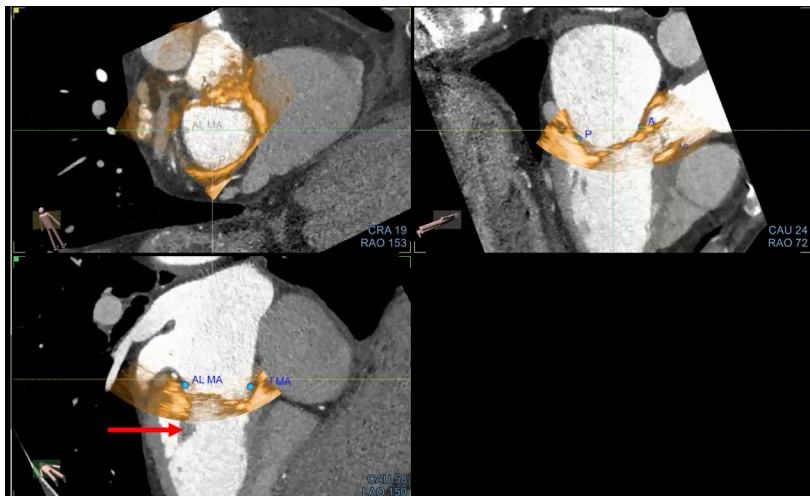


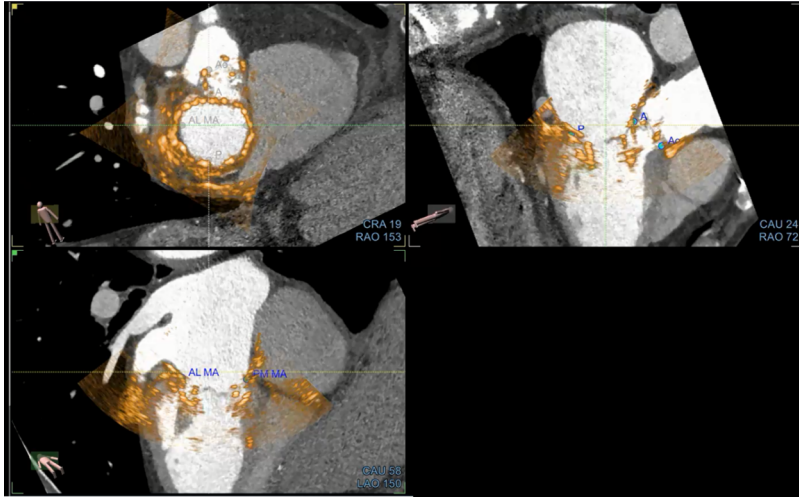


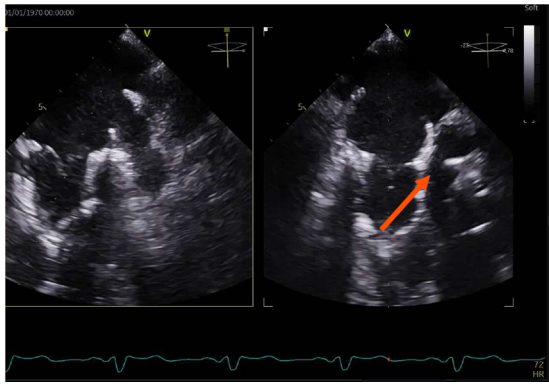
01/01/1970 00:00:00

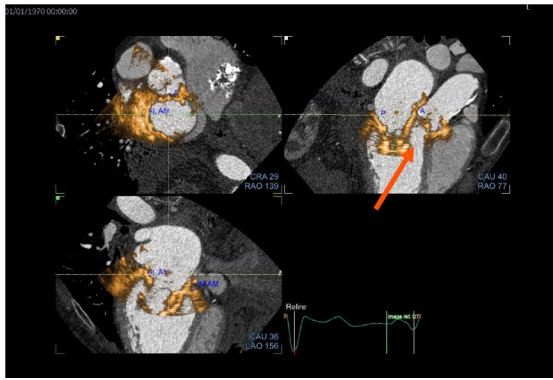


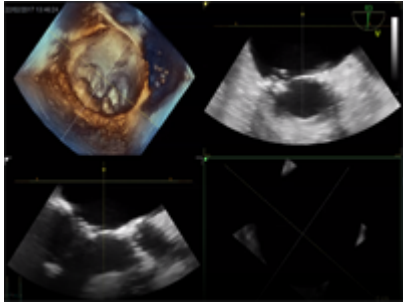
Pre- Deployment











VIDEO LEGEND

Video: Echo-CT fusion overview