



HAL
open science

Fatal acetaminophen poisoning with hepatic microvesicular steatosis in a child after repeated administration of therapeutic doses

Renaud Bouvet, Aurelie Cauchois, Alain Baert, Bernard Fromenty, Isabelle Morel,
Bruno Turlin, Thomas Gicquel

► To cite this version:

Renaud Bouvet, Aurelie Cauchois, Alain Baert, Bernard Fromenty, Isabelle Morel, et al.. Fatal acetaminophen poisoning with hepatic microvesicular steatosis in a child after repeated administration of therapeutic doses. *Forensic Science International*, 2020, 310, pp.110258. <10.1016/j.forsciint.2020.110258>. <hal-02563468>

HAL Id: hal-02563468

<https://univ-rennes.hal.science/hal-02563468v1>

Submitted on 14 May 2020

HAL is a multi-disciplinary open access archive for the deposit and dissemination of scientific research documents, whether they are published or not. The documents may come from teaching and research institutions in France or abroad, or from public or private research centers.

L'archive ouverte pluridisciplinaire **HAL**, est destinée au dépôt et à la diffusion de documents scientifiques de niveau recherche, publiés ou non, émanant des établissements d'enseignement et de recherche français ou étrangers, des laboratoires publics ou privés.



HAL Authorization

Fatal acetaminophen poisoning with hepatic microvesicular steatosis in a child after repeated administration of therapeutic doses

Renaud Bouvet^{1,2}, Aurélie Cauchois^{1,5}, Alain Baert¹, Bernard Fromenty³, Isabelle Morel^{3,4}, Bruno Turlin^{3,5}, Thomas Gicquel^{3,4}

¹Department of Forensic Medicine, Rennes University Hospital, Rennes, France. ²IDPSP – EA 4640, Rennes University, Rennes, France. ³Univ Rennes, Inra, Inserm, Institut NUMECAN – UMR_A 1341, UMR_S 1241, Rennes, France. ⁴Department of Forensic Toxicology, Rennes University Hospital, Rennes, France. ⁵Department of Pathology, Rennes University Hospital, Rennes, France

Corresponding author at: Rennes University Hospital. Department of Forensic Toxicology
2, rue Henri Le Guilloux 35033 Rennes cedex 9, France

E-mail address : thomas.gicquel@chu-rennes.fr (T. Gicquel)

Abstract

Acetaminophen is the leading cause of acute liver failure worldwide following massive ingestion. We present here a fatal acute liver failure after repeated administration of four therapeutic doses of acetaminophen at 4-hour intervals in a previously healthy 9-year-old female who presented dental pain after a facial trauma during sport practice. A diagnosis of paracetamol-induced hepatitis was deduced from the clinical picture of fulminant hepatitis and tubular necrosis, the encephalopathy with oedema and without signs of trauma. Liver biopsy showed typical acetaminophen-induced necrosis and a microvesicular steatosis in periportal hepatocytes. These injuries might have been favored by pre-existing mitochondrial

dysfunction related, for instance, to a deficiency in an enzyme of the mitochondrial β -oxidation pathway, or the respiratory chain. The observation of microvesicular steatosis in the periportal areas suggests an increased vulnerability via pre-existing mitochondrial dysfunction. As the liver status of patients is mostly unknown, the frequency of administration (every six hours) must be respected and the use of pharmaceutical forms allowing to adjust the dose as closely as possible to the child's weight should be promoted.

Key words : Acetaminophen-induced hepatotoxicity, Pediatric acute-liver, failure, Microvesicular steatosis, Painkiller toxicity, Death

Abbreviations

ALF : acute liver failure, CT: Computed Tomography, CYP: cytochrome P450, NAPQI: N-acetyl-p-benzoquinoneimine

1. Introduction

Acetaminophen is the leading cause of acute liver failure (ALF) worldwide, either following intentional overdose or unintentional ingestion [1]. The number of deaths in North America and Europe shows no sign of decreasing, despite some efforts to limit package size in the United Kingdom and the availability of an antidote [2]. Few cases of acetaminophen-induced ALF with slightly supratherapeutic doses have been reported in children [3, 4]. We present a fatal acute liver failure after repeated administration of four therapeutic doses of acetaminophen at 4-hour intervals in a previously healthy 9-year-old female. Liver biopsy

showed typical acetaminophen-induced necrosis and a microvesicular steatosis in periportal hepatocytes. This case highlights that as the liver status of patients is mostly unknown, the frequency of administration must be respected and the use of pharmaceutical forms allowing to adjust the dose as closely as possible to the child's weight should be promoted.

2. Case report

We report the case of a girl aged 9 years with unremarkable medical history (weight 30 kg; height: 1.35 m; body mass index 16.5 kg/m²). She developed dental pain after a facial trauma during sport practice. Her mother gave her a tablet of acetaminophen (acetaminophen) 500 mg on four occasions, with a 4-hour interval between each dose. In the evening, the girl experienced abdominal pain with vomiting. At 48 hours after taking acetaminophen, vomiting was still present, and headaches and confusion developed.

The clinical examination in the paediatric emergency department showed somnolence. Laboratory testing showed hepatocellular insufficiency (prothrombin ratio: 12%; factor V: 12%), cytolysis (AST: 11500 IU/L; ALT: 16200 IU/L), lactate: 5 mmol/L. and renal insufficiency (urea: 18 mmol/L; creatinine: 120 µmol/L). The acetaminophen blood concentration was measured at 8.9 µg/mL. Treatment with intravenous N-acetylcysteine (3g/24h) was initiated according to usual habits and the girl was admitted to the paediatric intensive care unit. Intracranial hypertension was treated with boluses of thiopental sodium, mannitol and moderate hyperventilation. A cranial CT scan demonstrated diffuse cerebral oedema with involvement of the cerebellum, without any haemorrhagic lesion. There was also a mild focal infection around one of the upper right molars. Laboratory results clearly demonstrated severe hepatocellular insufficiency (prothrombin ratio: 11% 12 hours after

admission in the paediatric emergency department then <10% 3 hours later, justifying infusion of fibrinogen; at the time of the death, prothrombin ratio: 21%), and also functional renal insufficiency, with diuresis preserved. A haemodynamic failure necessitated the infusion of normal saline solution and noradrenaline, then, following development of cardiac insufficiency (ejection fraction < 20%), dobutamine. In the presence of terminal liver failure with hepatorenal syndrome, high-volume haemodiafiltration (60 ml/kg) was started. A liver biopsy was performed to investigate this liver failure. Despite the initial regression of mydriasis, the neurological picture evolved to brain death. An autopsy was performed at the request of the judicial authority.

Additional investigations did not find any markers in support of a viral infection (hepatitis A, B, C, E; HIV; EBV; HSV; VZV) or autoimmune hepatitis (negative for presence of anti-smooth muscle antibodies, anti-mitochondrial antibodies, anti-LKM1 antibodies, anti-LC1 antibodies and anti-parietal cell antibodies). Testing for amanitin in urine was negative. Ceruloplasmin and urine and plasma copper concentrations, and the absence of copper deposits on liver biopsy allowed Wilson disease to be ruled out.

The liver biopsy showed two features. The first was necrosis in the centri and mediolobular zones, affecting 60% of hepatocytes (Figure 1A). This feature was typical of acetaminophen-induced necrosis. The second feature was microvesicular steatosis in periportal hepatocytes (Figure 1B). There were no fibrosis or inflammation. Perls staining did not find any evidence of haemosiderin deposition. Examination of a renal parenchymal specimen obtained during the autopsy showed several areas of eosinophilic necrosis of approximately 70% of tubules, with total disappearance of nuclei. Glomeruli were on the whole preserved, although there were some eosinophilic deposits in the form of crescents. The neuropathological examination

revealed multifocal subdural and subarachnoid haemorrhage with interstitial oedema and massive neuronal loss. There were no signs of infection.

A diagnosis of acetaminophen-induced hepatitis was deduced from the clinical picture of fulminant hepatitis and tubular necrosis, the encephalopathy with oedema and without signs of trauma, and the results of additional investigations, especially necrosis of hepatocytes with eosinophilic and apoptotic aspect, without inflammation. A thorough police investigation confirmed that four tablets of acetaminophen 500 mg had indeed been administered at 4-hour intervals and that no other treatment had been used. Figure 2 provides the time frame of events of this case according to police investigation and patient medical records.

3. Discussion

The pain reliever acetaminophen is one of the most widely prescribed drugs in the world. Although this medicine is usually considered as a safe drug, there is inscreasing evidence that the current maximum recommended dose of acetaminophen can induce hepatic cytolysis in a significant proportion of healthy subjects [5, 6].

In the absence of comorbidity, acetaminophen is prescribed at a dose of 15 mg/kg every 6 hours (60 mg/kg per day) for children weighing more than 10 kg, and 7.5 mg/kg every 6 hours (30 mg/kg per day) for children weighing less than 10 kg. The dosage of 150 mg/kg per day or as a single dose is widely accepted as the toxicity threshold. Nevertheless, Kozer et al. [7] and Heard et al. [8] proposed that the dose of 75 mg/kg per day could be considered without risk in children aged less than six years. More recently, Caparrotta et al. [9] estimated that the

safe (and still effective) oral dose of acetaminophen in patients weighing less than 50 kg had not been established.

In our case, the results of investigations allowed to conclude that the death was caused by acetaminophen poisoning: the diagnostic work-up allowed to eliminate differential diagnoses and to rule out an intercurrent pathological process and exposure to other medications, in contrast to other publications [10, 11]. This conclusion must be discussed with the following reservations: the speed of onset of fatal hepatitis does not correspond to the usually observed evolution, the evaluation of the ingested dose was based on the statements of the family, the absence of urine samples does not allow to assess the exposure to xenobiotics based on a full toxicological analysis. The pharmacogenetic study of cytochrome P4502E1 (CYP2E1) was not carried out [12], as well as the study of possible interference associated with other drug or dietary xenobiotics. However, these reservations would not affect the finding of acetaminophen exposure as the probable cause of death. Acetaminophen was administered at a dose of 16.7 mg/kg every four hours for twelve hours, giving a cumulative dose of 66.6 mg/kg in twelve hours, which is lower than the dose of 75 mg/kg per day considered safe in children aged below six years, and much lower than the commonly accepted toxicity threshold of 150 mg/kg per day.

Unintentional administration of suprathreshold doses of acetaminophen is known to induce hepatotoxicity and to be associated with high mortality [13-16]. It is also known that caregivers can be reluctant to accept the fact that they made a mistake contributing to child's illness. In our case, the history of consumption reported by the mother has not changed during extended medical and judicial investigations. The statements of the family were verified by a thorough police investigation, including interrogations of mother, relatives, pharmacist, dentist and general

practitioner involved in the care provision. Interpretation of acetaminophen blood concentration at presentation to hospital should be cautious. We agree that this concentration may be higher than expected. However, various studies conducted reported no correlation between the reported ingested doses and the plasma acetaminophen concentrations [17-19]. The last dose of acetaminophen occurred within 24 hours before admission and therefore the concentration measurement. If we assume the hypothesis of a pre-existing vulnerability leading, in the presence of acetaminophen, to a cellular dysfunction by mitochondrial involvement, then the toxicity no longer results solely from metabolism by an accessory pathway, and taking into account the half-life of acetaminophen alone does not explain the kinetics of hepatic injury.

Besides the presence of parenchymal necrosis in the centrilobular zones, it is noteworthy that microvesicular steatosis was present in the periportal areas. Notably, previous investigations have shown that the occurrence of drug-induced microvesicular steatosis was mainly the consequence of a severe impairment of mitochondrial fatty acid β -oxidation either via a direct inhibition of this metabolic pathway, or secondary to an alteration of the mitochondrial respiratory chain activity [20, 21]. Acetaminophen, via the generation of N-acetyl-*p*-benzoquinoneimine (NAPQI), can induce severe and irreversible mitochondrial dysfunction, thus leading to profound ATP depletion and liver necrosis [22, 23]. Hence, acetaminophen-induced mitochondrial dysfunction is able to induce not only centrilobular necrosis but also microvesicular steatosis [24]. However, acetaminophen has been given to the young patient at therapeutic doses, which might have been unable to induce severe mitochondrial dysfunction. In keeping with this assumption, a recent experimental study in mice showed that low dose acetaminophen induced reversible mitochondrial dysfunction in liver associated to steatosis but without the occurrence of necrosis [25].

Hence, alternatively, acetaminophen-induced necrosis and microvesicular steatosis might have been favored in this case by pre-existing mitochondrial dysfunction, as reported for other drugs. For instance, several studies reported the occurrence of severe and even fatal hepatotoxicity induced by therapeutic doses of sodium valproate in patients suffering from an underlying genetic mitochondrial diseases such as a deficiency in medium-chain acyl-coenzyme A dehydrogenase (MCAD, a mitochondrial β -oxidation enzyme), or in one of the five mitochondrial respiratory chain complexes [26, 27]. Unfortunately, we were unable to have biological samples usable for DNA extraction in order to perform genetic analysis in the patient, or her mother.

Although hepatic steatosis is not generally considered as a typical pathological feature in patients suffering from acetaminophen hepatotoxicity, some cases of mild steatosis (or mild fatty changes) have been previously reported [24, 28-30]. In one of these studies, the authors reported that fatty microvacuoles were invariably found in the surviving liver cells [21]. Notably, microvesicular steatosis has also been reported in different rodent models of acetaminophen hepatotoxicity [25, 31-33]. In one of these articles, microvesicular steatosis was particularly observed in C57BL/6N mice infected with influenza B virus and pretreated with 3-methylcholanthrene, a potent cytochrome P450 inducer [31]. Interestingly, microvesicular steatosis in this murine model was associated with ultrastructural alterations of mitochondria. Because microvesicular steatosis was not observed in acetaminophen-intoxicated mice only infected with influenza B virus, or in acetaminophen-intoxicated mice only pretreated with 3-methylcholanthrene, these data clearly indicated that the occurrence of microvesicular steatosis was due to the presence of concomitant predisposing factors [31]. Finally, it is noteworthy that fatty change and “fine fat vacuoles” (thus indicating

microvesicular steatosis) were observed in a dog model of acetaminophen-induced fulminant hepatic failure [34]. Considering the aforementioned data as well as our case report, we might recommend that pathologists should report any significant microvesicular steatosis associated with necrosis in patients with acetaminophen-induced liver injury. If possible, the search for potential predisposing factors (either genetic or environmental) might also help to understand why some drugs are able to induce severe microvesicular steatosis in a few patients [21, 26].

Wider debate about the evaluation of the hepatotoxic risk of acetaminophen and the medical management of slightly supratherapeutic doses has to be continued, with regard to both patients and health professionals. Concerning patients, the lack of public awareness surrounding safe self-medication has been demonstrated, especially in the context of dental pain, which contributes to a significant number of acute medical admissions as a result of accidental acetaminophen overdose [35]. Concerning health professionals, there is a need for training if we consider the caregivers' knowledge about acetaminophen administration in children. According to Mullan et al. [36], approximately a quarter of them did not know the maximum daily dose, just under half did not know how many days this dose could be safely given, and over one-third did not know that liver toxicity could result from overdose.

4. Conclusion

We report an observation of a fatal acute liver failure in a 9-year-old child after allegedly repeated administration of therapeutic doses at 4-hour intervals. Clinical and biological information strongly suggest that acetaminophen exposure is the cause of the ALF. One hypothesis is that this ALF results from an overdose. However no evidence came during the judicial investigation to support this hypothesis. The observation of a microvesicular steatosis

in the periportal areas, offers another hypothesis, that of increased vulnerability via pre-existing mitochondrial dysfunction. In this hypothesis, the scheme of administration consisting in reducing the recommended interval between two doses could have played a role. As the liver status of patients is mostly unknown, the frequency of administration (every six hours) must be respected and the use of pharmaceutical forms allowing to adjust the dose as closely as possible to the child's weight should be promoted [37].

Declaration of Interest statement

There are no interest statement to declare.

Acknowledgments

We wish to thank Professor Bruno Megarbane for enriching discussions and interesting comments.

References

1. Bunchorntavakul C, Reddy K. Acetaminophen (APAP or N-acetyl-p-aminophenol) and acute liver failure. *Clin Liver Dis* 2018; 22: 325-334.
2. Lee WM. Acetaminophen (APAP) hepatotoxicity - Isn't it time for APAP to go away? *J Hepatol* 2017; 67: 1324-13331.
3. Alonso E, Sokol R, Hart J, Tyson W, Narkewicz M, Whittington P. Fulminant hepatitis associated with centrilobular hepatic necrosis in young children, *J Pediatr* 1995; 127: 888-894.
4. Heubi J, Barbacci M, Zimmerman H. Therapeutic misadventures with acetaminophen: Hepatotoxicity after multiple doses in children. *J Pediatr* 1998; 132: 22-27.
5. Watkins PB, Kaplowitz N, Slattery JT, Colonese CR, Colucci SV, Stewart PW, Harris SC. Aminotransferase elevations in healthy adults receiving 4 grams of acetaminophen daily: a randomized controlled trial. *JAMA* 2006; 296:87-93.
6. Winnike JH, Li Z, Wright FA, Macdonald JM, O'Connell TM, Watkins PB. Use of pharmaco-metabonomics for early prediction of acetaminophen-induced hepatotoxicity in humans. *Clin Pharmacol Ther* 2010; 88:45-51.
7. Kozer E, Greenberg R, Zimmerman DR, Berkovitch M. Repeated supratherapeutic doses of paracetamol in children – a literature review and suggested clinical approach. *Acta Paediatr* 2006; 95: 1165-1171.
8. Heard K, Bui A, Mlynarchek SL, Green JL, Bond GR, RF Clark, Kozer E, Koff RS, Dart RC. Toxicity from repeated doses of acetaminophen in children: assessment of causality and dose in reported cases. *Am J Thera* 2014; 21: 174-183.

9. Caparrotta, T, Antoine D, Dear J. Are some people at increased risk of paracetamol-induced liver injury? A critical review of the literature. *Eur J Clin Pharmacol* 2018; 74:147-160.
10. Nahata M, Powell D, Durrell D, Miller M. Acetaminophen accumulation in pediatric patients after repeated therapeutic doses. *Eur J Clin Pharmacol* 1984; 27: 57-59.
11. Penna A, Buchanan N. Paracetamol poisoning in children and hepatotoxicity. *Br J Clin Pharmacol* 1991; 32: 143-149.
12. Anundi I, Lateenmaki T, Rundrgren M, Moldeus P, Lindros K. Zonation of acetaminophen metabolism and cytochrome P450 2E1-mediated toxicity studied in isolated periportal and perivenous hepatocytes. *Biochem Pharmacol* 1993; 45: 1251-1259.
13. Heubi JE, Barbacci MB, Zimmerman HJ. Therapeutic misadventures with acetaminophen: hepatotoxicity after multiple doses in children. *J Pediatr* 1998; 132: 22- 27.
14. Rivera-Penera T, Gugig R, Davis J, McDiarmid S, Vargas J, Rosenthal P, et al. Outcome of acetaminophen overdose in pediatric patients and factors contributing to hepatotoxicity. *J Pediatr* 1997; 130: 300-304.
15. Heubi JE, Bien JP. Acetaminophen use in children: more is not better. *J Pediatr* 1997; 130: 175.
16. Sztajnkrzyer MJ, Bond GR. Chronic acetaminophen overdosing in children: risk assessment and management. *Curr Opin Pediatr* 2001; 13: 177-182.
17. Gee P, Ardagh M. Paediatric exploratory ingestions of paracetamol. *N Z Med J* 1998; 111: 186-188.
18. Ambre J, Alexander M. Liver toxicity after acetaminophen ingestion: inadequacy of the dose estimate as an index of risk. *JAMA* 1977; 238: 500-501.
19. Read RB, Tredger JM, Williams R. Analysis of factors responsible for continuing mortality after paracetamol overdose. *Hum Toxicol* 1986; 5: 201–206.

20. Begriche K, Massart J, Robin MA, Borgne-Sanchez A, Fromenty B. Drug-induced toxicity on mitochondria and lipid metabolism: mechanistic diversity and deleterious consequences for the liver. *J Hepatol* 2011; 54: 773-794.
21. Fromenty B, Pessayre D. Inhibition of mitochondrial beta-oxidation as a mechanism of hepatotoxicity. *Pharmacol Ther* 1995; 67: 101-154.
22. Moles A, Torres S, Baulies A, Garcia-Ruiz C, Fernandez-Checa JC. Mitochondrial-lysosomal axis in acetaminophen hepatotoxicity. *Front Pharmacol* 2018; 9: 453.
23. Xie Y, McGill MR, Dorko K, Kumer SC, Schmitt TM, Forster J, Jaeschke H. Mechanisms of acetaminophen-induced cell death in primary human hepatocytes. *Toxicol Appl Pharmacol* 2014; 279: 266-274.
24. Massart J, Begriche K, Buron N, Porceddu M, Borgne-Sanchez A, Fromenty B. Drug-induced inhibition of mitochondrial fatty acid oxidation and steatosis. *Curr Pathobiol Rep* 2013; 1: 147-157.
25. Hu J, Ramshesh VK, McGill MR, Jaeschke H, Lemasters JJ. Low dose acetaminophen induces reversible mitochondrial dysfunction associated with transient c-Jun N-terminal kinase activation in mouse liver. *Toxicol Sci* 2016; 150: 204-215.
26. Labbe G, Pessayre D, Fromenty B. Drug-induced liver injury through mitochondrial dysfunction: mechanisms and detection during preclinical safety studies. *Fundam Clin Pharmacol* 2008; 22: 335-353.
27. Krähenbühl S, Brandner S, Kleinle S, Liechti S, Straumann D. Mitochondrial diseases represent a risk factor for valproate-induced fulminant liver failure. *Liver* 2000; 20: 346-348.
28. Portmann B, Talbot IC, Day DW, Davidson AR, Murray-Lyon IM, Williams R. Histopathological changes in the liver following a paracetamol overdose: correlation with clinical and biochemical parameters. *J Pathol* 1975; 117(3): 169-181.

29. Lubel JS, Angus PW, Gow PJ. Accidental paracetamol poisoning. *Med J Aust* 2007; 186(7): 371-372.
30. Ramachandran R, Kakar S. Histological patterns in drug-induced liver disease. *J Clin Pathol* 2009; 62(6): 481-492.
31. MacDonald MG, McGrath PP, McMartin DN, Washington GC, Hudak G. Potentiation of the toxic effects of acetaminophen in mice by concurrent infection with influenza B virus: a possible mechanism for human Reye's syndrome? *Pediatr Res* 1984; 18(2): 181-187.
32. Song Z, McClain CJ, Chen T. S-Adenosylmethionine protects against acetaminophen-induced hepatotoxicity in mice. *Pharmacology* 2004; 71(4): 199-208.
33. Belardinelli MC, Pereira F, Baldo G, Vicente Tavares AM, Kieling CO, da Silveira TR, Meurer L, Soares Duarte ME, Giugliani R, Matte U. Adult derived mononuclear bone marrow cells improve survival in a model of acetaminophen-induced acute liver failure in rats. *Toxicology* 2008; 247(1): 1-5.
34. Gazzard BG, Hughes RD, Mellon PJ, Portmann B, Williams R. A dog model of fulminant hepatic failure produced by paracetamol administration. *Br J Exp Pathol* 1975; 56(5): 408-411.
35. O'Sullivan L, Ahmed N, Sidebottom A. Dental pain management—a cause of significant morbidity due to paracetamol overdose. *British dental journal* 2018; 224: 623-630.
36. Mullan J, Burns P, Sargeant D. Caregivers' knowledge about children's paracetamol. *Journal of Pharmacy Practice and Research*, 2018; 48: 454-458.
37. Bilenko N, Tessler H, Okbe R, Press J, Gorodischer R. Determinants of antipyretic misuse in children up to 5 years of age: a cross-sectional study. *Clin Ther* 2006; 28: 783-793.

Figure legends

Figure 1. Histological features in liver biopsy A: Hepatocytic necrosis around central vein (CV) and steatosis in periportal hepatocytes (PT) (Sirius red stain, X 100) B: Microvesicular steatosis in upper part and necrosis in lower part (HES stain, X 400)

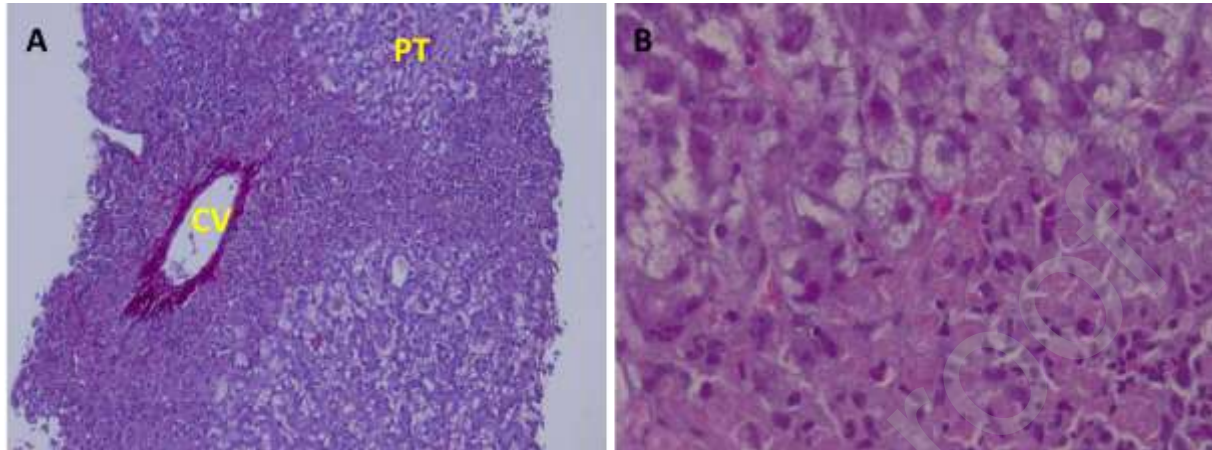


Figure 2. Time frame of events documented by story according to police investigation

