



HAL
open science

Patient-specific access planning in minimally invasive mitral valve surgery

Dario Di Perna, Miguel Castro, Yannig Gasc, Pascal Haigron, Jean-Philippe Verhoye, Amedeo Anselmi

► **To cite this version:**

Dario Di Perna, Miguel Castro, Yannig Gasc, Pascal Haigron, Jean-Philippe Verhoye, et al.. Patient-specific access planning in minimally invasive mitral valve surgery. *Medical Hypotheses*, 2020, 136, pp.109475. 10.1016/j.mehy.2019.109475 . hal-02493270

HAL Id: hal-02493270

<https://univ-rennes.hal.science/hal-02493270>

Submitted on 27 Feb 2020

HAL is a multi-disciplinary open access archive for the deposit and dissemination of scientific research documents, whether they are published or not. The documents may come from teaching and research institutions in France or abroad, or from public or private research centers.

L'archive ouverte pluridisciplinaire **HAL**, est destinée au dépôt et à la diffusion de documents scientifiques de niveau recherche, publiés ou non, émanant des établissements d'enseignement et de recherche français ou étrangers, des laboratoires publics ou privés.

Manuscript number	YMEHY_2019_916
Title	Patient-specific access planning in minimally invasive mitral valve surgery
Article type	Full length article

Abstract

Background: Minimally invasive mitral valve repair or replacement (MIMVR) approaches have been increasingly adopted for the treatment of mitral regurgitation, allowing a shorter recovery time and improving postoperative quality of life. However, inadequate positioning of the right mini thoracotomy access (working port) translates into suboptimal exposure, prolonged operative times and, potentially, reduction in the quality of mitral repair. At present, we are missing tools to further improve the positioning of the working port in order to ameliorate surgical exposure in a patient-specific fashion. Methods and evaluation of the hypothesis: We hypothesized that computation of relevant anatomical measurements from preoperative CT scans in patients undergoing MIMVR may provide patient-specific information in order to propose the surgical access that best fits to the patient's morphology. We hypothesized that this may systematize optimal mitral valve exposure, facilitating the procedure and potentially ameliorating the outcomes. We also hypothesized that preoperative simulation of the working port site and surgical instruments' insertion using a three-dimensional virtual model of the patient is feasible and may help in the customization of ports positioning. The hypothesis was evaluated by a multidisciplinary team including cardiac surgeons, experts in medical image processing and biomedical engineers. CT scans of 14 patients undergoing MIMVR were segmented to visualize 3D chest bones and heart structures meshes. The mitral valve annulus is pointed manually by the expert or extracted automatically when contrast-enhanced CT scan was available. The valve plane was then calculated and the optimal incision location analyzed according to a) the perpendicularity and b) the distance between the intercostal spaces and the valve plane. An angle-chart representation for the 4th, 5th and 6th intercostal spaces and a color map illustrating the distance between the skin and the mitral valve were created. We started the development of a simulation tool for preoperative planning using 3D Slicer software. Conclusions: Several patient-specific factors (including the orientation of the mitral valve plane and the morphology of the chest cage) may influence the performance of a MIMVR procedure, but they are not quantitatively considered in the current planning strategy. We suggest that the clinical results of MIMVR can be improved through preoperative virtual simulation and computer-assisted surgery (through determination of working port and surgical instruments insertion positioning). Further research is justified and the development of a software tool for clinical evaluation is warranted to verify the current hypothesis.

Taxonomy	Surgery, Image-Guided Intervention, Surgical Procedure
Corresponding Author	Dario Di Perna
Corresponding Author's Institution	Division of Thoracic and Cardiovascular Surgery, Pontchaillou University Hospital, Rennes
Order of Authors	Dario Di Perna, Miguel Castro, Yannig Gasc, Pascal Haigron, Jean-Philippe Verhoye, Amedeo Anselmi
Suggested reviewers	Scott LeMaire, Alessandro Parolari, Didier Loulmet

Submission files included in this PDF

File Name [File Type]

letter to the editor.pdf [Cover Letter]

Patient-specific access planning in minimally invasive mitral valve surgery.pdf [Manuscript File]

Figure 1.tif [Figure]

Figure 2.tif [Figure]

Figure 3.tif [Figure]

Figure 4.tif [Figure]

Figure 5.tif [Figure]

Figure 6.tif [Figure]

conflict of interest.pdf [Conflict of Interest]

To view all the submission files, including those not included in the PDF, click on the manuscript title on your EVISE Homepage, then click 'Download zip file'.

Research Data Related to this Submission

There are no linked research data sets for this submission. The following reason is given:
No data was used for the research described in the article

September 9th, 2019

To the attention of:

Mehar S. Manku, MD

Editor-in-Chief, Medical Hypotheses

OBJECT: Manuscript Submission

Dear Dr. Manku,

Please find enclosed the electronic version of the manuscript entitled "*Patient-specific access planning in minimally invasive mitral valve surgery*" which I would like to submit for consideration in Medical Hypotheses (Category: *Full Length Article*).

In the context of the treatment of mitral valve disease, minimally invasive techniques are increasingly employed in order to minimize the rate of post-operative complications and reduce recovery times. In such techniques, limited working space requires optimal positioning of the right minithoracotomy incision (the so-called working-port). Currently the decision of the incision site for the working port is based, primarily, on the surgeon's intuition; nevertheless, this choice directly affects the access to the surgical site and the maneuvering dexterity of the long-shafted surgical instruments. At present, we are missing tools to further improve the positioning of the working port in order to ameliorate surgical exposure in a patient-specific fashion. Herein, we hypothesized that: 1 – In patients with minimally invasive mitral valve surgery (MIMVS) indication, the analysis of the mitral valve plane and its spatial relationship with the thoracic cage, through segmentation and three dimensional reconstruction of the patients' CT scan may provide the determination of incision location for the working port in a patient-specific fashion. 2 – In candidates to MIMVS, pre-operative simulation of the working port site and surgical instruments' insertion by navigating in a three-dimensional virtual model of the patient can be a useful tool for pre-operative planning. The choice of the resulting working port and the use of a software tool for the planning of MIMVS might allow improved mitral valve exposure and optimized orientation of surgical instruments relative to the target. Herein we provide initial validation of the first hypothesis through original empirical data, and discuss the rationale of both hypotheses. Such research pathway could determine a decrease in operative times.

As the corresponding Author, I declare that there is no commercial association which may pose a conflict of interest in connection with the presented material, that there has been no duplicate submission elsewhere, and that the presented material is original and none of the paper's content have been previously published elsewhere. All Authors have read and approved the manuscript. In case of acceptance, we shall transfer the copyright to the Publisher.

Kind regards,

Dario Di Perna, MD

0dariodiperna0@gmail.com

Title: Patient-specific access planning in minimally invasive mitral valve surgery

Dario Di Perna, MD ^{a*}, Miguel Castro, PhD ^a, Yannig Gasc ^a, Pascal Haigron, PhD ^a, Jean-Philippe Verhoye MD, PhD ^a, Amedeo Anselmi, MD, PhD ^a

^aUniv Rennes, CHU Rennes, Inserm, LTSI – UMR 1099, F-35000 Rennes, France

***Corresponding author at:** Division of Thoracic and Cardiovascular Surgery, Pontchaillou University Hospital, 2 rue Henri le Guilloux, 35000 Rennes, France. Tel.: (+33)07.83.17.05.31, e-mail address: Odariodiperna0@gmail.com (D. Di Perna).

Sources of support: The authors received no specific funding for this work.

Ethical standards: Anonymous retrospective procedure data were used. For this type of study, formal consent is not required.

Keywords

- Minimally invasive mitral valve surgery;
- Computer-assisted surgery;
- Clinical outcomes.

Abstract

Background: Minimally invasive mitral valve repair or replacement (MIMVR) approaches have been increasingly adopted for the treatment of mitral regurgitation, allowing a shorter recovery time and improving postoperative quality of life. However, inadequate positioning of the right mini thoracotomy access (working port) translates into suboptimal exposure, prolonged operative times and, potentially, reduction in the quality of mitral repair. At present, we are missing tools to further improve the positioning of the working port in order to ameliorate surgical exposure in a patient-specific fashion.

Methods and evaluation of the hypothesis: We hypothesized that computation of relevant anatomical measurements from preoperative CT scans in patients undergoing MIMVR may provide patient-specific information in order to propose the surgical access that best fits to the patient's morphology. We hypothesized that this may systematize optimal mitral valve exposure, facilitating the procedure and potentially ameliorating the outcomes. We also hypothesized that preoperative simulation of the working port site and surgical instruments' insertion using a three-dimensional virtual model of the patient is feasible and may help in the customization of ports positioning. The hypothesis was evaluated by a multidisciplinary team including cardiac surgeons, experts in medical image processing and biomedical engineers. CT scans of 14 patients undergoing MIMVR were segmented to visualize 3D chest bones and heart structures meshes. The mitral valve annulus is pointed manually by the expert or extracted automatically when contrast-enhanced CT scan was available. The valve plane was then calculated and the optimal incision location analyzed according to a) the perpendicularity and b) the distance between the intercostal spaces and the valve plane. An angle-chart representation for the 4th, 5th and 6th intercostal spaces and a color map illustrating the distance between the skin and the mitral valve

were created. We started the development of a simulation tool for preoperative planning using 3D Slicer software.

Conclusions: Several patient-specific factors (including the orientation of the mitral valve plane and the morphology of the chest cage) may influence the performance of a MIMVR procedure, but they are not quantitatively considered in the current planning strategy. We suggest that the clinical results of MIMVR can be improved through preoperative virtual simulation and computer-assisted surgery (through determination of working port and surgical instruments insertion positioning). Further research is justified and the development of a software tool for clinical evaluation is warranted to verify the current hypothesis.

Text

INTRODUCTION

Mitral regurgitation (MR) is the second most common heart valve disease with surgical indication (1). In primary MR, the valve components are themselves structurally pathological, whereas secondary MR is the expression of a left ventricular disease. Currently, the gold standard treatment for severe primary MR is mitral valve repair, which is to be preferred over valve replacement surgery (2).

Although conventional median sternotomy remains a common approach for the performance of mitral surgery, efforts have been undertaken to develop less invasive surgical approaches in order to minimize the rate of post-operative complications and reduce recovery times. Currently, minimally invasive approaches have been adopted by many cardiac surgery centers as reference techniques, allowing not only better cosmetic results but also improving patients' quality of life (3-7). The most widely performed technique for minimally invasive mitral valve repair or replacement (MIMVR) involves the use of a right 7-to-5 cm antero-lateral mini thoracotomy, the so-called working port, through which dedicated instruments are inserted in order to reach the mitral valve through the right pleural cavity. Another incision in a more cranial and lateral position allows the placement of a 30-degree thoracoscope to achieve high-definition vision of the mitral valve. An atrial retractor is inserted, generally, through the same intercostal space (ICS) of the working port, lateral to the parasternal line. Such retractor allows maintaining the left atrium wide open and an anterior displacement of the mitral valve plane (8). After the establishment of extracorporeal circulation and cardiac arrest by cardioplegic protection, any sort of procedure on the mitral valve can be conducted (9, 10).

Operative times in MIMVR are still longer compared to conventional strategies (11). The minimization of both cardiopulmonary bypass and aortic clamp times is associated with better outcomes in cardiac surgery (12). In MIMVR, limited working space requires optimal positioning of the right minithoracotomy incision, in order to facilitate the technical performance of the operation. Inadequate positioning of the working port translates into suboptimal exposure, prolonged operative times and, potentially, reduction in the quality of mitral repair (9, 13). The localization of incisions in

minimally invasive surgery, in fact, directly affects the access to the surgical site and the maneuvering dexterity of the long-shafted surgical instruments (14, 15) (Fig. 1). The decision of the incision site (working port) has been based so far on general anatomical principles, based on external landmarks and surgeon's intuitive adaptation to the patient's characteristics. However, these criteria remain empirical and expose to suboptimal access in a significant proportion of patients (16, 17). Chest anatomy and localization of the mitral valve with respect to the chest wall structures is variable among individual patients.

At present, we are missing tools to further improve the positioning of the working port in order to ameliorate surgical exposure in a patient-specific fashion, with the ultimate goal of reducing intraoperative times and facilitate effective mitral repair.

THE HYPOTHESIS

We postulated that:

1 – In patients with MIMVR indication, the analysis of the mitral valve plane and its spatial relationship with the thoracic cage, through segmentation and three dimensional reconstruction of the patients' CT scan may provide the determination of incision location for the working port in a patient-specific fashion. The choice of the resulting working port might allow improved mitral valve exposure and optimized orientation of surgical instruments relative to the target.

2 – In candidates to MIMVR, pre-operative simulation of the working port site and surgical instruments' insertion by navigating in a three-dimensional virtual model of the patient can be a useful tool for pre-operative planning. A software tool for preoperative planning of the optimal working port location in MIMVR is feasible.

Effective mitral valve reach using long-shafted surgical instruments through an optimal position of the working port emerges from clinical experience to facilitate the surgical procedure on the valve, with consequent decrease in cardiopulmonary and cross-clamping times, ultimately improving outcomes.

EVALUATION OF THE HYPOTHESIS

For the study design and the preliminary evaluation of the hypotheses, we assembled a dedicated research team consisting of a cardiac surgeon specialized in MIMVR (AA), two experts in medical image processing for innovative clinical applications (MC, PH) and a biomedical engineer (YG) (18). We retrospectively selected 14 consecutive patients undergoing endoscopic MIMVR at a single University cardiac surgery center. These patients underwent preoperatively a chest CT scan with or without contrast enhancement. The indication to mitral surgery was decided according to the current guidelines (1, 19).

CT images must show sufficient visibility of the mitral valve annulus to have limited artifacts and noise. Artifacts can be due to implanted endovascular devices such pacemaker or internal automatic defibrillator leads (as usual gray values were calibrated on the Hounsfield scale).

CT scan investigations were performed preoperatively, as part of routine clinical management, in order to exclude potential contraindications to MIMVR (such as significant aortic atherosclerosis, severe calcification of the mitral annulus, aortic aneurysm or tortuosity, disease of the iliofemoral vessels).

All the acquired CT images were processed in order to obtain a three-dimensional reconstruction of the cardiac chambers, in particular of the mitral valve plane, and of the thoracic cage. Three-dimensional reconstruction was achieved through a semi-automatic segmentation process for those patients who had undergone a contrast-enhanced CT scan, and through manual placement of fiducial markers on the mitral valve annulus for those in which CT scan had been performed without contrast injection. The proposed planning system has been integrated into 3D Slicer, a software platform for the analysis and visualization of medical images (20).

Methods

The CT images were segmented to extract the skin contour, the chest bones and the vascular structures, as well as the localization of the ribs. If CT scan was done with contrast enhancement, the

intersection between the segmented structure of the left ventricle and the segmented structure of the left atrium provided the anatomical region corresponding to the mitral valve; the valve plane was then automatically calculated from this intersection. If the CT scan was done without contrast enhancement, the mitral valve annulus was pointed manually by the expert, and then the valve plane was automatically calculated from these landmark points.

We evaluated the definition of simulated optimal exposure of the mitral valve by several potential parameters. Initially, a perpendicular relationship between the ribs (throughout each one and their interspaces) and the mitral valve plane was defined as a mean to identify the optimal incision site (working port).

Skin segmentation

The skin surface was segmented by using a 3D region growing method (21). The seed point was placed automatically in the empty region of the CT that was not occupied by the human body. Then the contour of the skin was extracted applying a simple Sobel edge detection process.

Thoracic bones segmentation

A binary image was produced from the original CT images by applying a gray-level thresholding method. This binary image contains only the bones structures. If the CT scan was performed with contrast enhancement, a binary mask was used to eliminate the vascular structures.

Heart segmentation

A Multi-Atlas segmentation method proposed by Kirisli et al. (22) was used to obtain a multi-labeled image from the original CT scan with contrast enhancement and its corresponding surface models.

Intercostal spaces localization

Based on the works of Li et al. (23) et Zhang et al. (24), we developed an algorithm for extraction and labelling of individual ribs structures with a recursive tracking on coronal slices spreading from the middle coronal slice. The process starts with the identification of the ribs contours in the mid-coronal planes. A connected-component labelling function was used to identify each rib region and its

contour. A condition about the region size was given in order to eliminate the noise (no-rib structure). The ribs contour was surrounded by using the smallest encompassing circle (25) and then extract the circle centre as rib position. The ICSs locations were obtained by computing the midpoints between two consecutive circle centres. The tracking process continues in both directions, toward the sternum and toward the spinal column.

Mitral valve plane

If the surface models of the ventricle and atrium were present, the mitral valve plane was calculated based on the set of points extracted from the intersection of both models. If not, the mitral valve plane was calculated based on the landmarks manually pointed by the expert (Fig. 2).

Optimal incision location

We defined a measure based on the perpendicularity between a point along a given intercostal space (ICS) and the valve plane. This measure was defined as the angle with respect to the perpendicular plane to the mitral valve. If the angle is 90 degrees, then the incision in this place would show good visibility of the mitral valve. If the angle is much less than 90 degrees, the visibility of the mitral ring would be worse. We represent the possible areas of incision between the 4th, 5th and 6th ICSs as a color map representing the possible incision zones according to angle between the valve plane and the ICS.

Distance from the skin to the valve

We measured the distance between the skin and the valve plane in order to show the working distance. The distance was represented in a color map over the skin segmentation.

CONSEQUENCES OF THE HYPOTHESIS

In MIMVR, optimal exposure and excellent access to the mitral valve are essential. Given the minimal size of the incision, and the avoidance of costal spreading when a fully endoscopic technique with endo-clamping is employed (13), optimal alignment with the mitral valve is pivotal. In fact, valve procedure is performed using long-shafted instruments which extremity has limited degrees of freedom. Optimal alignment between the operator's hands and the valve, as well as limited distance as possible, facilitate the surgical gesture and allows the operator to fully focus on valve repair. The consequent reduction of CBP and aortic clamp times are expected to translate into minimization of operative morbidity.

Currently, the 4th right ICS is most frequently used site for the working port. This choice is mainly due to generalist topographic anatomic concepts, and tailoring on specific patients is done in a limited and non-standardized way. The incision at the 4th interspace may force the surgeon to operate with insufficient alignment or excessive distance from the mitral valve, depending on individual patients' conformation. Additionally, specific comorbidities (such as kyphoscoliosis or other chest deformities) represent a questioning for exposure and even feasibility of MIMVR, and in these circumstances tools for assessment are cruelly lacking.

Herein, we formulate the hypothesis that MIMVR can be facilitated and standardized through dedicated preoperative planning. In order to support such hypothesis, we conduct the preliminary developments of a software tool for preoperative planning of the working port, customizing the analysis for each specific patient. Such method, based on segmentation, 3D reconstruction and analysis of pre-operative CT scans, is aimed at achieving optimal exposure of the mitral valve and greater freedom of movement of instruments within a restricted surgical field. Computer-assisted surgery is a complex specialty which includes and integrates different disciplines, such as image analysis and processing, pre-operative planning, virtual reality and interactive simulation (26). It was applied for the first time in neurosurgery in the 1980s, later also in maxillofacial surgery, orthopedics and more recently in cardiac surgery for the treatment of coronary artery disease (27-29). The current initial work may open the pathway for application in the pre-operative planning of MIMVR.

Our first approach was based on the optimal ICS to incise resulting from the intersection of a line passing through the mitral valve plane with a perpendicular line passing through the center of this plane. The results of this approach in our patient population are shown in Table n. 1. The angles are calculated for the ICSs comprised between the third and the sixth. As can be appreciated from the table, the ICS showing most frequently an angle closer to 90° with respect to the mitral valve plane is most frequently the third interspace, in a quite posterior position. Nonetheless, the use of this space in such region is not technically feasible, especially due to the presence of bone structures (i.e. the scapula), that prevent the insertion of surgical instruments. The 4th ICS actually proves to be a viable option for most patients. This corresponds to the choice, essentially qualitative, reported in the literature (30). However, for several subjects in our population, the angle described at the 4th interspace is clearly less than 90 degrees. This implies intraoperative adaptation to visualize the mitral valve. ICS angle data also suggest that in several cases an approach through the 5th ICS could have been considered (proximity of the angle described by this space with the orthogonal line to the mitral valve plane). Indeed, patient M13 necessarily received incision in the 5th ICS due to the presence of non-mobilizable breast implants; the calculated angle was 85° . Therefore, the pre-operative analysis of the angle described between the mitral valve plane and each ICS allows us to verify which space determines an "*en face*" visualization of the mitral valve.

In a further development step, we used 3D slicer to obtain a representation of the angles described between the mitral valve plane and every individual point along the entire length of ICSs (from the vertebral column towards the sternum). In Figure 4, purple color describes points with angles closer to 90 degrees ('angles chart'). In this interface the user can visually assess which region

in each ICS has the greatest number of points perpendicular to the mitral valve. It is also possible to prospect the anteroposterior length of the incision on the virtual model of the patient.

Nonetheless, a representation based uniquely on perpendicularity to the mitral valve plane has important limitations : 1) the identification of angles closer to 90° in interspaces which cannot be used in clinical practice (such as the posterolateral region of the 3rd interspace); 2) the relatively frequent posterior orientation of the valve plane, the orthogonal line leading into a thoracotomy posterior to the midclavicular line which is not clinically feasible; 3) it does not consider the distance from the incision to the valve, another major determinant of exposure. Additionally, in clinical operations exposure tools (left atrial retractor) allow some degrees of rotation of the mitral plane in the anterior direction. Therefore, we then developed a 3D representation of the distances of each single point on the segmented skin of the thorax to the center of the mitral valve plane. This so-called “distance chart”, presented in Fig. 5, is another pre-operative assessment tool for the incision site, exploitable not only for the working port but also for the insertion of the other trocars. The smaller the mitral-skin distance, the greater the possibility of movement of surgical instruments within a restricted environment such as the left atrium. We believe that the combination of these two parameters (distance and perpendicularity to the valve plane) in a 3D chart might better approach the clinical needs of site incision choice. Therefore, the current simulation tool of the surgical environment integrates several components described for the selection of the working port site: angles measurement with angles-chart and skin-mitral distance chart, within the CT-scan volumes.

As a result of this stepwise approach, we started the design of a software tool for the simulation of the insertion of surgical instruments within a three-dimensional virtual model of the patient. The bony structures of the thorax, as well as the cardiac chambers (in case of contrast-enhanced CT scan)

or only the mitral valve plane (in case of non-contrast-enhanced CT scan) have been segmented and reconstructed. In this graphic interface the user can navigate the axial, coronary and sagittal planes of the loaded CT scan. Through windows management, intra-thoracic organs and structures can be visualized (Fig. 6). An example is the evaluation of the height of the right diaphragmatic dome, as well as the observation of any skeletal anomalies or the presence of intravascular devices. Such elements are difficultly evaluated quantitatively at the present stage; yet, a dedicated visualization tool with 3D representation of the mitral valve and chest structures is expected to facilitate evaluation by the user.

There are several limitations in the present work. CT scans without contrast enhancement were only available for several subjects included in the study. Although less invasive for the patient (avoidance of contrast medium), renders more challenging the placement of markers along the mitral annulus. In the future, either exclusive use of contrast-enhanced CT scan or dedicated acquisition protocols in non-contrast-enhanced CT scan will be applied. Furthermore, herein we do not consider the use of the left atrial retractor determining an intraoperative rotation of the mitral valve plane in the anterior direction. We are developing an algorithm based on deep-learning to can predict and simulate preoperatively such rotation, to be considered in perpendicularity analysis.

In conclusion, the present preliminary development supports the hypothesis that preoperative patient-specific planning may be employed to facilitate MIMVR, through preoperative identification of the working port location for optimal exposure. The combination of several parameters is more likely to achieve clinically reliable preoperative planning in such circumstances. Further research is justified and the development of a software tool for clinical evaluation is warranted to verify the current hypothesis.

References

- [1] V. Falk, H. Baumgartner, J.J. Bax, *et al.*, 2017 ESC/EACTS Guidelines for the management of valvular heart disease, *Eur J Cardiothorac Surg* 2017; 52:616-64.
- [2] H. Welp and S. Martens, Minimally invasive mitral valve repair, *Curr Opin Anaesthesiol* 2014; 27:65-71.
- [3] L.G. Svensson, F.A. Atik, D.M. Cosgrove, *et al.*, Minimally invasive versus conventional mitral valve surgery: a propensity-matched comparison, *J Thorac Cardiovasc Surg* 2010; 139:926-32 e1-2.
- [4] V. Falk, D.C. Cheng, J. Martin, *et al.*, Minimally invasive versus open mitral valve surgery: a consensus statement of the international society of minimally invasive coronary surgery (ISMICS) 2010, *Innovations (Phila)* 2011; 6:66-76.
- [5] D.M. Holzhey, W. Shi, M.A. Borger, *et al.*, Minimally invasive versus sternotomy approach for mitral valve surgery in patients greater than 70 years old: a propensity-matched comparison, *Ann Thorac Surg* 2011; 91:401-5.
- [6] M. Vollroth, J. Seeburger, J. Garbade, *et al.*, Minimally invasive mitral valve surgery is a very safe procedure with very low rates of conversion to full sternotomy, *Eur J Cardiothorac Surg* 2012; 42:e13-5; discussion e16.
- [7] F. Luca, L. van Garsse, C.M. Rao, *et al.*, Minimally invasive mitral valve surgery: a systematic review, *Minim Invasive Surg* 2013; 2013:179569.
- [8] J.A. Wolfe, S.C. Malaisrie, R.S. Farivar, *et al.*, Minimally Invasive Mitral Valve Surgery II: Surgical Technique and Postoperative Management, *Innovations (Phila)* 2016; 11:251-9.

- [9] M. Czesla, J. Gotte, T. Weimar, T. Ruttkay and N. Doll, Safeguards and pitfalls in minimally invasive mitral valve surgery, *Ann Cardiothorac Surg* 2013; 2:849-52.
- [10] A. Agnino, M. Parrinello, P. Panisi and A. Anselmi, Novel nonresectional posterior leaflet remodeling approach for minimally invasive mitral repair, *J Thorac Cardiovasc Surg* 2017; 154:1247-49.
- [11] A. Mazine, M. Pellerin, J.S. Lebon, P.O. Dionne, H. Jeanmart and D. Bouchard, Minimally invasive mitral valve surgery: influence of aortic clamping technique on early outcomes, *Ann Thorac Surg* 2013; 96:2116-22.
- [12] J.F. Sabik, 3rd, S. Raza and K.D. Chavin, Safety and benefits of new techniques and technologies in less invasive mitral valve repair, *J Card Surg* 2018; 33:609-19.
- [13] T. Ito, Minimally invasive mitral valve surgery through right mini-thoracotomy: recommendations for good exposure, stable cardiopulmonary bypass, and secure myocardial protection, *Gen Thorac Cardiovasc Surg* 2015; 63:371-8.
- [14] D. Loulmet, A. Carpentier, N. d'Attellis, *et al.*, Endoscopic coronary artery bypass grafting with the aid of robotic assisted instruments, *J Thorac Cardiovasc Surg* 1999; 118:4-10.
- [15] U. Kappert, J. Schneider, R. Cichon, *et al.*, Development of robotic enhanced endoscopic surgery for the treatment of coronary artery disease, *Circulation* 2001; 104:1102-7.
- [16] J.W. Cannon, J.A. Stoll, S.D. Selha, P.E. Dupont, R.D. Howe and D.F. Torchiana, Port Placement Planning in Robot-Assisted Coronary Artery Bypass, *IEEE Trans Rob Autom* 2003; 19:912-17.

- [17] G. Ailawadi, A.K. Agnihotri, J.R. Mehall, *et al.*, Minimally Invasive Mitral Valve Surgery I: Patient Selection, Evaluation, and Planning, *Innovations (Phila)* 2016; 11:243-50.
- [18] A. Anselmi, S. Collin, P. Haigron, J.P. Verhoye and E. Flecher, Virtual implantation and patient-specific simulation for optimization of outcomes in ventricular assist device recipients, *Med Hypotheses* 2016; 91:67-72.
- [19] S. Heuts, J.G. Maessen and P. Sardari Nia, Preoperative planning of left-sided valve surgery with 3D computed tomography reconstruction models: sternotomy or a minimally invasive approach?, *Interact Cardiovasc Thorac Surg* 2016; 22:587-93.
- [20] A. Fedorov, R. Beichel, J. Kalpathy-Cramer, *et al.*, 3D Slicer as an image computing platform for the Quantitative Imaging Network, *Magn Reson Imaging* 2012; 30:1323-41.
- [21] R. Adams and L. Bischof, Seeded region growing., *IEEE Transactions on Pattern Analysis and Machine Intelligence* 1994; 16:641 - 47.
- [22] H.A. Kirisli, M. Schaap, S. Klein, *et al.*, Evaluation of a multi-atlas based method for segmentation of cardiac CTA data: a large-scale, multicenter, and multivendor study, *Med Phys* 2010; 37:6279-91.
- [23] H. Li, J. Li, S. Pan, Q. Guo, J. Liu and Y. Kang, Automatic Rib Positioning Method in CT Images, *2010 4th International Conference on Bioinformatics and Biomedical Engineering* 2010, 1-4.
- [24] L. Zhang, X. Li and Q. Hu, Automatic Rib Segmentation in Chest CT Volume Data, *2012 International Conference on Biomedical Engineering and Biotechnology* 2012, 750-53.

- [25] E. Welzl, Smallest enclosing disks (balls and ellipsoids) In: H. Maurer, Editor, *New Results and New Trends in Computer Science*, Springer Berlin Heidelberg, Berlin, Heidelberg 1991, 359-70.
- [26] P. Haignon, J. Dillenseger, L. Luo and J. Coatrieux, Image-Guided Therapy: Evolution and Breakthrough [A Look At], *IEEE Engineering in Medicine and Biology Magazine* 2010; 29:100-04.
- [27] P. Jannin and X. Morandi, Surgical models for computer-assisted neurosurgery, *Neuroimage* 2007; 37:783-91.
- [28] R. Marmulla and H. Niederdellmann, Computer-assisted bone segment navigation, *J Craniomaxillofac Surg* 1998; 26:347-59.
- [29] D.Y. Loisanche, K. Nakashima and M. Kirsch, Computer-assisted coronary surgery: lessons from an initial experience, *Interact Cardiovasc Thorac Surg* 2005; 4:398-401.
- [30] F.P. Casselman, S. Van Slycke, H. Dom, D.L. Lambrechts, Y. Vermeulen and H. Vanermen, Endoscopic mitral valve repair: feasible, reproducible, and durable, *J Thorac Cardiovasc Surg* 2003; 125:273-82.

Table

1. **Table 1.** ICSs angle. The angles are calculated for the ICSs comprised between the 3rd and the 6th.

ICSs	3 rd	4 th	5 th	6 th
angle[degree]				
Patient M1	87.1°	83.73°	80.47°	78.20°
Patient M2	81.70°	76.51°	71.68°	65.35°
Patient M3	88.99°	89.86°	86.82°	75.23°
Patient M4	81.98°	77.70°	71.13°	60.33°
Patient M5	83.46°	78.15°	73.85°	66.35°
Patient M6	89.44°	89.98°	89.49°	87.69°
Patient M7	89.27°	87.44°	84.9°	81.88°
Patient M8	88.59°	86.06°	81.89°	77.49°
Patient M9	84.41°	81.10°	76.99°	69.02°
Patient M10	88.43°	84.25°	76.95°	68.03°
Patient M11	89.55°	88.59°	85.81°	81.32°
Patient M12	85.78°	82.87°	78.10°	75.05°
Patient M13	88.49°	87.29°	84.95°	80.99°
Patient M14	86.11°	87.69°	87.96°	86.83°

Captions to illustrations

Fig. 1. Operative setup for endoscopic mitral valve surgery. Red arrow: 5-cm. working port. White asterisk: site of insertion of camera. Green asterisk: site of insertion of field suction and CO2 insufflation. White arrowhead: patient's head.

Fig. 2. Mitral valve plane – semi-automatic segmentation from a contrast-enhanced CT-scan.

Fig. 3. Mitral valve plane – reconstruction based on manually pointed landmarks from a CT-scan without contrast injection.

Fig. 4. Angles-chart – The larger picture illustrates a coronal CT scan including the reconstructed mitral valve plane and the angles chart. The purple color indicates the points characterized by angles closer to 90 degrees and part of the 3rd to 5th ICSs. In small: a schematic representation, useful for planning the incision site. S= superior (cranial), I= inferior.

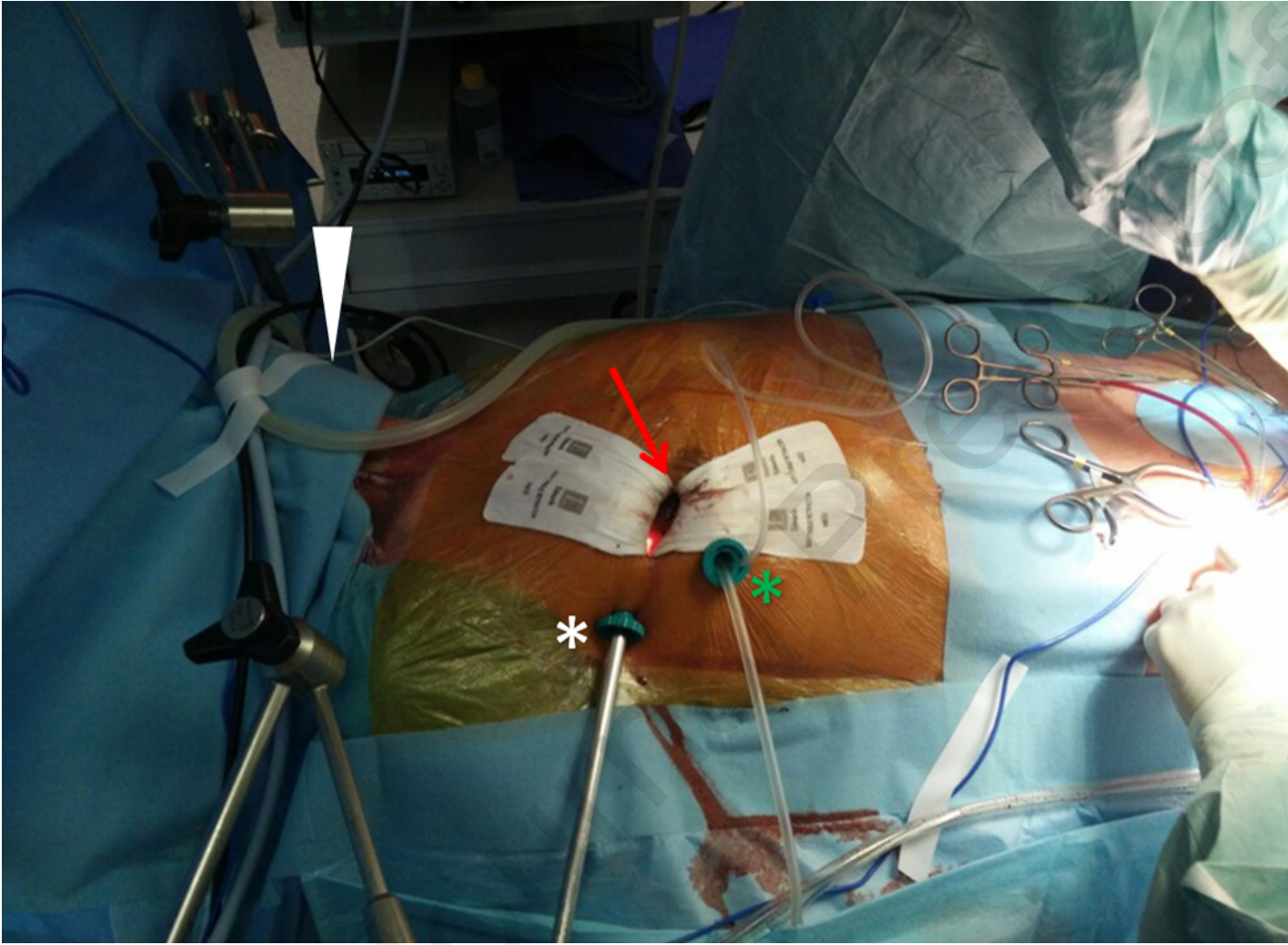Fig. 5. Picture including the angle-chart (A) and the distance-chart (B) calculated for the same patient. Distances were calculated between the center of the mitral valve plane and the skin, and expressed in mm. CT scans showing the reconstructed mitral valve plane for this patient.

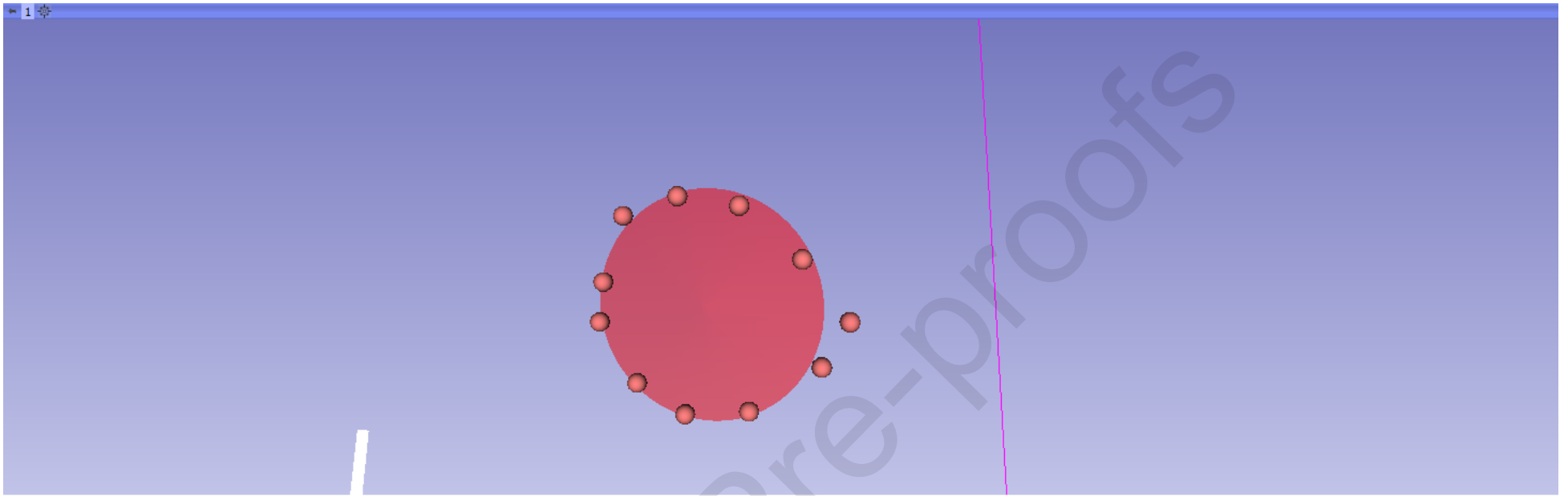
Fig. 6. 3D navigation in a virtual model of the patient. The picture shows the insertion of two long-shafted instruments in the proposed optimal incision for the working-port. Light blue color indicates the segmented scapula (an anatomical obstacle for the insertion of instruments).

Conflict of Interest Statement

There are no financial conflicts of interest to disclose.

Journal Pre-proofs

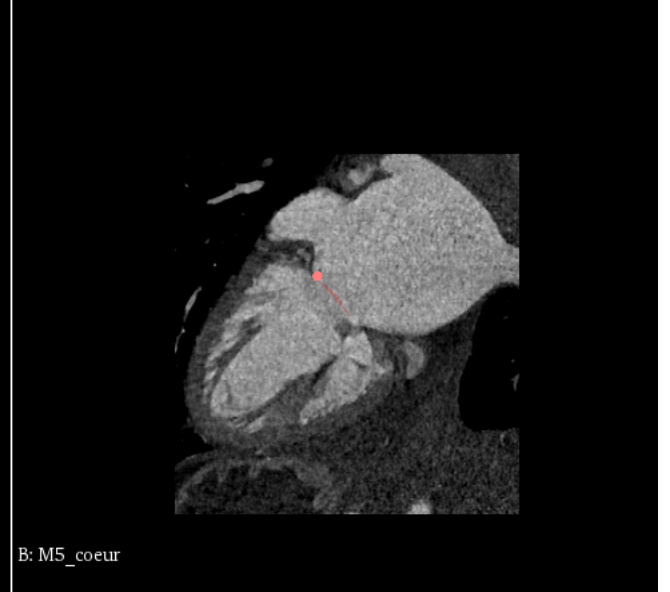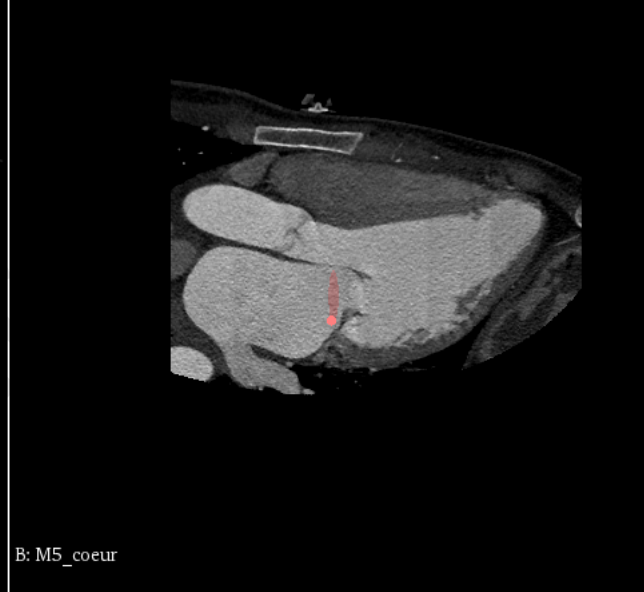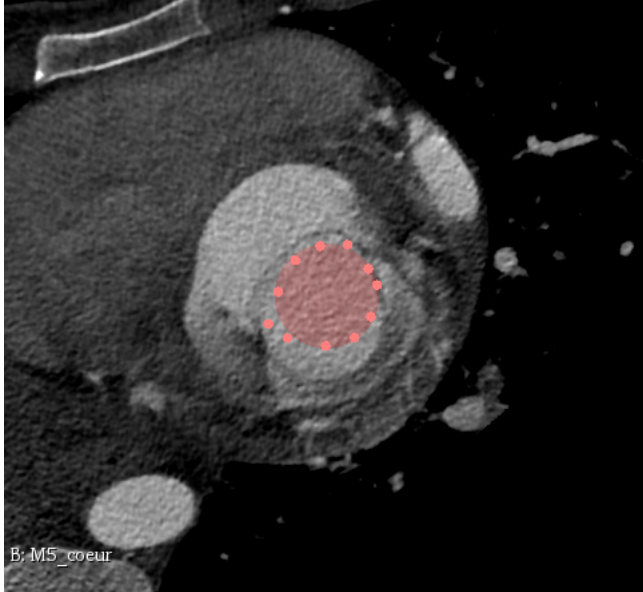


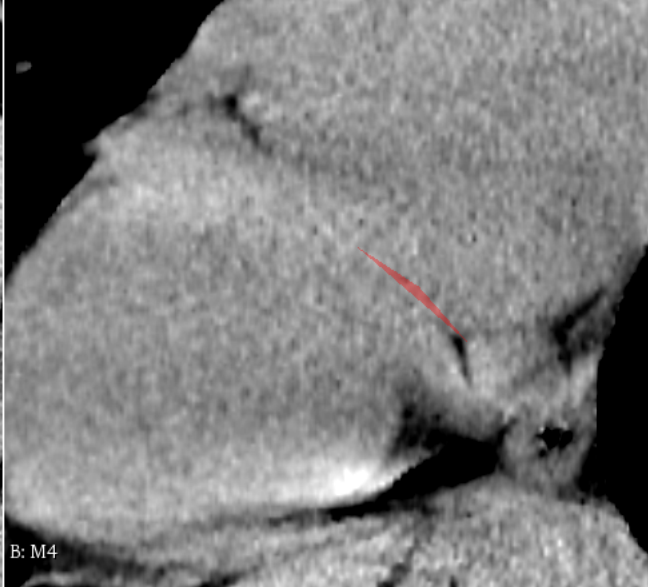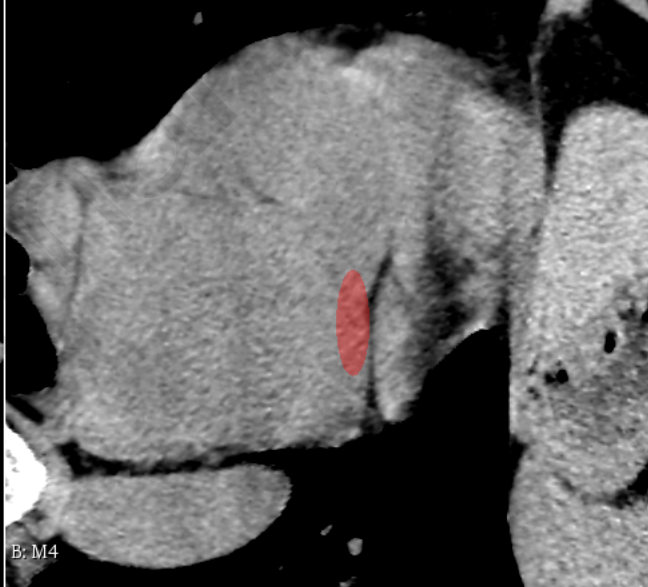
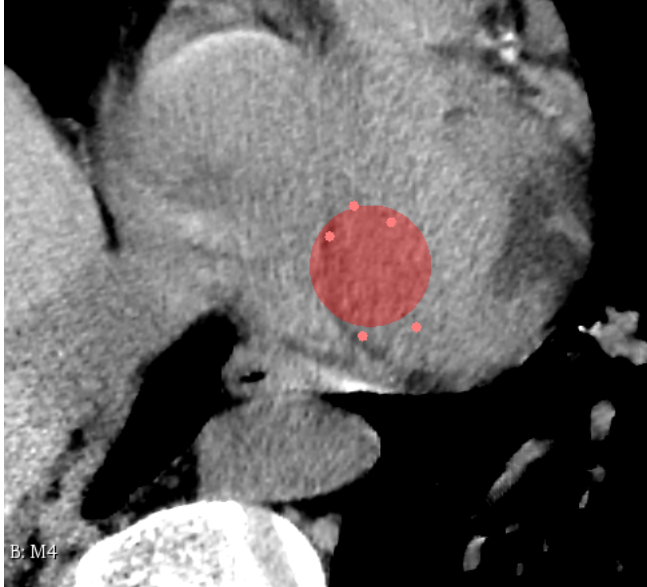
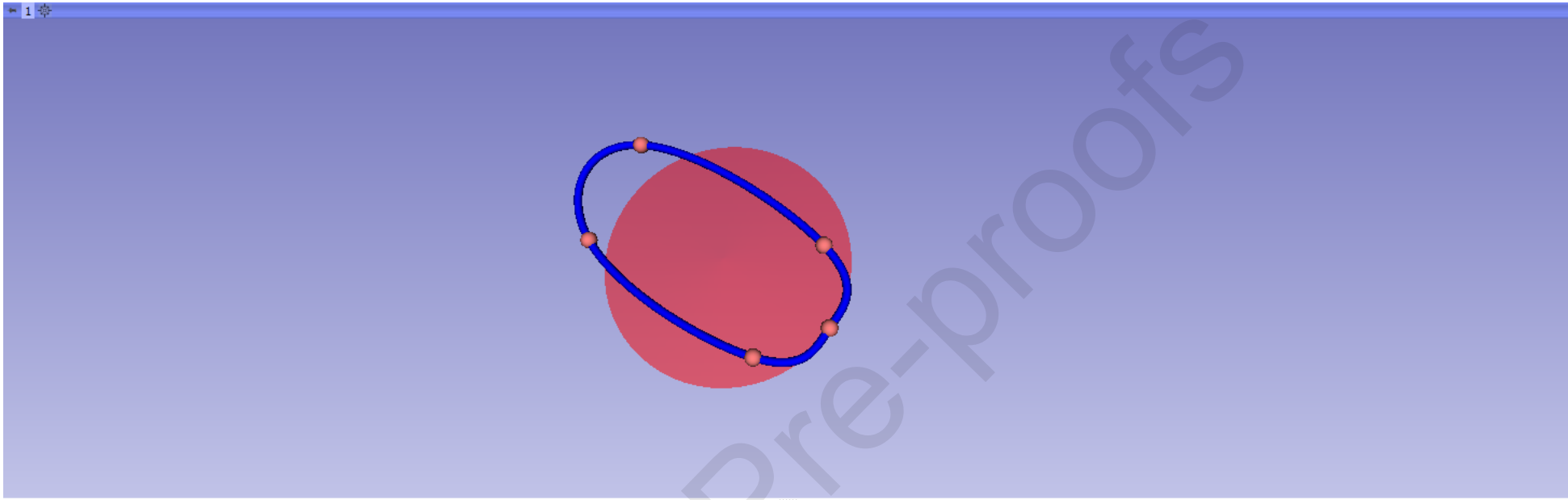


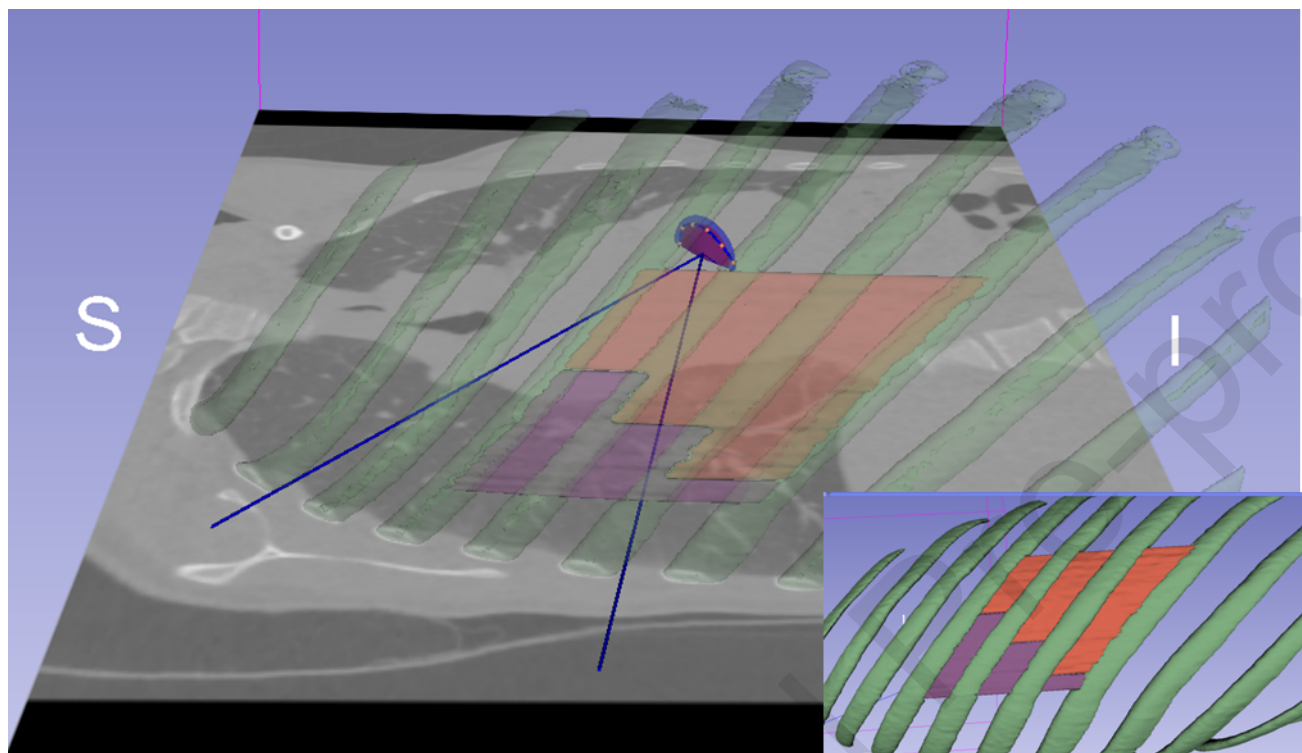
R 104.291mm

Y 64.704mm

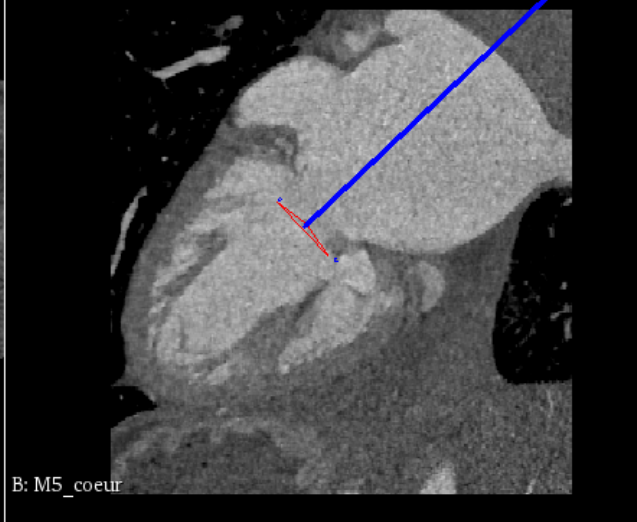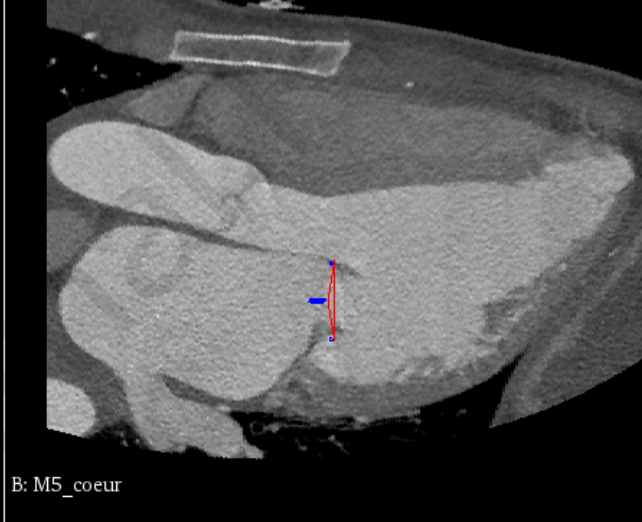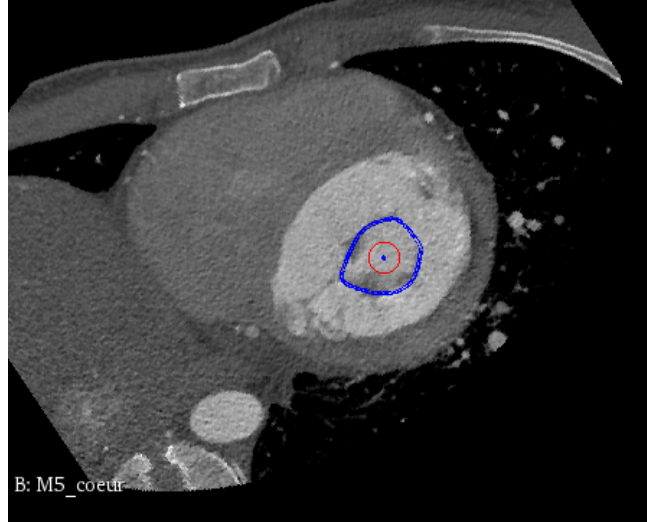
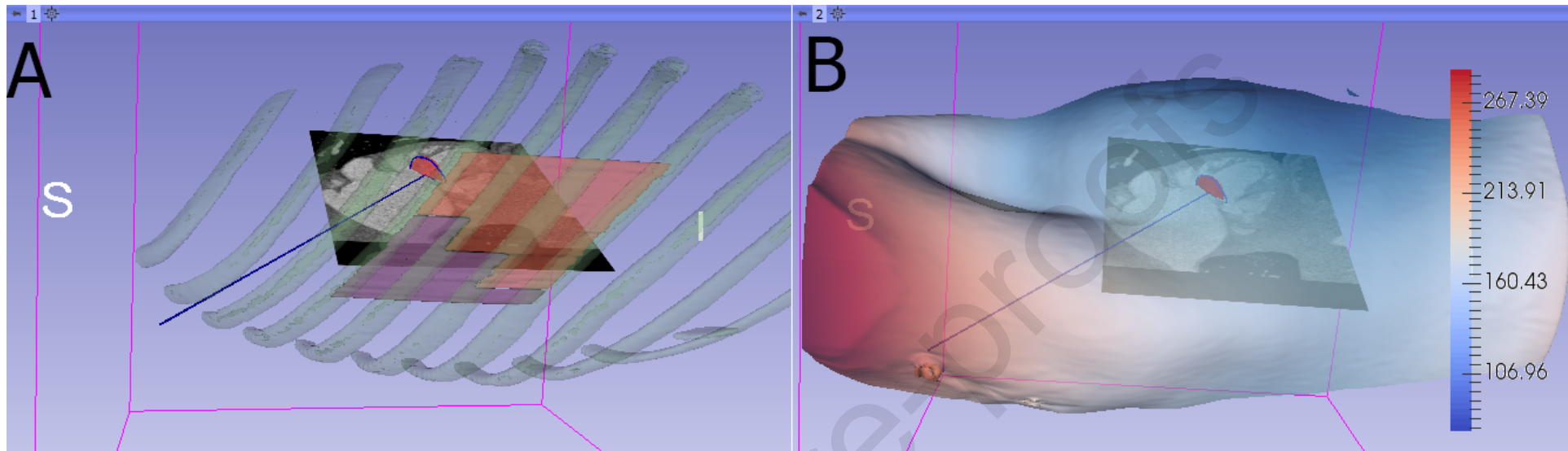
G 37.449mm

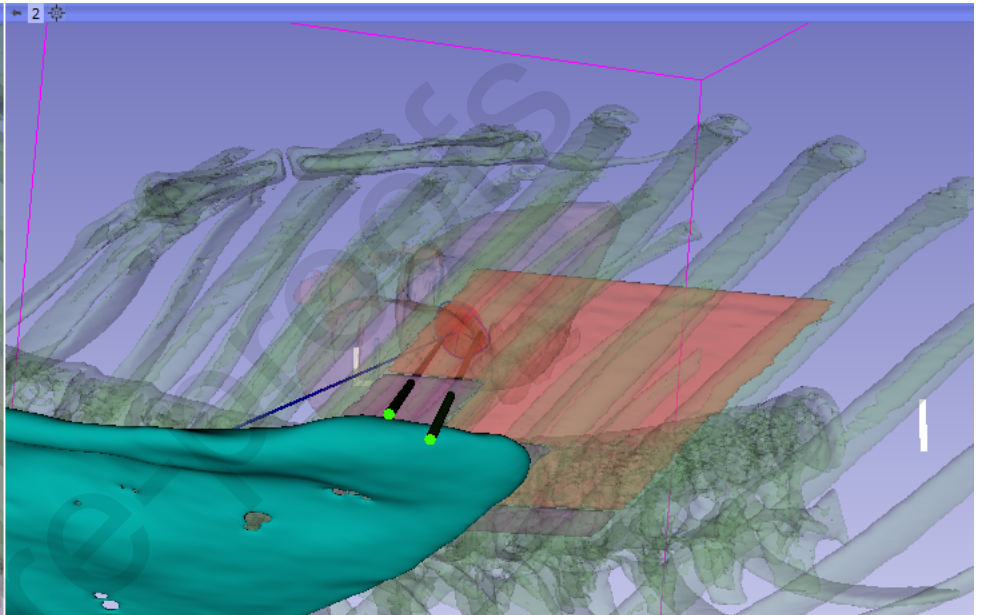
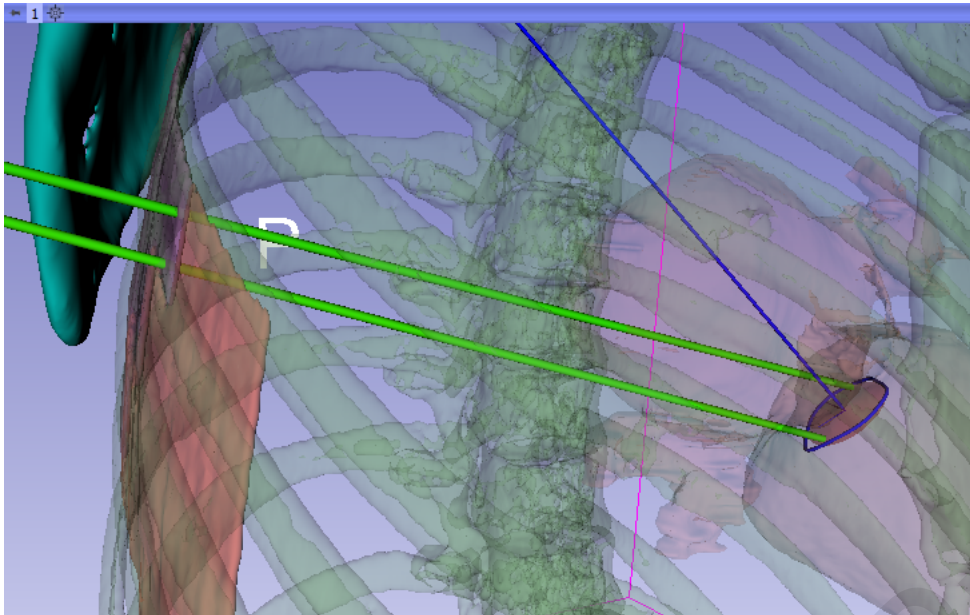






Journal Pre-proofs





R 120.158mm

Y 59.180mm

G 34.433mm

