



HAL
open science

Myocarditis in Athletes Is a Challenge: Diagnosis, Risk Stratification, and Uncertainties

Christian Eichhorn, Loïc Bière, Frédéric Schnell, Christian Schmied, Matthias Wilhelm, Raymond Kwong, Christoph Gräni

► To cite this version:

Christian Eichhorn, Loïc Bière, Frédéric Schnell, Christian Schmied, Matthias Wilhelm, et al.. Myocarditis in Athletes Is a Challenge: Diagnosis, Risk Stratification, and Uncertainties. *JACC: Cardiovascular Imaging*, 2020, 13 (Issue 2 Part 1), pp.494-507. 10.1016/j.jcmg.2019.01.039 . hal-02473901

HAL Id: hal-02473901

<https://univ-rennes.hal.science/hal-02473901v1>

Submitted on 17 Feb 2020

HAL is a multi-disciplinary open access archive for the deposit and dissemination of scientific research documents, whether they are published or not. The documents may come from teaching and research institutions in France or abroad, or from public or private research centers.

L'archive ouverte pluridisciplinaire **HAL**, est destinée au dépôt et à la diffusion de documents scientifiques de niveau recherche, publiés ou non, émanant des établissements d'enseignement et de recherche français ou étrangers, des laboratoires publics ou privés.

Myocarditis in athletes is a challenge – diagnosis, risk stratification and uncertainties

Christian Eichhorn, BSc¹, Loïc Bière, MD, PhD^{1,2}, Frédéric Schnell, MD, PhD³, Christian Schmied, MD⁴, Matthias Wilhelm, MD⁵, Raymond Y. Kwong, MD, MPH¹, Christoph Gräni, MD, PhD^{1,5,6}

1 Noninvasive Cardiovascular Imaging Section, Cardiovascular Division, Department of Medicine, Brigham and Womens Hospital, Harvard Medical School, Boston, USA

2 Institut MitoVasc, Laboratoire Cardioprotection, Remodelage et Thrombose, University of Angers, Angers, France; Department of Cardiology, University Hospital of Angers, Angers, France

3 Rennes University Health Centre, Sports Medicine Division; Physiology Laboratories, Rennes-1 University, Rennes, France

4 Department of Cardiology, University Heart Center, Zurich, Switzerland.

5 Department of Cardiology, Swiss Cardiovascular Center, University Hospital Berne, Berne, Switzerland

6 Cardiac Imaging, Department of Nuclear Medicine, University Hospital Zurich, Zurich, Switzerland

Corresponding Author:

Christoph Gräni, MD, PhD

Department of Cardiology, Cardiac Imaging

Swiss Cardiovascular Center

University Hospital Berne

Freiburgstrasse

CH - 3010 Berne, Switzerland

Tel: +41 31 632 45 08

Email: christoph.graeni@insel.ch

Brief title: CMR Myocarditis in athletes

Word count: 7459

Disclosures: None

Abstract

Presentation of myocarditis in athletes is heterogeneous and establishing the diagnosis is challenging with no current uniform clinical gold-standard. The combined information from symptoms, electrocardiography, laboratory testing, echocardiography, cardiac magnetic resonance imaging (CMR), and in certain cases endomyocardial biopsy (EMB) helps to establish the diagnosis. Most patients with myocarditis recover spontaneously; however, athletes may be at higher risk of adverse cardiac events. Based on scarce evidence and mainly autopsy studies and expert's opinions, current recommendations generally advise abstinence from competitive sports ranging from 3 to 6 months. However, the dilemma poses that (un-) necessary prolonged disqualification of athletes in order to avoid adverse cardiac events, can cause considerable disruption to training schedules and tournament preparation, and leading to a decline in performance and ability to compete. Therefore, better risk stratification tools are needed. Using latest available data, this review contrasts existing recommendations and presents a new proposed diagnostic flowchart putting a greater focus on the use of CMR imaging in athletes with suspected myocarditis. This may enable cardiac caregivers to risk stratify athletes with suspected myocarditis more systematically, and furthermore allow for pooling of more unified data. To modify recommendations regarding sports behavior in athletes with myocarditis, more evidence, based on large multicenter registries including CMR and EMB, is needed. In the future, physicians might rely on combined novel risk stratification methods, by implementing both noninvasive- and invasive tissue characterization methods.

Key words:

Myocarditis; Infection; Athletes; Sports; Recreational; Competitive, Sports Restriction; Cardiac Magnetic Resonance Imaging; Risk Stratification

Abbreviations:

BNP = Brain Natriuretic Peptide
CAD = Coronary Artery Disease
CMR = Cardiac Magnetic Resonance Imaging
ECG = Electrocardiography
ECV = Extracellular Volume Fraction
EMB = Endomyocardial Biopsy
LGE = Late Gadolinium Enhancement
LLC = Lake Louise Criteria
LVEF = Left Ventricular Ejection Fraction
MACE = Major Adverse Cardiovascular Events
RV = Right Ventricular
RVEF = Right Ventricular Ejection Fraction
SCD = Sudden Cardiac Death
TTE = Transthoracic Echocardiography

Introduction

Myocarditis is an underlying cause of sudden cardiac death (SCD) in young athletes (1-3). While the beneficial effects of exercise on both cardiovascular and general health are irrefutable, some evidence has emerged showing that excessive levels of exercise in the presence of an infection and particularly in myocarditis can be harmful (2,4). Current recommendations state that after a case of myocarditis abstinence from competitive sports lasting between 3 to 6 months is generally recommended; this, however, can be extended to up to 1 year and is based on scarce evidence, mainly autopsy studies and experts' opinions (5-7). However, prolonged disqualification of athletes is disruptive to athletic conditioning, which may lead to performance drop and inability to compete. In order to avoid adverse cardiac events and better risk stratify athletes with myocarditis, prognostic information may be gained from the application of using cardiac magnetic resonance imaging (CMR) (8). This review presents a new proposed diagnostic flowchart (Central Illustration) based on recent evidence and existing recommendations, which integrates the use of CMR imaging for diagnosing and risk stratification of athletes with suspected myocarditis.

Myocarditis in Athletes

In post-mortem studies of athletes who died from SCD, myocarditis was diagnosed in up to 8% (9,10). This represents the third most common cause after autopsy-negative sudden unexplained death and coronary artery anomalies (1). It is uncertain if physical activity is truly necessary to trigger malignant arrhythmias as the majority of SCD, especially due to myocarditis, did not occur during or immediately after exercise but at rest (1,11).

Viral infections, namely with enterovirus, Coxsackie B, Parvovirus B19 and Human Herpes Virus 6 are the most common responsible infectious pathogens in myocarditis (12,13). Initially,

these pathogens directly affect the myocardium, followed by autoimmune myocardial injury, which ultimately results in myocardial remodeling potentially leading to dilated cardiomyopathy. Another factor that determines the underlying causative pathogen may be governed by the type of sports performed. For example, cross-country runners have greater exposure to tick-bite-transmitted infections (*Borrelia Burgdorferi*). Myocarditis can also be caused by a great variety of medical drugs as well vasculitic or toxic causes (14), underlining the attention of considering co-morbidities in athletes. In general, non-infectious causes of myocarditis are rare in athletes but can include illicit drugs (15), illustrating the importance of lifestyle history in athletes.

Pathogenesis and Contributing Effect of Strenuous Exercise

The general hypothesis is that moderate exercise, which does not comprise of a common definition amongst studies of runners, is protective. However, more intense endurance training, typically that for a marathon may increase the likelihood of a systemic inflammatory response and susceptibility to viral upper respiratory tract infections (16). As a result, acute myocarditis can ensue and lead to an interaction between an environmental trigger and the host's immune system, leading to three phases of disease progression: acute viral, subacute immune and chronic phase, with 12 - 25% developing dilated cardiomyopathy (17). While the viral phase is often short-lived and not clinically detected, pathogens may reach the myocardium and affect it through direct myocyte injury as well as through activation of the innate immune system; this results in subacute and chronic inflammation, which leads to myocyte necrosis, fibrosis and ultimately adverse cardiac remodeling (17), pre-disposing an individual to arrhythmias. Exercise, particularly under extreme physical exertion, is associated with a higher propensity to arrhythmogenicity (18), which murine studies have shown to be due to an intensified inflammatory response in subjects exposed to extreme physical exertion (18,19). Even after the

myocardium has recovered after an episode of myocarditis, the chronic myocardial inflammatory process secondary to pathogenic autoimmunity may persist, where cytokines carry on to exert pro-arrhythmic effects and trigger circuit activity (20). Therefore, athletes with a history of myocarditis, or in certain cases even just a minor infection, may pose an increased risk for adverse cardiac events if physical exercise is continued.

Clinical Presentations and the Use of Biomarkers, Viral Serology, Electrocardiogram and Transthoracic Echocardiography

Myocarditis presents a challenging clinical scenario given its heterogeneous presentation. The suspicion of myocarditis may be raised when athletes complain of chest pain or indeed any other cardiac symptom in the context of general malaise with abnormal biomarkers, ECG or transthoracic echocardiogram (TTE) changes. This particularly affects those individuals who present with new onset left ventricular (LV) dysfunction after viral infection or prodromal symptoms in recent weeks. One must be aware that signs of myocarditis may resemble those of physiological changes in the athlete's heart (Table 1).

Biomarker and Viral Serology

Other than an increase in troponin, there are no other specific biomarkers indicative of myocardial injury due to myocarditis. Evidence for viral serology has not proved sufficient as shown by a prospective study by Mahfoud et al., which determined the sensitivity and specificity of virus serology to be 9% and 77% respectively. Only 5 out of 124 patients were shown to have viral serology consistent with the virus that was detected upon EMB (21). Where there is clinical suspicion or high risk, testing for hepatitis C, human immunodeficiency virus, Lyme disease or rickettsia is warranted. A recent study characterizing the causes of raised troponin in those 50 years or less including 6081 patients showed that myocarditis was the second most common

cause of raised troponins after myocardial infarction (22), further underlining the importance of myocarditis as a diagnosis especially in young and middle-aged patients. A meta-analysis including thirty-three studies with a total of 1045 athletes, mainly participating in endurance sports ranging from short runs to ultra-marathons showed that cardiac troponin was elevated above the 99th percentile in up to 83% of individuals following prolonged exercise (23). However, the troponin release tends to be less prominent and monophasic rather than biphasic and resolves faster than in myocardial injury as caused by myocarditis or acute coronary syndrome. Therefore, in the absence of an acute coronary syndrome, a judgement on the nature of the myocardial insult should consider the prominence of the rise in troponin, the timeframe of a high troponin level and the time elapsed since endurance exercise. Nevertheless, a recent study by Berg et al. has concluded that absolute baseline levels of cardiac enzymes and inflammatory biomarkers do not sufficiently represent the level of Late-Gadolinium Enhancement (LGE) by CMR in myocarditis. Further, it does not predict change in LGE at 3 months follow-up and does not correlate with improved LGE when a decrease in cardiac enzymes and inflammatory biomarkers is observed (24). Based on their findings, they concluded that it was not sufficient to simply use clinical findings, cardiac enzymes and inflammatory markers to monitor myocarditis and that CMR adds important additional information to current diagnostic techniques.

Electrocardiogram

Patients with myocarditis may present with unspecific ST-elevations, PQ-depression, QTc prolongation or T-wave inversion, which, in some cases, might be difficult to distinguish from normal variants in healthy athletes (Table 1) (25,26). In our recent report looking at the prognostic value of CMR tissue characterization in risk stratifying patients with suspected

myocarditis, only 42% of the 670 suspected myocarditis patients showed abnormal ECGs, with no significant difference between those where LGE was present and absent (8).

Transthoracic Echocardiography

Generally, the heart of trained athletes can present with various structural changes depending on the dynamic component of the type of exercise performed (27) – endurance training, such as that for a marathon, increases isotonic load on working muscles that can lead to increased LV dimensions, while high isometric load on working muscles, such as in weight lifting, can result in increased LV wall thickness. To what degree different types of exercise involve dynamic and static components has been further described by Mitchell et al. (28) and may help physicians to counsel athletes with cardiovascular abnormalities in regards to particular types of competitive exercise. Compared to healthy athletes, in a case of myocarditis, there are no specific features in TTE. Myocarditis can resemble dilated, hypertrophic, or restrictive cardiomyopathy with local wall motion abnormalities and/or pericardial effusion (29). Nonetheless, TTE can be of prognostic value in fulminant myocarditis, which presents with normal chamber size and severe impaired systolic left ventricular ejection fraction (LVEF) (30). It has been shown that regional wall motion abnormalities following myocarditis in athletes can be exacerbated by exercise in contrast to normal-/depressed LVEF among healthy athletes, which normalizes during exercise (31). TTE is therefore an important and feasible tool to fully assess LV function and wall motions at presentation and at follow-up. The LV remodeling index was identified to differentiate athletes from patients presenting with dilated and hypertrophic cardiomyopathy (32). However, TTE cannot always help to differentiate athlete's heart from other pathological structural or functional changes and in those cases CMR may be indicated as it also helps to identify further diagnostic information beyond geometric measures (33).

Invasive Coronary Angiography and Endomyocardial Biopsy

Generally, coronary artery disease (CAD) should be ruled out first using invasive or noninvasive imaging or a clinically low-pretest probability for CAD in individuals presenting with suspected myocarditis. If at the time of CMR scanning, no signs of active inflammation on T2-weighted imaging or T2 mapping is present, clinicians could consider performing CMR stress-perfusion to rule out ischemia. In this setting, CMR may further help to differentiate between an ischemic event with its typical pattern of endocardial LGE presence in coronary vessel distribution territory versus epicardial LGE in myocarditis (e.g. in athletes with low pre-test probability and no indication for invasive coronary angiography). Concerning the use of endomyocardial biopsy (EMB), European and American recommendations differ slightly (Table 2). EMB is an invasive diagnostic test with high specificity and complication rates as low as <1% in experienced centers (34,35). EMB can differentiate between different types of inflammation (infectious, autoimmune, idiopathic) causative of myocarditis and may therefore guide treatment and prognosis. This is particularly recommended in life-threatening presentations or unexplained reduced systolic LV function (14). However, it lacks sensitivity and exhibits high false negative results (sampling error). To avoid focal sampling error, EMB is preferably performed soon after presentation and multiple samples of sufficient size (1 – 2 mm) should be taken from both ventricles (35,36). Additionally, diagnosis by EMB can be improved by analyzing the viral genome through DNA-RNA extraction and RT-PCR amplification (37). This has the advantage of knowing exactly which pathogen is causing disease as different viruses have different effects on myocardial and vascular tissue and affect different areas of the myocardium, which in turn may affect presenting signs and symptoms as well as ECG. Historically, it has not been clear whether CMR helps in guiding biopsy and improving

sensitivity/specificity of EMB (35,38). A study by Baccouche et al. suggests a diagnostic synergy in using both CMR and EMB as complementary diagnostic tools in troponin-positive patients without CAD, identifying 78/82 myocarditis patients (95%) when applied together, which was superior to both CMR and EMB when applied individually (39). Recent evidence of real-time CMR-guided EMB in a porcine pre-clinical in-vivo model suggest that CMR-guidance of EMB may significantly improve sensitivity and specificity of EMB (40). However, whether EMB would help to earlier risk stratify athletes with regard to sports abstinence counseling is unknown. Therefore, performing EMB generally has the greatest potential benefit in cases where CMR cannot confirm a diagnosis of myocarditis or in cases with unclear depressed LVEF (Central Illustration).

Cardiac Magnetic Resonance Imaging

CMR plays a major role in evaluating the etiology of chest pain syndromes and suspected myocarditis but recommendations about the exact role of CMR in diagnosis and follow-up of myocarditis (Table 2) (41) are outdated due to new data and improvements in imaging technique. CMR has evolved as the primary noninvasive diagnostic modality in suspected myocarditis cases, with particularly high sensitivity (81%), specificity (71%) and diagnostic accuracy (79%) in acute myocarditis (42), given several technical advantages. Beyond the assessment of wall motion and LVEF, CMR is a noninvasive modality that allows tissue characterization with visualization of myocardial edema and fibrosis (43).

The Lake Louise Criteria (LLC) (44) utilized in the diagnosis of suspected myocarditis combine different CMR techniques to detect intramyocardial edema by T2-weighted imaging, fibrosis by LGE, typically in a non-ischaemic distribution, as well as hyperemia by myocardial early gadolinium enhancement (EGE). A certain number of patients with biopsy proven

myocarditis have no LGE and do not fulfil the LLC (35,45); reasons for this may include that active myocarditis may not always lead to regions of necrotic myocytes that are large enough to be detected by CMR. Moreover, the optimal time point after onset of symptoms for a CMR scan has not yet been determined yet and (too) early CMR scanning may yield false negative findings which necessitate repeat scanning (Central Illustration).

CMR may detect isolated myocarditis-like LGE on CMR in an athlete with non-acute symptoms (e.g. syncope, or palpitations without any clinical signs of acute myocarditis).

Whether these findings represent an acute myocarditis, a myocarditis in a late stage without presence of myocardial edema, a resolved myocarditis or another pathology can be challenging (see Figure 2), however, CMR can be considered the most suitable noninvasive modality for differentiation of different underlying cardiac causes.

T2 weighted imaging, T1 - and T2 mapping techniques

LLC are now often complemented by novel CMR techniques such as native T1 and T2 mapping as well as extracellular volume fraction (ECV) measurement to provide a higher sensitivity and specificity (46,47). Native T1 mapping values are affected by both edema and extracellular expansion and is therefore able to detect myocarditis at various stages, whereas T2 mapping evaluates free water content that is normally present in the acute phase of myocarditis and then gradually normalizes over months - this is relevant for cardiac caregivers evaluating the course of myocarditis as it is the only technique that can adequately discriminate between myocarditis and noninflammatory cardiomyopathies in patients with symptoms lasting longer than 2 weeks (48,49). A recent meta-analysis by Pan et al. (48) comparing the diagnostic performance of ECV, native T1 mapping and T2 mapping versus LLC for detection of acute myocarditis including 17 studies and 1308 subjects, has shown that only native T1 mapping had

significantly better sensitivity than LLC, while other parameters had comparable diagnostic performance to LLC and provided distinct advantages for evaluating myocarditis. The meta-analysis shows that LLC have been firmly established in clinical practice and that the use of native of T1 mapping can further enhance CMR accuracy in diagnosing myocarditis. These findings are supported by another meta-analysis including 22 studies by Kotanidis et al. (50), which similarly concludes that native T1 mapping has a significantly higher diagnostic accuracy compared to all other index tests: native T1 mapping showed an area under the curve (AUC) of 0.95 compared to T2 mapping with an AUC of 0.88 and LLC of 0.81 and will therefore likely be implemented in the upcoming updated Lake Louise Criteria. Additionally, the authors showed that T2 mapping was superior to T2-weighted and EGE imaging, suggesting that both EGE and T2-weighted imaging could be replaced by T1 - and T2 mapping respectively (50). The role of ECV is less clear at this stage. In our subset analysis, ECV showed a significant association with major adverse cardiovascular events (MACE) and death and may therefore be of additional benefit in a routine CMR for risk stratification in suspected myocarditis (8).

However, due to its novelty, it is important that further studies on the inherent characteristics of T1 mapping will be performed. As T1- and T2 mapping values are vendor and site specific, standardization of these mapping techniques and understanding how confounding factors will influence them in real-life clinical practice outside of the research setting is needed (51).

Furthermore, native T1 prolongation becomes less specific to myocarditis over time as early inflammation is replaced by fibrotic tissue, which, in patients with chronic symptoms, can be due multiple cardiac pathologies. To truly implement changes to diagnostic criteria, head-to-head comparisons performed at multiple centres would be desirable (52).

In our own sub-group analysis, T2 weighted imaging has demonstrated a significant association with MACE (8). Other studies were not able to show this predictive value, possibly due to the low patient number and the fact that T2 weighted imaging is prone to artefacts. Our study is supported by the study of Spieker et al. who could show that myocardial edema detected with T2 mapping has prognostic value in patients with myocarditis. Furthermore, it seems that T2 mapping is more robust and less prone to artefact compared to T2 weighted imaging and may be the better sequence for edema assessment in patients with suspected myocarditis (53,54).

Late Gadolinium Enhancement

Whether any LGE presence in athletes may be the substrate for ventricular tachycardia (e.g. from previous myocarditis or other causes) is unknown (55,56). Studies have reported a high rate of coincidentally detected LGE in athletes (55-57). In two recent series, which included athletes who had undergone CMR because of abnormal screening (ECG changes or ventricular arrhythmias) first line examination but structurally normal hearts on echocardiographic imaging, a high rate of cardiac events during follow-up was reported in those with large areas of sub-epicardial LGE (58,59). Although these athletes had no definite history of myocarditis, the authors hypothesise that due to the typical non-ischemic epicardial pattern of LGE a silent myocarditis is most probably the underlying cause. Although rather untypical, other causes like arrhythmogenic right ventricular cardiomyopathy (ARVC) with mainly left heart involvement are not completely excluded, however, it is generally more likely that myocarditis mimics an ARVC than vice versa (60). Furthermore, in the acute stage differential diagnosis of myocarditis and ARVC does not change the sports recommendation, but does change diagnostic downstream testing. The mentioned studies highlight the fact that subepicardial fibrosis may otherwise not have been detected by echocardiography alone and that CMR plays an important role especially

in athletes with ventricular arrhythmias. These findings support the argument to use CMR early for risk stratifying athletes with suspected myocarditis, which, when LGE is present, most commonly presents with subepicardial LGE (8,61). Our group had recently shown that in 670 patients with suspected myocarditis with a median follow-up of 4.7 years, CMR is not only a powerful diagnostic but also a prognostic tool (8). In fact, patients with suspected myocarditis and presence of LGE (n = 296, 44%) showed a doubled risk for MACE at follow-up. Regarding location and pattern, septal and mid-wall LGE demonstrated strongest significant associations with MACE (Hazard Ratio of 2.6 and 2.4). A patchy distribution portended to a near 3-fold increased hazards to MACE and LGE extent (increase by 10%) corresponded to a near eighty percent increase in risk of MACE. The Italian Multicenter study on Acute Myocarditis (ITAMY), which included 374 patients with acute myocarditis and preserved LVEF, similarly concluded that in these patients LGE in the mid-wall layer of the anteroseptal myocardial segment is associated with a worse prognosis (61). Mahrholdt et al. found that varying patterns of LGE are associated with different viruses; parvovirus B19 was associated with inferolateral LGE, while anteroseptal LGE was associated with either human herpesvirus 6 or the combined presence of the two viruses (62). On the contrary, a normal CMR study corresponded to low annual MACE and death rates of 0.8% and 0.3% respectively in our study (8), and no events were recorded in the ITAMY study (61). Alluding to the diagnostic usefulness and common application of CMR, our study showed that only 57 (9%) of patients underwent EMB with mostly unspecific results, which is consistent with other studies (44,63,64), while the ITAMY study (61) solely relied on LLC for diagnosis of acute myocarditis in 95% of cases. The prognostic power of LGE presence on CMR in suspected myocarditis is similarly shown by both our study (8) and the ITAMY study (61). It is to note that our study shows lower event rates as

we did not select patients who have already been diagnosed with acute myocarditis according to LLC; rather we chose a more real-life clinical setting, where low-risk patients are more likely to be included in the patient population; additionally, ITAMY and our study showed slight differences in MACE criteria.

Another important risk factor that will require further studies evaluating its prognostic strength is LV remodeling. Recently, Filippetti et al. (65) showed that not only the lack of LGE but also of any adverse LV remodeling at mid-term control scanning resulted in better outcomes in acute myocarditis.

CMR used as a diagnostic and risk stratification tool can help to identify how physicians should approach treatment of an athlete with current or recent infection and suspected myocarditis, what to recommend regarding disqualification from exercise and may help to fill apparent evidence gaps (Central Illustration). Assuming that cardiac centres have sufficient CMR experience and image quality is adequate, CMR can act as a gatekeeper in the diagnosis of myocarditis and a revised diagnostic algorithm that incorporates CMR in a uniform fashion will help to create necessary outcome data. While athletes with LGE presence may need to undergo CMR follow-up, absence of LGE on CMR scanning in athletes with suspected myocarditis could be interpreted as 'low-risk' and they might get allowed to go back to exercise after clinically resolved inflammation (66).

Therapy

In most cases, myocarditis is a benign pathology and resolves favorably. Currently, no randomized controlled trials for optimal therapy exist. Current recommendations (14) endorse heart failure medication as supportive therapy for LV dysfunction in myocarditis. Beta-blockade improves LVEF and reduces hospitalization while increasing survival; carvedilol has been

shown to exert cardioprotective effects (67), while metoprolol may play a role in increased inflammation (68). Non-steroidal anti-inflammatory agents are generally only advisable in patients with peri-/myocarditis with normal LVEF and chest pain (69). The use of immunosuppression with a combination of cortisol and azathioprine for 6 months has shown benefits in a single-centre study when there is no viral persistence (70). However, current recommendations do not include these immunomodulatory therapies. Of note, immunosuppression may be useful and improve outcome in patients with a particular form of myocarditis, a giant cell myocarditis (71). Beside heart failure therapy, supportive arrhythmia management is recommended. Specific recommendations for arrhythmias as well as intracardiac defibrillator implantation in myocarditis do not exist and hence, management should be in concordance with current arrhythmia guidelines. Wearable life-vests (72) may play a future role in athletes, who may want to try getting back into some low intensity exercise at an earlier stage, even at an increased risk of SCD since the effect of adverse remodeling will not be mitigated (if the physical aspects of the type of sports allow it, e.g. spinning).

Follow-up and sports restriction

First and foremost, athletes with acute myocarditis need to refrain from physical exercise, especially from competitive sports. Based on the most recent scientific statement from the AHA/ACC, it is recommended that athletes with probable or definite diagnosis of myocarditis should not participate in competitive sports while active inflammation is present (Class III, Level of evidence C) (Table 3), signs of which are most easily detected using CMR (e.g. T2-weighted imaging for edema). This recommendation applies across patient age groups, genders and left ventricular functions. Before returning to competitive sports, athletes should undergo an echocardiography, Holter monitoring – preferentially before and during a work-out, and an

exercise ECG no less than 3 - 6 months after initial illness (Class I, Level of Evidence C). There is currently no evidence available on the 'safe' level of exercise in the 3 - 6 months "competitive sports abstinence" period in athletes with myocarditis. High intensity training would be rather categorized as competitive sports and should not be recommended (see case presentation in Figure 1) during this period. Yet, the role of moderate or isometric exercise is still unclear. It is an individual case by case decision and according to the "Exercise in heart failure" consensus document (73) moderate exercise at 50% VO₂peak or 60% from their maximum predicted heart rate is recommended and may also be translated to myocarditis patients. However, clinical and laboratory absence of inflammation and absence of arrhythmias are a requirement to return to any exercise levels. Other missing gaps include whether different levels of 'severity' of myocarditis or locations, patterns and size of LGE require different lengths of sports abstinence and whether serial CMR scans are needed to guide therapy and recommendation regarding sports behavior. Furthermore, to what extent genetic predisposition determines disease progression and how clinical examination, biomarkers, ECG and EMB can help to anticipate adverse outcomes is still unclear.

CMR has the added advantage to unveil possible acute myocarditis by identifying myocardial edema even in absence of LGE. In order to avoid adverse cardiac events, this may allow clinicians to make conservative recommendations regarding returning to exercise until inflammation is resolved of the myocardium in the follow-up CMR (see Central Illustration). In a small study evaluating 28 myocarditis patients (non-athletes), patients with decreasing LGE at follow-up had a lower event rate compared to those with greater amount of LGE (74). However, at present it remains unresolved if resolution of myocarditis-related LGE should be a requirement prior to returning to competitive sports (5).

Recommendations should be applied not only to competitive athletes but also to those participating in recreational sports. Two studies showed that most myocarditis related SCD most frequently occurs in recreational athletes (75,76). Current European recommendations reflect this in that they generally recommend no competitive sports for those diagnosed with myocarditis (6), while also extending this to recreational and amateur sports activities (7,14); clinical assessment in the absence of abnormal LVEF and arrhythmias is necessary prior to resuming competitive sports. CMR features such as T2-weighted imaging, LGE and T1/T2 mapping with regard to sports behavior recommendations are currently not included. Further research will be needed in order to assess how this novel mapping techniques can help treating physicians to counsel athletes with myocarditis.

Conclusion

Information leading to sports restriction recommendations in athletes with myocarditis are mainly based on autopsy studies, animal models and experts' opinions. Recent evidence showed that CMR as a non-invasive imaging tool plays an important role in the risk stratification of patients with suspected myocarditis. To modify recommendations regarding sport behavior in physically active individuals with myocarditis, more evidence, based on large multicenter registries including CMR and immunochemistry EMB, is needed. Physicians might rely in the future on combined novel risk stratification methods, which will be likely improved by implementing both noninvasive- and invasive tissue characterization methods using CMR and EMB.

References

1. Harmon KG, Asif IM, Maleszewski JJ et al. Incidence, Cause, and Comparative Frequency of Sudden Cardiac Death in National Collegiate Athletic Association Athletes: A Decade in Review. *Circulation* 2015;132:10-9.
2. Corrado D, Basso C, Pavei A, Michieli P, Schiavon M, Thiene G. Trends in sudden cardiovascular death in young competitive athletes after implementation of a preparticipation screening program. *Jama* 2006;296:1593-601.
3. Maron BJ, Doerer JJ, Haas TS, Tierney DM, Mueller FO. Sudden deaths in young competitive athletes: analysis of 1866 deaths in the United States, 1980-2006. *Circulation* 2009;119:1085-92.
4. Corrado D, Basso C, Rizzoli G, Schiavon M, Thiene G. Does sports activity enhance the risk of sudden death in adolescents and young adults? *Journal of the American College of Cardiology* 2003;42:1959-1963.
5. Maron BJ, Udelson JE, Bonow RO et al. Eligibility and Disqualification Recommendations for Competitive Athletes With Cardiovascular Abnormalities: Task Force 3: Hypertrophic Cardiomyopathy, Arrhythmogenic Right Ventricular Cardiomyopathy and Other Cardiomyopathies, and Myocarditis. *Circulation* 2015;132:e273-e280.
6. Pelliccia A, Fagard R, Bjørnstad HH et al. Recommendations for competitive sports participation in athletes with cardiovascular diseaseA consensus document from the Study Group of Sports Cardiology of the Working Group of Cardiac Rehabilitation and Exercise Physiology and the Working Group of Myocardial and Pericardial Diseases of the European Society of Cardiology. *European heart journal* 2005;26:1422-1445.

7. Pelliccia A, Corrado D, Bjørnstad HH et al. Recommendations for participation in competitive sport and leisure-time physical activity in individuals with cardiomyopathies, myocarditis and pericarditis. *European Journal of Cardiovascular Prevention & Rehabilitation* 2006;13:876-885.
8. Grani C, Eichhorn C, Biere L et al. Prognostic Value of Cardiac Magnetic Resonance Tissue Characterization in Risk Stratifying Patients With Suspected Myocarditis. *J Am Coll Cardiol* 2017;70:1964-1976.
9. Vassalini M, Verzeletti A, Restori M, De Ferrari F. An autopsy study of sudden cardiac death in persons aged 1-40 years in Brescia (Italy). *J Cardiovasc Med (Hagerstown)* 2016;17:446-53.
10. Harmon KG, Drezner JA, Maleszewski JJ et al. Pathogenesis of sudden cardiac death in national collegiate athletic association athletes. *Circ Arrhythm Electrophysiol* 2014;7:198-204.
11. Phillips M, Robinowitz M, Higgins JR, Boran KJ, Reed T, Virmani R. Sudden cardiac death in Air Force recruits: a 20-year review. *Jama* 1986;256:2696-2699.
12. Yilmaz A, Klingel K, Kandolf R, Sechtem U. A geographical mystery: do cardiotropic viruses respect national borders? *J Am Coll Cardiol*. United States, 2008;82; author reply 82-3.
13. Breinholt JP, Moulik M, Dreyer WJ et al. Viral epidemiologic shift in inflammatory heart disease: the increasing involvement of parvovirus B19 in the myocardium of pediatric cardiac transplant patients. *J Heart Lung Transplant* 2010;29:739-46.
14. Caforio AL, Pankuweit S, Arbustini E et al. Current state of knowledge on aetiology, diagnosis, management, and therapy of myocarditis: a position statement of the European

- Society of Cardiology Working Group on Myocardial and Pericardial Diseases. *Eur Heart J* 2013;34:2636-48, 2648a-2648d.
15. Pilgrim JL, Woodford N, Drummer OH. Cocaine in sudden and unexpected death: a review of 49 post-mortem cases. *Forensic Sci Int* 2013;227:52-9.
 16. Martin SA, Pence BD, Woods JA. Exercise and Respiratory Tract Viral Infections. *Exerc Sport Sci Rev* 2009;37:157-64.
 17. Sagar S, Liu PP, Cooper LT. Myocarditis. *The Lancet* 2012;379:738-747.
 18. Mont L, Elosua R, Brugada J. Endurance sport practice as a risk factor for atrial fibrillation and atrial flutter. *Europace* 2009;11:11-7.
 19. Aschar-Sobbi R, Izaddoustdar F, Korogyi AS et al. Increased atrial arrhythmia susceptibility induced by intense endurance exercise in mice requires TNFalpha. *Nat Commun* 2015;6:6018.
 20. Saito J, Niwano S, Niwano H et al. Electrical remodeling of the ventricular myocardium in myocarditis. *Circulation journal* 2002;66:97-103.
 21. Mahfoud F, Gartner B, Kindermann M et al. Virus serology in patients with suspected myocarditis: utility or futility? *Eur Heart J* 2011;32:897-903.
 22. Wu C, Singh A, Collins B et al. Causes of Troponin Elevation and Associated Mortality in Young Patients. *Am J Med* 2018;131:284-292.e1.
 23. Sedaghat-Hamedani F, Kayvanpour E, Frankenstein L et al. Biomarker changes after strenuous exercise can mimic pulmonary embolism and cardiac injury--a metaanalysis of 45 studies. *Clin Chem* 2015;61:1246-55.
 24. Berg J, Kottwitz J, Baltensperger N et al. Cardiac Magnetic Resonance Imaging in Myocarditis Reveals Persistent Disease Activity Despite Normalization of Cardiac

- Enzymes and Inflammatory Parameters at 3-Month Follow-Up. *Circ Heart Fail* 2017;10:e004262.
25. Schnell F, Riding N, O'Hanlon R et al. Recognition and significance of pathological T-wave inversions in athletes. *Circulation* 2015;131:165-73.
 26. Malhotra A, Dhutia H, Gati S et al. Anterior T-Wave Inversion in Young White Athletes and Nonathletes: Prevalence and Significance. *J Am Coll Cardiol* 2017;69:1-9.
 27. Morganroth J, Maron BJ, Henry WL, Epstein SE. Comparative left ventricular dimensions in trained athletes. *Ann Intern Med* 1975;82:521-4.
 28. Mitchell JH, Haskell W, Snell P, Van Camp SP. Task Force 8: classification of sports. *J Am Coll Cardiol* 2005;45:1364-7.
 29. Pinamonti B, Alberti E, Cigalotto A et al. Echocardiographic findings in myocarditis. *The American journal of cardiology* 1988;62:285-291.
 30. Felker GM, Boehmer JP, Hruban RH et al. Echocardiographic findings in fulminant and acute myocarditis. *Journal of the American College of Cardiology* 2000;36:227-232.
 31. Damm S, Andersson LG, Henriksen E et al. Wall motion abnormalities in male elite orienteers are aggravated by exercise. *Clin Physiol* 1999;19:121-6.
 32. De Castro S, Caselli S, Maron M et al. Left ventricular remodelling index (LVRI) in various pathophysiological conditions: a real-time three-dimensional echocardiographic study. *Heart* 2007;93:205-9.
 33. Galderisi M, Cardim N, D'Andrea A et al. The multi-modality cardiac imaging approach to the Athlete's heart: an expert consensus of the European Association of Cardiovascular Imaging. *Eur Heart J Cardiovasc Imaging* 2015;16:353.

34. Holzmann M, Nicko A, Kuhl U et al. Complication rate of right ventricular endomyocardial biopsy via the femoral approach: a retrospective and prospective study analyzing 3048 diagnostic procedures over an 11-year period. *Circulation* 2008;118:1722-8.
35. Yilmaz A, Kindermann I, Kindermann M et al. Comparative evaluation of left and right ventricular endomyocardial biopsy: differences in complication rate and diagnostic performance. *Circulation* 2010;122:900-9.
36. Stiermaier T, Fohrenbach F, Klingel K et al. Biventricular endomyocardial biopsy in patients with suspected myocarditis: Feasibility, complication rate and additional diagnostic value. *Int J Cardiol* 2017;230:364-370.
37. Dennert R, Crijns HJ, Heymans S. Acute viral myocarditis. *Eur Heart J* 2008;29:2073-82.
38. Mahrholdt H, Goedecke C, Wagner A et al. Cardiovascular magnetic resonance assessment of human myocarditis: a comparison to histology and molecular pathology. *Circulation* 2004;109:1250-8.
39. Baccouche H, Mahrholdt H, Meinhardt G et al. Diagnostic synergy of non-invasive cardiovascular magnetic resonance and invasive endomyocardial biopsy in troponin-positive patients without coronary artery disease. *Eur Heart J* 2009;30:2869-79.
40. Behm P, Gastl M, Jahn A et al. CMR-guidance of passively tracked endomyocardial biopsy in an in vivo porcine model. *Int J Cardiovasc Imaging* 2018;34:1917.
41. Patriki D, Gresser E, Manka R, Emmert MY, Luscher TF, Heidecker B. Approximation of the Incidence of Myocarditis by Systematic Screening With Cardiac Magnetic Resonance Imaging. *JACC Heart Fail* 2018;6:573-579.

42. Lurz P, Luecke C, Eitel I et al. Comprehensive cardiac magnetic resonance imaging in patients with suspected myocarditis: the MyoRacer-Trial. *Journal of the American College of Cardiology* 2016;67:1800-1811.
43. Parsai C, O'Hanlon R, Prasad SK, Mohiaddin RH. Diagnostic and prognostic value of cardiovascular magnetic resonance in non-ischaemic cardiomyopathies. *Journal of cardiovascular magnetic resonance : official journal of the Society for Cardiovascular Magnetic Resonance* 2012;14:54.
44. Friedrich MG, Sechtem U, Schulz-Menger J et al. Cardiovascular magnetic resonance in myocarditis: A JACC White Paper. *Journal of the American College of Cardiology* 2009;53:1475-1487.
45. Grun S, Schumm J, Greulich S et al. Long-term follow-up of biopsy-proven viral myocarditis: predictors of mortality and incomplete recovery. *J Am Coll Cardiol* 2012;59:1604-15.
46. Nadjiri J, Nieberler H, Hendrich E et al. Performance of native and contrast-enhanced T1 mapping to detect myocardial damage in patients with suspected myocarditis: a head-to-head comparison of different cardiovascular magnetic resonance techniques. *Int J Cardiovasc Imaging* 2017;33:539-547.
47. Radunski UK, Lund GK, Saring D et al. T1 and T2 mapping cardiovascular magnetic resonance imaging techniques reveal unapparent myocardial injury in patients with myocarditis. *Clin Res Cardiol* 2017;106:10-17.
48. Pan JA, Lee YJ, Salerno M. Diagnostic Performance of Extracellular Volume, Native T1, and T2 Mapping Versus Lake Louise Criteria by Cardiac Magnetic Resonance for

- Detection of Acute Myocarditis: A Meta-Analysis. *Circ Cardiovasc Imaging* 2018;11:e007598.
49. von Knobelsdorff-Brenkenhoff F, Schuler J, Doganguzel S et al. Detection and Monitoring of Acute Myocarditis Applying Quantitative Cardiovascular Magnetic Resonance. *Circ Cardiovasc Imaging* 2017;10:e005242.
 50. Kotanidis CP, Bazmpani MA, Haidich AB, Karvounis C, Antoniadis C, Karamitsos TD. Diagnostic Accuracy of Cardiovascular Magnetic Resonance in Acute Myocarditis: A Systematic Review and Meta-Analysis. *JACC Cardiovasc Imaging* 2018;11:1583-1590.
 51. Friedrich MG. Cardiovascular Magnetic Resonance for Myocardial Inflammation: Lake Louise Versus Mapping? *Circ Cardiovasc Imaging*. United States, 2018:e008010.
 52. Ferreira VM. CMR Mapping For Myocarditis: Coming Soon to a Center Near You. *JACC Cardiovasc Imaging* 2018;11:1591-1593.
 53. Spieker M, Haberkorn S, Gastl M et al. Abnormal T2 mapping cardiovascular magnetic resonance correlates with adverse clinical outcome in patients with suspected acute myocarditis. *J Cardiovasc Magn Reson* 2017;19:38.
 54. Bohnen S, Radunski UK, Lund GK et al. Performance of t1 and t2 mapping cardiovascular magnetic resonance to detect active myocarditis in patients with recent-onset heart failure. *Circ Cardiovasc Imaging* 2015;8:e003073.
 55. La Gerche A, Burns AT, Mooney DJ et al. Exercise-induced right ventricular dysfunction and structural remodelling in endurance athletes. *European heart journal* 2011;33:998-1006.
 56. van de Schoor FR, Aengevaeren VL, Hopman MT et al. Myocardial fibrosis in athletes. *Mayo Clinic Proceedings* 2016;91:1617-1631.

57. Breuckmann F, Mohlenkamp S, Nassenstein K et al. Myocardial late gadolinium enhancement: prevalence, pattern, and prognostic relevance in marathon runners. *Radiology* 2009;251:50-7.
58. Schnell F, Claessen G, La Gerche A et al. Subepicardial delayed gadolinium enhancement in asymptomatic athletes: let sleeping dogs lie? *Br J Sports Med* 2016;50:111-7.
59. Zorzi A, Perazzolo Marra M, Rigato I et al. Nonischemic Left Ventricular Scar as a Substrate of Life-Threatening Ventricular Arrhythmias and Sudden Cardiac Death in Competitive Athletes. *Circ Arrhythm Electrophysiol* 2016;9:e004229.
60. Pieroni M, Dello Russo A, Marzo F et al. High prevalence of myocarditis mimicking arrhythmogenic right ventricular cardiomyopathy differential diagnosis by electroanatomic mapping-guided endomyocardial biopsy. *J Am Coll Cardiol* 2009;53:681-9.
61. Aquaro GD, Perfetti M, Camastra G et al. Cardiac MR With Late Gadolinium Enhancement in Acute Myocarditis With Preserved Systolic Function: ITAMY Study. *J Am Coll Cardiol* 2017;70:1977-1987.
62. Mahrholdt H, Wagner A, Deluigi CC et al. Presentation, patterns of myocardial damage, and clinical course of viral myocarditis. *Circulation* 2006;114:1581-90.
63. Greulich S, Kindermann I, Schumm J et al. Predictors of outcome in patients with parvovirus B19 positive endomyocardial biopsy. *Clin Res Cardiol* 2016;105:37-52.
64. Baughman KL. Diagnosis of myocarditis: death of Dallas criteria. *Circulation* 2006;113:593-5.

65. Filippetti L, Mandry D, Venner C et al. Long-Term Outcome of Patients With Low/Intermediate Risk Myocarditis Is Related to the Presence of Left Ventricular Remodeling in Addition to the MRI Pattern of Delayed Gadolinium Enhancement. *JACC Cardiovasc Imaging* 2018;11:1367-1369.
66. Gati S, Sharma S, Pennell D. The Role of Cardiovascular Magnetic Resonance Imaging in the Assessment of Highly Trained Athletes. *JACC Cardiovasc Imaging* 2018;11:247-259.
67. Yuan Z, Shioji K, Kihara Y, Takenaka H, Onozawa Y, Kishimoto C. Cardioprotective effects of carvedilol on acute autoimmune myocarditis: anti-inflammatory effects associated with antioxidant property. *Am J Physiol Heart Circ Physiol* 2004;286:H83-90.
68. Rezkalla S, Kloner RA, Khatib G, Smith FE, Khatib R. Effect of metoprolol in acute coxsackievirus B3 murine myocarditis. *J Am Coll Cardiol* 1988;12:412-4.
69. Dickstein K, Cohen-Solal A, Filippatos G et al. ESC guidelines for the diagnosis and treatment of acute and chronic heart failure 2008: the Task Force for the diagnosis and treatment of acute and chronic heart failure 2008 of the European Society of Cardiology. Developed in collaboration with the Heart Failure Association of the ESC (HFA) and endorsed by the European Society of Intensive Care Medicine (ESICM). *Eur J Heart Fail* 2008;10:933-89.
70. Frustaci A, Russo MA, Chimenti C. Randomized study on the efficacy of immunosuppressive therapy in patients with virus-negative inflammatory cardiomyopathy: the TIMIC study. *European heart journal* 2009;30:1995-2002.
71. Cooper LT, Hare JM, Tazelaar HD et al. Usefulness of immunosuppression for giant cell myocarditis. *The American journal of cardiology* 2008;102:1535-1539.

72. Prochnau D, Surber R, Kuehnert H, Heinke M, Klein HU, Figulla HR. Successful use of a wearable cardioverter-defibrillator in myocarditis with normal ejection fraction. *Clin Res Cardiol* 2010;99:129-31.
73. Piepoli MF, Conraads V, Corra U et al. Exercise training in heart failure: from theory to practice. A consensus document of the Heart Failure Association and the European Association for Cardiovascular Prevention and Rehabilitation. *Eur J Heart Fail* 2011;13:347-57.
74. Barone-Rochette G, Augier C, Rodiere M et al. Potentially simple score of late gadolinium enhancement cardiac MR in acute myocarditis outcome. *J Magn Reson Imaging* 2014;40:1347-54.
75. Bohm P, Scharhag J, Meyer T. Data from a nationwide registry on sports-related sudden cardiac deaths in Germany. *Eur J Prev Cardiol* 2016;23:649-56.
76. Grani C, Chappex N, Fracasso T et al. Sports-related sudden cardiac death in Switzerland classified by static and dynamic components of exercise. *Eur J Prev Cardiol* 2016;23:1228-36.
77. Cooper LT, Baughman KL, Feldman AM et al. The role of endomyocardial biopsy in the management of cardiovascular disease: a scientific statement from the American Heart Association, the American College of Cardiology, and the European Society of Cardiology. Endorsed by the Heart Failure Society of America and the Heart Failure Association of the European Society of Cardiology. *J Am Coll Cardiol* 2007;50:1914-31.
78. Cooper LT, Baughman KL, Feldman AM et al. The role of endomyocardial biopsy in the management of cardiovascular disease: a scientific statement from the American Heart Association, the American College of Cardiology, and the European Society of

Cardiology Endorsed by the Heart Failure Society of America and the Heart Failure Association of the European Society of Cardiology. *Eur Heart J* 2007;28:3076-93.

79. Yancy CW, Jessup M, Bozkurt B et al. 2013 ACCF/AHA guideline for the management of heart failure: a report of the American College of Cardiology Foundation/American Heart Association Task Force on Practice Guidelines. *J Am Coll Cardiol* 2013;62:e147-239.
80. Maron BJ, Udelson JE, Bonow RO et al. Eligibility and Disqualification Recommendations for Competitive Athletes With Cardiovascular Abnormalities: Task Force 3: Hypertrophic Cardiomyopathy, Arrhythmogenic Right Ventricular Cardiomyopathy and Other Cardiomyopathies, and Myocarditis: A Scientific Statement From the American Heart Association and American College of Cardiology. *Circulation* 2015;132:e273-80.

Tables

Table 1. Challenges in ECG, biomarkers and noninvasive imaging characteristics in patients with athlete's heart versus acute myocarditis

| | Differentiating Features Athletes Heart | Differentiating Features Myocarditis |
|---|--|--|
| Symptoms | Asymptomatic | Symptomatic |
| ECG/Holter | <ol style="list-style-type: none"> Specific ECG changes such as early repolarization/ST segment elevation, T-wave inversion in V1-V3 \leq age 16 years old, ST elevation followed by T wave inversion V1-V4 in black athletes | <ol style="list-style-type: none"> Unspecific ECG changes. Possible PQ depression, ST elevation in multiple leads. |
| Biomarkers/ Inflammatory markers | <ol style="list-style-type: none"> Troponin elevation mild and normalizes quickly. May be present in ultra-endurance athletes. | <ol style="list-style-type: none"> Troponin elevation mild to high Others: BNP elevation, Creatine-Kinase, Leucocytosis, |

| | | |
|------------|--|---|
| | <p>2. Others: BNP mildly elevated after ultra-endurance exercise</p> | <p>elevated C-reactive Protein, elevated Erythrocyte sedimentation rate</p> |
| TTE | <p>1. Ejection fraction: Sub-depressed LVEF and/or RVEF in ultra-endurance athletes, normalizes when exercising.</p> <p>2. Dilatation and eccentric remodeling, no focal regional wall motion abnormalities</p> | <p>1. Ejection fraction: Depressed LVEF, can further decline when exercising.</p> <p>2. Focal hypokinesia at rest or during exercise (regional wall motion abnormalities)</p> <p>3. Pericardial Effusion</p> |
| CMR | <p>1. LGE typically absent; possible LGE if previous silent myocarditis</p> <p>2. Edema rarely present after exercise</p> | <p>1. LGE: normal or specific mid to sub-epicardial LGE pattern</p> <p>2. Edema present</p> |

Table 2: Recommendations regarding endomyocardial biopsy and the use of CMR in patients with suspected myocarditis

| Endomyocardial biopsy recommendations | | |
|--|--|---|
| <i>ESC/ACC/AHA 2007 Scientific Statement (77,78)</i> | <i>ESC 2013 Position Statement (14)</i> | <i>ACC/AHA 2013 HF Management Guidelines (79)</i> |
| <p>Presents 13 scenarios in which EMB might be considered. Class IB recommendations for ‘EMB in the setting of unexplained, new-onset heart failure of... ... <2 weeks’ duration associated with a normal-sized or dilated left ventricle in addition to hemodynamic compromise.’</p> <p>And</p> <p>... 2 weeks’ to 3 months’ duration associated with a dilated left ventricle and new</p> | <p>Use EMB widely in order to make a diagnosis, management plan and prognosis according to whether viral genomes and inflammation are present.</p> | <p>Routine EMB in all cases of heart failure is not recommended. In those patients progressing rapidly or suffer from unexplained cardiomyopathy and where active myocarditis, in particular giant cell myocarditis is suspected, should undergo EMB.</p> |

| | | |
|--|---|--|
| <p><i>ventricular arrhythmias, Mobitz type II second- or third-degree atrioventricular (AV) heart block, or failure to respond to usual care within 1 to 2 weeks.'</i></p> | | |
| <p>Differences:</p> <p>European and US guidelines differ in so far as European guidelines do recommend routine EMB in myocarditis cases, whereas US guidelines are more conservative in using EMB.</p> | | |
| <p>Recommendations regarding the use of CMR in patients with suspected myocarditis</p> | | |
| <p><i>JACC 2009 White Paper (44)</i></p> | <p><i>ESC 2013 Position Statement (14)</i></p> | <p><i>ACC/AHA 2015 Scientific Statement (80)</i></p> |
| <p>Recommends the use of CMR as part of a more comprehensive diagnostic approach. Particularly in patients with significant ongoing, recurring or persisting inflammation, it is able to determine the extent and regional distribution of reversible and irreversible</p> | <p>Reasonable to perform CMR prior to EMB but only if the situation is not life-threatening. CMR should not replace EMB as a diagnostic tool. The use of the 'Lake – Louise – Criteria' is recommended.</p> | <p>Pericardial effusion on CMR or characteristic alterations in tissue signal on T2- or T1-weighted images and the presence of LGE are sufficient for the diagnosis of probable acute myocarditis if a clinical syndrome that includes acute heart failure, angina-type chest pain, or</p> |

| | | |
|---|--|--|
| <p>myocardial injury, as well as to detect functional abnormalities. Proposes 'Lake – Louise – Criteria'. Pooled diagnostic accuracy of 78% with a sensitivity of 67% and specificity of 91% for diagnosis of myocarditis on CMR compared to biopsy as the gold-standard.</p> | | <p>myopericarditis of <3 months' duration is present.</p> |
| <p>Differences:</p> <p>US recommendations are more inclusive of CMR as a diagnostic tool and do not require EMB in the assessment of myocarditis, whereas European recommendations include the use of CMR only complimentary to EMB.</p> | | |

Table 3: Sports Restriction Recommendations in athletes with myocarditis

| <i>ESC 2005 Consensus Document (6)</i> | <i>ESC 2006 Position Paper (7)</i> | <i>ACC/AHA 2015 Scientific Statement (80)</i> |
|---|--|---|
| <p>Medical history, physical examination, 12-lead ECG and echocardiography.</p> <p>No competitive exercise during active myocarditis or pericarditis. First control within 6 months through assessment by the above modalities as well as exercise testing; if no symptoms, normal LV function and no arrhythmias allowed to continue with all competitive sports.</p> <p>Follow-up according to individual case.</p> | <p>Medical history, physical examination, 12-lead ECG and echocardiography according to individual case assessment.</p> <p>Temporary exclusion of both competitive and recreational athletes independent of age, gender and severity for a minimum of 6 months.</p> <p>Clinical assessment prior to resumption required.</p> | <p>Biopsy not required to guide clinical management but recommended in certain cases (see Table 2). Time period of absence from exercise will depend on severity of initial symptoms. Based on experimental models, a resting period of at least 3 – 6 months is recommended. No exercise during active inflammation for patients with probable or definite myocarditis. Within 3 – 6 months of presentation, ECG, 24-hr Holter and exercise ECG to assess fitness to exercise – normal systolic function, normal biomarkers and absence of arrhythmias</p> |

| | | |
|--|--|---|
| | | <p>recommended before exercise resumption.</p> <p>Unclear whether myocarditis-related LGE should resolve first.</p> |
|--|--|---|

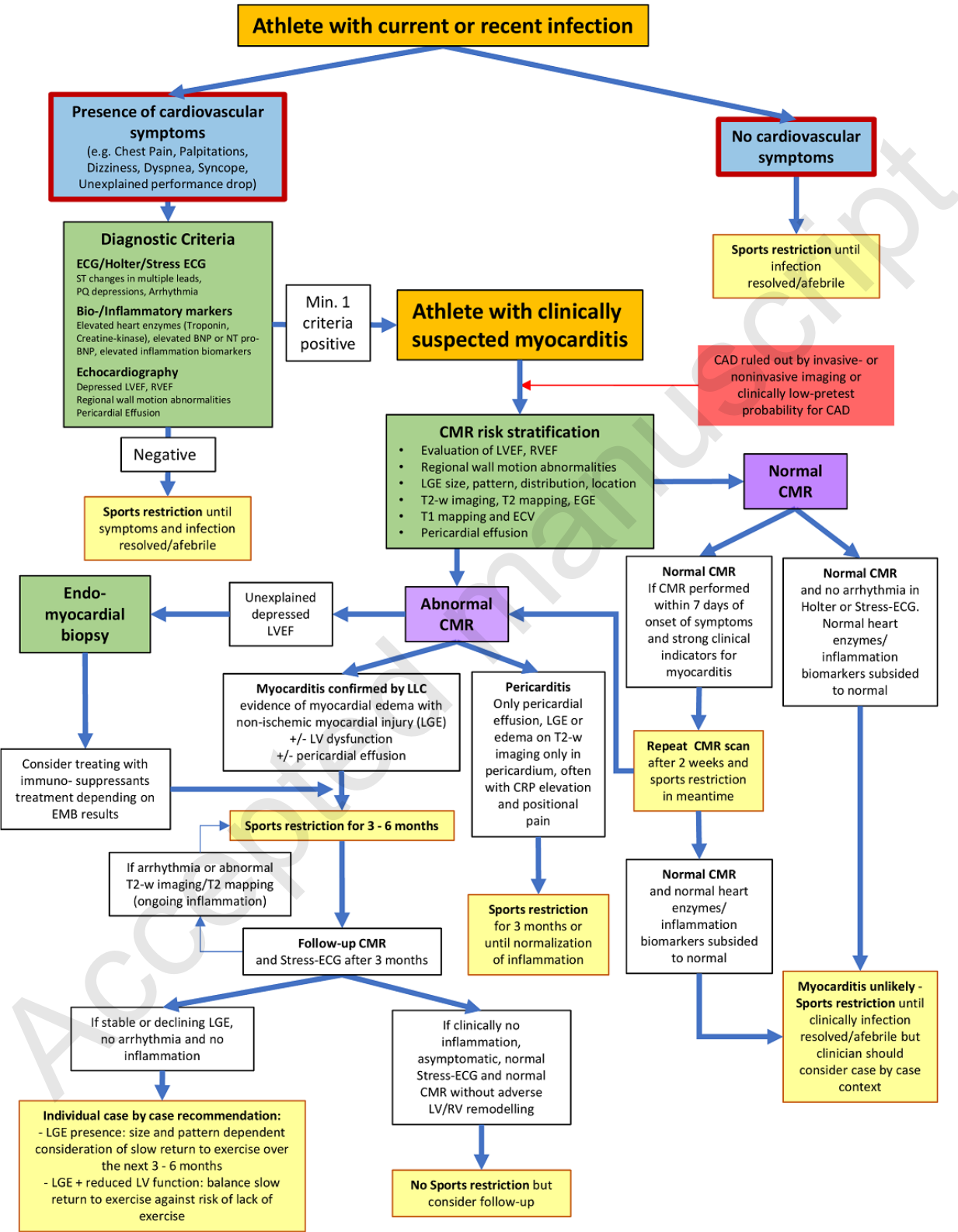
Differences:

While ACC/AHA scientific statements mention a possible minimum of 3 months of abstinence from sport, European consensus and position papers tend to focus more on 6 months of abstinence. European recommendations included the necessity of absence of symptoms, LV ventricular dysfunction and arrhythmias upon clinical assessment, while ACC/AHA recommendations also consider biomarkers and the possibility of CMR.

Accepted manuscript

Figure legends

Accepted manuscript



Central Illustration. Proposed diagnostic and treatment algorithm in the assessment of athletes who present with a clinical syndrome of current/recent infection and suspected myocarditis.

BNP = Brain Natriuretic Peptide; CAD = Coronary Artery Disease; ECG = Electrocardiogram; LLC = Lake Louise Criteria; LVEF = Left Ventricular Ejection Fraction; RVEF = Right Ventricular Ejection Fraction; T2-w = T2-weighted;

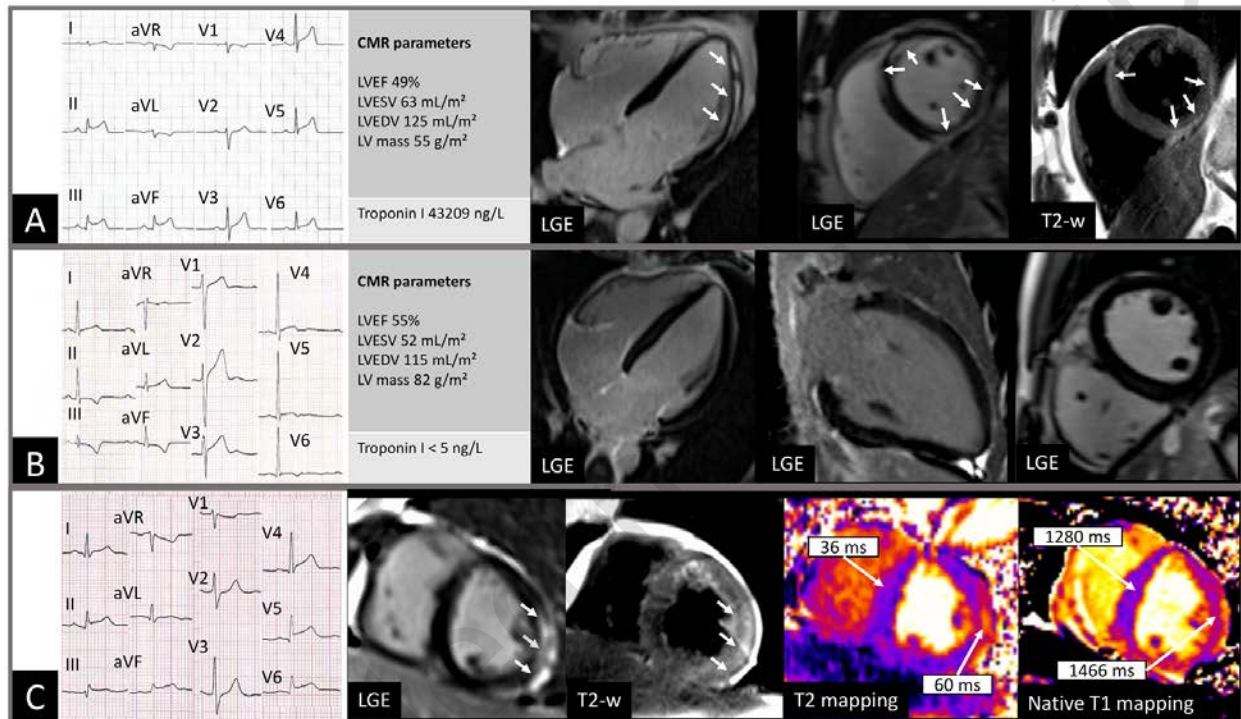


Figure 1. Examples of different myocarditis cases in athletes.

Panel A (CMR scan 10 days after onset of symptoms) represents a case of a 39 years-old recreational athlete who presented with chest pain, increased troponin, ST elevation and depressed LVEF. LGE showed midwall and subepicardial hyperenhancement in the lateral wall (white arrows) with corresponding epicardial myocardial edema (hyperintensity signal) in the T2 weighted images. Treadmill tests revealed ventricular couplet but no cardiac event was reported after a 1-year follow-up.s. Panel B (CMR scan 3 days after onset of symptoms) shows a soccer player presenting with syncope during exercise. Laboratory testing's showed no troponin increase but T waves inversion were seen on ECG. The CMR showed no LV hypertrophy, butLV dilation, normal RV dimension and preserved LVEF. There was no myocardial oedema seen on T2 weighted imaging and no LGE present. Acute myocarditis was therefore unlikely. Multiple serial follow-up exercise testing and ECG Holter were normal. Competitive physical activity was resumed with no further cardiac event during a 9-month follow-up. Panel C represents a 49 years old recreational athlete with acute chest pain. EKG showed ST elevation and Troponin I was elevated with 44792 ng/L. Invasive coronary angiogram could exclude a coronary artery disease. The CMR was performed 3 days after symptoms onset and LGE images showed epicardial enhancement on the lateral wall consistent with acute myocarditis. T2-

weighted imaging showed a hyperintensity signal in the lateral wall and T2 mapping depicted increased T2 time in the same region (60 ms) compared to the inferior wall and the septum (36 ms). These findings corresponded to intramyocardial edema. Native T1 mapping native showed increased T1 time in the lateral wall (1466 ms) compared to septum (1280 ms), anterior (1293 ms) and inferior wall (1329 ms).

LV = left ventricular; EF = ejection fraction; ESV = end-systolic volume; EDV = end-diastolic volume; RV = right ventricular; T2-w = T2-weighted

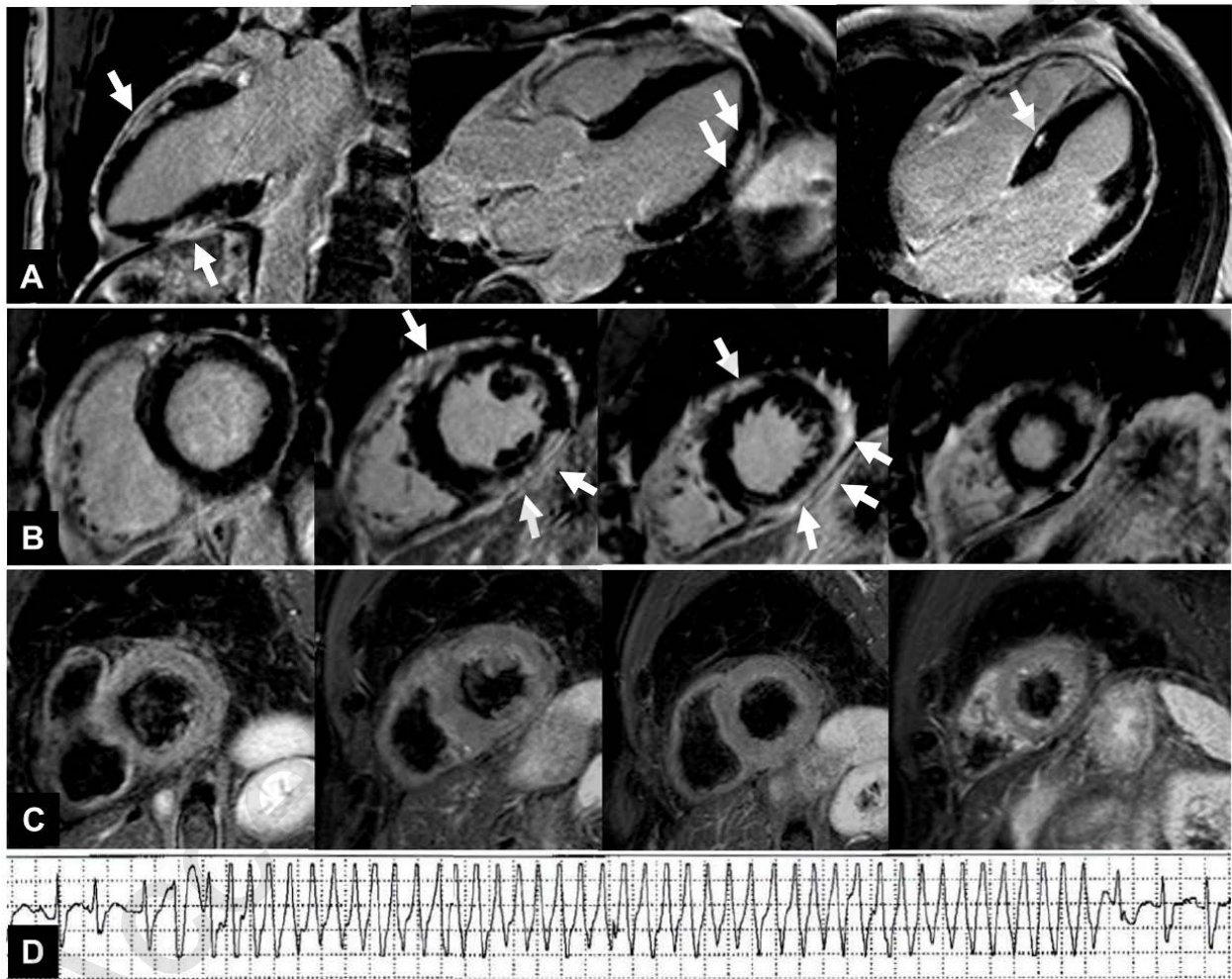


Figure 2. Case of a 62-year-old competitive triathlete who experienced vertigo and syncope of 10 seconds on maximal exertion during cycling.

Electrocardiogram and 24h Holter were normal. Ergometry was normal except ventricular triplets. Coronary arteries were normal on invasive coronary angiography. Echocardiography was normal except mild dilatation of all cardiac chambers. Severe upper respiratory tract infection was remembered two months ago. Laboratory testing including inflammation parameters and cardiac biomarkers were normal. CMR 1 months after the syncope showed large extent of epicardial late gadolinium enhancement (panel A and B, white arrows) anterior and inferior/inferolateral (midventricular) and small amount in the septum seen on the two-chamber,

three chamber and short-axis view. There was no corresponding myocardial edema visible in the T2-weighted imaging (panel C, short axis view shows signal intensity ratio of myocardium compared to skeletal muscle less than 2.0). The diagnosis of myocarditis was made (however, not “acute” at the time of the CMR scan). The athlete was recommended to abstain from strenuous exercise. After implantation of a Reveal recorder, the athlete continued (against the advice of the physician) with high intensity training and experienced a pre-syncope and a ventricular tachycardia of 333/min for 8 seconds (1 months after the CMR was done) recorded on the reveal device (panel D). The recommended beta-blocker was taken infrequently by the athlete and he denied any further electrophysiology study or intra-cardiac defibrillator implantation evaluation. He continued his high intensity trainings (again against the physician advice) and five months after first syncope the athlete died during a strenuous training of a sudden cardiac death.

Accepted manuscript