



HAL
open science

One-step nucleic acid amplification for detecting lymph node metastasis of head and neck squamous cell carcinoma

Lucie Peigne, Florence Godey, Mathieu Le Gallo, François Le Gall, Alain Fautrel, Jeff Morcet, Franck Jégoux

► **To cite this version:**

Lucie Peigne, Florence Godey, Mathieu Le Gallo, François Le Gall, Alain Fautrel, et al.. One-step nucleic acid amplification for detecting lymph node metastasis of head and neck squamous cell carcinoma. *Oral Oncology*, 2020, 102, pp.104553. 10.1016/j.oraloncology.2019.104553 . hal-02470971

HAL Id: hal-02470971

<https://univ-rennes.hal.science/hal-02470971>

Submitted on 21 Jul 2022

HAL is a multi-disciplinary open access archive for the deposit and dissemination of scientific research documents, whether they are published or not. The documents may come from teaching and research institutions in France or abroad, or from public or private research centers.

L'archive ouverte pluridisciplinaire **HAL**, est destinée au dépôt et à la diffusion de documents scientifiques de niveau recherche, publiés ou non, émanant des établissements d'enseignement et de recherche français ou étrangers, des laboratoires publics ou privés.



Distributed under a Creative Commons Attribution - NonCommercial 4.0 International License

One-step nucleic acid amplification for detecting lymph node metastasis of head and neck squamous cell carcinoma

Authors :

Lucie Peigné, MD¹; Florence Godey, MD²; Mathieu Le Gallo, PhD³; François Le Gall⁴, MD, PhD¹; Alain Fautrel, PhD⁵; Jeff Morcet⁶; Franck Jégoux MD, PhD^{1,3}

1. Head Neck Surgery Department, University hospital, Rennes, France
2. Department of Biology, Eugène Marquis Comprehensive Cancer Center, CS 44 229, Av. De Bataille Flandres Dunkerques, 35042 Rennes Cedex, France
3. Chemistry, Oncogenesis, Stress, Signaling COSS , INSERM 1242, Rennes 1 University, CLCC Eugene Marquis, rue de la bataille Flandres Dunkerques, Rennes, France
4. Pathology Department, University hospital, Rennes, France
5. H2P2, histopathological platform, University of Rennes, 35000 Rennes, France
6. Clinical investigation center, CIC INSERM 1414, University hospital of Rennes, France

Contact:

- franck.jegoux@chu-rennes.fr

One-step nucleic acid amplification for detecting lymph node metastasis of head and neck squamous cell carcinoma

ABSTRACT

BACKGROUND: In head and neck squamous cell carcinoma (HNSCC) 30% of cN0 patients have occult metastasis. LN invasion is a major prognostic factor. Sentinel lymph node (SLN) is an option for cN0 neck management. One-step nucleic acid amplification (OSNA) used to analyze SLN in breast cancer is also a candidate to get more reliable intraoperative HNSCC lymph node (LN) staging.

OBJECTIVE: To compare OSNA analysis to pathological analysis in cN0 HNSCC.

MATERIALS AND METHODS: 157 LN from 26 cN0 HNSCC patients were prospectively analyzed (6.3LN/patient). Exclusion criteria were previous surgery or radiotherapy. Each node was cut into 4 equal pieces alternatively sent to pathological analysis and OSNA technique. IHC CK19 was performed on the primary tumor biopsy and RT-qPCR of CK19, PVA and EPCAM on the LN lysate of discordant cases.

RESULTS: OSNA was able to provide intraoperative result in all patients. OSNA detected 21 metastases. There were 139 concordant LN (88.5%). There were 18 initial discordant LN (11.5%), 13 (8.3%) were OSNA positive/pathological analysis negative, 5 (3.2%) were OSNA negative/pathological analysis positive. After elimination of allocation bias, false negative rate was 1.3%, sensitivity and specificity were 90% and 95.6%, PPV and NPV were 75% and 98.5%.

CONCLUSION: Our results suggest that OSNA should be considered to improve SNB analysis both for increasing micro metastasis diagnosis and offer extemporaneous results.

Study registered under clinicaltrials.gov database number NCT02852343.

KEYWORDS: Lymph node, OSNA, head and neck squamous cell carcinoma, pathological analysis, CK19, sentinel lymph node biopsy, micro metastasis.

INTRODUCTION

In head and neck squamous cell carcinoma (HNSCC) 30% of cN0 patients have occult lymph node (LN) metastasis [1,2]. Lymph node metastasis reduce the survival by up to 50% [3,4]. The diagnosis of occult LN metastasis is relevant since metastatic patients may benefit from adjuvant therapies whereas observation may be sufficient in pN0. Actual treatment of LN is systematic neck dissection to treat all metastatic patients and to get accurate LN staging. Systematic neck dissection may increase morbidity in 70% of the patients[5]. To limit morbidity and to improve pathological analysis focusing it on a small number of nodes, Sentinel Lymph Node (SLN) analysis has been developed for cN0 neck management[6,7] . If the SLN biopsy is negative, neck dissection can be avoided, reducing the risk for post-operative complications such as nerve injuries, cervical hematomas and post-operative infections. However, intra operative SLN pathological analysis by frozen section or imprint cytology doesn't provide definitive result. After completion of pathological analysis, post operatively second-time surgery is required in patient with metastatic SLN. A technique giving definitive and accurate intra-operative results is needed. One step nucleic acid amplification (OSNA) assay allows rapid amplification of CK19 mRNA which is a biomarker of epithelial and adenocarcinoma cells absent in healthy LN. OSNA assay uses RT-LAMP (Loop isothermal Amplification) method. The main advantages of this technique are to give a definitive intra operative result within 30min thus allowing concurrent neck dissection and avoiding second time surgery. This technique has been approved for intra-operative SLN analysis in breast cancers [8] and is widely used in SLN analysis of colon cancer in Europe and Japan [9]. Three main studies investigated the feasibility of OSNA assay in HNSCC [10–12] whatever the neck LN invasion was. As OSNA assay is a candidate for intra operative SLN analysis in HNSCC the main objective of our study was to compare OSNA assay to standard pathological analysis in cN0 HNSCC patients.

MATERIALS AND METHODS

Study design

A monocentric, prospective non-interventional study of feasibility was conducted in our university tertiary care institution. This study of non-inferiority was comparative; each LN was its own control, two quarters of the LN was analyzed by pathological analysis and the two quarters left by OSNA assay.

Inclusion criteria were cN0 HNSCC patients over 18 years old requiring neck dissection or SLN. Non-inclusion criteria were previous neck dissection or radiotherapy. Patients unable to consent weren't enrolled. Characteristics of the 26 patients included were summarized in Table 1. Mean age was 61.1

±10.0 years old (range 29-79 years old) and male sex was predominant (80.8%). 158 LN were collected (6.3LN/patients), 1 LN wasn't analyzed due to technical issue. Institutional ethical committee approval and written informed consent from all patients was obtained. This study was recorded in clinicaltrials.gov database under the number NCT02852343.

Lymph nodes processing

From February 2015 to December 2016, lymph nodes were harvested during surgery. While patients underwent neck dissection, LN were harvested in a limited time of 15 minutes to prevent mRNA degradation. After removing extra nodal tissue and lipid, LN harvested from the neck dissection were cut into 4 equal pieces. The 4 pieces were alternatively sent to pathological examination and OSNA technique. The 2 pieces dedicated to OSNA technique were immediately snap-frozen in liquid nitrogen (Figure 1).

For pathological examination, LN samples were embedded in paraffin blocks and 5µm-sections were cut every 200µm. Each level was stained with HES. HES results were express according to Hermanek's classification[13] : micro metastasis ≤2mm and macro metastasis >2mm.

For OSNA assay LN samples were homogenized with Lynorhag Lysis buffer (Sysmex®, Kobe, Japan) and shortly centrifuged at 10.000xg at room temperature according to the manufacturer's instructions (Sysmex®, Kobe, Japan). OSNA analysis was carried out in duplicate with pure and diluted sample (1/10) of LN lysate without prior isolation and purification of mRNA. A 2µL sample of each lysate was subjected to a RT-LAMP reaction. Six CK19 primers were used for the reaction (5'-GGA GTT CTC AAT GGT GGC ACC AAC TAC TAC ACG ACC ATC CA-3' (CK19FA), 5'-GTC CTG CAG ATC GAC AAC GCC TCC GTC TC AAA CTT GGT TCG-3' (CK19RA), 5'-TGG TAC CAG AAG CAG GGG-3' (CK19F3), 5'-GTT GAT GTC GGC CTC CAC G-3' (CK19R3), 5'-AGA ATC TTG TCC CGC AGG-3' (CK19LPF) and 5'-CGT CTG GCT GCA GAT GA-3' (CK19LPR)) to avoid pseudo gene detection. After 16min amplification time using Lymoamp BC gene amplification reagent (Sysmex®, Kobe, Japan), the CK19 mRNA copy number per µL of lysate was determined by real-time monitoring of turbidity caused by increasing levels of magnesium pyrophosphate (a byproduct of amplification) with the RD-100i device (Sysmex®, Kobe, Japan). The node status was assessed as previously validated for breast cancer: copy number <250 = no metastasis, 250 ≤ copy number = metastasis [8]. Leftover lysates are used for RNA extraction, and other molecular techniques.

Tumor biopsy analysis

To study CK19 protein expression all primary tumors were stained with IHC CK19 (Agilent Dako®, Santa Clara, USA). CK19 tumoral expression was considered as positive if there were more or equal to 1% of

the cells stained [11]. Paraffin-embedded tissue was cut at 4 μm , mounted on positively charged slides and dried at 58°C for 60 minutes. Immunohistochemical staining was performed on the Discovery XT Automated IHC stainer using the Ventana® detection kit (Ventana® Medical Systems, Tucson, Arizona). Following deparaffination with Discovery wash solution (Ventana® Medical Systems, Tucson, Arizona) at 75 °C for 8 minutes, antigen retrieval was performed using Tris EDTA-based buffer solution pH8, at 95°C to 100°C for 24 minutes. Endogen peroxidase was blocked 3% H₂O₂ for 10 minutes. After rinsing, slides were incubated at 37°C for 32minutes with primary antibody: mouse anti-CK19 (clone RCK108, dilution at 1/50). Signal enhancement was performed using a goat anti-mouse HRP. Secondary antibody was incubated at 37°C for 16 minutes using OmniMap Kit (Ventana® Medical Systems, Tucson, Arizona). Slides were then counterstained for 16 minutes with hematoxylin and rinsed. Slides were manually dehydrated and cover slipped.

Complementary analysis:

For all discordant samples complementary molecular analysis were done with OSNA lysate: RT-PCR for CK19 (target of OSNA Assay) and also two other makers EPCAM and PVA. PVA and EPCAM were chosen because Ferris et al. [14–16] showed that PVA and EPCAM were present in HNSCC metastatic LN with a high accuracy.

Tissues and pathological examination

A second reading of all HES slides from all discordant LN in this study was realized by an experimented head and neck pathologist aware of the discordance of HES staining with OSNA assay. All discordant LN were stained with IHC CKAE1/3 with the same protocol described for CK19 above.

RNA isolation, cDNA synthesis and quantitative PCR

RNA was isolated from lymph nodes lysates used for OSNA assay (method described above) using NucleoSpin®RNA kit (Macherey-Nagel®, Düren, Germany) essentially as described by the manufacturer. Total RNA was quantified by spectrophotometry (260/280 nm ratio).

Reverse transcription (RT) was performed on 500ng of RNA, using random hexamer primers, using the Superscript III Reverse transcription kit (Thermo-fisher®, Massachusetts, USA) according to the manufacturer's instructions.

Each 5 μL PCR reaction contained 2,5 μL TaqMan® Fast Advance Master Mix (2X) (Applied Biosystem®, Foster City, USA), 0,25 μL of TaqMan® Assay (20X), 1,75 μL of nuclease free water and 2 μL of 1/10 diluted cDNA. The amplification program consisted of one stage with an initial 50°C activation stage for 2 minutes followed by one 95°C polymerase activation stage for 2 minutes and 40 stages of 95°C denaturation for 1 second followed by one 60°C extend stage for 20 seconds.

All quantitative PCR was performed on the QuantStudio® 5 system (Thermofisher®, Massachusetts, USA). Relative expression of the marker genes was calculated using the ΔC_T methods and with β -glucuronidase as the endogenous control gene. All assays were designed for use with 5' nuclease hybridization probes.

The references of probes for β -glucuronidase, CK19, EPCAM and PVA (purchased from Thermofisher®, Massachusetts, USA) are listed in Supplementary table 1.

Data from the PCR melting curve were analyzed using the applied biosystems Relative Quantitation software on the Thermo Fisher Cloud. The first derivative of the melting curve was used to determine the product T_m and to establish the presence of the specific product in each sample. Samples were analyzed in triplicate PCR reactions and the average C_t value was used in the calculation of relative expression to obtain the highest value of background expression for the sample.

To validate the RT-qPCR method in our study, the correlation between PVA, EPCAM and CK19 was calculated (Figure 2).

Definition of final discordant rate

Final discordant rate was defined as the number of discordant nodes after exclusion of the allocation bias, meaning the node in which complementary analysis confirmed that metastases were strictly located in either the tissue used for OSNA or the tissue used for histology which renders a comparison of the 2 methods impossible.

Statistical analysis

Qualitative variables were expressed as numbers and percentages. Quantitative data were expressed as means \pm standard deviations (SD) if normally distributed and medians (Q1–Q3) if not normally distributed and compared with matched Student t-tests and McNemar tests. HES was considered as the objective standard and those of the OSNA assay as the diagnostic test value. P values <0.05 were considered statistically significant. The sensitivity, specificity, positive and negative predictive values were calculated. Statistical analyses were performed using SAS® software version 9.4 (SAS Institute, Cary, NC, USA).

RESULTS

Comparison of OSNA assay with pathological analysis

OSNA was successful in 157 LN in a median time of 30'. With OSNA assay 136 LN were negative. OSNA analysis detected 21 metastases, representing 13.4% of the LN. OSNA number of copies range from <250 to 670 000 copies/ μ L of CK19 mRNA (Table 3). Average number of copies/ μ L was $48\,702 \pm 156$

357 in positive nodes. Pathological analysis detected 13 metastases: 7 micro and 6 macro metastases, representing 8.3% of the LN. There was no significant difference regarding to the rate of metastasis detection between the two techniques ($p=0.14$).

There were 139 (88.5%) concordant LN in which 131 (83.4%) were negative and 8 (5.1%) were positive for both OSNA and HES (Table 2). There were 18 initially discordant LN (11.5%): 13 OSNA+/HES- (8.3%) and 5 OSNA-/HES+ (3.2%) (Table 2).

Analysis of primary tumor CK19 protein and mRNA expression

On the primary tumor, CK19 IHC was positive in 14/26 cases (53.8%). Four patients had an IHC CK19 staining at 100%, 7 had 75% staining, one had 50% staining and 2 had 25% staining (Table 4). The 12 remaining patients did not express CK19 at protein level on the primary tumor. Number of discordant cases was not influenced by IHC CK19 ($p=0.12$).

Identification of allocation bias and analysis of discordant cases

The second reading by an experimented pathologist did not change the results of the first reading. IHC CKAE1/3 was negative in all discordant LN except for patient 8.

Among the 18 nodes initially discordant, six were associated to concordant positive nodes (patients 8, 9, 24 and 26, Table 4) in adjacent levels leading to consider them as allocation bias (Figure 3).

Among the 12 remaining LN, two were OSNA-/HES+ and 10 were OSNA+/HES-. The 2 OSNA-/HES+ were associated to a non-expression of CK19 on primary tumor biopsy, a negative CK19 RT-qPCR and a positive PVA and EPCAM RT-qPCR on the LN lysate confirming the metastatic status of the LN (patient 15, Table 4). These 2 LN were considered as false negative for OSNA analysis (Figure 3).

Among the ten OSNA+/HES- LN, four LN had positive RT-qPCR detection of CK19, PVA or EPCAM, leading to consider them as true positive for OSNA analysis and allocation bias in favor to OSNA (patients 2, 5, 7, Table 4). RT-qPCR was negative for the remaining 6 OSNA+/HES- LN (patients 12, 13, 16, 21 and 22, Table 4) leading to consider them as OSNA false positive LN (Figure 3).

After identification of allocation bias the final discordant rate was 5.1% ($n=8$). The OSNA false negative rate was 1.3% (2 LN) and the sensitivity and specificity were respectively 90% and 95.6%. The positive predictive value and the negative predictive value were respectively 75% and 98.5%.

DISCUSSION

In our study, OSNA analysis was technically feasible in all specimen and allowed micro metastasis diagnosis with a low false negative rate of 1.3%.

Allocation bias are the main pitfall of histological tissue comparison studies. They are related to the necessity to split the node which lead to an isolation of micro metastasis that become strictly located in either the tissue used for OSNA or the tissue used for histology. This renders a comparison of the two methods impossible. In our study overall discordant rate before exclusion of tissue allocation bias was 11.5% with a majority of OSNA+/HES- discordant LN. Thus, real discordant samples were distinguished from allocation bias using a second reading of all HES slides, IHC CKAE1/3 staining and complementary molecular analysis. This last was based on EPCAM and PVA markers as Ferris et al. [14–16] showed that among multiple markers these ones were present in HNSCC metastatic LN with a high accuracy. After these analyses, the final statistical analysis, only eight LN remain discordant.

There were 6 LN with positive OSNA results despite negative HES analysis and negative RT-qPCR. OSNA assay is able to detect one tumoral cell among 10^6 non tumoral cells [17] with more sensitive results when compared to HES or RT-qPCR [18]. False positive results for OSNA analysis could be due to the detection of heterotopic salivary, thyroid or epithelial inclusion in LN [19]. These inclusions account for only 1.6% of the LN [20] and are mainly located in the parotid gland or in level II and could express low level of CK19 potentially detected by OSNA. Actually, these inclusions are probably not detected as positive by OSNA regarding to the choosing threshold. Goda et al. studied OSNA results in salivary gland tissue and found that CK19 mRNA copies with OSNA ranged from 180 to 200 copies/ μ L [10] which is below the positive cut off (250copies/ μ L). Another cause for false positive is contamination by epithelial cells from skin. For this reason, as managed in the present study, LN should be carefully dissected from all surrounding non-lymphatic tissue with clean tools free from any prior use to avoid false positive results. Thus, it is likely that positive OSNA/negative HES LN suggest a superiority of OSNA on HES.

The overall false negative rate after identification of allocation bias was only 1.3% which is consistent with the literature. Goda et al. [10], Matsuzuka et al.[12] and Suzuki et al. [11] found respectively 2.6%, 3.4% and 3.7% of FN. We found a sensitivity and specificity similar to the literature, respectively of 90% and 95.6%. Goda et al. [10] found a sensitivity of 92% and a specificity of 95%. Matsuzuka et al. [12] found a sensitivity of 82.4% and a specificity of 99.3%. Suzuki et al. found a sensitivity and specificity of OSNA assay respectively at 86% and 100% in tumor expressing CK19 protein [11]. The studies of Goda[10], Matsuzuka[12] and Suzuki[11]

were undertaken in a population with a variety of neck invasion and sites of HNSCC. None of these studies targeted a population fully eligible for SLN biopsy. As we included only cN0 nodes the low number histologically positive nodes could have impacted the sensitivity and specificity rates.

Most of the negative OSNA/positive HES were due to an allocation bias, only two of them were due to non-expression of CK19 mRNA. As found in our study, CK19 protein expression in HNSCC primary tumor range from 39% to 80% [11,18,21]. Some authors suggested to restrain OSNA analysis to patient harboring a tumor positive for CK19 IHC [11,18] excluding tumor with no CK19 protein expression. However, we think that this selection criterion is not relevant because we found that CK19 mRNA can be detected both by OSNA and RT-qPCR even if the protein expression is not detected in the tumor burden as reported by previous studies [11][21] this was probably the case of patient 15. Furthermore, Norlaag et al reported that 36 to 43% of CK19 negative tumor have CK19 positive metastatic LN for [21]. This underline that CK19 protein expression in the primary tumor is not well correlated to the one of metastatic LN. Thus, we do think that when dealing with OSNA analysis the question of under expression of CK19 has to be address but not only with the CK19 protein detection in the tumor. In a cohort of 87 primary tumor biopsies, Shaw et al. analyzed the detection of CK19 using OSNA assay, RT-qPCR, RNA-ISH and IHC. They found that OSNA was the most sensitive technique with 80% of tumor expressing CK19.

To solve the issue of the variability of CK19 expression in HNSCC, molecular tests targeting other markers in the node analysis could be discuss. Yamauchi et al. also showed that CK19 had an insufficient expression in tongue cancer and proposed to use p63[22] . In a pioneer study, Brennan et al. proposed p53 as a biomolecular target[23], afterwards Hamakawa et al. suggested to use SCCA[24]. Other molecular targets were also studied [25]: MUC1 [26], E48 transcripts[27] , CK13 [20,28], CK14 [29], CK17 [30,31] , CK20 [25], PTHrp [15]. Recently, Ferris et al. screened 40 potential markers using RT-qPCR for their ability to detect HNSCC LN metastasis [14,16]. As they identified PVA [30] and EPCAM as the most specific markers they developed a rapid RT-qPCR targeting them using an automated RNA isolation and RT-qPCR instrument (Cepheid GeneXpert®, Sunnyvale, USA) with an excellent reproducibility and linearity [32]. At that time « this homemade » molecular technology could not be used for clinical practice instead of OSNA that is already implemented in clinical practice for breast, gastric and colon cancer.

A 14% false negative rate have been reported using SNB analysis in T1T2N0 in the SENT European Trial[33] which renders the 1.3% false negative rate of OSNA acceptable in clinical practice. It could be suggested to analyze extemporaneously the LN with OSNA and to keep a central histological

section that could be analyzed post-operatively with IHC staining targeting more ubiquitous cytokeratin like CKAE1/3. The great advantage with this strategy is to analyze extemporaneously SLN with good specificity and sensitivity in order to complete SLN dissection or not. The central section kept for histological analysis would allow to confirm that the tissue analyzed with OSNA assay is indeed lymphatic tissue and to diagnose the rare macro metastasis in cases without CK19 expression.

CONCLUSION

OSNA was able to provide intraoperative result in all specimen and to diagnose micro metastasis in cN0 HNSCC with a low false negative rate. This suggests that OSNA should be considered to improve SNB analysis both for increasing micro metastasis diagnosis and offer extemporaneous results. Further studies in SLN conditions with morbidity, prognosis, and survival analysis to address the benefit for patients are warranted.

ROLE OF THE FUNDING SOURCE

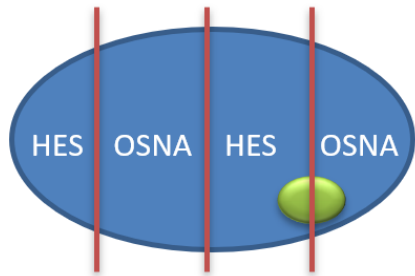
The University hospital of Rennes gave us a funding in order to finance the analysis and the technical support needed for the study. This funding was free from conflicts of interest.

REFERENCES

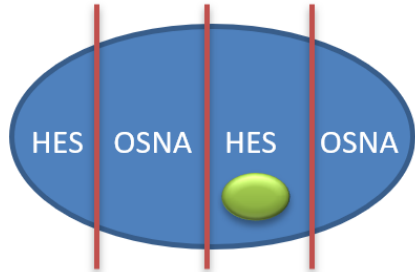
- [1] Barrera JE, Miller ME, Said S, Jafek BW, Campana JP, Shroyer KR. Detection of Occult Cervical Micrometastases in Patients With Head and Neck Squamous Cell Cancer. *The Laryngoscope* 2003;113:892–6. doi:10.1097/00005537-200305000-00022.
- [2] Gurney BAS, Schilling C, Putcha V, Alkureishi LW, Alvarez AJ, Bakholdt V, et al. Implications of a positive sentinel node in oral squamous cell carcinoma. *Head Neck* 2012;34:1580–5. doi:10.1002/hed.21973.
- [3] Tao L, Lefèvre M, Ricci S, Saintigny P, Callard P, Périé S, et al. Detection of occult carcinomatous diffusion in lymph nodes from head and neck squamous cell carcinoma using real-time RT–PCR detection of cytokeratin 19 mRNA. *Br J Cancer* 2006;94:1164–9. doi:10.1038/sj.bjc.6603073.
- [4] Alkureishi LWT, Burak Z, Alvarez JA, Ballinger J, Bilde A, Britten AJ, et al. Joint Practice Guidelines for Radionuclide Lymphoscintigraphy for Sentinel Node Localization in Oral/Oropharyngeal Squamous Cell Carcinoma. *Ann Surg Oncol* 2009;16:3190–210. doi:10.1245/s10434-009-0726-8.
- [5] D’Cruz AK, Vaish R, Kapre N, Dandekar M, Gupta S, Hawaldar R, et al. Elective versus Therapeutic Neck Dissection in Node-Negative Oral Cancer. *N Engl J Med* 2015;373:521–9. doi:10.1056/NEJMoa1506007.
- [6] Stoeckli SJ, Broglie MA. Sentinel node biopsy for early oral carcinoma: *Curr Opin Otolaryngol Head Neck Surg* 2012;20:103–8. doi:10.1097/MOO.0b013e32834ef6d3.
- [7] Broglie MA, Haile SR, Stoeckli SJ. Long-Term Experience in Sentinel Node Biopsy for Early Oral and Oropharyngeal Squamous Cell Carcinoma. *Ann Surg Oncol* 2011;18:2732. doi:10.1245/s10434-011-1780-6.
- [8] Tsujimoto M, Nakabayashi K, Yoshidome K, Kaneko T, Iwase T, Akiyama F, et al. One-step Nucleic Acid Amplification for Intraoperative Detection of Lymph Node Metastasis in Breast Cancer Patients. *Am Assoc Cancer Res* 2007;13:4807–16. doi:10.1158/1078-0432.CCR-06-2512.
- [9] Wild JB, Iqbal N, Francombe J, Papettas T, Sanders DS, Ramcharan S. Is it time for one-step nucleic acid amplification (OSNA) in colorectal cancer? A systematic review and meta-analysis. *Tech Coloproctology* 2017;21:693–9. doi:10.1007/s10151-017-1690-0.
- [10] Goda H, Nakashiro K, Oka R, Tanaka H, Wakisaka H, Hato N, et al. One-step nucleic acid amplification for detecting lymph node metastasis of head and neck squamous cell carcinoma. *Oral Oncol* 2012;48:958–63. doi:10.1016/j.oraloncology.2012.03.026.
- [11] Suzuki M, Matsuzuka T, Hashimoto Y, Ikeda M, Saijo S, Omori K. Diagnostic potential of 1-step nucleic acid amplification assay in patients with head and neck squamous cell carcinoma based on CK19 expression in a primary lesion. *Head Neck* 2016;38:E239–45. doi:10.1002/hed.23979.
- [12] Matsuzuka T, Takahashi K, Kawakita D, Kohno N, Nagafuji H, Yamauchi K, et al. Intraoperative Molecular Assessment for Lymph Node Metastasis in Head and Neck Squamous Cell Carcinoma Using One-Step Nucleic Acid Amplification (OSNA) Assay. *Ann Surg Oncol* 2012;19:3865–70. doi:10.1245/s10434-012-2409-0.
- [13] Hermanek P, Hutter RVP, Sobin LH, Wittekind C. Classification of isolated tumor cells and micrometastasis. *Cancer* 1999;86:2668–73.

- [14] Ferris RL, Xi L, Raja S, Hunt JL, Wang J, Gooding WE, et al. Molecular Staging of Cervical Lymph Nodes in Squamous Cell Carcinoma of the Head and Neck. *Cancer Res* 2005;65:2147–56. doi:10.1158/0008-5472.CAN-04-3717.
- [15] Ferris RL, Xi L, Seethala RR, Chan J, Desai S, Hoch B, et al. Intraoperative qRT-PCR for Detection of Lymph Node Metastasis in Head and Neck Cancer. *Am Assoc Cancer Res* 2011;17:1858–66. doi:10.1158/1078-0432.CCR-10-3110.
- [16] Trivedi S, Mattos J, Gooding W, Godfrey TE, Ferris RL. Correlation of tumor marker expression with nodal disease burden in metastatic head and neck cancer. *Otolaryngol--Head Neck Surg Off J Am Acad Otolaryngol-Head Neck Surg* 2013;149:261–8. doi:10.1177/0194599813486876.
- [17] Ghossein R., Bhattacharya S. Molecular detection and characterisation of circulating tumour cells and micrometastases in solid tumours. *Eur J Cancer* 2000;36:1681–94. doi:10.1016/S0959-8049(00)00152-0.
- [18] Shaw R, Christensen A, Java K, Maddani RE, Liloglou T, Asterios T, et al. Intraoperative Sentinel Lymph Node Evaluation: Implications of Cytokeratin 19 Expression for the Adoption of OSNA in Oral Squamous Cell Carcinoma. *Ann Surg Oncol* 2016;23:4042–8. doi:10.1245/s10434-016-5337-6.
- [19] Shinohara M, Harada T, Nakamura S, Oka M, Tashiro H. Heterotopic salivary gland tissue in lymph nodes of the cervical region. *Int J Oral Maxillofac Surg* 1992;21:166–71. doi:10.1016/S0901-5027(05)80787-8.
- [20] Hamakawa H, Fukuzumi M, Bao Y, Sumida T, Kayahara H, Onishi A, et al. Keratin mRNA for detecting micrometastasis in cervical lymph nodes of oral cancer. *Cancer Lett* 2000;160:115–23. doi:10.1016/S0304-3835(00)00574-7.
- [21] Noorlag R, van Es RJJ, de Bree R, Willems SM. Cytokeratin 19 expression in early oral squamous cell carcinoma and their metastasis: Inadequate biomarker for one-step nucleic acid amplification implementation in sentinel lymph node biopsy procedure. *Head Neck* 2017;39:1864–8. doi:10.1002/hed.24847.
- [22] Yamauchi K, Fujioka Y, Kogashiwa Y, Kohno N. Quantitative expression study of four cytokeratins and p63 in squamous cell carcinoma of the tongue: suitability for sentinel node navigation surgery using one-step nucleic acid amplification. *J Clin Pathol* 2011;64:875–9. doi:10.1136/jclinpath-2011-200085.
- [23] Brennan JA, Mao L, Hruban RH, Boyle JO, Eby YJ, Koch WM, et al. Molecular assessment of histopathological staging in squamous-cell carcinoma of the head and neck. *N Engl J Med* 1995;332:429–35. doi:10.1056/NEJM199502163320704.
- [24] Hamakawa H, Fukizumi M, Bao Y, Sumida T, Onishi A, Tanioka H, et al. Genetic diagnosis of micrometastasis based on SCC antigen mRNA in cervical lymph nodes of head and neck cancer. *Clin Exp Metastasis* 1999;17:593–9.
- [25] Elsheikh MN, Rinaldo A, Hamakawa H, Mahfouz ME, Rodrigo JP, Brennan J, et al. Importance of molecular analysis in detecting cervical lymph node metastasis in head and neck squamous cell carcinoma. *Head Neck* 2006;28:842–9. doi:10.1002/hed.20368.
- [26] Cai Q, Guan C, Ren Z. [Detection mucin gene in cervical lymph nodes in supraglottic cancer by reverse transcription polymerase chain reaction]. *Zhonghua Er Bi Yan Hou Ke Za Zhi* 2001;36:247–9.
- [27] Nieuwenhuis EJC, Leemans CR, Kummer JA, Denkers F, Snow GB, Brakenhoff RH, et al. Assessment and clinical significance of micrometastases in lymph nodes of head and neck cancer patients detected by E48 (Ly-6D) quantitative reverse transcription-polymerase chain reaction. *Lab Invest J Tech Methods Pathol* 2003;83:1233–40.

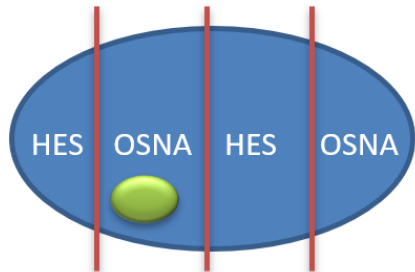
- [28] Onishi A, Nakashiro K-I, Mihara M, Sumida T, Kawamata H, Shintani S, et al. Basic and clinical studies on quantitative analysis of lymph node micrometastasis in oral cancer. *Oncol Rep* 2004;11:33–9.
- [29] Shores CG, Yin X, Funkhouser W, Yarbrough W. Clinical Evaluation of a New Molecular Method for Detection of Micrometastases in Head and Neck Squamous Cell Carcinoma. *Arch Otolaryngol Neck Surg* 2004;130:937–42. doi:10.1001/archotol.130.8.937.
- [30] Solassol J, Burcia V, Costes V, Lacombe J, Mange A, Barbotte E, et al. PempHigus vulgaris antigen mRNA quantification for the staging of sentinel lymph nodes in head and neck cancer. *Br J Cancer* 2010;102:181–7. doi:10.1038/sj.bjc.6605470.
- [31] Garrel R, Dromard M, Costes V, Barbotte E, Comte F, Gardiner Q, et al. The Diagnostic Accuracy of Reverse Transcription-PCR Quantification of Cytokeratin mRNA in the Detection of Sentinel Lymph Node Invasion in Oral and Oropharyngeal Squamous Cell Carcinoma: A Comparison with Immunohistochemistry. *Am Assoc Cancer Res* 2006;12:2498–505. doi:10.1158/1078-0432.CCR-05-2136.
- [32] Ferris RL, Stefanika P, Xi L, Gooding W, Seethala RR, Godfrey TE. Rapid molecular detection of metastatic head and neck squamous cell carcinoma as an intraoperative adjunct to sentinel lymph node biopsy. *The Laryngoscope* 2012;122:1020–30. doi:10.1002/lary.22467.
- [33] Schilling C, Stoeckli SJ, Haerle SK, Broglie MA, Huber GF, Sorensen JA, et al. Sentinel European Node Trial (SENT): 3-year results of sentinel node biopsy in oral cancer. *Eur J Cancer Oxf Engl* 1990 2015;51:2777–84. doi:10.1016/j.ejca.2015.08.023.



Metastatic cells given to HES analysis and OSNA assay



Allocation bias HES +/-OSNA-



Allocation bias HES -/OSNA+

 Metastatic tissue



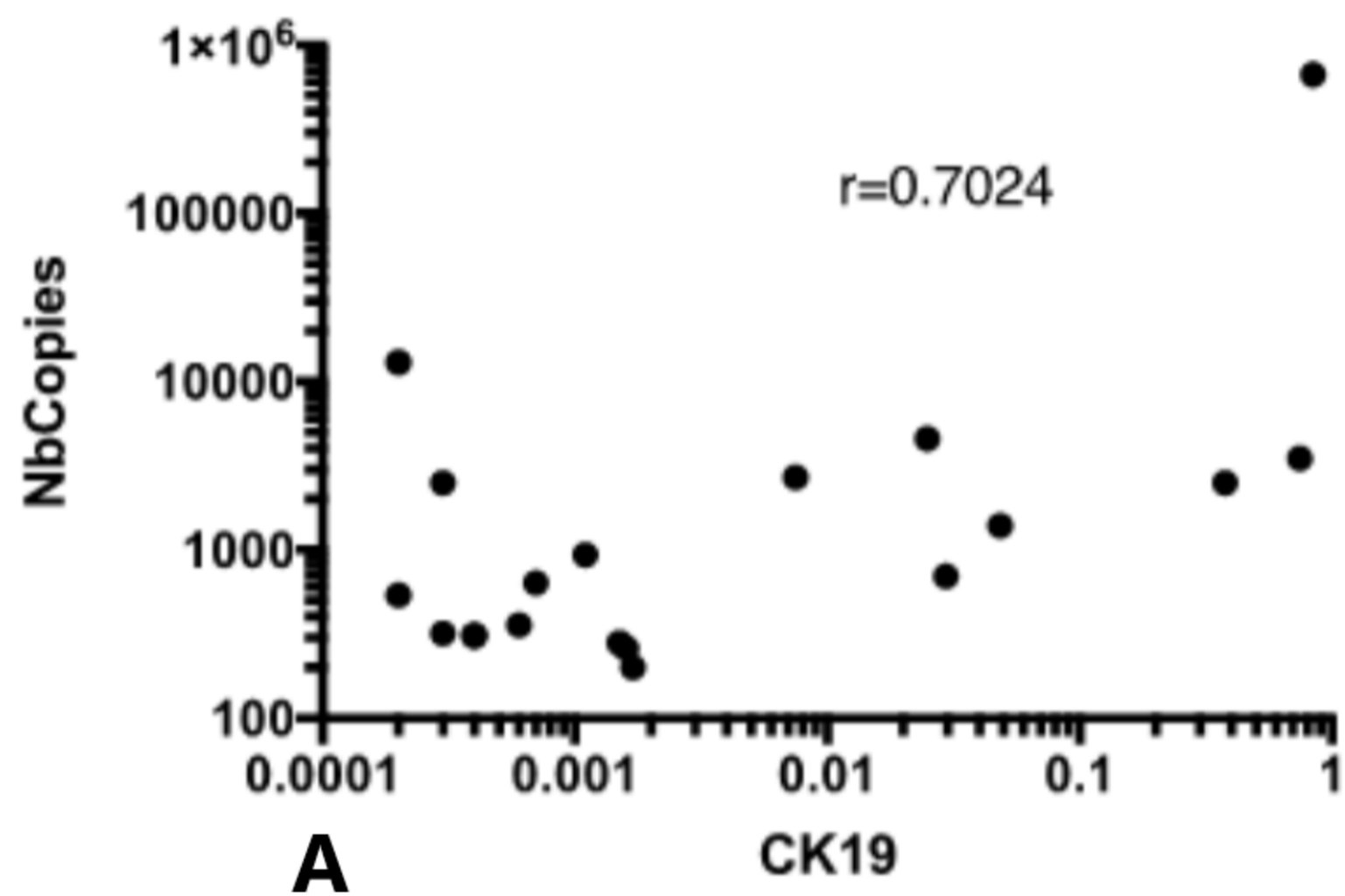
Complementary analysis if discordance



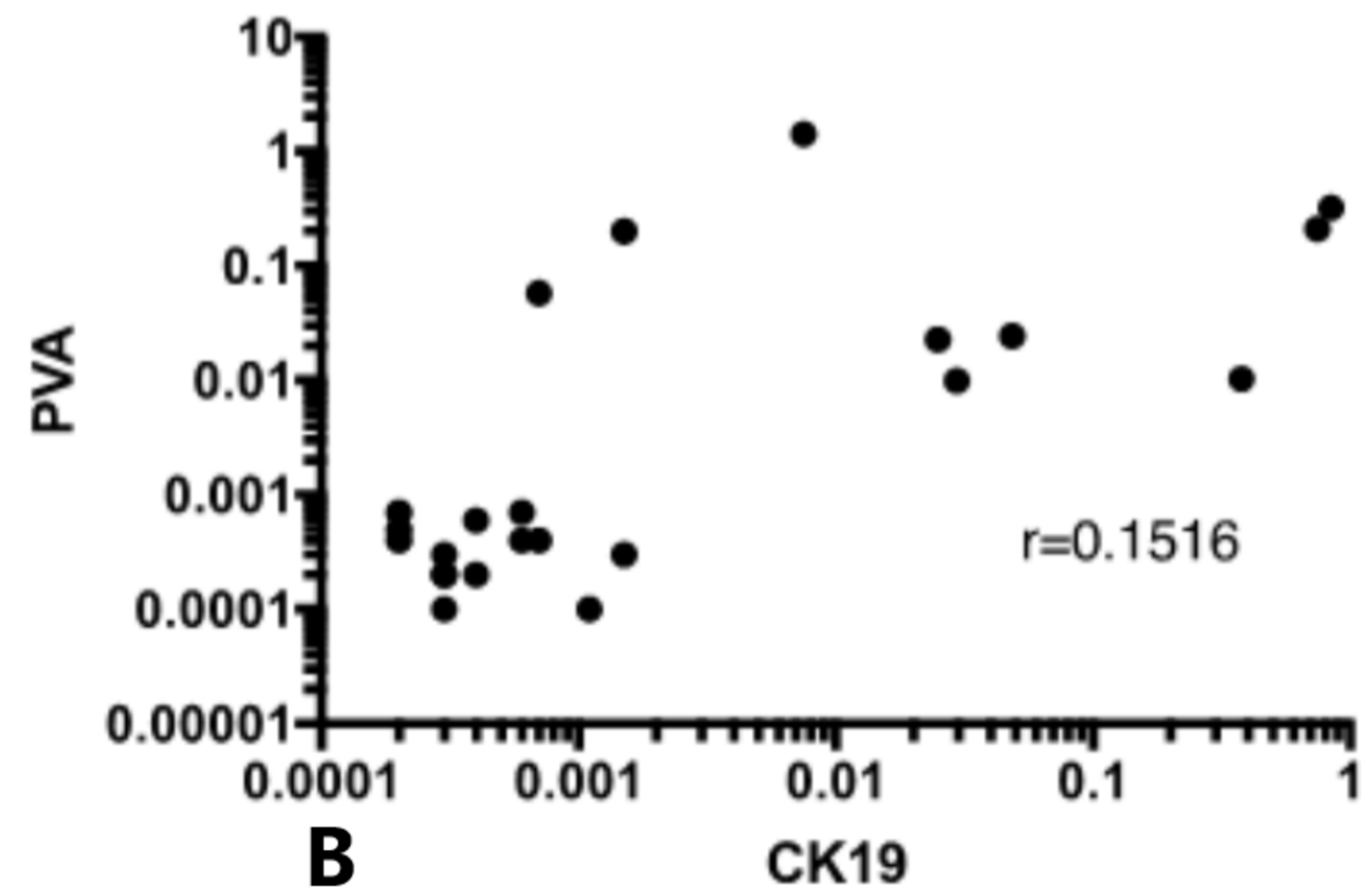
RT-qPCR CK19, PVA, EPCAM on the lysate



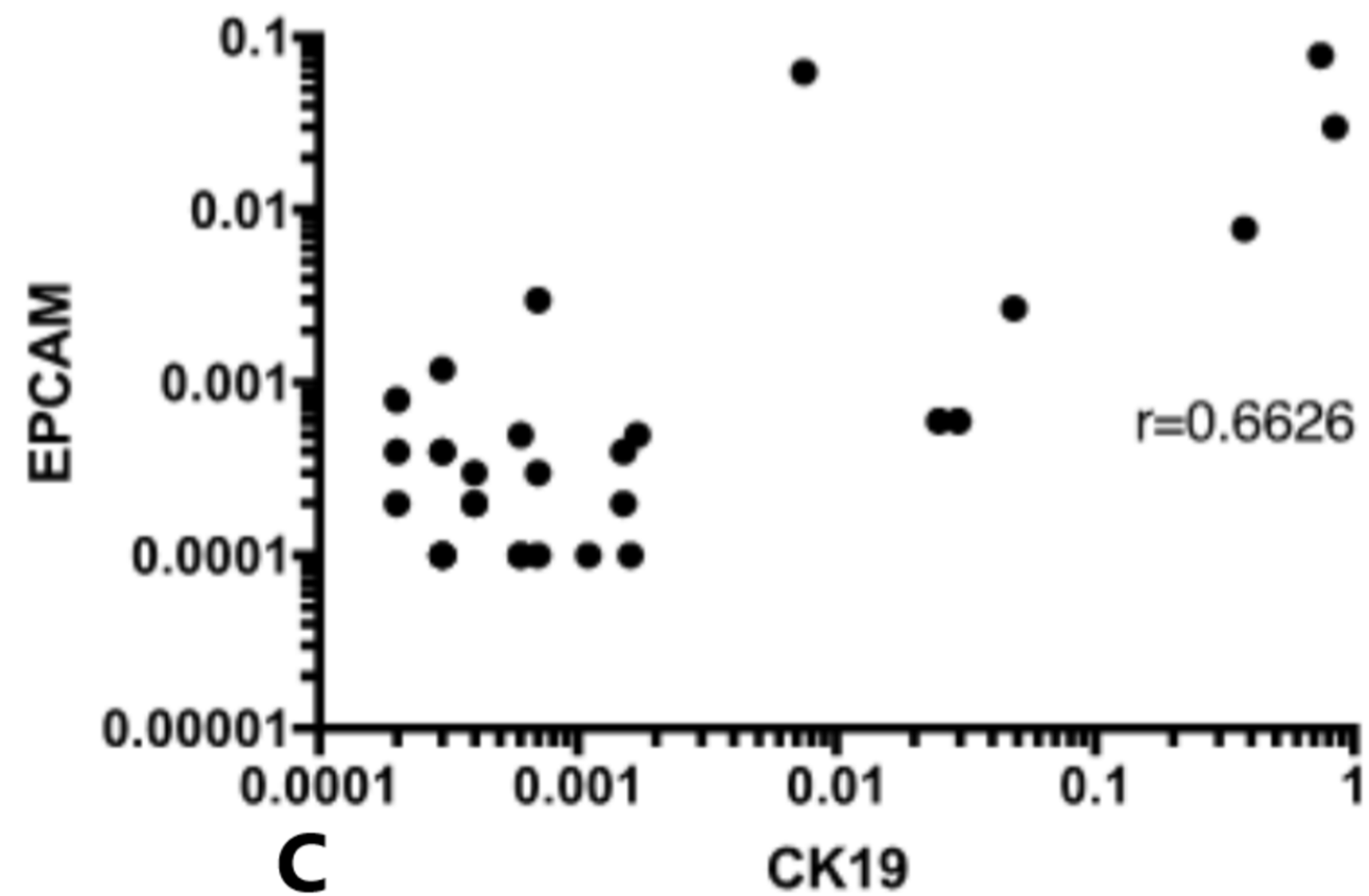
CK19vsCopiesOSNA



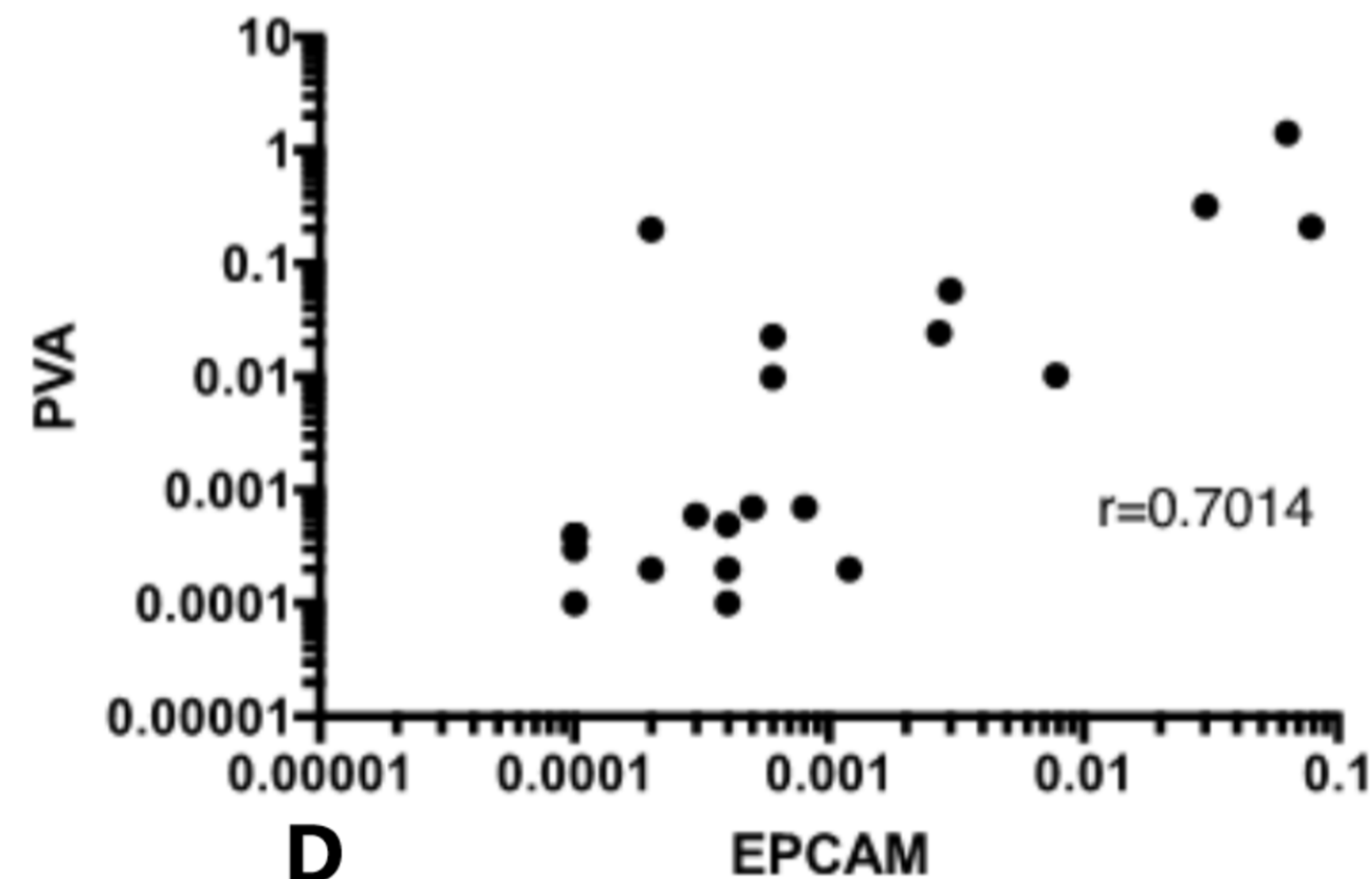
CK19vsPVA

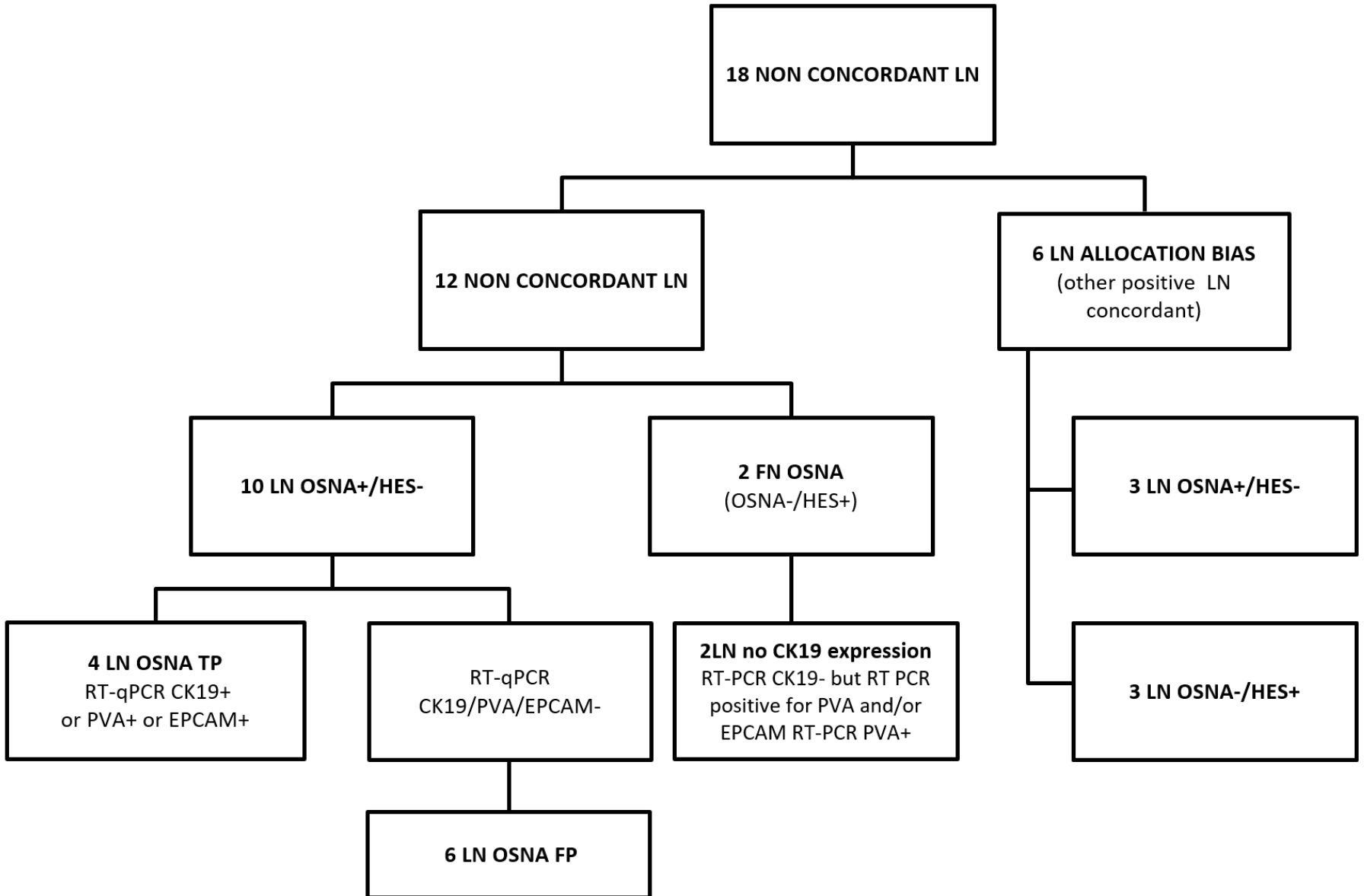


CK19vsEPCAM



EPCAMvsPVA





Gender	
Male	21 (80.8%)
Female	5 (19.2%)
Age (year)	
	61.1 (29-79)
Tumor location	
Oral Cavity	15 (57.7%)
Oropharynx	1 (3.8%)
Hypopharynx	2 (7.7%)
Larynx	8 (30.8%)
Differentiation	
Well	18 (69.2%)
Medium	8 (30.8%)
Low	0 (0.00%)
Stage	
T1N0M0	7 (26.9%)
T2N0M0	11 (42.3%)
T3N0M0	2 (7.7%)
T4N0M0	6 (23.1%)

Table 1 : Patients characteristics

		HES			Total
		Macro	Micro	Negative	
OSNA	Positive	6	2	13	21
	Negative	1	4	131	136
Total		7	6	144	157

Table 2: Concordance between HES and OSNA.

Patient	Number of LN	CK19 mRNA copies/ μ L	RESULTS HES	Discordance	IHC tumoral CK19 % cell +
08-DP	8	<250	HES -	no	100
08-DP	1	700	HES micro	no	100
08-DP	1	3500	HES micro	no	100
08-DP	2	<250	HES micro	biais	100
09-CJ	2	2500 / 2700	HES micro	no	0
09-CJ	2	540 / 2500	HES -	biais	0
09-CJ	5	<250	HES -	no	0
10-PT	1	260	HES micro	no	100
10-PT	7	<250	HES -	no	100
24-BA	1	<250	HES -	no	0
24-BA	1	<250	HES micro	biais	0
24-BA	1	1400	HES micro	no	0
26-DJ	1	360	HES -	biais	0
26-DJ	2	67000/25000	HES macro	no	0
26-DJ	2	<250	HES -	no	0
15-AY	2	<250	HES micro	yes	0
15-AY	6	<250	HES -	no	0
02-BY	1	260	HES -	yes	0
05-TD	12	<250	HES -	no	0
05-TD	1	280	HES -	yes	0
05-TD	1	6800	HES -	yes	0
07-BM	8	<250	HES -	no	100
07-BM	1	3800	HES -	yes	100
12-DP	10	<250	HES -	no	75
12-DP	1	640	HES -	yes	75
12-DP	1	320	HES -	yes	75
13-PS	1	940	HES -	yes	0
13-PS	1	<250	HES -	no	0
16-FJ	5	<250	HES -	no	100
16-FJ	1	<250	HES -	no	100
16-FJ	1	310	HES -	yes	100
21-DF	2	<250	HES -	no	0
21-DF	1	310	HES -	yes	0
22-BP	1	13000	HES -	yes	50
22-BP	2	<250	HES -	no	50

Table 3: Results of OSNA assay and HES on LN and IHC CK19 on primary tumor for patients with positive nodes. LN = Lymph Node. OSNA is positive if >250 copies/ μ L

Patient n° (Number of discordant LN)	Age	Sex	Site of primary disease	cTNM ^a	Grade of differentiation	Pathological examination (HES)	OSNA CK19mRNA (copies/μL)	Tumor IHC CK19	RT-qPCR LN lysate			Interpretation
									CK19	PVA	Epcam	
02	62	M	Oral Cavity	T1N0M0	Well	Negative	260	0%	+	-	-	TP OSNA, allocation bias
05 (2LN)	62	M	Hypopharynx	T4N0M0	Basaloid	Negative	6800 280	0%	+	+	-	TP OSNA, allocation bias
07	71	F	Oropharynx	T2N0M0	Moderate	Negative	3800	100%	+	+	+	TP OSNA, allocation bias
15 (2LN)	51	M	Larynx	T4N0M0	Well	Micro	0	0%	-	+	-	FN OSNA No CK19 expression
12 (2LN)	63	M	Oral Cavity	T2N0M0	Moderate	Negative	640 320	75%	-	-	-	FP OSNA not excluded
13	64	F	Oral Cavity	T4N0M0	Well	Negative	940	0%	-	-	-	FP OSNA not excluded
16	62	M	Larynx	T4N0M0	Well	Negative	310	100%	-	-	-	FP OSNA not excluded
21	54	M	Larynx	T4N0M0	Well	Negative	310	0%	-	-	-	FP OSNA not excluded
22	57	M	Oral Cavity	T2N0M0	Well	Negative	13000	50%	-	-	-	FP OSNA not excluded

Table 4: Complementary analysis of the 12 non-concordant lymph nodes. ^a According to the 7th UICC tumor, node, metastasis staging system. T = Tumor. LN= Lymph Node. TP= True Positive. FN = False Negative. FP = False Positive.