



Localization of Residual Conduction Gaps After Wide Antral Circumferential Ablation of Pulmonary Veins

R.P. Martins, V. Galand, N. Behar, J.-C. Daubert, P. Mabo, Christophe Leclercq, D. Pavin

► To cite this version:

R.P. Martins, V. Galand, N. Behar, J.-C. Daubert, P. Mabo, et al.. Localization of Residual Conduction Gaps After Wide Antral Circumferential Ablation of Pulmonary Veins. JACC: Clinical Electrophysiology, 2019, 5 (7), pp.753-765. 10.1016/j.jacep.2019.05.019 . hal-02181312

HAL Id: hal-02181312

<https://univ-rennes.hal.science/hal-02181312>

Submitted on 25 Oct 2021

HAL is a multi-disciplinary open access archive for the deposit and dissemination of scientific research documents, whether they are published or not. The documents may come from teaching and research institutions in France or abroad, or from public or private research centers.

L'archive ouverte pluridisciplinaire **HAL**, est destinée au dépôt et à la diffusion de documents scientifiques de niveau recherche, publiés ou non, émanant des établissements d'enseignement et de recherche français ou étrangers, des laboratoires publics ou privés.



Distributed under a Creative Commons Attribution - NonCommercial 4.0 International License

Localization Of Residual Conduction Gaps After Wide Antral Circumferential Ablation Of Pulmonary Veins: A Comprehensive Review Of The Different Techniques Available To Help Electrophysiologists

Raphaël P. Martins, MD, PhD¹, Vincent Galand, MD¹, Nathalie Behar, MD,¹ Jean-Claude Daubert, MD,¹ Philippe Mabo, MD,¹ Christophe Leclercq, MD, PhD,¹ Dominique Pavin, MD,¹

Address:

1 Univ Rennes, CHU Rennes, INSERM, LTSI – UMR 1099, F-35000, France

Corresponding author:

Raphaël P. Martins

Service de Cardiologie et Maladies Vasculaires

CHU de Rennes

2 rue Henri Le Guilloux

35000 Rennes, France

Tel: + 33 299 282 525; Fax: +33 299 282 529

Email: raphael.martins@chu-rennes.fr

Conflicts of interest: None

Abstract:

Ablation of atrial fibrillation (AF) is the cornerstone therapy for patients with symptomatic AF resistant to anti-arrhythmic drugs, or as first-line therapy, and is based on permanent pulmonary vein (PV) isolation. Indeed, the presence of a conduction gap in a wide antral circumferential ablation lesion around PVs is often sufficient to transform an initially successful ablation into a procedural failure, thus necessitating a redo intervention. The strategy during redo procedure is based on the detection and ablation of reconnection gap. Finding gaps is often simple, but sometimes challenging since gaps may be difficult to detect, resulting in unnecessary radiofrequency delivery. The present review aimed at describing the various techniques published thus far to detect residual reconnections along the encircling ablation lines around PVs, in order to help electrophysiologists to detect and ablate reconnection gaps.

Condensed Abstract: Ablation of atrial fibrillation (AF) is based on permanent pulmonary vein (PV) isolation. The presence of a conduction gap in a wide antral circumferential ablation lesion is often associated with AF recurrences, necessitating a redo intervention to find and ablate reconnection gaps. Finding gaps is often simple, but sometimes challenging since gaps may be difficult to detect, resulting in unnecessary radiofrequency delivery. The present review aimed at describing the various techniques published thus far to detect residual reconnections along the encircling ablation lines around PVs, in order to help electrophysiologists to detect and ablate reconnection gaps.

Abbreviations:

AF: Atrial fibrillation

CB: Cryoballoon

CMC: Circular mapping catheter

CS: Coronary sinus

EGM: Electrogram

LIPV: Left inferior pulmonary vein

LSPV: Left superior pulmonary vein

MRI: Magnetic resonance imaging

PV: Pulmonary vein

PVI: Pulmonary vein isolation

RF: Radiofrequency

RIPV: Right inferior pulmonary vein

RSPV: Right superior pulmonary vein

WACA: Wide antral circumferential ablation

Keywords: Atrial Fibrillation; Gaps; Ablation; Reconnection

“If you no longer go for a gap that exists, you are no longer a racing driver”.

Ayrton Senna, November 4, 1990

For every racing fan, this is certainly one of the most famous quotes ever pronounced by a Formula One driver. Going for a gap is the essence of racing, and sounds like evidence for racing drivers. No gaps, no wins. Similarly, finding gaps is the essence of electrophysiology, especially in the field of atrial fibrillation (AF) ablation. Since the seminal description of pulmonary vein (PV) isolation (PVI) by Haisseguerre et al,[1] the technique has evolved from a segmental to a more antral ablation and the achievement of a continuous transmural lesion is essential to obtain entry and exit block, permanent PVI and long-term maintenance of sinus rhythm.[2, 3] No gaps, less AF recurrences.

The presence of a conduction gap in a wide antral circumferential ablation (WACA) around PVs is sometimes enough to transform an initially successful ablation into a procedural failure, thus necessitating a redo intervention.[2] Indeed, as previously demonstrated, a large number of recurrences is due to reconnected PVs,[4, 5, 6] the remaining due to extra-PV triggers or the underlying left atrial substrate. In such cases, the redo procedure aims at detecting and ablating these reconnections. Such procedure sounds simple, but in reality is often challenging since gaps are sometimes tough to find, and therefore, to ablate.

The present review aimed at describing the various techniques published thus far to detect residual reconnections along the encircling ablation lines around PVs, in order to help electrophysiologists to “*go for a gap that exists*” and avoid the frustration of having to leave PVs connected at the end of AF ablation procedures.

Avoiding gaps during the initial ablation

First, an optimal ablation setup should be pursued during the initial ablation to avoid future gaps, whether using RF or cryoballoon (CB) energies. If one uses RF energy, the “ablation line contiguity index” algorithm, combining depth and contiguity was shown to be an accurate predictor of acute and durable PVI, and may help to identify the “weakest link in the ablation chain” in a WACA lesion set, as stated by authors. This approach was evaluated in the recently published CLOSE protocol, evaluating the safety and efficacy of a rigorous and standardized PVI workflow with delivery of deep and contiguous RF lesions.[7] Lesions were performed in a power-control mode with 25-35W (irrigation up to 30 ml/min) until an ablation index ≥ 400 at the posterior wall/roof and ≥ 550 at the anterior wall. First-pass isolation was validated in 98% of PV lesions sets (100% and 97% for right and left PVs, respectively), and only a very limited number of patients needed inter-lesion gap search and ablation. Thus, a careful and rigorous ablation workflow should be pursued to avoid gaps and obtain a persistent PVI at the end of procedure. For CB ablation, shorter applications have been shown to be as efficient as longer ones, and that a 180 seconds application may be sufficient to obtain a durable PVI.[8] A time-to-PVI < 30 seconds can predict a durable lesion, while a time-to-PVI > 60 seconds can indicate a poor contact to atrial tissue and the need to increase the application duration or to interrupt freezing and reposition the CB.[8] Current practice in most laboratories involves a 20-30 min post-ablation waiting period. The rationale for such waiting time is based on early studies showing that spontaneous PV reconnection is a time-dependent process occurring in damaged but viable cells, leading to spontaneous reconnection of PVs, initially supposed to be successfully isolated.[9] Many studies have shown that most reconnections occur during the first 30 min after the initial PVI, with a significant proportion of patients having further reconnections at 60 min and very few between 60 and 90 min.[10, 11, 12, 13] Consequently, in the “2017 HRS/EHRA/ECAS/APHRS/SOLAECE Expert Consensus statement on catheter and surgical

ablation of AF”, experts recommend a 20 min waiting period as a reasonable option during AF ablation using RF energy (Class IIa recommendation).[2]

Adenosine induces a transient hyperpolarization of the resting membrane potential of cardiomyocytes, restoring excitability in damaged but viable cells and, consequently, the conduction between PVs and the left atrium.[9] Administration of a dose of adenosine sufficient to achieve atrioventricular block or a 3-second pause has been shown to unmask dormant conduction and could improve outcomes.[14, 15] However, a sufficient waiting time is necessary before adenosine testing, since a negative response can be observed immediately after RF delivery; furthermore, the negative predictive value is very low, and negative PVs with no dormant conduction may later show PV reconnection.[16] Thus, the expert consensus statement indicates that administration of adenosine 20 minutes “may be considered” after initial PVI (Class IIb recommendation).[2]

Usual localization of conduction gaps during redo ablation of AF

First of all, one should be aware of the common localization of conduction gaps. As demonstrated in many studies, gaps are often localized in the usual same regions, sometimes thicker, or more difficult to reach with the ablation catheter or due to the inability to get a sufficient contact force to obtain a transmural lesion. An elegant histopathological analysis has demonstrated the presence of thermal injuries in ablated PVs, associating endocardial thickening, fibrous scar or nuclear pyknosis.[17] Transmural scar without viable myocardium was more frequently observed in patients with isolated PVs than those with persistent conduction, supporting the evidence that PV reconnection is due to a failure to obtain a permanent electrical lesion. However, some isolated PVs demonstrated viable myocardium alone or mixed with scar, probably explained by local tissue architecture and/or anisotropy.

For patients benefiting from a first ablation procedure, the inability to obtain PVI at the end of a first WACA pass is often due to wall thickness, making a non-transmural lesion, or catheter instability. This is particularly true for the ridge between the left PVs and the left atrial appendage. The vicinity of transeptal puncture for the ablation of right-sided PVs may also explain the difficulties to achieve an optimal contact between the catheters and the atrial tissue. El-Haddad et al showed that acute, as late PV reconnections were linked to lack of deep lesions and/or contiguity.[18] Interestingly, as shown by Sandorfi et al, the need for gap closure at de novo procedure gap was the only predictor of PV reconnection highlighting the fact that reconnection gaps usually occur in regions already difficult to isolate during the initial ablation.[19]

The localization of conduction gaps for those patients requiring a redo ablation has been thoroughly described. Galand et al compared the localization of conduction gaps in redo ablations of patients primarily ablated using a radiofrequency (RF) or a CB-based ablation.[20] Overall, an identical number of gaps per patient was observed among groups, although a significantly higher number of gaps was observed in the right superior PV for those patients first ablated with RF. The localization of gaps displayed different patterns depending on the initial energy used.

Recent studies have shown a 66.0–91.0% rate of durable PVI in patients initially ablated with cryoenergy and referred for a redo procedure.[21, 22, 23, 24, 25] In the 5 main studies having analyzed redo procedures of second-generation CB ablation, the most reconnected PV was the RSPV,[21] the RIPV,[23, 24, 25, 26] or both right PVs equally.[22] Furnkranz et al. described that reconnection gaps following CB ablation using first-generation balloon were predominantly found in the anterior part of left PVs (at the ridge between the left atrial appendage and PVs) and in the inferior segment of the RIPV.[27] Regarding patients previously ablated with second-generation CB, different preferential patterns of reconnection

were described: the anterior RSPV,[21] the inferior RIPV and LIPV, anterior LSPV and all around RSPV,[22] the postero-inferior RIPV [25, 26, 28] or the superior part of superior PVs and inferior part of inferior PVs.[23, 24] Thus, knowing *a-priori* the usual site of reconnections may help electrophysiologists to directly look after gaps in those “usual suspect” regions.

RF or CB ablation for the redo procedure?

In most laboratories, the current practice is to perform the redo ablation using RF energy, since it allows a detailed and precise characterization of the localization of the reconnection gaps. Data regarding redo ablations performed using CB ablation are scarce. A study presented at Venice Arrhythmias 2017 evaluated CB ablation for redo procedures after an initial CB ablation.[29] In this work, authors performed CB redo ablations in 67 patients, 9 (5-16) months after the initial CB ablation. 30% and 37% of the patients had AF recurrences after 1 and 2 years. Authors concluded that CB redo procedures after a first CB ablation had acceptable long-term success rate. Another study from the Chierchia group retrospectively analyzed the efficacy of second-generation CB for repeat procedures initially performed with RF. After 15 ± 8 months, 83% of the patients were free from recurrences.[30] Although these results may sound promising, we do believe that RF should be the energy of choice for a redo ablation, regardless of the energy used for the initial ablation. Indeed, as described above, it allows a precise characterization of the localization of reconnection gaps and touch-up ablation, avoiding unnecessary energy delivery.

Analysis of PV electrograms

In 2005, Ouyang et al first described that local electrograms (EGMs) at the site of reconnection gaps presented low amplitude with fragmented or double potentials. In their

study, they described a “double Lasso technique” in order to localize gaps through the analysis of local EGMs.[4] Two circular mapping catheters (CMC) were placed within the ipsilateral superior and inferior PVs to confirm whether there was recovered PV conduction. An ablation catheter was advanced close to the site with the earliest PV potential and then withdrawn to the left atrium and placed to the area near the earliest PV potential. Ablation was conducted at these locations and the presence of a conduction gap confirmed if PVI was obtained. An additional conduction gap was suspected if the PV activation sequence changed after one conduction gap was successfully ablated. Although convenient to simultaneously record both superior and inferior ipsilateral PVs, this technique needed 3 transeptal accesses, with inherent complications. The pattern of EGMs at the site of connection gaps was later carefully analyzed by Arenal et al later, using a single CMC.[31] In 85% of conduction gaps, a multicomponent low voltage (0.11 ± 0.02 mV) and long duration (59 ± 12 ms) EGM was recorded. Two or 3 components were recorded, with no isoelectric lines between them. A minority of gaps (15%) did not exhibit any discernable potential at the reconnection site. Dong et al hypothesized that a single ablation catheter was sufficient to analyze PV local EGMs and identify reconduction gaps,[32] avoiding to introduce a CMC in the left atrium, and thus, to perform a double transeptal puncture. Patients were randomly assigned to a standard double-catheter technique (CMC and RF catheter) or to a single ablation catheter group. The ablation catheter was placed into each PV and pulled back to a point just before passing the WACA lesion. The activation sequence all around the PV antrum within the WACA lesion was then calculated according to the coronary sinus reference (6 to 8 points all around the lesion). All residual gaps could eventually be identified by activation mapping in the single ablation catheter, and authors concluded that a single ablation catheter technique was feasible and as effective as CMC in analyzing PV local EGMs and localizing the residual gaps.

As stated above, the activation sequence recorded on the CMC may help to localize conduction gaps. However, one has to keep in mind that it only gives a rough estimation of its' precise location. Indeed, in the study by Bacquelin et al,[33] only two thirds of the connections were located in the region of the earliest-activated dipole of the CMC. In the recent study by Salas et al,[34] a concordance between gap location and the earliest PV EGM in the CMC during pacing was only found in 25% of the cases, with an average distance between the gap to the site in front of the earliest PV EGM of 20.4 ± 9.6 mm. The anatomy of muscle sleeves may explain such discrepancies since they are often composed of circular or spirally oriented bundles of myocytes with additional longitudinally or obliquely oriented ones, forming a mesh-like structure.[35] Muscular discontinuities and abrupt fiber orientation changes have been demonstrated in more than 50% of PV-left atrial segments,[36] which may also explain the discrepancies observed. Furthermore, the CMC often does not perfectly fit inside PV ostia due to their oval shape. This technique is therefore imprecise, especially in case of large circular lesions where the activation within the isolated PV antra may not propagate along a straight course.

The “Pace and ablate” technique

In 2010, Eitel et al[37] and Steven et al[38] simultaneously introduced a novel technique to localize conduction gaps, the so-called “pace and ablate” technique (Figure 1, panel A). Briefly, the entire ablation line is mapped while pacing from the tip of the ablation catheter with a high output of 10V or 10 mA for 2ms. If the atrial tissue is excitable at this output, a conduction gap is suspected and additional RF lesions delivered until loss of pacing capture is obtained. Simultaneous pacing and ablation from the tip of the catheter is also useful to immediately evaluate the effect of ablation and avoid ablating already isolated regions.

To note, high-output pacing may induce atrial far-field capture and overestimate the presence of excitable tissue leading to unnecessary energy delivery. This phenomenon was mainly described in the area of the left atrial ridge between PVs and the LA appendage.[37]

PV mapping during sinus rhythm or atrial pacing

A technique to find gaps using PV mapping during atrial pacing or sinus rhythm was described by Miyamoto et al.[39] A local activation map of the PV antrum, inside the WACA line, is performed in sinus rhythm or during coronary sinus pacing for right and left PVs, respectively (Figure 1, panel B). Local signals are recorded by the CMC or the ablation catheter, moved within the PV antrum and ostium, and projected to the 3D atrial shell constructed at the beginning of the procedure. The window of interest is set from the latest atrial EGM recorded on the CMC to the QRS onset. The localization of the conduction gap is defined as the precise site from which the activation proceeds towards the PV. The color-coded isochronal lines represented in 3D reconstructed geometry can help to identify the localization of the gap. If the activation sequence changes during the ablation of an initial gap, a second gap is suspected and a new PV map constructed until PVI is obtained. One of the concerns described by the authors, the need of a perfect contact between CMC electrodes and PV tissue, can now be overcome by specific algorithms in 3D mapping systems. An example of the map obtained using this technique is shown in Figure 2.

In 2017, Bacquelin et al introduced an alternative technique to detect gaps in an initial WACA lesion by pacing the atrial tissue all around the ablation line (Figure 1, panel C).[33] First, the CMC is positioned in the superior or inferior PV with the shortest atrio-PV activation time. To do so, the CMC is consecutively placed in the ipsilateral non-isolated superior and inferior PVs. Atrio-PV activation time is assessed in sinus rhythm for right PVs (from the onset of the P wave in lead II to the earliest PV potential recorded in the CMC) and during coronary sinus

pacing for left PVs (from the pacing spike to the earliest PV potential). The CMC is then placed in the PV ostium with the shortest atrio-PV activation time in a stable position. Then, the atrium is paced using the ablation catheter, 5 mm away from the ablation line (bipolar stimulation; 600 ms pacing cycle length; output at twice the pacing threshold). For each site, the following variables are analyzed: the atrio-PV delay between the pacing spike and the earliest PV potential recorded in the CMC, called the “activation delay”; and the pattern of “activation sequence” recorded on the CMC. These two variables (“activation delay” and “activation sequence”) are determined all around the WACA line. Lastly, after determining the zone with the shortest activation delay, multiple pacing points are obtained to carefully determine the exact location of the zone with the shortest activation delay. Three distinct patterns can be identified (Figure 3). In pattern A, the activation delays converged towards a single point where the delay is shortest, without change in the activation sequence recorded on the CMC, indicating the presence of a single gap in the WACA line, in front of the location of the shortest activation delay. In pattern B, the shortest activation delays converge towards two or more close locations, without any change in the activation sequence, indicating the presence of multiple close gaps. In pattern C, the activation delays converge towards two or more remote locations, with a modification of the activation sequence recorded on the CMC, indicating the presence of multiple remote gaps. RF energy is then delivered at this location. If PVI is achieved, the presence of one single gap in the WACA lesion was established. If PVI is not achieved, the effect of RF delivery on atrio-PV activation time and sequence is analyzed, to determine if residual gaps are present. Pacing maneuvers as described above are repeated, and ablation delivered in the presumed location of the other gaps until PVI was achieved.

Atrial mapping during PV pacing

The so-called “pace and map” maneuver was described by Salas et al in 2016. Briefly, the atrial side of the ablation line is mapped with the ablation catheter during PV pacing (Figure 1, panel D).[34] Bipolar pacing is conducted at 600 ms, 10 mA / 2 ms from the CMC placed inside the PV. A pacing bipole located clearly inside the PV (as shown by the 3D mapping system) is chosen, if a consistent capture is obtained. A bipole with a late activation in sinus rhythm compared to the other PV recordings should be preferred. During PV pacing, the ablation catheter is moved along the atrial side of the WACA line and the PV-atrial delay is measured at each site. A color-coded representation of the local activation time can be used to facilitate the localization of the conduction gap. The earliest electrical breakthrough into the LA is then considered as a gap site, where RF energy is delivered. During RF delivery, 3 responses can be observed: 1) PVI is obtained, suggesting that the gap was successfully ablated; 2) PVI is not obtained, and the local activation time remains the earliest activation site, suggesting insufficient ablation; or 3) PVI is not obtained, and the local activation time shifts to a later activation, with a different zone around the WACA having a earliest activation time, suggesting the presence of a second gap. This technique was described in a cohort of patients benefiting from a first RF ablation of AF, when complete PVI was not obtained after a first pass,[34] and also in a group of patients undergoing a second PVI procedure.[40] One of the advantages described by the authors to support this technique is that the conduction in the atrium is expected to be less complex than in the PV antrum itself, resulting in less abnormal local EGMs, easier to annotate, compared to a PV mapping during atrial pacing. To note, this technique cannot be performed in case of unidirectional exit block, although such situation is uncommon, and is only feasible if PV remains excitable. An example of the maps obtained with technique is shown in Figure 4.

The “escape mapping” technique: pacing inside the PV and recording the coronary sinus signal

Recently, Yang et al described a technique to detect conduction gaps without the need of a CMC, only using a single ablation catheter, called the “escape mapping” technique (Figure 1, panel E).[41] Pacing at 10 mV/2ms is performed in the PV and its’ ostia, and a reference signal is selected in the coronary sinus. An activation map is then created while pacing from the ablation catheter inside the WACA line and recording the activation time to the reference signal. The shortest time from the captured PV tissue to the coronary sinus (CS) reference signal denotes the localization of the conduction gap. Multiple gaps can be sequentially detected (Figure 5). The great advantages of this technique are 1) the need of a single catheter and a single transeptal approach 2) the fact that activation measurements are taken from the pacing spike to a clean CS reference signal, while for other methods, when pacing is performed from the atrial tissue surrounding the WACA line or from the CS catheter, the annotation is performed on PV signals, frequently split, fractionated, or of small amplitude, sometimes hampering an accurate annotation and mapping.

Limits of all these pacing techniques

All the techniques described above are based on pacing maneuvers, and consequently, are impossible to perform in patients in AF. In such patients, a cardioversion would be necessary to obtain a stable sinus rhythm and then allow pacing the atrium or PVs.

For both techniques of “PVs mapping during sinus rhythm or atrial pacing” (for the entire technique for Miyamoto et al[39] and for finding the PV with the shortest atrio-PV delay for Bacquelin et al[33]), authors mapped right PVs during sinus rhythm and left PVs during CS pacing. Pacing from the CS may lead to difficulties in EGM interpretation since the near-field PV EGM may be fused with a far-field left atrial appendage EGM. In such cases, pacing from

the left atrial appendage can be of great help to differentiate real near-field EGMs and far-field potentials. Similarly to left PVs, far-field signals from the posterior wall or the superior vena cava can confuse the analysis of right PV potentials and dedicated pacing maneuvers can be used to distinguish PV EGM components from adjacent structures.[42]

Furthermore, the further away from the PVs the WACA line is, the easier it is to identify and annotate PV potentials, and consequently, one can face difficulties performing an activation map inside the WACA line if perform too close to the PV ostia.

Future directions

Magnetic resonance imaging

Anecdotal case reports initially demonstrated the ability of magnetic resonance imaging (MRI) to non-invasively detect gaps in ablation lesions,[43] paving the way to a whole new field of research. A few years later, Ranjan et al showed that an acute identification of gaps using a real-time MRI system was possible in a swine model of AF ablation.[44] High resolution late gadolinium enhancement MRI detected the conduction gaps up to 1.4 mm that could be later ablated in the MRI scanner using real-time catheter navigation and visualization systems. Gap length determined by MRI was similar to what was observed from gross pathology. Human studies found controversial results regarding the ability of MRI to detect conduction gaps. Indeed, in a pilot study including 10 patients, Spragg et al showed that there was a significant correlation between scar identified by delayed enhancement MRI and low-voltage regions recorded during the electroanatomic mapping,[45] although there was no association between scar observed at the MRI and reconnection sites: of the 18 PV reconnection sited identified during redo ablation, 13 (72%) were localized within imaged scar, while only 5 (28%) were found to be away from MRI-detected scar. This disappointing result was later confirmed by Harrison et al, in two different studies showing in 11 redo

patients that the positive and negative predictive values for gap detection were only 35% and 43%, respectively,[46] and in another studies including 20 patients, they demonstrated a weak point-by-point relationship between late gadolinium enhancement MRI and endocardial voltage in patients undergoing repeat left atrial ablation. [47]In both studies, MRI was unable to reliably predict the sites of electrical reconnection. Conversely, Brisbal et al showed that the sensitivity/specificity and positive/negative predictive values of detecting PV reconnections with delayed enhancement MRI were 100%/57% and 94%/100%, respectively.[48] Discrepancies observed may be due to the imaging technique or the characteristics of electroanatomical mapping.[49, 50] Further prospective randomized trials are warranted to assess the utility of MRI guidance for targeting reconnection gaps after an initial PV isolation.

High resolution electroanatomic mapping

Multielectrode catheters with closely spaced electrodes permit higher resolution mapping, improving detection of gaps in reconnected PVs. Multiple electrograms can simultaneously be acquired, leading to a rapid high-density mapping of atrial and PV activity. Low amplitude signals, invisible on the ablation catheter, can be detected and ablated, as recently demonstrated in a case using the Advisor HD Grid catheter (Abbott, St Paul, MN, USA).[51] In a study including 33 patients scheduled for a repeat ablation of AF, Lin et al compared substrate mapping of the left atrium and reconnection gaps using a 3.5-mm electrode tip ablation catheter and a 1-mm electrode multielectrode PentaRay catheter (Biosense Webster, Diamond Bar, CA, USA). The PentaRay catheter identified significantly more reconnected PVs (1.97 ± 0.59 vs. 1.49 ± 0.62 , $p = 0.002$) and more conducting gaps (2.91 ± 0.68 vs. 2.12 ± 0.65 , $p = 0.001$). The 3.5-mm ablation catheter missed 26 gaps which were seen with the PentaRay catheter, gaps that displayed lower voltage amplitude and shorter duration than

those which were not missed. Compared to a historical propensity matched control cohort undergoing AF ablation guided by mapping with wide inter-electrode spacing catheters, patients ablated with multielectrode catheters appeared to have a superior 1-year freedom from arrhythmia (79% vs. 50%; $p < 0.05$) suggesting a potential effect on long-term efficacy in patients referred for a redoablation.

Recently, Kosiuk et al and Benito et al reported the value of ultra-high resolution electroanatomic mapping for localizing gaps in 2 cases.[52, 53] Mapping of PV-left atrial junction was performed with the new Rhythmia® electroanatomical mapping system (Boston Scientific, Marlborough, MA, USA) using the Orion catheter. Compared to a regular Lasso catheter with twenty 1 mm² surface electrodes, this basket catheter has 8 splines with 8 electrodes on each spline (total of 64 electrodes), each one having a surface area of 0.4mm². Such small electrodes can record low amplitude signals, as observed in reconnection gaps. Indeed, authors describe that gaps could be easily spotted using activation and voltage maps in their respective patients. Masuda et al reported the use of the Orion catheter to localize gaps in 39 reconnected PVs from 31 patients.[54] A total of $7,454 \pm 4,289$ mapping points were acquired during an average of 12.2 ± 3.6 min. Fifty four gaps were encountered in these 39 reconnected PVs, 57% of which localized using the automatic EGM annotation system, while the remaining 43% of gaps were not visualized due to incorrect annotation of the local activation time, either on far field signals or electric noise. Manual correction of these EGMs resulted in identification of all the reconnection gaps. Furthermore, the line created by the initial ablation was identified by changing the lower limit of the voltage coloring range, starting with 0.20 mV and with subsequent decrements of 0.02 mV. Sites with a voltage-preserved EGM pathway surround by scar tissue were identified as gaps. Using such technique, a rough estimation of gap localization was possible for all the gaps, but its exact localization was identified in the voltage map in only one-third of the patients. The great

advantage of ultra-high resolution electroanatomic mapping is that it allows visualization of near-field low voltage EGMs. Indeed, the ablation catheter failed to record the previously annotated local EGM at the exact gap localization in 20% of the cases.[54] In a larger population of 108 patients, Garcia-Bolao et al demonstrated that the Orion catheter was more accurate to detect reconnection gaps than a regular CMC, resulting in less applications and total RF time.[55] In summary, gaps can be successfully localized, either automatically, or by manually re-annotating the local EGMs. However, importantly, and as suggested in Benito et al case report, and in Masuda et al study, voltage map failed to identify gap localization in two-third of the cases, and comparative analysis of the voltage map and the local EGM has to be performed to correctly localize conduction gaps. An example of the activation map obtained in a patient with a gap after WACA is shown in Figure 6.

Direct visualization of gaps

The ability to visualize endocardial RF ablation lesions guided by direct endocardial visualization (DEV) was described in 2009 by Eversull et al in a porcine ex-vivo and in-vivo model.[56] RF lesions could be accurately seen. Inter-lesions gaps visualized by DEV corresponded to gross pathology examination. The first-in-human use of a DEV ablation catheter (Voyage Medical Inc., Redwood City, CA) to visualize and ablate inter-lesion gaps was later published.[57] A fiberoptic camera is placed at the distal hood of the catheter to visualize the endocardial surface of the myocardium, and an unobstructed field of view is created by a saline irrigation purging away the blood at the tip of the catheter. Four metal plate electrodes are positioned at the distal hood of the catheter creating 4 pairs of bipolar EGMs. Using this system, authors could have a full-color endocardial visualization of gaps that could be ablated under visual guidance. Further studies will be needed to determine whether such technology can be implemented in daily clinical practice.

Conclusion

Finding a reconnection gap in a WACA line is often straightforward, but sometimes challenging. In some instances, electrophysiologists may spend a significant part of a procedure going for a refractory gap, leading to unnecessary RF delivery and longer procedure/fluoroscopy durations. Various techniques, mainly based on pacing, have been described and should be known in order to rapidly achieve PVI.

References

- 1 Haissaguerre M, Jais P, Shah DC, et al. Spontaneous initiation of atrial fibrillation by ectopic beats originating in the pulmonary veins. *N Engl J Med* 1998;339:659-66.
- 2 Calkins H, Hindricks G, Cappato R, et al. 2017 HRS/EHRA/ECAS/APHRS/SOLAECE expert consensus statement on catheter and surgical ablation of atrial fibrillation. *Europace* 2018;20:e1-e160.
- 3 Gerstenfeld EP, Dixit S, Callans D, et al. Utility of exit block for identifying electrical isolation of the pulmonary veins. *J Cardiovasc Electrophysiol* 2002;13:971-9.
- 4 Ouyang F, Ernst S, Chun J, et al. Electrophysiological findings during ablation of persistent atrial fibrillation with electroanatomic mapping and double Lasso catheter technique. *Circulation* 2005;112:3038-48.
- 5 Nery PB, Belliveau D, Nair GM, et al. Relationship Between Pulmonary Vein Reconnection and Atrial Fibrillation Recurrence: A Systematic Review and Meta-Analysis. *JACC Clin Electrophysiol* 2016;2:474-83.
- 6 Verma A, Kilicaslan F, Pisano E, et al. Response of atrial fibrillation to pulmonary vein antrum isolation is directly related to resumption and delay of pulmonary vein conduction. *Circulation* 2005;112:627-35.
- 7 Taghji P, El Haddad M, Philips T, et al. Evaluation of a Strategy Aiming to Enclose the Pulmonary Veins With Contiguous and Optimized Radiofrequency Lesions in Paroxysmal Atrial Fibrillation: A Pilot Study. *JACC Clin Electrophysiol* 2017;4:99-108.
- 8 Su W, Aryana A, Passman R, et al. Cryoballoon Best Practices II: Practical guide to procedural monitoring and dosing during atrial fibrillation ablation from the perspective of experienced users. *Heart Rhythm* 2018;15:1348-55.

- 9 Datino T, Macle L, Qi XY, et al. Mechanisms by which adenosine restores conduction in dormant canine pulmonary veins. *Circulation* 2010;121:963-72.
- 10 Cheema A, Dong J, Dalal D, et al. Incidence and time course of early recovery of pulmonary vein conduction after catheter ablation of atrial fibrillation. *J Cardiovasc Electrophysiol* 2007;18:387-91.
- 11 Nakamura K, Naito S, Kaseno K, et al. Optimal observation time after completion of circumferential pulmonary vein isolation for atrial fibrillation to prevent chronic pulmonary vein reconnections. *Int J Cardiol* 2013;168:5300-10.
- 12 Teunissen C, Clappers N, Kassenberg W, et al. Time matters: adenosine testing immediately after pulmonary vein isolation does not substitute a waiting period. *Europace* 2017;19:1140-5.
- 13 Wang XH, Liu X, Sun YM, et al. Early identification and treatment of PV reconnections: role of observation time and impact on clinical results of atrial fibrillation ablation. *Europace* 2007;9:481-6.
- 14 Kobori A, Shizuta S, Inoue K, et al. Adenosine triphosphate-guided pulmonary vein isolation for atrial fibrillation: the UNmasking Dormant Electrical Reconduction by Adenosine TriPhosphate (UNDER-ATP) trial. *Eur Heart J* 2015;36:3276-87.
- 15 Macle L, Khairy P, Weerasooriya R, et al. Adenosine-guided pulmonary vein isolation for the treatment of paroxysmal atrial fibrillation: an international, multicentre, randomised superiority trial. *Lancet* 2015;386:672-9.
- 16 Dallaglio PD, Betts TR, Ginks M, et al. The Role of Adenosine in Pulmonary Vein Isolation: A Critical Review. *Cardiol Res Pract* 2016;2016:8632509.
- 17 Kowalski M, Grimes MM, Perez FJ, et al. Histopathologic characterization of chronic radiofrequency ablation lesions for pulmonary vein isolation. *J Am Coll Cardiol* 2012;59:930-8.

- 18 El Haddad M, Taghji P, Philips T, et al. Determinants of Acute and Late Pulmonary Vein Reconnection in Contact Force-Guided Pulmonary Vein Isolation: Identifying the Weakest Link in the Ablation Chain. *Circ Arrhythm Electrophysiol* 2017;10.
- 19 Sandorfi G, Rodriguez-Manero M, Saenen J, et al. Less Pulmonary Vein Reconnection at Redo Procedures Following Radiofrequency Point-by-Point Antral Pulmonary Vein Isolation With the Use of Contemporary Catheter Ablation Technologies. *JACC Clin Electrophysiol* 2018;4:1556-65.
- 20 Galand V, Pavin D, Behar N, et al. Localization of gaps during redo ablations of paroxysmal atrial fibrillation: Preferential patterns depending on the choice of cryoballoon ablation or radiofrequency ablation for the initial procedure. *Arch Cardiovasc Dis* 2016;109:591-8.
- 21 Bordignon S, Furnkranz A, Perrotta L, et al. High rate of durable pulmonary vein isolation after second-generation cryoballoon ablation: analysis of repeat procedures. *Europace* 2015;17:725-31.
- 22 Ciconte G, Mugnai G, Sieira J, et al. On the Quest for the Best Freeze: Predictors of Late Pulmonary Vein Reconnections After Second-Generation Cryoballoon Ablation. *Circ Arrhythm Electrophysiol* 2015;8:1359-65.
- 23 Koektuerk B, Yorgun H, Koektuerk O, et al. Characterization of Electrical Reconnection Following Pulmonary Vein Isolation Using First- and Second-Generation Cryoballoon. *Pacing Clin Electrophysiol* 2016;39:434-42.
- 24 Martins RP, Galand V, Cesari O, et al. The second generation cryoballoon has improved durable isolation of left but not right pulmonary veins: new insights from a multicentre study. *Europace* 2018;20:1115-21.

- 25 Miyazaki S, Taniguchi H, Hachiya H, et al. Clinical recurrence and electrical pulmonary vein reconnections after second-generation cryoballoon ablation. *Heart Rhythm* 2016;13:1852-7.
- 26 Heeger CH, Wissner E, Mathew S, et al. Once Isolated, Always Isolated? Incidence and Characteristics of Pulmonary Vein Reconduction After Second-Generation Cryoballoon-Based Pulmonary Vein Isolation. *Circ Arrhythm Electrophysiol* 2015;8:1088-94.
- 27 Furnkranz A, Chun KR, Nuyens D, et al. Characterization of conduction recovery after pulmonary vein isolation using the "single big cryoballoon" technique. *Heart Rhythm* 2010;7:184-90.
- 28 Reddy VY, Sediva L, Petru J, et al. Durability of Pulmonary Vein Isolation with Cryoballoon Ablation: Results from the Sustained PV Isolation with Arctic Front Advance (SUPIR) Study. *J Cardiovasc Electrophysiol* 2015;26:493-500.
- 29 Westra SW, Van Vugt SPG, Sezer S, et al. 073_16772-H5 First Long-Term Redo Experiences With Cryo After Cryoballoon Ablation for Atrial Fibrillation: A Two-Year Follow-Up Registry. *JACC Clin Electrophysiol* 2017;3:S9-S10.
- 30 De Regibus V, Iacopino S, Abugattas JP, et al. Repeat procedures using the second-generation cryoballoon for recurrence of atrial fibrillation after initial ablation with conventional radiofrequency. *J Interv Card Electrophysiol* 2017;49:119-25.
- 31 Arenal A, Atea L, Datino T, et al. Identification of conduction gaps in the ablation line during left atrium circumferential ablation: facilitation of pulmonary vein disconnection after endpoint modification according to electrogram characteristics. *Heart Rhythm* 2008;5:994-1002.
- 32 Dong J, Liu X, Long D, et al. Single-catheter technique for pulmonary vein antrum isolation: is it sufficient to identify and close the residual gaps without a circular mapping catheter? *J Cardiovasc Electrophysiol* 2009;20:273-9.

- 33 Bacquelin R, Martins RP, Behar N, et al. A novel method for localization and ablation of conduction gaps after wide antral circumferential ablation of pulmonary veins. *Arch Cardiovasc Dis* 2017;111:340-8.
- 34 Salas J, Castellanos E, Peinado R, et al. Atrial mapping during pulmonary vein pacing: a novel maneuver to detect and close residual conduction gaps in an ablation line. *J Interv Card Electrophysiol* 2016;47:299-307.
- 35 Ho SY, Cabrera JA, Tran VH, et al. Architecture of the pulmonary veins: relevance to radiofrequency ablation. *Heart* 2001;86:265-70.
- 36 Tan AY, Li H, Wachsmann-Hogiu S, et al. Autonomic innervation and segmental muscular disconnections at the human pulmonary vein-atrial junction: implications for catheter ablation of atrial-pulmonary vein junction. *J Am Coll Cardiol* 2006;48:132-43.
- 37 Eitel C, Hindricks G, Sommer P, et al. Circumferential pulmonary vein isolation and linear left atrial ablation as a single-catheter technique to achieve bidirectional conduction block: the pace-and-ablate approach. *Heart Rhythm* 2010;7:157-64.
- 38 Steven D, Reddy VY, Inada K, et al. Loss of pace capture on the ablation line: a new marker for complete radiofrequency lesions to achieve pulmonary vein isolation. *Heart Rhythm* 2010;7:323-30.
- 39 Miyamoto K, Tsuchiya T, Yamaguchi T, et al. A new method of a pulmonary vein map to identify a conduction gap on the pulmonary vein antrum ablation line. *Circ J* 2011;75:2363-71.
- 40 Barrio-Lopez MT, Castellanos E, Ortiz M, et al. Atrial mapping during pulmonary vein pacing to detect conduction gaps in a second pulmonary vein isolation procedure. *J Interv Card Electrophysiol* 2018;53:195-205.
- 41 Yang F, Murphy T. Escape Mapping: Rapid Identification of Pulmonary Vein Isolation Gaps Utilizing an Ablation Catheter. *JACC Clin Electrophysiol* 2017;4:151-2.

- 42 Kircher S, Sommer P. Electrophysiological Evaluation of Pulmonary Vein Isolation. *J Atr Fibrillation* 2013;6:934.
- 43 Reddy VY, Schmidt EJ, Holmvang G, et al. Arrhythmia recurrence after atrial fibrillation ablation: can magnetic resonance imaging identify gaps in atrial ablation lines? *J Cardiovasc Electrophysiol* 2008;19:434-7.
- 44 Ranjan R, Kholmovski EG, Blauer J, et al. Identification and acute targeting of gaps in atrial ablation lesion sets using a real-time magnetic resonance imaging system. *Circ Arrhythm Electrophysiol* 2012;5:1130-5.
- 45 Spragg DD, Khurram I, Zimmerman SL, et al. Initial experience with magnetic resonance imaging of atrial scar and co-registration with electroanatomic voltage mapping during atrial fibrillation: success and limitations. *Heart Rhythm* 2012;9:2003-9.
- 46 Harrison J, Linton N, Williams S, et al. Prediction of gaps in atrial ablation lesion sets by late gadolinium enhancement magnetic resonance imaging. *J Cardiovasc Magn Res* 2013;15(Suppl 1):E95.
- 47 Harrison JL, Sohns C, Linton NW, et al. Repeat left atrial catheter ablation: cardiac magnetic resonance prediction of endocardial voltage and gaps in ablation lesion sets. *Circ Arrhythm Electrophysiol* 2015;8:270-8.
- 48 Bisbal F, Guiu E, Cabanas-Grandio P, et al. CMR-guided approach to localize and ablate gaps in repeat AF ablation procedure. *JACC Cardiovasc Imaging* 2014;7:653-63.
- 49 Bisbal F, Berruezo A, Mont L. Letter by Bisbal et al regarding article, "Repeat left atrial catheter ablation: cardiac magnetic resonance prediction of endocardial voltage and gaps in ablation lesion sets". *Circ Arrhythm Electrophysiol* 2015;8:753.
- 50 Harrison JL, Sohns C, Linton NW, et al. Response to letter from Bisbal et al regarding, "Repeat left atrial catheter ablation: cardiac magnetic resonance prediction of endocardial voltage and gaps in ablation lesion sets". *Circ Arrhythm Electrophysiol* 2015;8:754-5.

- 51 Yeo C, Tan VH, Wong KCK. Pulmonary vein reconnection mapping with Advisor HD Grid demonstrating local EGM which were not visible on TactiCath ablation catheter. *J Arrhythm* 2018;35:152-4.
- 52 Benito EM, Andreu D, Mont L, et al. Correlation between functional electrical gaps identified by ultrahigh-density mapping and by late gadolinium enhancement cardiac magnetic resonance in repeat atrial fibrillation procedure. *HeartRhythm Case Rep* 2017;3:282-5.
- 53 Kosiuk J, Hilbert S, Hindricks G, et al. Channel-Based Gap Mapping for Pulmonary Vein Isolation. *J Cardiovasc Electrophysiol* 2016;27:488-9.
- 54 Masuda M, Fujita M, Iida O, et al. The identification of conduction gaps after pulmonary vein isolation using a new electroanatomic mapping system. *Heart Rhythm* 2017;14:1606-14.
- 55 Garcia-Bolao I, Ballesteros G, Ramos P, et al. Identification of pulmonary vein reconnection gaps with high-density mapping in redo atrial fibrillation ablation procedures. *Europace* 2018;20:f351-f8.
- 56 Eversull CS, Lin B, Irani AR, et al. Direct visualization of cardiac radiofrequency ablation lesions. *J Cardiovasc Transl Res* 2009;2:198-201.
- 57 Chik WWB, Robinson D, Ross DL, et al. First-in-human case of repeat pulmonary vein isolation by targeting visual interlesion gaps using the direct endoscopic ablation catheter after single ring pulmonary vein isolation. *HeartRhythm Case Rep* 2015;1:279-84.

Figure legends:

Figure 1: Schematic representation of the various techniques described to determine the localization of a conduction gap in a WACA lesion set. The square symbol represents a pacing point, while the star represents a recording point.

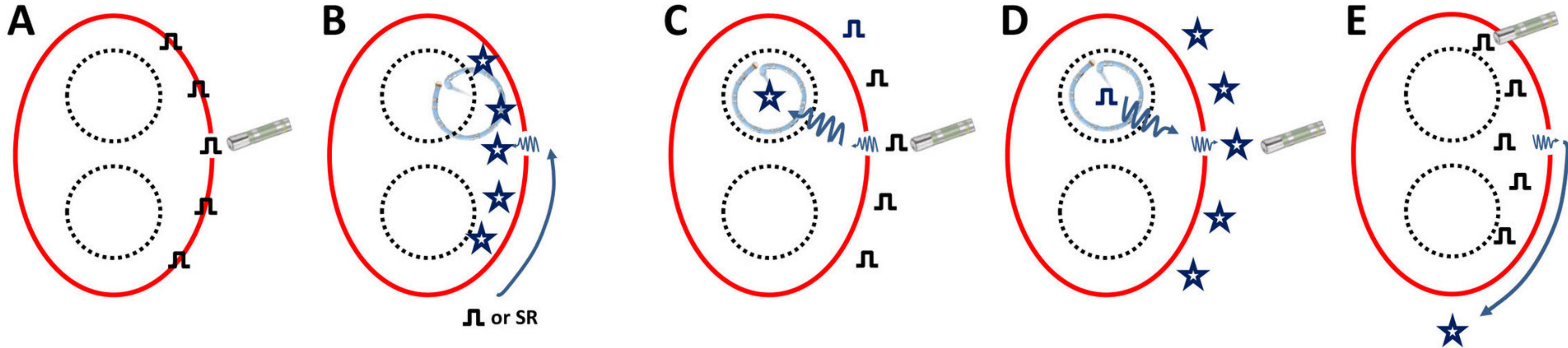
Figure 2: PV mapping during sinus rhythm or atrial pacing. In this patient, the coronary sinus is paced, and the left PVs are mapped using a CMC. A color-coded map (from white to purple) is performed using a 3D-mapping system. The earliest activation point inside the WACA line, from where the entire antral activation proceeds, is easily detected and color-coded in white. Adapted from Miyamoto et al.[39] CMC: Circular mapping catheter; PV: pulmonary vein; WACA: Wide antral circumferential ablation.

Figure 3: PV mapping during atrial pacing. Schemes showing different responses to pacing around the circumferential ablation lesions, and assumptions of gap localization. A. Superior and inferior PVs are arbitrarily separated into eight different zones (1-8). The CMC is positioned in the PV with the shortest atrio-PV activation time. In this example, the CMC is positioned in a superior PV. For the following panels, pacing applied around the lesions (red dots) and responses to pacing (activation delays and sequences) for each point are shown. B. Pattern A: the activation delays converge towards a single point where the delay is the shortest (49 ms), without any modification of the activation sequence; the presence of a single residual connection, in front of this pacing site, is assumed. C. Pattern B: the shortest activation delays converge towards two locations (41 and 51 ms), without any change in the activation sequence, indicating the presence of two close gaps. D. Pattern C: the activation delays converge towards two remote locations (38 and 36 ms), with a clear modification of the activation sequence recorded on the CMC, indicating the presence of two remote gaps. Adapted from Bacquelin et al.[33] CMC: Circular mapping catheter; Inf: inferior; Sup: superior; PV: Pulmonary vein; WACA: wide antral circumferential ablation.

Figure 4: Atrial mapping during PV pacing. Examples of maps obtained using the technique to detect gaps in a right and left WACA lesion set (left and right panel, respectively). The atrial side of the WACA line is mapped during PV pacing. A color-coded map (from white to blue) is performed using a 3D-mapping system. The earliest activation point outside the WACA line, from where the entire atrial activation proceeds, is easily detected and color-coded in white. Adapted from Salas et al.[34]

Figure 5: The escape mapping technique. The delay between pacing within the PV and the coronary sinus reference signal is noted and color-coded in a 3D-mapping system (from purple to red). The shortest PV to coronary sinus signal is depicted in purple, while pacing further inside PV antrum results in longer delays, depicted in blue to red. Since the reference is a clean coronary sinus signal, the error of asserting the annotation is reduced. Furthermore, a CMC is not required, and this technique can be performed with a single ablation catheter. Adapted from Yang et al.[41] CMC: Circular mapping catheter; PV: pulmonary vein.

Figure 6: High resolution mapping for gap detection. Example of an activation map of the entire atrium and PV antrum. The presence of a large gap in the posterior part of the right inferior PV is noted, while the anterior aspect of the right WACA line is isolated. PV: Pulmonary vein; WACA: Wide antral circumferential ablation.



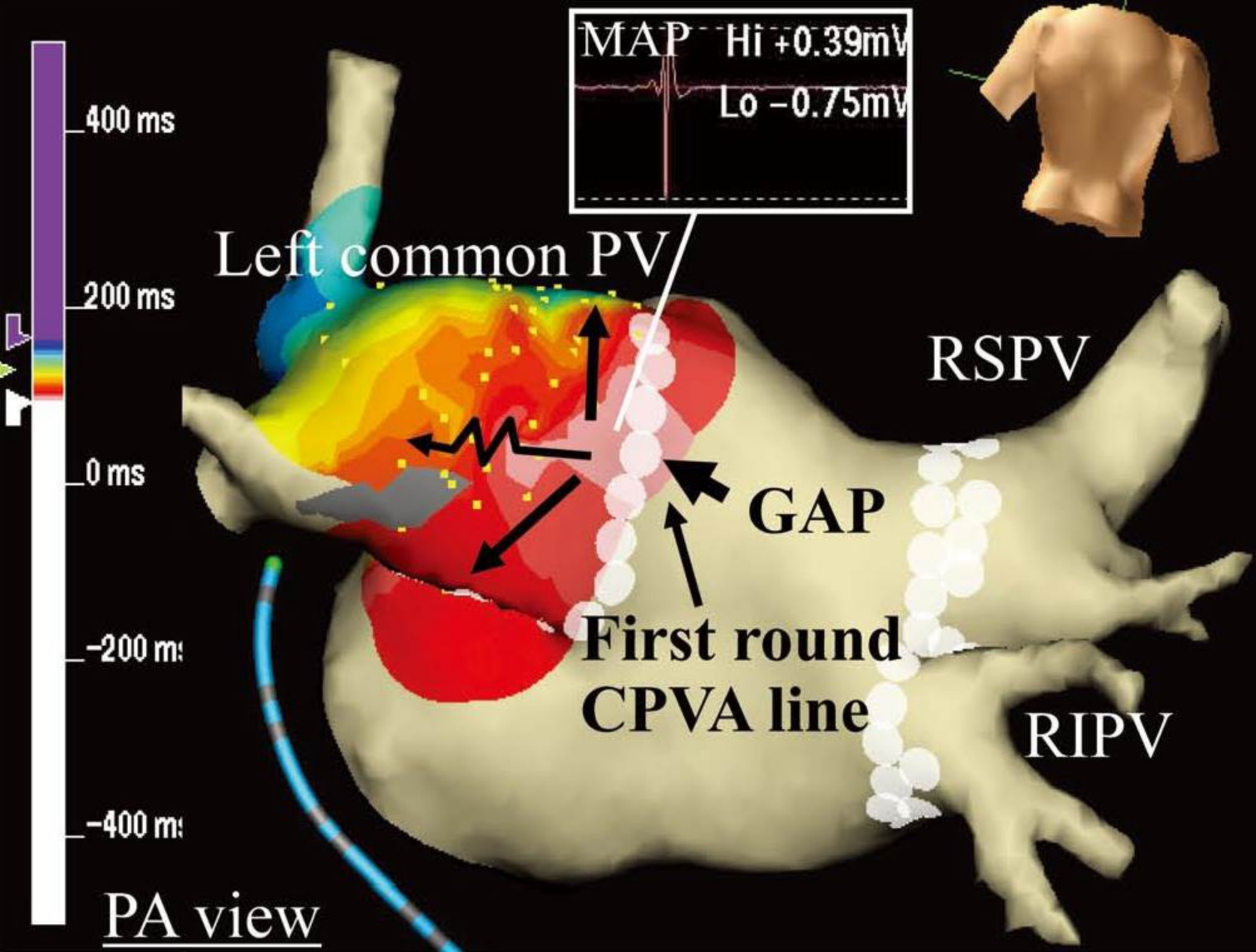
Pacing: along the WACA line
Capture → *ablation*
No capture → *no ablation*

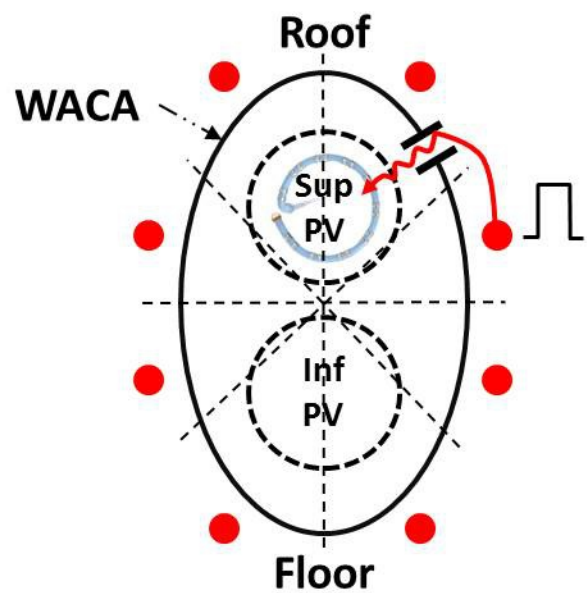
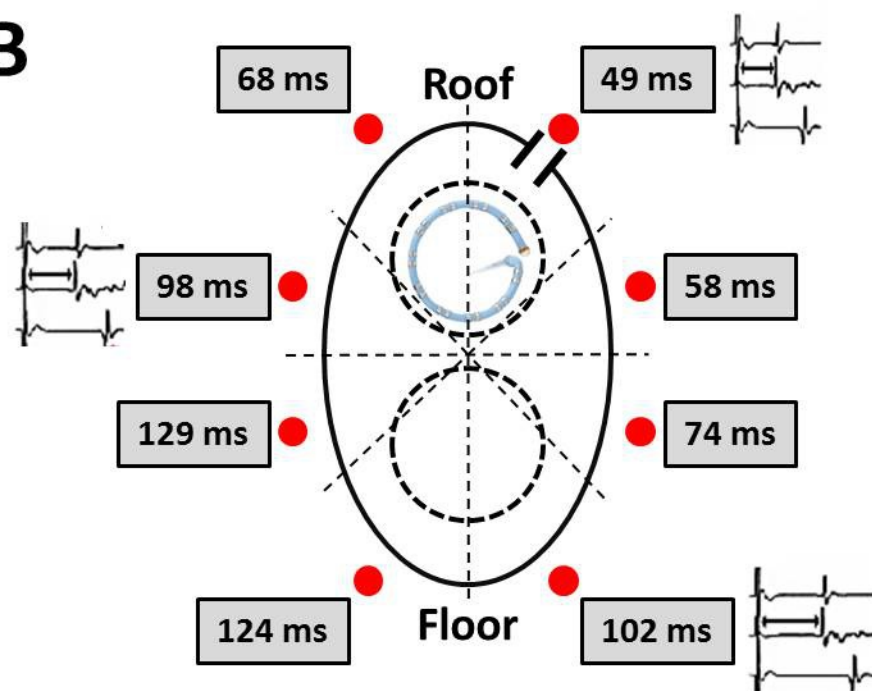
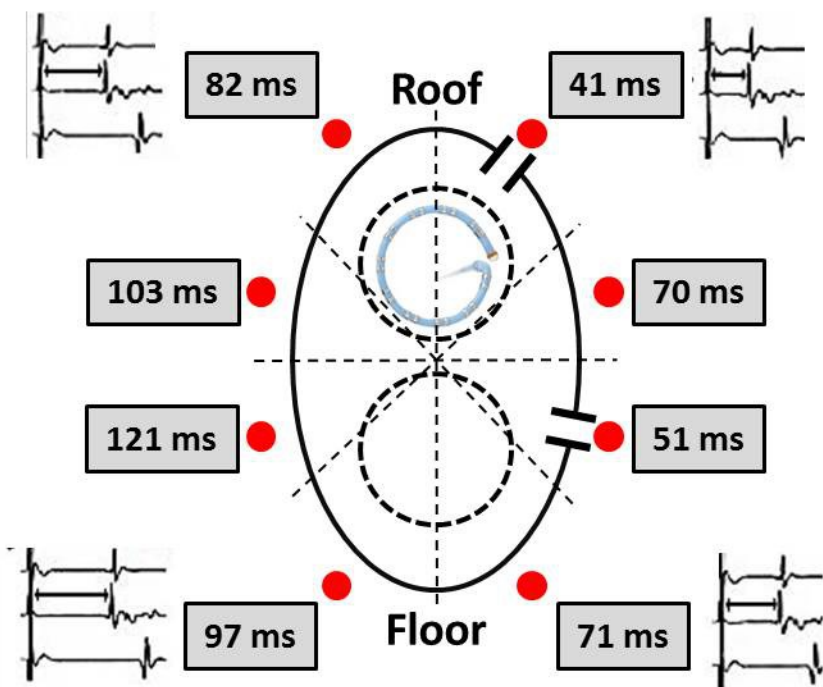
Pacing: CS (left PVs) or SR (right PVs)
Recording: inside the WACA line

Pacing: outside the WACA line
Recording: earliest PV potentials

Pacing: inside PV
Recording: earliest atrial signal

Pacing: inside the WACA line
Recording: CS signal



A**B****C****D**