



HAL
open science

Spinal dural arteriovenous fistulas clinical outcome after surgery versus embolization a retrospective study

Maxime Bretonnier, Pierre-Louis Henaux, Thomas Gaberel, Vincent Roualdes, Gaele Kerdiles, Pierre-Jean Le Reste, Xavier Morandi

► To cite this version:

Maxime Bretonnier, Pierre-Louis Henaux, Thomas Gaberel, Vincent Roualdes, Gaele Kerdiles, et al.. Spinal dural arteriovenous fistulas clinical outcome after surgery versus embolization a retrospective study. *World Neurosurgery*, 2019, 127, pp.e943-e949. 10.1016/j.wneu.2019.04.005 . hal-02119235

HAL Id: hal-02119235

<https://univ-rennes.hal.science/hal-02119235v1>

Submitted on 25 Oct 2021

HAL is a multi-disciplinary open access archive for the deposit and dissemination of scientific research documents, whether they are published or not. The documents may come from teaching and research institutions in France or abroad, or from public or private research centers.

L'archive ouverte pluridisciplinaire **HAL**, est destinée au dépôt et à la diffusion de documents scientifiques de niveau recherche, publiés ou non, émanant des établissements d'enseignement et de recherche français ou étrangers, des laboratoires publics ou privés.



Distributed under a Creative Commons Attribution - NonCommercial 4.0 International License

Spinal dural arteriovenous fistulas: clinical outcome after surgery versus embolization: a retrospective study

Running title: SDAVF: clinical outcome after surgery versus embolization

Maxime Bretonnier^{1,2}, Pierre-Louis Hénaux^{1,2}, Thomas Gaberel³, Vincent Roualdes⁴, Gaëlle Kerdiles⁵, Pierre-Jean Le Reste¹, Xavier Morandi^{1,2}

1 Department of Neurosurgery, Rennes University Hospital, 2, rue Henri Le Guilloux 35033 Rennes, Cedex 9, France

2 Univ Rennes, CHU Rennes, INSERM, LTSI - UMR 1099, F-35000 Rennes, France

3 Department of Neurosurgery, Caen University Hospital, Avenue de la Côte de Nacre, 14000 Caen, France

4 Department of Neurosurgery, Nord Laennec, Nantes University Hospital, Boulevard Professeur Jacques Monod 44800 Saint-Herblain, France

5 Department of Neurosurgery, Tours University Hospital, 2, Boulevard Tonnellé, 37000 Tours, France

Authors' e-mail address: maxime.bretonnier@chu-rennes.fr; pierre-louis.henaux@etudiant.univ-rennes1.fr; gaberel-t@chu-caen.fr; vincent.roualdes@chu-nantes.fr; gaelle.kerdiles@yahoo.fr; pierre-jean.le.reste@chu-rennes.fr; xavier.morandi@chu-rennes.fr

Correspondence should be addressed to:

Maxime Bretonnier, Service de Neurochirurgie, CHU Rennes, 2, rue Henri Le Guilloux, 35 033 Rennes Cedex 9, Email: maxime.bretonnier@chu-rennes.fr

Phone Number: + 33 2 99 28 42 77

Fax: + 33 2 99 28 41 80

Key words: clinical outcome; embolization; initial occlusion; late recurrence; spinal dural arteriovenous fistula; surgery

Abbreviations list: SDAVF: Spinal dural arteriovenous fistula; ALS: Aminoff-Logue Scale

Spinal dural arteriovenous fistulas: clinical outcome after surgery versus embolization: a retrospective study

Running title: SDAVF: clinical outcome after surgery versus embolization

Maxime Bretonnier^{1,2}, Pierre-Louis Hénaux^{1,2}, Thomas Gaberel³, Vincent Roualdes⁴, Gaëlle Kerdiles⁵, Pierre-Jean Le Reste¹, Xavier Morandi^{1,2}

1 Department of Neurosurgery, Rennes University Hospital, 2, rue Henri Le Guilloux 35033 Rennes, Cedex 9, France

2 Univ Rennes, CHU Rennes, INSERM, LTSI - UMR 1099, F-35000 Rennes, France

3 Department of Neurosurgery, Caen University Hospital, Avenue de la Côte de Nacre, 14000 Caen, France

4 Department of Neurosurgery, Nord Laennec, Nantes University Hospital, Boulevard Professeur Jacques Monod 44800 Saint-Herblain, France

5 Department of Neurosurgery, Tours University Hospital, 2, Boulevard Tonnellé, 37000 Tours, France

Authors' e-mail address: maxime.bretonnier@chu-rennes.fr; pierre-louis.henaux@etudiant.univ-rennes1.fr; gaberel-t@chu-caen.fr; vincent.roualdes@chu-nantes.fr; gaëlle.kerdiles@yahoo.fr; pierre-jean.le.reste@chu-rennes.fr; xavier.morandi@chu-rennes.fr

Correspondence should be addressed to:

Maxime Bretonnier, Service de Neurochirurgie, CHU Rennes, 2, rue Henri Le Guilloux, 35 033 Rennes Cedex 9, Email: maxime.bretonnier@chu-rennes.fr

Phone Number: + 33 2 99 28 42 77

Fax: + 33 2 99 28 41 80

Key words: clinical outcome; embolization; initial occlusion; late recurrence; spinal dural arteriovenous fistula; surgery

Abbreviations list: SDAVF: Spinal dural arteriovenous fistula; ALS: Aminoff-Logue Scale

Abstract

Objective: Spinal dural arteriovenous fistulas (SDAVFs) are rare vascular spinal malformations. According to the literature, surgery seems to result in better occlusion rates than endovascular treatment. However, the post-treatment evolution of neurological symptoms depending on the treatment remains unknown. The main objective of this study was to compare the clinical outcome for patients according to the method of treatment.

Methods: 63 patients with a SDAVFs from 4 academic neurosurgical departments were retrospectively included between 2000 and 2017. Preoperative and postoperative examination neurological status was assessed by the Aminoff-Logue Scale (ALS) which evaluates gait and micturition disturbances. Initial occlusion, late recurrence and complications of the two techniques were also reviewed.

Results: Patients treated by surgery and embolization improved clinically on the ALS ($P = 0.0009$) and there were no significant differences between the two techniques. Subgroup analysis showed that patients treated by surgery and embolization without late recurrence improved on the ALS ($P < 0.0001$ and $P = 0.0334$ respectively) and that patients who had a surgery or an embolization followed by a late recurrence did not improve. Initial occlusion rate was in favour of surgery with 91.3 % versus 70 % for endovascular treatment ($P = 0.050$). Late recurrence rate was higher for embolization, 21.4 % versus 9.1 % for surgery ($P = 0.28$).

Conclusions: Surgery can be proposed as a first-line treatment in SDAVFs after multidisciplinary discussion between neurosurgeons and neuroradiologists. Late recurrences negatively impact the neurological outcome of patients.

Introduction

Spinal dural arteriovenous fistulas (SDAVFs) are rare vascular malformations, yet they represent about 80 % of all spinal arteriovenous malformations.^{1,2} They are also referred to as type I spinal arteriovenous malformations.³ They are defined as direct arteriovenous shunts in the spinal dura mater between a segmental root artery and a peri-medullary vein.³ The high venous pressure leading to chronic hypoxia is presumed to be the cause of clinical symptoms.^{4,5,6} SDAVFs are commonly located at the thoracic and lumbar levels and are responsible for progressive myelopathies with progressive sensory and motor deficit of the lower limbs associated with sphincter disturbances.^{4,7} The etiology of SDAVFs is unknown but they are presumed to be an acquired pathology mainly affecting middle-aged men.¹ There is a male predominance with a sex ratio of almost 5:1.¹ SDAVFs is considered as a curable cause of myelopathy. However, neurological prognosis remains strongly dependent on the severity of pre-operative neurologic deficits and duration of symptoms before treatment.^{8,9,10} Furthermore, neurological deterioration can occur rapidly and the treatment should be carried out with minimum delay once the condition is diagnosed.^{8,9,10} SDAVFs treatment consists of interrupting the shunt between the artery and the vein either surgically or endovascularly. The main surgical difficulty is locating the origin of the shunting vein,¹¹ while the challenge of endovascular treatment is respecting medullary arteries during the catheterization.¹²

Initial failure and late recurrence rates for both treatments have been well studied.^{13,14} Recently, Bakker et al. showed the superiority of surgical treatment over endovascular treatment in initial occlusion and late recurrence rates in a meta-analysis of 1112 patients (initial definitive occlusion in 96.6% in the surgical group versus 72.2% in the embolization group and an odd-ratio of 3.15 for late recurrence in favour of surgery).¹⁵ Improvement of the neurological outcome after embolization and surgery has been shown by several studies.^{11,12,15,16,17} However, comparisons of the neurological outcome between the different

treatment methods were not assessed and further studies are needed to compare the neurological outcome between these two therapies.

The main objective of this study was to compare the clinical outcome of patients treated for a SDAVFs according to the treatment method (*i.e.* surgical or endovascular). Secondary objectives were to compare the failure rate, late recurrence rate and complication rate of the two treatments.

Material and methods

The STROBE guidelines were used to ensure the correct reporting of this observational study.¹⁸

We retrospectively reviewed the medical records of 63 consecutive patients with a SDAVFs treated in 4 academic neurosurgical departments (University Hospitals of Rennes, Nantes, Caen, Tours) between 2000 and 2017. Inclusion criteria were: patients treated for a SDAVFs either surgically or endovascularly. Exclusion criteria were: short term follow up (<6 months), SDAVFs that were not treated. Data collection was done by first author from June to September 2018.

Clinical data

Age at diagnosis, gender, medical history, symptoms and diagnostic delay were collected for each patient. The neurological status was assessed using the Aminoff-Logue Scale (ALS) (Table 1).⁷ This scale evaluates gait (G score) and micturition (M score) disturbances. Pre-operative ALS (G+M score) and ALS at last medical examination were retrospectively calculated.

Radiological data

Height of intramedullary hyperintensity on T2-weighted MRI was measured using the corresponding number of vertebral bodies. Arterial(s) feeder(s) on spinal arteriography were noted for each SDAVFs.

Treatment

Treatment method of SDAVFs, initial success of treatment, late recurrence and complications were reviewed. Late recurrence was defined as a symptomatic re-opening of the fistula after an initial successful exclusion. Multidisciplinary discussion between neurosurgeons and neuroradiologists were carried out for 40 patients. The surgical procedure consisted in a uni- or bilateral laminectomy centred on the arteriovenous shunt, opening of the dura and exclusion of the fistula at the origin of the draining vein. Endovascular treatment was excluded if arterial feeders of the SDAVFs were too small to catheterize or if it shared a common origin with the artery of Adamkiewicz. Groups were defined by the first successful treatment realized for the SDAVF. Patients who had surgery after an initial failed embolization attempt were included in the surgical group. Patients who had a failed surgery were included in the surgery group for one patient and in the embolization group for the other according to the first successful treatment.

Primary endpoint

The primary objective of the study was to compare neurological evolution between patients initially treated by surgery and those initially treated by embolization. Neurological outcome was evaluated by the difference between the pre-treatment ALS and the last examination ALS.

Secondary endpoints

Secondary endpoints were comparisons of the initial failure rate, the late recurrence rate and the complication rate between surgical and endovascular treatment. Further analyses

compared the clinical evolution assessed by pre-treatment and last examination ALS between 4 sub-groups of patients: surgery without late recurrence, embolization without late recurrence, surgery with late recurrence, embolization with late recurrence. Lastly, an intention-to-treat analysis was realized, the clinical outcome was compared between two groups according to the first treatment attempted whether it enabled the occlusion of the SDAVF or not.

Statistical analysis

SAS® v.9.4 (SAS Institute, Cary, NC, USA) was used. Descriptive statistics were used for age, gender, delay of diagnosis, height of intramedullary T2 hyperintensity, pre-treatment and last examination ALS, length of hospital stay, follow-up time. Differences were researched between patients initially treated by surgery or by embolization. Linear mixed models were used for the primary objective, for the intention-to-treat analysis and for comparisons of subgroups. Comparisons between pre-treatment and last examination ALS for each subgroup were made using the Tukey Test. The Chi-square test was used for comparisons of initial failure rate and the Fisher test for comparisons of late recurrence rate between the surgical and embolization groups. The significance threshold was set at $P \leq 0.05$.

Ethical approval

This study was reviewed and approved by the ethics committee of our institution (Notice n°18.25).

Results

Patient characteristics

The flow chart of the 63 patients (Figure 1) represents the treatment methods, initial success/failure and late recurrences.

A total of 45 surgical procedures were performed: 23 as an initial treatment, 12 after an initial failed embolization attempt, 3 after a late recurrence after surgery, 5 after a late recurrence after embolization, 2 after a failed surgery.

A total of 42 endovascular procedures were carried out. There were 12 initial failed procedures. 30 resulted in successful embolizations, 28 as an initial treatment, 1 after a late recurrence after embolization, 1 after a failed surgery. Successful embolization was defined as the closure of the arteriovenous shunt at the end of the procedure.

Patient characteristics of the surgical and embolization groups are shown in Table 2. Comparisons of each variable between the 2 groups were made. Mean follow-up time was 34.3 months in the embolization group and 21.7 months in the surgery group (no statistical difference). Heights of intramedullary T2 hyperintensity were significantly higher in the surgery group ($P = 0.0023$) but there was no significant difference for the pre-treatment neurological status assessed by ALS between the two groups. Length of hospital stay was significantly shorter in the embolization group (3.9 days versus 9.6; $P < 0.0001$).

Clinical outcome of patients treated for a SDAVFs according to the treatment method

Mean pre-treatment ALS in the surgery group was 5.3 and mean last examination ALS was 3.9. Mean pre-treatment ALS in the embolization group was 4.8 and mean last examination ALS was 4.1. There was a significant improvement of the ALS between pre-treatment and last examination ALS ($P = 0.0009$) but there were no differences in improvements between the surgery and embolization groups ($P = 0.746$).

Further analyses were made for the G score and the M score. Mean pre-treatment and mean last examination G score were respectively 3.6 and 2.5 in the surgery group and 3.2 and 2.5 in the embolization group. The G score improved significantly in the 2 groups of treatment ($P < 0.0001$) but there was no difference when the 2 treatments were compared ($P =$

0.450). Mean pre-treatment and mean last examination M score were respectively 1.6 and 1.4 in the surgery group and 1.5 and 1.3 in the embolization group. M score did not improve significantly after the treatment either in the surgery or embolization group and there was no difference between the 2 groups of treatment ($P = 0.104$ and $P = 0.611$, respectively).

Intention to treat analysis

There were no significant differences in clinical improvement between groups when we compared the 40 patients for whom an embolization was attempted to the 23 patients for whom a surgery was attempted.

Comparisons of clinical outcome for patient subgroups according to late recurrences

Comparisons were made between 4 patient subgroups: patients treated by surgery without late recurrence, embolization without late recurrence, surgery with late recurrence, embolization with late recurrence (Table 3).

Patients with late recurrence had not clinically improved on the ALS when the pre-treatment ALS and last examination ALS were compared. ALS and G score had significantly improved in patients treated by surgery and embolization without late recurrence, M score had significantly improved in patients treated by embolization without late recurrence.

The clinical and radiological characteristics of patients with late recurrence are shown in Table 4. The recurrence was diagnosed after a spinal arteriography. The neurological symptoms worsened for 3 patients after the initial treatment, there was an initial improvement for 3 patients and stability for 4 patients. The recurrence was caused by recanalization of the same SDAVF for 8 patients (7 after an embolization, one after a surgical procedure). The recurrence was caused by a new SDAVF for 2 patients initially treated by surgery. For 2 patients, the definitive occlusion of the SDAVF was not performed: therapeutic abstention

was decided on after discussion between neurosurgeons and neuroradiologists because of the general condition of the patient (patients 8 and 10).

Initial failure rate, late recurrence rate and complications of surgery and embolization

An initial failure occurred in 14 patients out of 63: 12/40 when initial embolization was attempted (30 %), 2/23 when initial surgery was attempted (8.7 %) (Chi-square test, $P = 0.050$). Failure of embolization was caused by the impossibility of performing a selective catheterization of the arterial feeders of the SDAVF for the 12 patients. Failure of surgery was caused by an error of vertebral level in the 2 patients. A late recurrence occurred in 6 patients out of 28 after successful embolization (21.4 %) and in 3 patients out of 33 after a successful surgical procedure (9.1%) (no significant difference, Fisher test $P = 0.28$). One patient had a recurrence after both treatments.

A total of 45 surgical procedures were performed with 4 complications (8,9 %): epidural hematoma in 2 cases, cerebrospinal fluid leakage in 1 case and post-operative wound infection in 1 case. A revision surgery was necessary for all 4 patients. A patient with an epidural hematoma had a worsening of neurological symptoms which persisted until last examination (severe complication rate of 2.2 %). The other patients had no permanent worsening of symptoms. A total of 42 endovascular procedures were performed, one complication occurred (2.4 %): a medullary ischemia responsible for a permanent worsening of the neurological symptoms.

Discussion

Comparisons of clinical evolution between surgery and embolization showed no statistical differences with an improvement in both groups after treatment. Recurrence of the SDAVF was a factor of poor prognosis: patients treated by surgery or embolization without late recurrence showed a clinical improvement whereas those who had a late recurrence did

not. Indeed, late recurrence and iterative treatments cause a therapeutic delay leading to a worsening of the symptoms.

Our study also showed that surgery was superior to embolization when considering the initial occlusion rate (91.3 % versus 70 %) and late recurrence rate (9.1 % versus 21.4 %). The overall re-operation rate was 14.3% after initial surgery and 45% after initial embolization. This finding is consistent with the previous literature. A recent meta-analysis observed an initial definitive occlusion in 96.6% in the surgical group versus 72.2% in the embolization group ($P < 0.001$) and an odd-ratio of 3.15 for late recurrence in favour of surgery.¹⁵ However, this meta-analysis included few studies comparing surgery and embolization and, in most cases, comparative studies included few patients (mean of 37 patients). Two comparative studies included a large number of patients. In 2010, Hessler et al.¹⁹ reported the initial exclusion rate of 156 SDAVFs from 1980 to 2008. They found an initial failure rate of 8/54 for surgery and 21/102 for embolization. The mean follow-up was short (4.6 months) and late recurrence rate was not assessed. In 2013, Kirsch et al.¹² published a study of 78 patients with a SDAVFs treated from 1992 to 2012, the endovascular treatment being attempted for all patients if possible. Sixty-one were actually embolized with a 23 % failure rate and one patient had spinal ischemia causing permanent paraparesis. The previously cited studies included patients treated before 2000. Since then, embolization technique has improved and occlusion rates are better with the use of liquid embolization agents.^{12-15,19} However, our study included patients treated recently between 2000 and 2017, and surgical treatment was still superior to embolization.

These results suggest that surgery could be proposed as a first-line treatment because it appears to be more efficient than embolization in achieving a permanent occlusion using a single procedure. Indeed, embolization has a higher late recurrence rate than surgery and we showed that patients with a recurrence had a worse neurological prognosis.

Pre-treatment intramedullary T2 hyperintensity was different between the surgery and embolization groups, 6.9 and 5 vertebral bodies, respectively. However, there was no statistical difference of pre-operative ALS between surgery and embolization so this imaging difference had no clinical significance.

In our study, one complication occurred in the embolization group with a medullary ischemia (complication rate of 2.4%). Four complications occurred in the surgery group: 2 epidural hematomas, 1 infection, 1 CSF leakage. The overall complication rate was 8.9 % which was higher than that of other studies.^{8,17} However, when considering severe complications that caused a permanent neurological worsening, these concerned one patient in the surgery group (severe complication rate of 2.2 %) and one in the embolization group (severe complication rate of 2.4 %). Therefore, complication rate should not present an obstacle for the choice of surgery.

The main surgical difficulty is localizing the origin of the draining vein as the remainder of the surgical procedure is straightforward. Surgical technique has improved in recent years, which has raised the occlusion rate and decreased the risk of complications. Operating microscopes have been perfected with fluorescence modules. The use of indocyanine green or fluorescein has been proved to be useful in vascular neurosurgery.²⁰⁻²² They can be used in the same way for confirmation of the angioarchitecture of the SDAVFs and to verify its occlusion at the end of the procedure.^{23,24} Furthermore, some authors have reported that pre-operative identification of the level of the SDAVF can be carried out by placing a coil in the feeding artery during the pre-operative spinal arteriography. This technique appears to decrease the risk of error of vertebral level.²⁵ Finally, mini-invasive technique with limited surgical exposure could reduce the risk of infection and decrease the length of hospital stay.²⁶

Our study has some limitations. The patient sample was small due to the rarity of this pathology. For this reason, we did not compare recurrence rates of each embolization agents because this would have implied comparing small subgroups of patients. However, to date, it is one of the larger comparative studies in the literature. Our clinical endpoint (ALS) was calculated retrospectively which was a potential bias, however the ALS is simple and easy to use retrospectively.

Conclusions

The clinical outcome for patients is highly dependent on the severity of pre-treatment neurological deficits, so the delay between the suspicion of SDAVFs and effective treatment should be minimal. A failed embolization or surgery attempt or a late recurrence could extend this delay and have a negative impact on the neurological outcome for patients. Surgery may be proposed as a first-line treatment in SDAVFs after multidisciplinary discussion between neurosurgeons and neuroradiologists because of a higher initial occlusion rate, a lower late recurrence rate and no added severe morbidity.

Declaration of interest: The authors declare no conflict of interest.

Funding sources This research did not receive any specific grant from funding agencies in the public, commercial, or not-for-profit sectors.

Acknowledgements The authors thank Estelle Le Pabic for her help with the statistical analysis and Deirdre McKeown for revising the English style.

References

1. Jellema K, Tijssen CC, van Gijn J. Spinal dural arteriovenous fistulas: a congestive myelopathy that initially mimics a peripheral nerve disorder. *Brain*. 2006;129:3150-3164. <https://doi.org/10.1093/brain/awl220>.
2. Rosenblum B, Oldfield EH, Doppman JL, Di Chiro G. Spinal arteriovenous

malformations: a comparison of dural arteriovenous fistulas and intradural AVM's in 81 patients. *J Neurosurg.* 1987;67:795-802. <https://doi.org/10.3171/jns.1987.67.6.0795>.

3. Kim LJ, Spetzler RF. Classification and Surgical Management of Spinal Arteriovenous Lesions: Arteriovenous Fistulae and Arteriovenous Malformations. *Neurosurgery.* 2006;59:195-201. <https://doi.org/10.1227/01.NEU.0000237335.82234.CE>.
4. Aminoff MJ, Barnard RO, Logue V. The pathophysiology of spinal vascular malformations. *J Neurol Sci.* 1974;23:255-263. [https://doi.org/10.1016/0022-510X\(74\)90229-9](https://doi.org/10.1016/0022-510X(74)90229-9).
5. Kendall BE, Logue V. Spinal epidural angiomatous malformations draining into intrathecal veins. *Neuroradiology.* 1977;13:181-189. <https://doi.org/10.1007/BF00344211>.
6. Hassler W, Thron A, Grote EH. Hemodynamics of spinal dural arteriovenous fistulas. An intraoperative study. *J Neurosurg.* 1989;70:360-370. <https://doi.org/10.3171/jns.1989.70.3.0360>.
7. Aminoff MJ, Logue V. Clinical features of spinal vascular malformations. *Brain.* 1974;97:197-210. <https://doi.org/10.1093/brain/97.1.197>.
8. Cenzato M, Debernardi A, Stefini R, D'Aliberti G, Piparo M, Talamonti G et al. Spinal dural arteriovenous fistulas: outcome and prognostic factors. *Neurosurg Focus.* 2012;32:E11. <https://doi.org/10.3171/2012.2.FOCUS1218>.
9. Nagata S, Morioka T, Natori Y, Matsukado K, Sasaki T, Yamada T. Factors that affect the surgical outcomes of spinal dural arteriovenous fistulas. *Surg Neurol.* 2006;65:563-568. <https://doi.org/10.1016/j.surneu.2005.09.018>.
10. Muralidharan R, Mandrekar J, Lanzino G, Atkinson JL, Rabinstein AA. Prognostic value of clinical and radiological signs in the postoperative outcome of spinal dural arteriovenous fistula. *Spine.* 2013;14:1188-1193.

<https://doi.org/10.1097/BRS.0b013e31828b2e10>.

11. Ropper AE, Gross BA, Du R. Surgical treatment of Type I spinal dural arteriovenous fistulas. *Neurosurg Focus*. 2012;32:E3. <https://doi.org/10.3171/2012.1.FOCUS11344>.
12. Kirsch M, Berg-Dammer E, Musahl C, Bätzner H, Kühne D, Henkes H. Endovascular management of spinal dural arteriovenous fistulas in 78 patients. *Neuroradiology*. 2013;55:337-343. <https://doi.org/10.1007/s00234-013-1134-0>.
13. Steinmetz MP, Chow MM, Krishnaney AA, Andrews-Hinders D, Benzel EC, Masaryk TJ, et al. Outcome after the treatment of spinal dural arteriovenous fistulae: a contemporary single-institution series and meta-analysis. *Neurosurgery*. 2004;55:77-87. <https://doi.org/10.1227/01.NEU.0000126878.95006.0F>.
14. Van Dijk JM, TerBrugge KG, Willinsky RA, Farb RI, Wallace MC. Multidisciplinary management of spinal dural arteriovenous fistulas: clinical presentation and long-term follow-up in 49 patients. *Stroke*. 2002;33:1578-1583. <https://doi.org/10.1161/01.STR.0000018009.83713.06>.
15. Bakker NA, Uyttenboogaart M, Luijckx GJ, Eshghi OS, Mazuri A, Metzemaekers JDM, et al. Recurrence Rates After Surgical or Endovascular Treatment of Spinal Dural Arteriovenous Fistulas: A Meta-analysis. *Neurosurgery*. 2015;77:137-144. <https://doi.org/10.1227/NEU.0000000000000727>.
16. Gemmete JJ, Chaudhary N, Elias AE, Toma AK, Pandey AS, Parker RA et al. Spinal dural arteriovenous fistulas: clinical experience with endovascular treatment as primary therapy at 2 academic referral centers. *AJNR Am J Neuroradiol*. 2013;34:1974-1979. <https://doi.org/10.3174/ajnr.A3522>.
17. Saladino A, Atkinson JL, Rabinstein AA, Piepgras DG, Krauss WE, Kaufmann TJ et al. Surgical treatment of spinal dural arteriovenous fistulae: a consecutive series of 154 patients. *Neurosurgery*. 2010;67:1350-1357.

<https://doi.org/10.1227/NEU.0b013e3181ef2821>.

18. Von Elm E, Altman DG, Egger M, Pocock SJ, Gøtzsche PC, Vandenbroucke JP; STROBE Initiative. The Strengthening the Reporting of Observational Studies in Epidemiology (STROBE) statement: guidelines for reporting observational studies. *Lancet*. 2007;370.:1453-1457. [https://doi.org/10.1016/S0140-6736\(07\)61602-X](https://doi.org/10.1016/S0140-6736(07)61602-X).
19. Hessler C, Regelsberger J, Grzyska U, Illies T, Zeumer H, Westphal M. Therapeutic clues in spinal dural arteriovenous fistulas: a 30 year experience of 156 cases. *Cent Eur Neurosurg*. 2010;71:8-12. <https://doi.org/10.1055/s-0029-1224195>.
20. Zaidi HA, Abla AA, Nakaji P, Chowdhry SA, Albuquerque FC, Spetzler RF. Indocyanine green angiography in the surgical management of cerebral arteriovenous malformations: lessons learned in 130 consecutive cases. *Neurosurgery*. 2014;10:246-251. <https://doi.org/10.1227/NEU.0000000000000318>.
21. Raabe A, Beck J, Gerlach R, Zimmermann M, Seifert V. Near-infrared indocyanine green video angiography: a new method for intraoperative assessment of vascular flow. *Neurosurgery*. 2003;52:132-139. <https://doi.org/10.1227/0006123-200301000-00017>.
22. Bretonnier M, Henaux PL, Morandi X, Le Reste PJ. Fluorescein-guided resection of brain arteriovenous malformations: A short series. *J Clin Neurosci*. 2018;52:37-40. <https://doi.org/10.1016/j.jocn.2018.02.015>.
23. Schuette AJ, Cawley CM, Barrow DL. Indocyanine green videoangiography in the management of dural arteriovenous fistulae. *Neurosurgery*. 2010;67:658-662. <https://doi.org/10.1227/01.NEU.0000374721.84406.7F>.
24. Spiotta AM, Bain M, Moskowitz S. Intraoperative indocyanine green angiography as a substitute for conventional angiography in the surgical management of spinal dural arteriovenous fistulae. *J Neurointerv Surg*. 2011;3:182-185. <https://doi.org/10.1136/jnis.2010.003210>.

- 25.** Marquardt G, Berkefeld J, Seifert V, Gerlach R. Preoperative coil marking to facilitate intraoperative localization of spinal dural arteriovenous fistulas. *Eur Spine J.* 2009;18:1117-1120. <https://doi.org/10.1007/s00586-009-0946-4>.
- 26.** Patel NP, Birch BD, Lyons MK, DeMent SE, Elbert GA. Minimally invasive intradural spinal dural arteriovenous fistula ligation. *World Neurosurg.* 2013;80:267-270. <https://doi.org/10.1016/j.wneu.2012.04.003>.

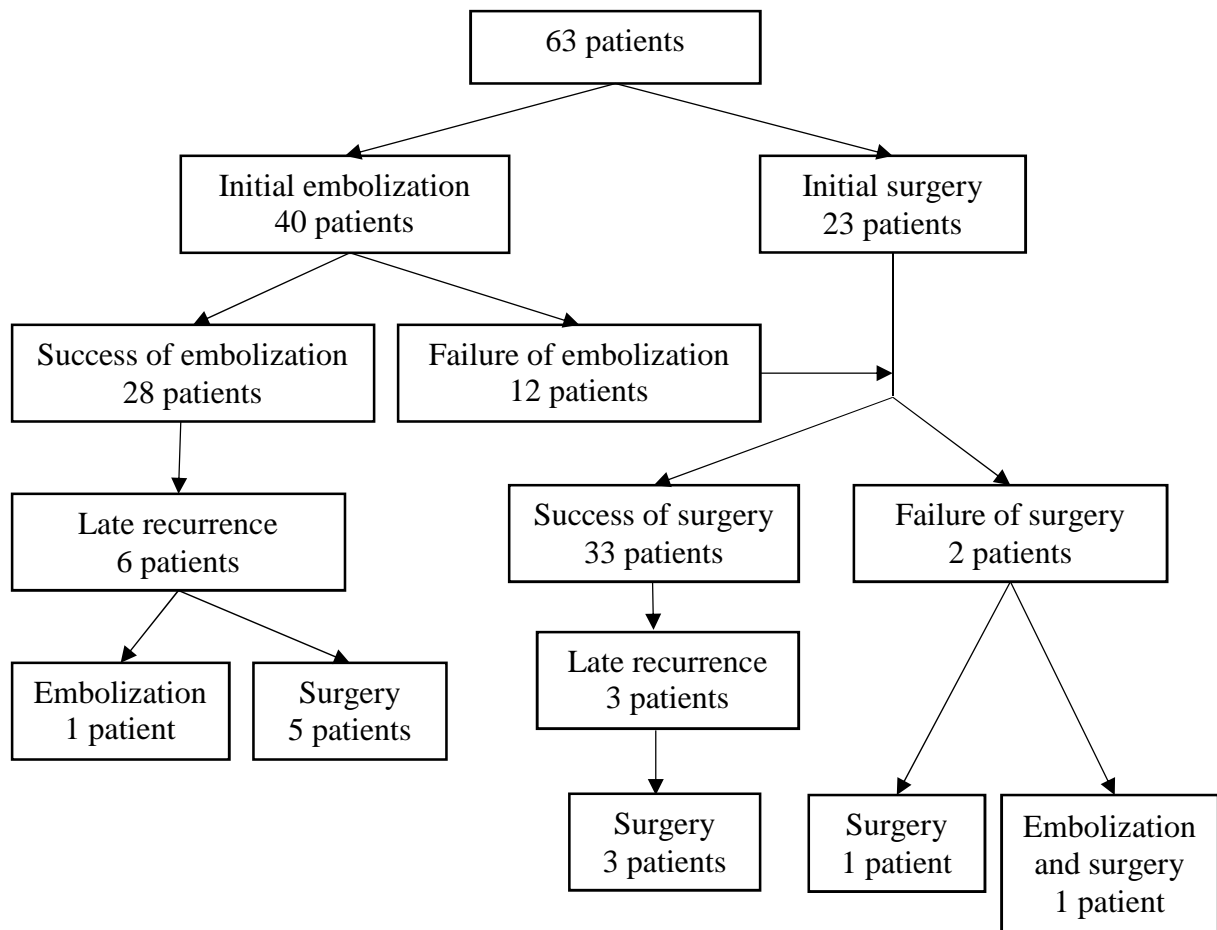


Figure 1. Flow chart of the 63 patients treated for a SDAVFs

Table 1. Aminoff-Logue Scale⁷

Gait (G)	Micturition (M)
G0 Normal	M0 Normal
G1 Leg weakness, abnormal gait or stance, but no restriction of activity	M1 Hesitancy, frequency, urgency
G2 Restricted activity	M2 Occasional urinary incontinence or retention
G3 Requiring one stick for walking	M3 Total incontinence or persistent retention
G4 Requiring two sticks, crutches or walker	
G5 Confined to wheelchair	
G Score	M score
G+M score	

Table 2. Comparisons of variables between surgery and embolization groups

Variables	Embolization (29 patients)	Surgery (34 patients)	<i>P</i>
	Mean ± SD	Mean ± SD	
Age	63.0 ± 9.2	65.7 ± 9.1	0.247 (S)
Sex	Female	5 (14.7 %)	0.0662 (K)
	Male	29 (85.3 %)	
Delay of diagnosis (months)	14.4 ± 12.3	16.0 ± 15.5	0.872 (W)
Height of T2 hyperintensity	5.0 ± 2.3 *	6.9 ± 2.2 *	0.0023* (S)
Pre-treatment G+M score	4.8 ± 2.3	5.3 ± 2.2	0.380 (S)
Pre-treatment G score	3.2 ± 1.5	3.6 ± 1.5	0.261 (W)
Pre-treatment M score	1.5 ± 1.1	1.6 ± 1.2	0.781 (S)
Last follow-up G+M score	4.1 ± 2.5	3.9 ± 2.6	0.810 (S)
Last follow-up G score	2.5 ± 1.7	2.5 ± 1.7	0.882 (S)
Last follow-up M score	1.3 ± 1.1	1.4 ± 1.3	0.538 (S)
Length of hospital stay (days)	3.9 ± 3.1 *	9.6 ± 7.3 *	<0.0001* (W)
Follow-up time (months)	34.3 ± 32.6	21.7 ± 25.1	0.0908 (W)

* statistical significance at $P < 0.05$

SD: Standard deviation; S: Student test; K: Chi-square test; W: Wilcoxon-Mann-Whitney test

Table 3. Improvement on ALS, G score and M score for each subgroup using Tukey Test

Subgroup	Improvement on ALS <i>P</i> value	Improvement on G score <i>P</i> value	Improvement on M score <i>P</i> value
Surgery without late recurrence	1.733 * <i>P</i> < 0.0001	1.367 * <i>P</i> < 0.0001	0.367 <i>P</i> = 0.052
Embolization without late recurrence	1.048 * <i>P</i> = 0.0334	0.952 * <i>P</i> = 0.0009	0.476 * <i>P</i> = 0.035
Surgery with late recurrence	-1.000 <i>P</i> = 0.526	1.11E-16 <i>P</i> = 1.000	-1.000 <i>P</i> = 0.169
Embolization with late recurrence	-0.778 <i>P</i> = 0.297	-0.222 <i>P</i> = 0.601	-0.556 <i>P</i> = 0.106

* statistical significance at *P* < 0.05

Table 4. Clinical and radiological characteristics of patients with a late recurrence

Patient, Age, Gender	Comorbidity	Initial ALS†	Arterial feeder(s)	Initial treatment/ Success or failure	Clinical evolution	Diagnostic delay of recurrence (months)	Cause of recurrence	Last examination ALS†
1/ Female	69, 0	3 (3/0)	Left T7 and left T8	Embolization/ Success	Stability	2	Recanalization	3 (3/0)
2/ Male	70, Arteritis, bipolar disorder, prostatic adenocarcinoma	6 (4/2)	Left T12	Embolization/ Success	Improvement (ALS 4)	12	Recanalization	6 (3/3)
3/ Female	64, Spina bifida	6 (5/1)	Left L4	Embolization/ Success	Stability	3	Recanalization	7 (5/2)
4/ Male	63, Active smoking	3 (1/2)	Right T6	Embolization/ Success	Worsening (ALS 6)	6	Recanalization	3 (2/1)
5/ Female	62, 0	7 (5/2)	Right T11	Embolization/ Success	Stability	3	Recanalization	5 (4/1)
6/ Female	62, 0	4 (3/1)	Left T8	Embolization/ Success	Worsening (ALS 7)	2	Recanalization	7 (4/3)
7/ Male	64, Type 2 diabetes, high blood pressure	2 (2/0)	Left T12	Embolization/ Failure, treated by surgery	Worsening (ALS 6)	4	Recanalization	5 (2/3)
8/ Male *	80, Chronic obstructive pulmonary disease, high blood pressure, dyslipidaemia	7 (4/3)	Left T10	Embolization/ Failure, treated by surgery	Improvement (ALS 5)	5	New SDAVF Left T9	8 (5/3)
9/ Male	59, High blood pressure	8 (5/3)	Right L1	Surgery/ Success	Improvement (ALS 4)	14	New SDAVF Left T0	3 (1/2)
10/ Male *	53, Myocardial infarction	0	Right T10	Surgery/ Failure, treated by embolization	Stability	19	Recanalization	8 (5/3)

* patients for whom SDAVF was not efficiently occluded at the end of the follow up; † ALS corresponds to the G+M score (G score/M score)