



The Lipo-Body Lift Operative Technique

Nicolas Bertheuil, Benoit Chaput, Damien Bergeat, Christophe Morvan,
Camille Mocquard, Eric Watier

► To cite this version:

Nicolas Bertheuil, Benoit Chaput, Damien Bergeat, Christophe Morvan, Camille Mocquard, et al..
The Lipo-Body Lift Operative Technique. Plastic and Reconstructive Surgery, Global Open, 2019, 7
(2), pp.e2156. 10.1097/GOX.0000000000002156 . hal-02090918

HAL Id: hal-02090918

<https://univ-rennes.hal.science/hal-02090918>

Submitted on 10 Jul 2020

HAL is a multi-disciplinary open access archive for the deposit and dissemination of scientific research documents, whether they are published or not. The documents may come from teaching and research institutions in France or abroad, or from public or private research centers.

L'archive ouverte pluridisciplinaire **HAL**, est destinée au dépôt et à la diffusion de documents scientifiques de niveau recherche, publiés ou non, émanant des établissements d'enseignement et de recherche français ou étrangers, des laboratoires publics ou privés.

The Lipo-Body Lift: Operative Technique

Nicolas Bertheuil, MD, PhD*†§; Benoit Chaput, MD, PhD§¶; Damien Bergeat, MD||; Christophe Morvan*; Camille Mocquard, MD*; Eric Watier, MD, PhD*

Summary: Bariatric surgery induces massive weight loss, which results in global and complex skin deformities. Lower body lift procedure has become the gold standard for lower trunk reconstruction. The authors describe in this video the lipo-body lift technique in detail. The video is divided into 4 parts: part 1, indications and preoperative markings; part 2, posterior contouring; part 3, anterior contouring; and part 4, preoperative and postoperative results. Patient selection and technical key points of the technique are discussed. The lipo-body lift method is an important component of reconstructive strategies and should be widely offered to patients who experienced massive weight loss.

Bariatric surgery induces massive weight loss that results in global and complex skin deformities. Lower body lift procedure has become the gold standard for the lower trunk reconstruction. Our team has previously described a new procedure for circumferential contouring of the abdomen: the lipo-body lift. In this video, the senior author (N.B.) relates his personal technique with the key steps to obtain a safe and reproducible result.

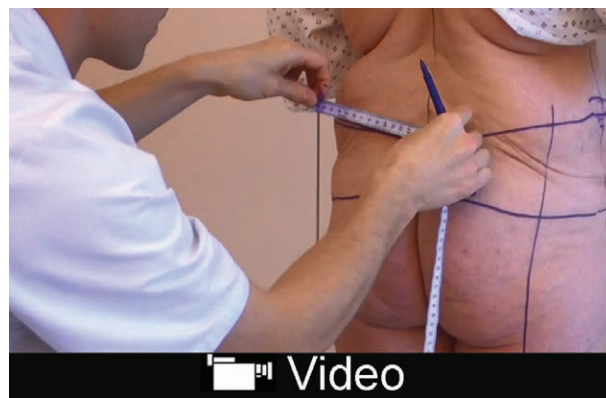PART 1: INDICATIONS AND PREOPERATIVE MARKING

In the authors' experience, following massive weight loss patients have complex and variable deformities, which can be divided into 3 groups as previously reported.¹ Ideal candidates are type 1 and 2 patients, and type 3 should preferentially be treated with a traditional tech-

*From the *Department of Plastic, Reconstructive and Aesthetic Surgery, Hospital Sud, University of Rennes 1, Rennes, France; †INSERM U1236, University of Rennes 1, Rennes, France; ‡SITI Laboratory Rennes University Hospital, Rennes, France; §STROMalab, UMR5273 CNRS/UPS/EFS - INSERM U1031, Rangueil Hospital, Toulouse, France; ¶Department of Plastic, Reconstructive and Aesthetic Surgery, Rangueil Hospital, Toulouse, France; and ||Department of Digestive Surgery, Rennes University Hospital, Rennes, France.*

Received for publication November 16, 2018; accepted December 19, 2018.

Copyright © 2019 The Authors. Published by Wolters Kluwer Health, Inc. on behalf of The American Society of Plastic Surgeons. This is an open-access article distributed under the terms of the Creative Commons Attribution-Non Commercial-No Derivatives License 4.0 (CCBY-NC-ND), where it is permissible to download and share the work provided it is properly cited. The work cannot be changed in any way or used commercially without permission from the journal. *Plast Reconstr Surg Glob Open* 2019;7:e;2156 doi:10.1097/GOX.0000000000002156; Published online 25 February 2019.



Video Graphic 1. See video, Supplemental Digital Content 1, which displays indications and markings. This video is available in the “Related Videos” section of the Full-Text article on PRSGlobalOpen.com or available at <http://links.lww.com/PRSGO/A995>.

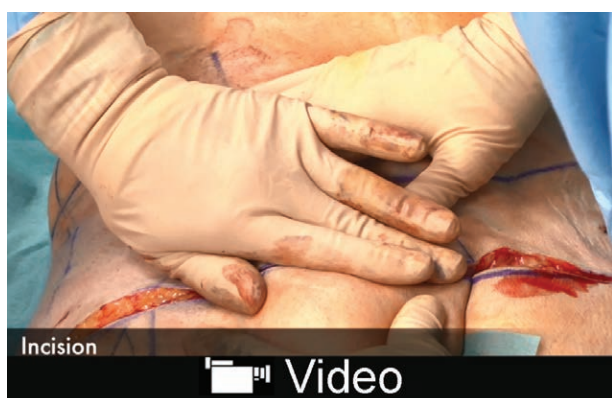nique. Briefly, type 1 patients exhibit only an excess of deflated skin with generally a normal weight. Type 2 patients exhibit both a deflated skin and also moderate lipodystrophy. They are generally overweight or type 1 obese. Type 3 patients have a nondeflated skin with moderate to abundant lipodystrophy. Their weight ranges from type 1 to 3 obesity.

The operative drawings are performed in both standing and supine positions and are quite similar to the description of Pascal markings.² Nonetheless, we do not realize flap for the buttock augmentation. We reshape the buttocks with the help of a suture craftiness by moving the inferior tissue from outside to inside. This creates a difference in length between the lower and the upper edges that provides a moderate autoaugmentation.³ (See video, Supplemental Digital Content 1, which displays indications and markings. This video is available in the “Related Videos” section of the Full-Text article on PRSGlobalOpen.com or available at <http://links.lww.com/PRSGO/A995>.)

PART 2: POSTERIOR CONTOURING

The surgery started by the posterior contouring with the patient placed in a prone position. Adipose tissue was infiltrated with an adrenaline saline solution (1:1,000; weight/volume). A drastic liposuction under the skin area, which will be excised, was performed, as well as a liposuction under the superficialis fascia in the trochanteric area. Then,

Disclosure: The authors have no financial interest to declare in relation to the content of this article.



Video Graphic 2. See video, Supplemental Digital Content 2, which displays posterior contouring. This video is available in the “Related Videos” section of the Full-Text article on PRSGlobalOpen.com or available at <http://links.lww.com/PRSGO/A996>.

the skin was removed just under the dermis with a careful conservation of the connective tissue, which contains microvessels. This tissue preservation allows a reduced dead space filled by a framework that may afford good physiologic preservation of the remaining tissue. Indeed, we have previously reported that in these connective tissues, the microvascular network and probably the microvasculature were partly preserved.⁴ This is particularly important because in intact organs, fluid exchange occurs at this level. In our opinion, it is the conservation of this microvascular network that enables the diminution of postoperative complications and drainage duration. Wound closure is achieved through a flapness autoaugmentation³ without drains by separated absorbable stitches using Polysorb 2 (Covidien, Dublin, Ireland) at the level of superficialis fascia between the inferior and the superior flap and by separated intradermal stitches using Monocryl 3/0 (Ethicon, Inc., Somers-

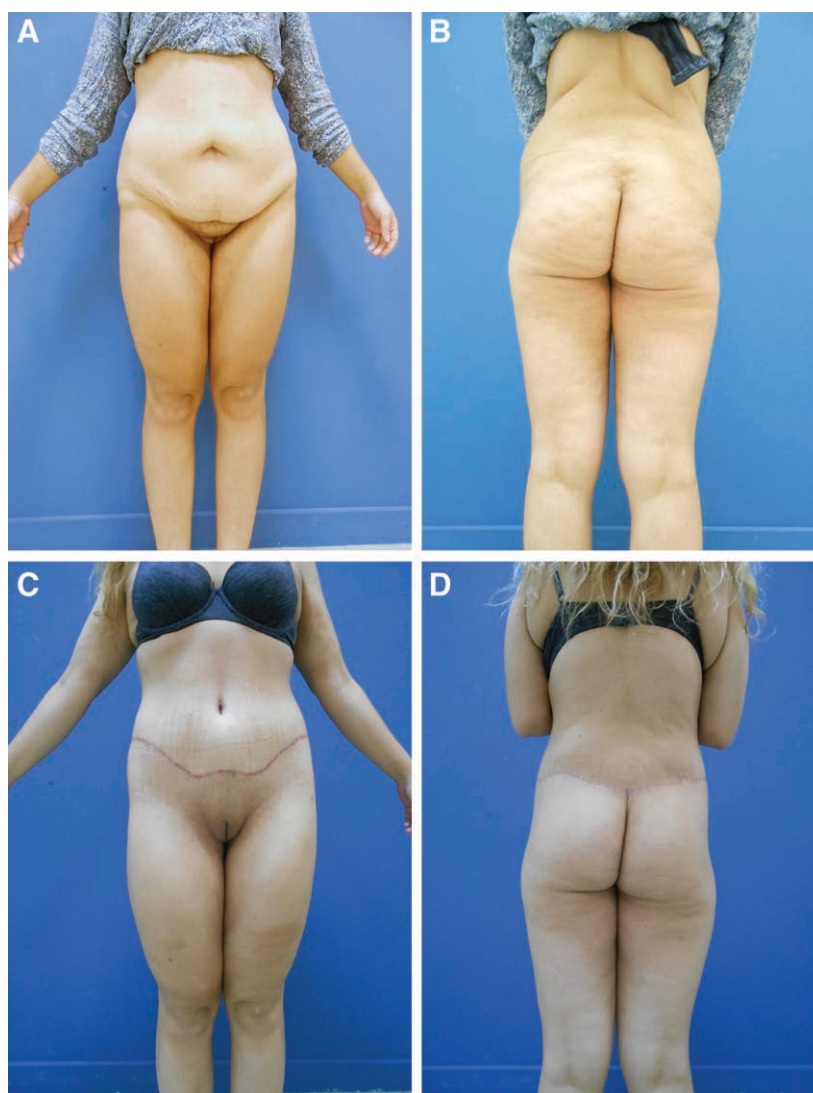
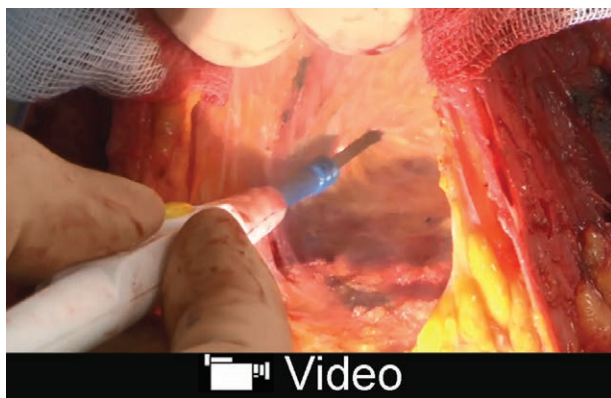


Fig. 1. Patient with massive weight loss deformity by bypass. A, Preoperative view (front). B, Preoperative view (back). C, Postoperative view (front) at 3 months. D, Postoperative view (back) at 3 months.

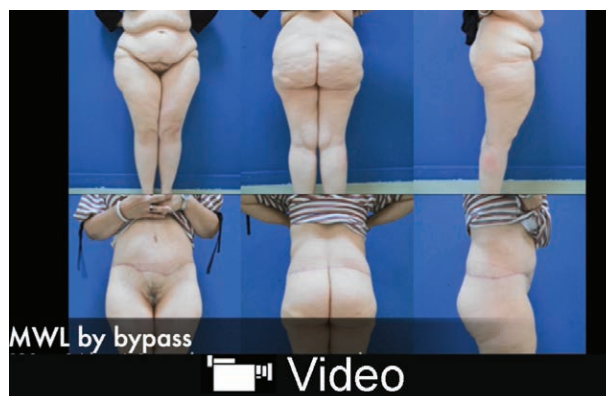ville, N.J.). Briefly, the buttock tissues were sutured on the lumbar tissues 4 to 5 cm inside. The first point (“A” in this video) is placed on the inferior drawing at the junction between this mark and a perpendicular line located at the end of the sub gluteal fold. The second point (“B”) is placed on the superior mark 4 to 5 cm inside this last line. Point B was sutured to point A. It allows the buttock to move medially, thus increasing moderately the projection without performing buttock undermining or fat grafting. The closure ends with a running suture (Monocryl 4/0; *see video*, Supplemental Digital Content 2, which displays posterior contouring. This video is available in the “Related Videos” section of the Full-Text article on PRSGlobalOpen.com or available at <http://links.lww.com/PRSGO/A996>).

PART 3: ANTERIOR CONTOURING

The surgery continues with the patient positioned in a supine position. The anterior contouring starts with an infiltration of the adipose tissue using an adrenaline saline solution (1:1,000; weight/volume) and an extensive liposuction under the resection area. Skin was excised with conservation of the connective tissue. Then, a small traditional undermining above the umbilicus to the xiphoid was performed. This dissection is performed just above the fascia and extends laterally to the medial edge of the recti muscles. Thereafter, a monsplasty⁵ with 3 nonabsorbable stitches (1 Premicron; B.Braun, Melsungen, Germany) was achieved, and the medial point was placed between Crumpler’s fascia and rectus aponeurosis and the 2 lateral stitches between Crumpler’s fascia and the periosteum of the iliac crest. A high-tension stitch was placed at the top of the neo-umbilicus between the dermis of the abdominal flap and the rectus fascia to reduce tension of the scar. A drain was positioned in the subumbilical undermining, and the wound closure was performed as the posterior closure by separate absorbable stitches (Polysorb 2; Covidien, Dublin, Ireland; and Monocryl 3/0; Ethicon, Inc., Somerville, N.J.) and by a running suture (Monocryl 4/0; *see video*, Supplemental Digital Content 3, which displays anterior contouring. This video is available in the “Related Videos” section of the Full-Text article on PRSGlobalOpen.com or at <http://links.lww.com/PRSGO/A997>).



Video Graphic 3. See video, Supplemental Digital Content 3, which displays anterior contouring. This video is available in the “Related Videos” section of the Full-Text article on PRSGlobalOpen.com or available at <http://links.lww.com/PRSGO/A997>.



Video Graphic 4. See video, Supplemental Digital Content 4, which displays preoperative and postoperative results. This video is available in the “Related Videos” section of the Full-Text article on PRSGlobalOpen.com or available at <http://links.lww.com/PRSGO/A998>.

PART 4: PREOPERATIVE AND POSTOPERATIVE RESULT

In this video, a few preoperative and postoperative results are shown after massive weight loss after bariatric surgery. (*See video*, Supplemental Digital Content 4, which displays preoperative and postoperative results. This video is available in the “Related Videos” section of the Full-Text article on PRSGlobalOpen.com or at <http://links.lww.com/PRSGO/A998>).

DISCUSSION

Over our last 90 lipo-body lift performed between January 2015 and September 2018, the mean drainage time was 3.38 ± 0.80 days (drain was removed as soon as it gave less than 20 ml/24 h), and the mean length of stay was 3.46 ± 0.93 days. Of all patients, 26 patients (28.9%) experienced at least 1 complication. One patient had hematoma that necessitated a reoperation (1.1%), and the others had minor complications including wound dehiscence, wound infection, and fat necrosis. We have had no case of thromboembolism, skin necrosis, or seroma.

The aesthetic result is rather good and does not seem inferior to the traditional technique (Fig. 1). The scar is a bit high in the pubic area, which is the consequence of our monsplasty technique. We have the same result with traditional undermining and this monsplasty technique. This could be improved by not doing the suspension of the pubis, but in our experience, patients are not troubled and prefer a high scar rather than an uncorrected pubis.

CONCLUSIONS

This video illustrates the main key point to perform a lipo-body lift. This technique thanks to the conservation of the connective framework is less aggressive than traditional lower body lifts that use classic undermining. We really believe that this technique can benefit to patients with massive weight loss.

Nicolas Bertheuil, MD, PhD

Department of Plastic, Reconstructive and Aesthetic Surgery
Hospital Sud
16 Boulevard de Bulgarie
35200 Rennes, France
E-mail: nbertheuil@gmail.com

REFERENCES

1. Bertheuil N, Chaput B, De Runz A, et al. The lipo-body lift: a new circumferential body-contouring technique useful after bariatric surgery. *Plast Reconstr Surg*. 2017;139:38e–49e.
2. Pascal JF, Le Louarn C. Remodeling bodylift with high lateral tension. *Aesthetic Plast Surg*. 2002;26:223–230.
3. Bertheuil N, Carloni R, Herlin C, Chaput B, Watier E. Lower body lift after massive weight loss: autoaugmentation versus no augmentation. *Plast Reconstr Surg*. 2016;137:476e–477e.
4. Bertheuil N, Chaput B, Berger-Müller S, et al. Liposuction preserves the morphological integrity of the microvascular network: flow cytometry and confocal microscopy evidence in a controlled study. *Aesthet Surg J*. 2016;36:609–618.
5. Patoue A, De Runz A, Carloni R, Aillet S, Watier E, Bertheuil N. Safe monsplasty technique. *J Plast Surg Hand Surg* 2017:1–6.