



Maladie de Fabry en cardiologie revue de la littérature et point de vue d'experts [Fabry disease in cardiology practice Literature review and expert point of view]

Albert Hagège, P. Réant, G. Habib, T. Damy, G. Barone-Rochette, Gilles
Soulat, Erwan Donal, D.P. Germain

► To cite this version:

Albert Hagège, P. Réant, G. Habib, T. Damy, G. Barone-Rochette, et al.. Maladie de Fabry en cardiologie revue de la littérature et point de vue d'experts [Fabry disease in cardiology practice Literature review and expert point of view]. Archives of cardiovascular diseases, 2019, 112 (4), pp.278-287. 10.1016/j.acvd.2019.01.002 . hal-02088219

HAL Id: hal-02088219

<https://univ-rennes.hal.science/hal-02088219>

Submitted on 22 Oct 2021

HAL is a multi-disciplinary open access archive for the deposit and dissemination of scientific research documents, whether they are published or not. The documents may come from teaching and research institutions in France or abroad, or from public or private research centers.

L'archive ouverte pluridisciplinaire **HAL**, est destinée au dépôt et à la diffusion de documents scientifiques de niveau recherche, publiés ou non, émanant des établissements d'enseignement et de recherche français ou étrangers, des laboratoires publics ou privés.



Distributed under a Creative Commons Attribution - NonCommercial 4.0 International License

Fabry disease in cardiology practice: Literature review and expert point of view

Abbreviated title: Fabry disease in cardiology practice: A review

**Albert Hagege^{a,*}, Patricia Réant^b, Gilbert Habib^c, Thibaud Damy^d, Gilles Barone-Rochette^e,
Gilles Soulat^f, Erwan Donal^g, Dominique P. Germain^h**

^a Cardiology Department, Hôpital Européen Georges Pompidou, AP-HP, 75015 Paris; Faculty of Medicine, Paris Descartes University, Sorbonne Paris Cité, 75006 Paris; Paris Cardiovascular Research Centre, INSERM, UMR970, 75015 Paris, France

^b Bordeaux University Hospital, University of Bordeaux, 33000 Bordeaux, France

^c Service de Cardiologie, CHU La Timone, 13005 Marseille, France

^d Department of Cardiology, Centre d'Investigation Clinique et Plateforme de Ressources Biologiques, Hôpital Henri Mondor, 94010 Créteil, France

^e Department of Cardiology, University Hospital of Grenoble Alpes, 38700 La Tronche; Radiopharmaceutiques Biocliniques, INSERM, U1039, Grenoble Alpes University, 38706 La Tronche; French Alliance for Cardiovascular Trials, French Clinical Research Infrastructure Network, Toulouse, France

^f Département de Radiologie, INSERM U970, Hôpital Européen Georges Pompidou, Université Paris Descartes, 75015 Paris, France

^g Service de Cardiologie et Maladies Vasculaires et CIC-IT 804, LTSI INSERM U642, CHU de Rennes, 35000 Rennes, France

^h French Referral Centre for Fabry Disease, Division of Medical Genetics, Hôpital Raymond Poincaré, AP-HP, 92380 Garches; INSERM U1179, University of Versailles, 78180 Montigny, France

* Corresponding author at: Cardiology Department, Hôpital Européen Georges Pompidou, 20 Rue Leblanc, 75015 Paris, France.

E-mail address: albert.hagege@egp.aphp.fr (A. Hagege).

Summary

Fabry disease is an X-linked progressive multisystemic genetic sphingolipidosis caused by deficient activity of lysosomal α -galactosidase A. Men aged > 30 years and women aged > 40 years most often present with unexplained left ventricular hypertrophy, usually concentric and non-obstructive, but sometimes mimicking sarcomeric hypertrophic cardiomyopathy, particularly when isolated, as in the cardiac or late-onset variant of the disease. In hypertrophic cardiomyopathy cohorts, up to 1% of patients have been diagnosed with Fabry disease. Frequent cardiac symptoms include chronotropic incompetence, severe conduction disturbances and arrhythmias, heart failure and sudden death, and cardiovascular complications are currently the leading cause of death at a mean age of 55 years in men and 66 years in women. Complementary to screening for extracardiac manifestations, the initial cardiac evaluation should include long-duration electrocardiogram recordings, echocardiography and late gadolinium and T1 mapping magnetic resonance imaging. Abnormalities of a non-hypertrophied inferolateral wall at the base of the left ventricle (thinning, decreased strain, midwall fibrosis) and low native T1 signal on magnetic resonance imaging are evocative. Aggressive cardiac management may include the control of cardiovascular risk factors, anticoagulation, permanent cardiac pacing and/or an implantable cardioverter defibrillator device, while antiarrhythmics and beta-blockers should be used with caution. Specific therapy should be initiated at the earliest stage, when the first structural or functional cardiac abnormalities are detected, and should include enzyme replacement therapy (available since 2001) or chaperone therapy (available since 2016) (the use of which is limited to patients with Fabry disease and an amenable α -galactosidase A [GLA] gene mutation).

Résumé

La maladie de Fabry est une sphingolipidose lysosomale de transmission génétique liée au chromosome X, entraînant un déficit d'activité de l' α -galactosidase A lysosomale. Les hommes atteints de plus de 30 ans et les femmes de plus de 40 ans présentent souvent une hypertrophie ventriculaire gauche, habituellement concentrique et non-obstructive, mais qui peut mimer une cardiomyopathie hypertrophique (CMH) sarcomérique, particulièrement lorsqu'isolée comme dans le cas du variant cardiaque de l'affection. La maladie de Fabry est cause de 0,7–1 % des CMH en milieu cardiologique. Les symptômes cardiaques, fréquents, incluent incompetence chronotrope, anomalies sévères de conduction, arythmies, insuffisance cardiaque et mort subite. Les complications cardiovasculaires

représentent désormais la cause la plus fréquente de décès à un âge moyen de 55 ans chez l'homme et 66 ans chez la femme. Associée au dépistage des atteintes extracardiaques, l'évaluation cardiaque initiale inclut enregistrements holter ECG longue durée, échocardiographie et imagerie cardiaque par résonnance magnétique (IRM) avec injection de gadolinium. Les anomalies du segment ventriculaire gauche basal inférolatéral (amincissement, strain diminué, fibrose médio-murale) sont évocatrices, comme un signal T1 altéré en IRM. La thérapeutique cardiovasculaire doit être agressive et associe potentiellement contrôle des facteurs de risque, anticoagulation, implantation de pacemaker et/ou défibrillateur, alors que amiodarone et bêtabloquants devraient être considérés avec prudence. Les traitements spécifiques devraient être initiées tôt, dès la détection des premières anomalies cardiaques structurales ou fonctionnelles, et incluent le traitement enzymatique substitutif et une molécule chaperonne (réservée uniquement aux patients porteurs d'une mutation sensible du gène *GLA*).

KEYWORDS

Fabry disease;

Hypertrophic cardiomyopathy;

Guidelines;

Enzyme replacement therapy

MOTS CLÉS

Maladie de Fabry ;

Cardiomyopathie hypertrophique ;

Recommandations ;

Enzymothérapie substitutive

Abbreviations: α -Gal A, α -galactosidase A; AF, atrial fibrillation; ERT, enzyme replacement therapy; FD, Fabry disease; GL-3, globotriaosylceramide; *GLA*, α -galactosidase A gene; HCM, hypertrophic cardiomyopathy; hs-TNT, high-sensitivity troponin T; ICD, implantable cardioverter defibrillator; LGE, late gadolinium enhancement; LVEF, left ventricular ejection fraction; LVH, left

ventricular hypertrophy; lyso-GL-3; globotriaosylsphingosine; MRI, magnetic resonance imaging;
NSVT, non-sustained ventricular tachycardia; SCD, sudden cardiac death.

Definition

Fabry disease (FD; Online Mendelian Inheritance in Man [OMIM] #301500) is a progressive X-linked genetic disease caused by absent or deficient activity of lysosomal α -galactosidase A (α -Gal A; α -D-galactoside galactohydrolase, Enzyme Commission [EC] number 3.2.1.22), resulting in deposition of globotriaosylceramide (GL-3; also abbreviated to Gb₃) and its deacylated derivative globotriaosylsphingosine (lyso-GL-3; also abbreviated to lyso-Gb₃) within lysosomes in virtually all cell types and in body fluids. Lysosomal and cellular dysfunction probably trigger a cascade of events, including cellular death, inflammation, small vessel injury, oxidative stress, tissue ischaemia and the development of cardiac and renal fibrosis. The worldwide incidence of FD is reported to be in the range of 1 in 40,000–117,000, although this may be a significant underestimation given the under-recognition of symptoms and delayed or missed diagnoses. Thus, many recent publications based on newborn screening initiatives have found an unexpectedly high prevalence of the disease – as high as 1 in ~3100 newborns in Italy [1] – although a prevalence of around 1 in 8000 is more probable, once likely benign variants of the α -galactosidase A (*GLA*) gene have been excluded [2].

Patients with FD most often present with left ventricular hypertrophy (LVH) that is unexplained by abnormal cardiac loading conditions (such as hypertension or aortic stenosis), sometimes as a predominant or isolated feature (the so-called “cardiac variant” of FD) [2, 3]. Cardiologists should therefore be aware of the cardiac variant of FD in case of hypertrophic cardiomyopathy (HCM). The prevalence of HCM resulting from sarcomeric gene mutation is reported in 1/500 to 1/200 of the general population, and at least 10% of HCM in adults is estimated to have non-sarcomeric origins [4], arising rather from amyloidosis, FD or mitochondrial diseases, which require specific treatments. Guidelines also recommend that patients undergo an initial evaluation at referral or expert centres for FD or HCM [4]. This system of care, largely specific to France, is designed to optimize the management of patients with rare diseases.

This document, written by experts in cardiology, imaging and genetics, aims to summarize what the cardiologist should know about FD, particularly concerning the physiopathology of cardiovascular damage, methods of screening in cardiology practice, and current cardiovascular management. The respective advantages of specific therapies, which are usually initiated by non-cardiologists in France, will not be detailed.

Cardiovascular involvement

Physiopathology

Accumulation of GL-3 in all cardiac tissue cells, cardiomyocytes, valvular fibroblasts, the heart conduction system and endothelial cells leads to the clinical consequences presented in [Fig. 1](#).

Cardiomyocyte hypertrophy results from increased concentrations of lyso-GL-3 and vascular smooth muscle cell proliferation, while GL-3 accumulation seems to contribute only marginally to the increased ventricular mass observed in FD [2]. Cardiomyocyte and endothelial dysfunctions occur before the onset of clinical manifestations. Therefore, disease-specific treatments are more effective when administered in the early stages of the disease, before irreversible tissue fibrosis takes place.

Signs and symptoms

In adults, clinical signs of FD include a variable combination of kidney, neurological and cardiac dysfunctions. The mean time from appearance of the first signs or symptoms to diagnosis of FD is 15 years [2]; this is because of the rarity of FD and the corresponding lack of awareness among physicians, and the diversity and non-specificity of presenting signs and symptoms [5]. According to the Fabry Outcome Survey (FOS) registry for FD [6], cardiac symptoms affect 60% of patients, and include exertional dyspnoea and heart failure (23%), exercise angina caused by microvascular dysfunction (23%), palpitations or arrhythmias (27%) – particularly atrial fibrillation (AF) (17%) and non-sustained ventricular tachycardia (NSVT) (8%) – and syncope (up to 4%). LVH is the most frequent cardiac sign, reported in 50% of men (up to 88%, usually after the third decade of life) and over one-third of women (usually after the fourth decade of life) [6]. Other common abnormalities include chronotropic incompetence and/or sinus node dysfunction or severe atrioventricular block (in 7–30% of patients). Resting bradycardia and an impaired heart rate response on exercise have been reported with a frequency > 70% in a study that included 38 patients with FD [7]. Hypertension (infrequent in the absence of renal dysfunction), moderate and usually asymptomatic valvular regurgitation (in 7–20% of patients) and moderate and asymptomatic dilatation of the aortic root at the Valsalva level have also been reported. Myocardial infarction and left ventricular systolic dysfunction are rare (observed in < 5% of patients).

Prognosis and major cardiovascular events

According to data in the Fabry Registry (NCT00196742), cardiovascular complications are the leading cause of death [8]; 40% of patients die as a result of cardiovascular complications versus < 10% as a result of neurological or kidney complications [9]. Deaths caused by cardiovascular complications generally occur at a mean age of 55 years in men and 66 years in women [9]. The main predictive factors in determining major adverse cardiovascular events in patients with FD include increasing age, overall disease severity (particularly end-stage renal disease) and the presence and magnitude of LVH and prolonged QRS (≥ 120 ms) [10]. In a cohort of 207 patients with a 7-year median follow-up, major adverse cardiovascular events occurred in 15% of patients (2.64/100 person-years).

Specifically, 10% of the patients developed New York Heart Association class III/IV heart failure (1.62/100 person-years), 6% had new-onset AF (1/100 person-years), 6% required an antibradycardia device (1.07 person-years) and 3% died (all men aged > 40 years; 0.52/100 person-years) [11]. In another recent cohort of 261 patients, 12 of the 21 deaths were caused by cardiac complications (six were the result of sudden cardiac death [SCD]). An ICD was implanted in 19 (7%) patients, mainly for primary prevention (11 patients) [12]. Finally, a recent systematic review including 13 studies and 4185 patients, with a follow-up period of 1.2–10 years, revealed that of the 8.3% of deaths that occurred, 75% had cardiovascular causes and 62% were the result of SCD, a major cause of cardiovascular mortality in FD. In this review, the average prevalence of ventricular tachycardia was 15.3%, and age, male sex, LVH, late gadolinium enhancement (LGE) on magnetic resonance imaging (MRI) and NSVT were associated with SCD events [13].

Cardiac variants of FD

Several case reports have documented the existence of a cardiac variant of FD, with only cardiac symptoms and signs, and accumulation of sphingolipids in the heart. Recently, specific mutations have been reported to be responsible for this cardiac variant, particularly the p.N215S mutation (the most frequent in Caucasian subjects) and the splice IVS4 (Chinese-Taiwanese hotspot). In the latter, the mechanism proposed is that alternative splicing of the *GLA* gene leads to α -Gal A activity at approximately 10% of normal values. This relatively high residual enzyme activity would also explain the slower clinical progression of the disease compared with “classic” FD, and delayed onset in middle

age. Although not always exclusively cardiac, the clinical presentation in patients with residual activity is usually dominated by cardiovascular involvement [6].

Similarly to “classic” FD, the cardiac variant can cause global LVH or an asymmetrical septal hypertrophy mimicking sarcomeric HCM. LVH is usually absent in men aged < 30 years and women aged < 40 years. Left ventricular ejection fraction (LVEF) is usually preserved, while diastolic dysfunction, generally moderate, is frequent. According to a multicentre FD registry study, cardiac damage may become as severe as in patients with classic FD, especially in men, but 15 years later than in classic FD. Cardiac prognosis is then similar in both forms, but LVH may be more severe in patients with cardiac variants of FD in case of late diagnosis [3]. HCM as a result of FD has been shown to have a more severe prognosis than sarcomeric HCM [14].

Cardiac variants of FD may be under-recognized, as patients can present with only LVH and/or conduction abnormalities, lacking other classic manifestations of FD. Indeed, in patients with LVH or HCM screened for FD, about 1% have been newly diagnosed with this condition. In the FOCUS study, which screened 392 French patients with HCM for FD using a dried blood spot α -Gal A assay, four male patients (1%; corresponding to 1.8% of men aged ≥ 40 years), but no female patients, were genetically confirmed to have FD [15]. These four patients had diffuse but asymmetric LVH, and two presented with systolic anterior motion of the mitral valve and obstruction, which was severe in one case, leading to septal ablation. Three patients underwent pacemaker implantation for high grade atrioventricular block. Screening the families of the four probands detected eight additional cases of FD [15]. Other studies using genetic testing reported a prevalence of 0.5% among 1386 patients in the European Fabry Study [16], 1% (three men, two women) among 508 patients in a Spanish cohort [17] and 0.34% (all with the p.N215S variant) among 585 patients in a cohort in the USA [18].

Diagnosis

FD is a multisystemic disease, and can affect several organs, resulting in neurological, ocular, skin, renal and cardiac manifestations. Therefore, cardiologists, neurologists, dermatologists, nephrologists and ophthalmologists should all be aware of the possibility of FD, depending on the patient’s clinical presentation. In the cardiology environment, a diagnosis of FD should be considered systematically in the case of unexplained LVH, particularly when concentric, symmetric, homogeneous or non-obstructive. Unexplained LVH in combination with the non-cardiac signs and symptoms presented in

Fig. 2 are the diagnostic red flags that should trigger the referral of the patient to an FD or HCM centre of excellence for further assessment.

Suspected FD should be followed up with biochemical and genetic confirmation. Assay of α -Gal A activity in dried blood spots or leukocytes will usually confirm the diagnosis in men. Plasma lyso-GL-3 and/or urinary GL-3 have also been used in the biochemical diagnosis of FD. However, GL-3 and lyso-GL-3 levels are generally lower in women than in men, and may not be elevated with particular *GLA* gene mutations and later-onset FD (e.g. p.Phe113Leu or p.Asn215Ser mutations). In female heterozygotes, α -Gal A activity is often within the normal range. The diagnosis in suspected cases should therefore be confirmed by genetic analysis of the *GLA* gene. The pattern of X chromosome inactivation – where one X chromosome in each cell of a female individual is randomly and permanently inactivated – has been found to be a major predictor in determining the natural history of FD in female patients [19]. Nowadays, diagnosis is increasing via pedigree analysis or family screening after diagnosis of another family member.

Finally, patients with undetected FD can be identified by systematic or orientated screening of HCM patients aged > 30 years for men and > 40 years for women, and patients with end-stage renal disease or stroke at a young age [20]. These at-risk groups are often screened by measuring circulating α -Gal A activity, but this method can fail to detect FD in women. Therefore, next-generation sequencing (gene panels or exome) is becoming more widespread; this is a useful innovative technology, but may lead to the identification of genetic variants of unknown significance (GVUS), which are often not associated with the characteristic features of FD. Individuals identified through screening protocols therefore require careful assessment and an unambiguous diagnosis of FD before initiation of therapy [2].

Initial clinical workup

Cardiovascular examinations

Electrocardiography

In patients with FD, the electrocardiogram is rarely normal, and often displays LVH. FD should be considered if LVH occurs in combination with frequent (15%) short PR interval (as a result of accelerated conduction in the absence of accessory pathway), sinus bradycardia with chronotropic

incompetence and/or severe atrioventricular conduction disturbances. Atrial or ventricular arrhythmias, enlarged QRS and bundle branch block may also occur [2, 5].

Long-duration electrocardiogram recordings

Supraventricular and ventricular arrhythmias are common in FD, and may occur even in the prehypertrophic phase [2] as the first manifestations of FD, before any clinical or cardiac imaging abnormalities [21]. Recent guidelines for managing patients with FD recommend a systematic annual 48-hour Holter electrocardiogram [22], as is the case for patients with HCM [4]. Long-duration electrocardiogram recordings using subcutaneous Holter systems have shown a markedly high frequency of abnormalities, leading to new management decisions (i.e. pacemaker or ICD insertion, anticoagulant treatment) in half of patients with signs of myocardial damage (LVH, fibrosis) and a normal 24-hour Holter electrocardiogram [23], and NSVTs were reported in up to 15% of patients [13]. The prevalence of abnormalities leading to the implantation of a cardiac device is high (18%), with an incidence of 1.9% per year after 8 years of follow-up [24]. Ventricular tachycardia and fibrillation, including SCD, are relatively frequent in patients with FD with HCM and/or myocardial fibrosis [25].

Echocardiography

Even if no echocardiographic sign is specific to FD, echocardiography should be systematic for the initial assessment and follow-up of patients with FD. The main echocardiographic feature is LVH ([Fig. 3](#)), which typically combines concentric thickening without left ventricular obstruction and normal LVEF. However asymmetric septal or apical hypertrophy has also been described, along with subaortic obstruction, which may mimic the phenotypical and clinical features of sarcomeric HCM. In a cohort of 139 patients with FD, the main observed echocardiographic features were LVH (concentric in 96% of patients), left atrial enlargement and valvular thickening with or without mild regurgitation [26]. Decreased longitudinal strain within the basal inferolateral left ventricular wall in the absence of localized hypertrophy, as well as infrequent thinning of (and eventually hyperechoic) basal left ventricular inferolateral wall are evocative of FD [27] ([Fig. 3](#)). Right ventricular hypertrophy with preserved systolic function, left atrium function impairment and moderate aortic dilatation may also be observed, and left ventricular hypertrabeculation and non-compaction have been described [28]. Left ventricular function may deteriorate with time, leading to a restrictive cardiomyopathy pattern. Other

echocardiographic features include prominent papillary muscles (Fig. 3) and binary appearance of left ventricular endocardial border [28], but their diagnostic value is controversial. In patients without LVH, decreased tissue Doppler imaging velocities at the mitral annulus may be the first sign of initial intrinsic myocardial impairment, suggesting that myocardial dysfunction precedes LVH, and favouring early disease-specific treatment of FD [29].

Cardiac MRI

Cardiac MRI is becoming increasingly important for the diagnosis of cardiac involvement in FD.

Cardiac MRI is usually more accurate than echocardiography in assessing left ventricular thickness and mass, diagnosing LVH [4] and assessing LVH distribution and severity, which in FD correlates with ventricular arrhythmias [30]. LGE frequently shows a midwall pattern on the inferolateral wall at the base of the left ventricle, often occurring on a non-hypertrophied wall [31] (Fig. 3). The reason for this distribution of LGE remains unclear, and may be because of inhomogeneous left ventricular wall stress, microvascular dysfunction or chronic myocardial inflammation. The role of systematic MRI in FD is reinforced by recent studies showing that, if increased wall thickness precedes fibrosis in most patients, LGE in the absence of LVH is found in 17% of female patients [32, 33] and 38% of male patients with IVS4 mutations [32]. Another study showed that of 28 patients with FD who were not on enzyme replacement therapy (ERT) at enrolment, six patients (21%) were reclassified as having cardiac involvement after cardiac MRI (LGE but no LVH, $n = 4$; LGE and LVH, $n = 1$; LVH but no LGE, $n = 2$) [34]. It remains unclear whether early specific therapies are useful in the presence of fibrosis. Low native T1 values of the myocardium secondary to sphingolipid storage are observed in 40% of patients with FD without LVH and in > 90% of patients with FD with LVH, making T1 mapping a useful test for early detection of cardiac involvement, even in the absence of LVH [35, 36]. A low native T1 is specific to FD cardiomyopathy, while very uncommon in HCM because of sarcomere gene mutations, amyloidosis or hypertension [36]. Low native T1 can be also encountered in cases of iron overload (haemochromatosis); a diagnosis of haemochromatosis can be eliminated based on low T2* values [30]. Of note, T1 mapping sequences are investigational tools, and their results must be interpreted with caution because of difficulties in standardizing measurements. Recent guidelines recommend that centres use mapping sequences for the diagnosis of FD, after obtaining normal values from a reference population of more than 15 healthy volunteers [37]. Finally, MRI may help in the diagnosis

and monitoring of aortic dilation at the Valsalva sinuses, which is found in one third of male patients with FD [38].

Stress testing

Exercise electrocardiograms usually show a decrease in working capacity in patients with advanced cardiomyopathy and chronotropic incompetence. Few data are available regarding stress myocardial imaging, which could detect perfusion defects in patients with angina pectoris and normal epicardial coronary arteries. Exercise echocardiography can be performed in symptomatic patients with LVH to detect provokable left ventricular outflow tract obstruction [39].

Biological testing

In a large cohort of patients with FD, high-sensitivity troponin T (hs-TNT) seemed to be an accurate biomarker for detecting replacement fibrosis in patients with FD, and correlated positively with the presence and extent of LGE on MRI [40]. Moreover, it might predict cardiomyopathy progression, and patients with elevated hs-TNT at baseline showed an increased LGE at 3.9 years of follow-up, along with decreased LVH and LVEF [40]. It has therefore been proposed that hs-TNT should be regularly assayed in all patient with FD: values within the normal range, together with normal echocardiography and electrocardiography, indicate that FD cardiomyopathy is unlikely, while borderline abnormal values should lead to repeat echocardiography and MRI, and elevated values indicate advanced cardiomyopathy (with fibrosis replacement), and should trigger close follow-up [40]. Moreover, N-terminal prohormone of brain natriuretic peptide (NT-proBNP) concentrations were shown in one study to correlate with LGE and LVH [41]. However, whether regular assessment of those biomarkers can have a direct impact on management remains to be studied.

Non-cardiac examinations

FD – and the resulting intracellular accumulation of GL-3 – causes manifestations in the peripheral nerves (in 45% of patients) and in renal (45%), ocular (38%), dermatological (34%), neurological (34%), gastrointestinal (31%) and auditory (19%) systems [42]; frequent airway obstruction, Raynaud's phenomenon and increased arterial intima-media thickness have been reported [6]. Therefore, extracardiac examinations are necessary to investigate these clinical signs and aid

diagnosis. At childhood or adolescence, male patients with the classic FD phenotype develop early onset symptoms, including acroparesthesia, angiokeratoma, hypohidrosis, gastrointestinal symptoms and the characteristic corneal verticillata. With age, they develop LVH, renal failure or cerebrovascular disease. Sensorineural manifestations, such as tinnitus, hearing loss and orthostatic hypotension should be investigated. The spectrum of disease severity in female patients ranges from asymptomatic to a severe phenotype [18]. Therefore, multidisciplinary evaluation and management of the multiorgan system and quality of life is necessary.

Therapeutics

Cardiovascular management

Control of cardiovascular risk factors

Despite the lack of formal studies showing a benefit in morbidity or mortality, recommendations include smoking cessation, increased aerobic exercise, treatment of diabetes, hypertension and dyslipidaemia and a heart-healthy diet [21]. The Fabry Registry shows that hypertension is a strong predictor of major adverse cardiovascular events, including myocardial infarction, heart failure and cardiac-related death [11]. Hypertension, when present, should be treated preferentially with angiotensin-converting enzyme inhibitors or angiotensin receptor blockers for kidney protection. Angina should be treated with calcium channel blockers, nitrates and low-dose aspirin. Beta-blockade must be carefully evaluated because of the propensity of patients with FD to experience bradyarrhythmia and chronotropic incompetence.

Conduction abnormalities

In case of symptomatic bradyarrhythmias resulting from sinus node disease (including inappropriate sinus bradycardia or chronotropic incompetence) and/or high-degree atrioventricular block, permanent cardiac pacing should be considered [21]. The rates of antibradycardia pacing are more than 25 times greater than that in the general population, with a 5-year cumulative incidence reaching 8% [43]. Moreover, in implanted patients, there is a high rate of atrial or ventricular pacing [20].

Supraventricular arrhythmias

As the mechanism of AF in FD is probably multifactorial (glycosphingolipid storage, myocardial hypertrophy, myocardial interstitial fibrosis), rhythm control or rate control is challenging. For sarcomeric HCM, lifelong anticoagulant treatment using a vitamin K antagonist or a direct oral anticoagulant is recommended after the detection of at least one episode of sustained AF of ≥ 30 seconds [4]. The choice of antiarrhythmic drug is often limited. Amiodarone is a cationic amphiphilic drug that induces phospholipidosis in numerous organs by inhibiting lysosomal degradation of phospholipids, and is therefore not recommended in FD [21]. Beta-blockers (and all bradycardia agents) may exacerbate bradycardia and/or chronotropic incompetence and conduction impairment, limiting their tolerability. Class Ic antiarrhythmics are contraindicated, as in all cardiomyopathies. His bundle radiofrequency ablation combined with pacemaker implantation is an alternative to pharmacological treatments in case of rapid symptomatic AF. Alternatively, radiofrequency ablation (isolation of pulmonary veins) has been reported anecdotally in patients with FD, but may require longer and repeated procedures.

Ventricular arrhythmias

As previously discussed for AF prevention, antiarrhythmic drugs are of limited use in FD, and are insufficient to prevent SCD. Radiofrequency ablation by endocardial and/or epicardial approaches is also challenging, as the target tissue is frequently localized at the midwall. Although NSVT is more frequent in patients with FD who die suddenly, a causal link has not yet been established, and statistical association is complicated by the small numbers of subjects studied. There is no clear model for SCD risk prediction in FD. While the appropriate indications for prophylactic ICD implantation are still unknown in FD, SCD events – attributed to malignant bradyarrhythmias or tachyarrhythmias – seem only to occur in patients with previous documentation of NSVT and with LGE on cardiac MRI [44]. Then, an ICD should be widely considered, particularly in patients with NSVT and LGE on MRI.

Heart failure

Patients with heart failure symptoms and low LVEF $< 50\%$ should be treated according to current heart failure guidelines using angiotensin-converting enzyme inhibitors or angiotensin receptor blockers and diuretics, while beta-blockers should be used with caution. Amiodarone should be

avoided, particularly in patients receiving ERT, because of a possible interaction between amiodarone and ERT. Heart transplantation has been proposed in patients with FD with end-stage cardiac involvement and without evidence of recurrence of GL-3 deposits on endomyocardial biopsies [45]. In case of symptoms secondary to left ventricular outflow tract obstruction and refractory to optimized drug therapy, surgical septal myectomy or alcohol septal ablation have been proposed, and have improved symptoms in some patients [46]. Cardiac resynchronization therapy in symptomatic patients with LVEF < 50% and left bundle branch block with or without an ICD should be assessed case by case according to current guidelines [4].

Disease-specific therapies

ERT

ERT has provided the first opportunity to address the underlying enzyme deficiency of FD, and has been the standard specific approach to treating FD for over 18 years. ERT reduces the severity of symptoms and lowers concentrations of GL-3/lyso-GL-3 in plasma, urine and tissue. Two different preparations of recombinant human α -Gal A have been available in Europe since 2001, both administered as an infusion every 2 weeks: agalsidase alfa (Replagal®; Shire, Lexington, MA, USA) and agalsidase beta (Fabrazyme®; Sanofi-Genzyme, Cambridge, MA, USA); these have subsequently become available in many other countries. Although clinical trials have demonstrated agalsidase alfa and agalsidase beta to be safe and effective disease-specific therapeutic agents for FD [28, 47], the cardiac outcomes of both products are difficult to compare based on published trials. Clinical and observational evidence suggests that ERT can improve mild-to-moderate LVH and stabilize severe LVH [48, 49] while patients with mild or severe fibrosis showed a minor reduction in LVH and no improvement in myocardial function or exercise capacity [49]. ERT response is not always optimal, and may be influenced by age, time since disease onset and disease severity before drug initiation. Furthermore, ERT might not prevent the development of fibrosis in patients with advanced cardiomyopathy [24] and, even when ERT is initiated at an earlier stage, fibrosis may not be halted completely, and occasionally progresses [48].

Chaperone therapy

ERT intravenous infusions are a lifelong burden for the patient, and may induce infusion reactions. Pharmacological chaperones are promising for patients with *GLA* mutations resulting in misfolded or unstable enzymes. These are small molecular ligands that can be administered orally, and which bind reversibly to the misfolded enzyme, promoting correct folding and delivery of the enzyme to the lysosome. In FD, the pharmacological chaperone migalastat is an inhibitor of α -Gal A that, at subinhibitory concentrations, reversibly binds the active site of α -Gal A, increases the activity of several α -Gal A amenable mutants and reduces plasma concentrations of lyso-GL-3 in patients with amenable missense mutations [50]. Further long-term outcome evaluation of this novel approach is needed.

Conclusions

FD is a rare disease that is being diagnosed by cardiologists more frequently than it used to be. Men aged > 30 years and women aged > 40 years presenting with unexplained LVH or HCM without other proven aetiologies should be screened for FD, particularly when other red flags for FD are found, with subsequent careful interpretation of any variant identified in the *GLA* gene by a geneticist. Patients already diagnosed with FD should have extensive cardiovascular checkups at the initial evaluation, and then periodically, as cardiac complications, particularly SCD, are the main cause of a severely shortened lifespan and death in patients with FD. Cardiac complications of FD should be managed aggressively, including ICD when indicated, and disease-specific therapies, such as ERT or chaperone (only in patients with amenable disease-causing variants), should be initiated promptly upon detection of structural or functional cardiac abnormalities [47].

Patient support

Patient support can be sought from the following organizations: Centre de Référence Coordonnateur de la Maladie de Fabry, CHU Raymond Poincaré, AP-HP, 104 boulevard Raymond Poincaré, 92380 Garches, France (<http://www.centre-geneo.com>); Centre de Référence Constitutif des Cardiomyopathies et des Troubles du Rythme Cardiaque Héritaires ou Rares, Départements de Cardiologie et de Génétique Médicale, Hôpital Européen Georges Pompidou, 20 rue Leblanc, 75015 Paris, France; Association des Patients de la Maladie de Fabry (APMF), 21 rue Monge, 21160 Marsannay La Cote, France (contact@apmf-fabry.org); Association Vaincre les Maladies

Lysosomales (VML), 2 ter avenue de France, 91300 Massy, France (<https://www.vml-asso.org/spip.php?page=contact>).

Sources of funding

Support for meeting organization was obtained from Sanofi Genzyme, France; the company was not involved in the discussions. The authors were responsible for all content and editorial decisions.

Disclosure of interest

A. H. Consulting fees or research grants from the companies **Sanofi Genzyme, Myokardia** and **Amicus Therapeutics**.

P. R. Consulting fees or research grants from the companies **Sanofi Genzyme, Shire, Pfizer, Novartis** and **Amicus Therapeutics**.

T. D. Consulting fees or research grants from the companies **Sanofi Genzyme, Pfizer, Novartis, Resmed, VIFOR** and **AKCEA**.

D. P. G. Consulting fees or research grants from the companies **Amicus Therapeutics, Sanofi Genzyme** and **Shire**.

The other authors declare that they have no conflicts of interest concerning this article.

References

- [1] Spada M, Pagliardini S, Yasuda M, et al. High incidence of later-onset fabry disease revealed by newborn screening. *Am J Hum Genet* 2006;79:31-40.
- [2] Germain DP. Fabry disease. *Orphanet J Rare Dis* 2010;5:30.
- [3] Germain DP, Brand E, Burlina A, et al. Phenotypic characteristics of the p.Asn215Ser (p.N215S) GLA mutation in male and female patients with Fabry disease: A multicenter Fabry Registry study. *Mol Genet Genomic Med* 2018.
- [4] Elliott PM, Anastasakis A, Borger MA, et al. 2014 ESC Guidelines on diagnosis and management of hypertrophic cardiomyopathy: the Task Force for the Diagnosis and Management of Hypertrophic Cardiomyopathy of the European Society of Cardiology (ESC). *Eur Heart J* 2014;35:2733-79.
- [5] Hagege AA, Germain DP. Adult patients with Fabry disease: what does the cardiologist need to know? *Heart* 2015;101:916-8.
- [6] Linhart A, Kampmann C, Zamorano JL, et al. Cardiac manifestations of Anderson-Fabry disease: results from the international Fabry outcome survey. *Eur Heart J* 2007;28:1228-35.
- [7] Lobo T, Morgan J, Bjorksten A, et al. Cardiovascular testing in Fabry disease: exercise capacity reduction, chronotropic incompetence and improved anaerobic threshold after enzyme replacement. *Intern Med J* 2008;38:407-14.
- [8] Mehta A, Clarke JT, Giugliani R, et al. Natural course of Fabry disease: changing pattern of causes of death in FOS - Fabry Outcome Survey. *J Med Genet* 2009;46:548-52.
- [9] Waldek S, Patel MR, Banikazemi M, Lemay R, Lee P. Life expectancy and cause of death in males and females with Fabry disease: findings from the Fabry Registry. *Genet Med* 2009;11:790-6.
- [10] Talbot AS, Lewis NT, Nicholls KM. Cardiovascular outcomes in Fabry disease are linked to severity of chronic kidney disease. *Heart* 2015;101:287-93.
- [11] Patel MR, Cecchi F, Cizmarik M, et al. Cardiovascular events in patients with fabry disease natural history data from the fabry registry. *J Am Coll Cardiol* 2011;57:1093-9.
- [12] Oder D, Muentze J, Salinger T, et al. Role of sudden cardiac death as end-stage complication in Fabry disease cardiomyopathy: Impact of primary and secondary prophylactic ICD therapy on long-term outcome. *Eur Heart J* 2017;38:6421.

- [13] Baig S, Edward NC, Kotecha D, et al. Ventricular arrhythmia and sudden cardiac death in Fabry disease: a systematic review of risk factors in clinical practice. *Europace* 2017.
- [14] Rosmini S, Biagini E, O'Mahony C, et al. Relationship between aetiology and left ventricular systolic dysfunction in hypertrophic cardiomyopathy. *Heart* 2017;103:300-6.
- [15] Hagege AA, Caudron E, Damy T, et al. Screening patients with hypertrophic cardiomyopathy for Fabry disease using a filter-paper test: the FOCUS study. *Heart* 2011;97:131-6.
- [16] Elliott P, Baker R, Pasquale F, et al. Prevalence of Anderson-Fabry disease in patients with hypertrophic cardiomyopathy: the European Anderson-Fabry Disease survey. *Heart* 2011;97:1957-60.
- [17] Monserrat L, Gimeno-Blanes JR, Marin F, et al. Prevalence of fabry disease in a cohort of 508 unrelated patients with hypertrophic cardiomyopathy. *J Am Coll Cardiol* 2007;50:2399-403.
- [18] Maron MS, Xin W, Sims KB, et al. Identification of Fabry Disease in a Tertiary Referral Cohort of Patients with Hypertrophic Cardiomyopathy. *Am J Med* 2018;131:200.e1-.e8.
- [19] Echevarria L, Benistan K, Toussaint A, et al. X-chromosome inactivation in female patients with Fabry disease. *Clin Genet* 2016;89:44-54.
- [20] Reuser AJ, Verheijen FW, Bali D, et al. The use of dried blood spot samples in the diagnosis of lysosomal storage disorders--current status and perspectives. *Mol Genet Metab* 2011;104:144-8.
- [21] Acharya D, Doppalapudi H, Tallaj JA. Arrhythmias in Fabry cardiomyopathy. *Card Electrophysiol Clin* 2015;7:283-91.
- [22] Ortiz A, Germain DP, Desnick RJ, et al. Fabry disease revisited: Management and treatment recommendations for adult patients. *Mol Genet Metab* 2018;123:416-27.
- [23] Weidemann F, Maier SK, Stork S, et al. Usefulness of an Implantable Loop Recorder to Detect Clinically Relevant Arrhythmias in Patients With Advanced Fabry Cardiomyopathy. *Am J Cardiol* 2016;118:264-74.
- [24] Sene T, Lidove O, Sebbah J, et al. Cardiac device implantation in Fabry disease: A retrospective monocentric study. *Medicine (Baltimore)* 2016;95:e4996.
- [25] Kramer J, Niemann M, Stork S, et al. Relation of burden of myocardial fibrosis to malignant ventricular arrhythmias and outcomes in Fabry disease. *Am J Cardiol* 2014;114:895-900.

- [26] Wu JC, Ho CY, Skali H, et al. Cardiovascular manifestations of Fabry disease: relationships between left ventricular hypertrophy, disease severity, and alpha-galactosidase A activity. *Eur Heart J* 2010;31:1088-97.
- [27] Kawano M, Takenaka T, Otsuji Y, et al. Significance of asymmetric basal posterior wall thinning in patients with cardiac Fabry's disease. *Am J Cardiol* 2007;99:261-3.
- [28] Yeung DF, Sirrs S, Tsang MYC, et al. Echocardiographic Assessment of Patients with Fabry Disease. *J Am Soc Echocardiogr* 2018;31:639-49 e2.
- [29] Zamorano J, Serra V, Perez de Isla L, et al. Usefulness of tissue Doppler on early detection of cardiac disease in Fabry patients and potential role of enzyme replacement therapy (ERT) for avoiding progression of disease. *Eur J Echocardiogr* 2011;12:671-7.
- [30] Deva DP, Hanneman K, Li Q, et al. Cardiovascular magnetic resonance demonstration of the spectrum of morphological phenotypes and patterns of myocardial scarring in Anderson-Fabry disease. *J Cardiovasc Magn Reson* 2016;18:14.
- [31] Moon JC, Sheppard M, Reed E, Lee P, Elliott PM, Pennell DJ. The histological basis of late gadolinium enhancement cardiovascular magnetic resonance in a patient with Anderson-Fabry disease. *J Cardiovasc Magn Reson* 2006;8:479-82.
- [32] Hsu TR, Hung SC, Chang FP, et al. Later Onset Fabry Disease, Cardiac Damage Progress in Silence: Experience With a Highly Prevalent Mutation. *J Am Coll Cardiol* 2016;68:2554-63.
- [33] Niemann M, Herrmann S, Hu K, et al. Differences in Fabry cardiomyopathy between female and male patients: consequences for diagnostic assessment. *JACC Cardiovasc Imaging* 2011;4:592-601.
- [34] Kozor R, Grieve SM, Tchan MC, et al. Cardiac involvement in genotype-positive Fabry disease patients assessed by cardiovascular MR. *Heart* 2016;102:298-302.
- [35] Sado DM, White SK, Piechnik SK, et al. Identification and assessment of Anderson-Fabry disease by cardiovascular magnetic resonance noncontrast myocardial T1 mapping. *Circ Cardiovasc Imaging* 2013;6:392-8.
- [36] Thompson RB, Chow K, Khan A, et al. T(1) mapping with cardiovascular MRI is highly sensitive for Fabry disease independent of hypertrophy and sex. *Circ Cardiovasc Imaging* 2013;6:637-45.

- [37] Messroghli DR, Moon JC, Ferreira VM, et al. Clinical recommendations for cardiovascular magnetic resonance mapping of T1, T2, T2* and extracellular volume: A consensus statement by the Society for Cardiovascular Magnetic Resonance (SCMR) endorsed by the European Association for Cardiovascular Imaging (EACVI). *J Cardiovasc Magn Reson* 2017;19:75.
- [38] Barbey F, Qanadli SD, Juli C, et al. Aortic remodelling in Fabry disease. *Eur Heart J* 2010;31:347-53.
- [39] Calcagnino M, O'Mahony C, Coats C, et al. Exercise-induced left ventricular outflow tract obstruction in symptomatic patients with Anderson-Fabry disease. *J Am Coll Cardiol* 2011;58:88-9.
- [40] Seydelmann N, Liu D, Kramer J, et al. High-Sensitivity Troponin: A Clinical Blood Biomarker for Staging Cardiomyopathy in Fabry Disease. *J Am Heart Assoc* 2016;5:e002839.
- [41] Coats CJ, Parisi V, Ramos M, et al. Role of serum N-terminal pro-brain natriuretic peptide measurement in diagnosis of cardiac involvement in patients with anderson-fabry disease. *Am J Cardiol* 2013;111:111-7.
- [42] Favalli V, Disabella E, Molinaro M, et al. Genetic Screening of Anderson-Fabry Disease in Proband Referred From Multispecialty Clinics. *J Am Coll Cardiol* 2016;68:1037-50.
- [43] O'Mahony C, Coats C, Cardona M, et al. Incidence and predictors of anti-bradycardia pacing in patients with Anderson-Fabry disease. *Europace* 2011;13:1781-8.
- [44] Weidemann F, Niemann M, Stork S, et al. Long-term outcome of enzyme-replacement therapy in advanced Fabry disease: evidence for disease progression towards serious complications. *J Intern Med* 2013;274:331-41.
- [45] Cantor WJ, Daly P, Iwanochko M, Clarke JT, Cusimano RJ, Butany J. Cardiac transplantation for Fabry's disease. *Can J Cardiol* 1998;14:81-4.
- [46] Magage S, Linhart A, Bultas J, et al. Fabry disease: percutaneous transluminal septal myocardial ablation markedly improved symptomatic left ventricular hypertrophy and outflow tract obstruction in a classically affected male. *Echocardiography* 2005;22:333-9.
- [47] Wanner C, Arad M, Baron R, et al. European expert consensus statement on therapeutic goals in Fabry disease. *Mol Genet Metab* 2018;124:189-203.

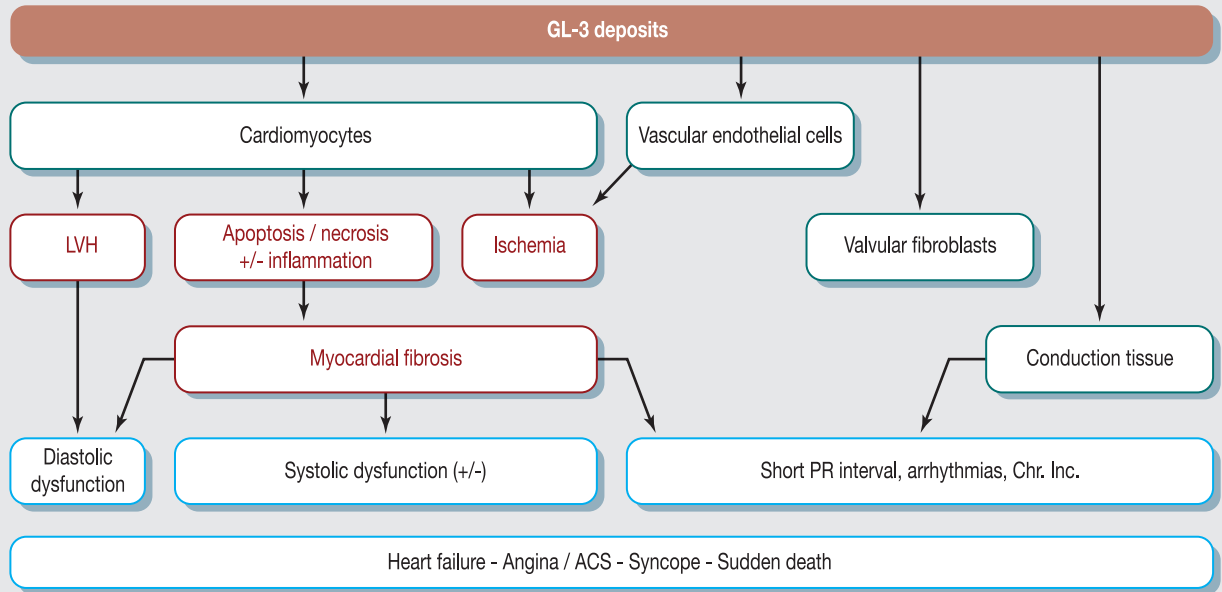
- [48] Germain DP, Weidemann F, Abiose A, et al. Analysis of left ventricular mass in untreated men and in men treated with agalsidase-beta: data from the Fabry Registry. *Genet Med* 2013;15:958-65.
- [49] Weidemann F, Niemann M, Breunig F, et al. Long-term effects of enzyme replacement therapy on fabry cardiomyopathy: evidence for a better outcome with early treatment. *Circulation* 2009;119:524-9.
- [50] Germain DP, Hughes DA, Nicholls K, et al. Treatment of Fabry's Disease with the Pharmacologic Chaperone Migalastat. *N Engl J Med* 2016;375:545-55.

Figure legends

Figure 1. Pathophysiology of the cardiac damage in Fabry disease, and clinical consequences. ACS: acute coronary syndrome; Chr. Inc.: chronotropic incompetence; GL-3: globotriaosylceramide; LVH: left ventricular hypertrophy.

Figure 2. When should Fabry disease (FD) be suspected in cardiology patients? Systematic examinations (in bold) are used to orient towards a diagnosis of FD in patients with left ventricular hypertrophy (LVH) and for screening of cardiac involvement in patients with confirmed FD, with or without LVH (in the latter case examinations should be repeated periodically every 6–12 months). α -Gal A: α -galactosidase A; AV: atrioventricular; ECG: electrocardiogram; GFR: glomerular filtration rate; HCM: hypertrophic cardiomyopathy; HRV: heart rate variability; hs-TNN: high-sensitivity troponin; LGE: late gadolinium enhancement; LV: left ventricle; MRI: magnetic resonance imaging; TIA: transient ischaemic attack.

Figure 3. Cardiac imaging for Fabry disease in a 65-year-old female heterozygote (p.Gly183Asp mutation). She presented unexplained dizziness episodes leading to a long-term (3-year) Holter electrocardiogram monitoring implantation; severe conduction abnormalities were identified (complete right bundle branch block, high-degree atrioventricular block) along with sustained ventricular tachycardia, which justified implantation of a pacemaker-implantable cardioverter defibrillator. Her 30-year-old son underwent kidney dialysis and then transplantation. Echocardiography (upper panel, from left to right) with concentric moderate homogeneous left ventricular hypertrophy, right ventricular hypertrophy and alteration of longitudinal strain in basal posterolateral segments; magnetic resonance imaging (lower panel, from left to right) with typical late gadolinium enhancement in the basal segment of the posterolateral wall (white myocardial area) and basal short-axis T1 mapping of the myocardium at 1.5 Tesla with homogenous low T1 values (in blue, corresponding to a T1 at 800 ms).



LVH in an adult patient : when should Fabry disease be suspected ?

HCM (unexplained LVH $\geq 15\text{mm}$)

Systematically consider FD in males ≥ 30 years, females ≥ 40 years particularly if :

FD/ HCM reference centers

Males : α -Gal A and gene-testing, females : gene-testing.

Unexplained LVH 13-15mm in

males ≥ 30 years, females ≥ 40 years particularly if :

Alert signs :

- **Extracardiac abnormalities** : kidney dysfunction, stroke / TIA, angiokeratoma, corneal verticillata...
- **ECG / 48-hour Holter** : short PR interval, AV block, decreased HRV, pacemaker, arrhythmias.
- **Echocardiography** : concentric LVH (13-22mm), non-obstructive HCM, abnormal infero-lateral longitudinal strain, right ventricular hypertrophy, thinning of the basal infero-lateral LV wall.
- **Cardiac MRI** : Postero-lateral LGE, reduction in non-contrast T1 signal, elevated T2.
- **Biology** : decreased GFR, proteinuria, hs-TNN.
- **Family history** (no father-to-son transmission, cryptogenic stroke, severe kidney failure).

