



HAL
open science

Management of epithelial cancer of the ovary, fallopian tube, and primary peritoneum. Short text of the French Clinical Practice Guidelines issued by FRANCOGYN, CNGOF, SFOG, and GINECO-ARCAGY, and endorsed by INCa

V Lavoué, C Huchon, C Akladios, P Alfonsi, N Bakrin, M Ballester, S Bendifallah, P A Bolze, F Bonnet, C Bourgin, et al.

► **To cite this version:**

V Lavoué, C Huchon, C Akladios, P Alfonsi, N Bakrin, et al.. Management of epithelial cancer of the ovary, fallopian tube, and primary peritoneum. Short text of the French Clinical Practice Guidelines issued by FRANCOGYN, CNGOF, SFOG, and GINECO-ARCAGY, and endorsed by INCa. *European Journal of Obstetrics & Gynecology and Reproductive Biology*, 2019, 236, pp.214-223. 10.1016/j.ejogrb.2019.03.010 . hal-02088076

HAL Id: hal-02088076

<https://univ-rennes.hal.science/hal-02088076>

Submitted on 17 Apr 2019

HAL is a multi-disciplinary open access archive for the deposit and dissemination of scientific research documents, whether they are published or not. The documents may come from teaching and research institutions in France or abroad, or from public or private research centers.

L'archive ouverte pluridisciplinaire **HAL**, est destinée au dépôt et à la diffusion de documents scientifiques de niveau recherche, publiés ou non, émanant des établissements d'enseignement et de recherche français ou étrangers, des laboratoires publics ou privés.

Management of epithelial cancer of the ovary, fallopian tube, and primary peritoneum.
Short text of the French Clinical Practice Guidelines issued by FRANCOGYN, CNGOF,
SFOG, and GINECO-ARCAGY, and endorsed by INCa.

Lavoue V^{1*}, **Huchon C**², Akladios C³, Alfonsi P⁴, Bakrin N⁵, Ballester M⁶, Bendifallah S⁷, Bolze PA⁸, Bonnet F⁹, Bourgin C¹⁰, Chabbert-Buffet N⁷, Collinet P¹⁰, Courbiere B¹¹, De la motte rouge T¹², Devouassoux-Shisheboran M¹³, Falandry C¹⁴, Ferron G¹⁵, Fournier L¹⁶, Gladieff L¹⁷, Golfier F⁸, Gouy S¹⁸, Guyon F¹⁹, Lambaudie E²⁰, Leary A²¹, Lecuru F²², Lefrere-Belda MA²³, Leblanc E²⁴, Lemoine A⁹, Narducci F²⁴, Ouldamer L²⁵, Pautier P²¹, Planchamp F²⁶, Pouget N²⁷, Ray-Coquard I²⁸, Rousset-Jablonski C²⁸, Senechal-Davin C¹⁹, Touboul C²⁹, Thomassin-Naggara I³⁰, Uzan C³¹, You B³², **Darai E**⁷.

Affiliations:

1. Service de gynécologie, CHU de Rennes, Hôpital sud, 16 Bd de Bulgarie 35000 Rennes, France. INSERM 1242, Chemistry, Oncogenesis, Stress and Signaling, Centre Eugène Marquis, Rue Bataille Flandres-Dunkerques, Rennes, France.
2. Service de Gynécologie, CHI Poissy, France.
3. Service de Gynécologie, Hôpital Hautepierre, CHU Strasbourg, France
4. Service d'Anesthésie, Hôpital Saint Joseph, Paris, France.
5. Service de chirurgie digestive, CHU Lyon-Sud, Pierre-Bénite, Lyon, France.
6. Service de gynécologie, GH Diaconesses Croix Saint Simon, Paris, France.
7. Service de Gynécologie-Obstétrique et Médecine de la Reproduction, Hôpital Tenon, 4 rue de La Chine, APHP, Institut Universitaire de Cancérologie Sorbonne Université, UMRS-938.
8. Service de chirurgie gynécologique, CHU Lyon-Sud, Pierre Bénite, Lyon, France.

9. Service d'anesthésie, Hôpital Tenon, AP-HP, Paris, France
10. Service de Chirurgie Gynécologique, Hôpital Jeanne de Flandres, CHRU, Lille, France
11. Pôle Femmes-Parents-Enfants – Centre Clinico-Biologique d'AMP, AP-HM La Conception, 147 bd Baille, 13005 Marseille / Aix Marseille Université, CNRS, IRD, Avignon Université, IMBE UMR 7263, 13397, Marseille, France
12. Service d'oncologie médicale, Centre Eugène Marquis, Rennes, France.
13. Service d'anatomo-pathologie, Hospices civiles de Lyon, CHU Lyon-Sud, Pierre-Bénite, Lyon, France.
14. Service d'oncogériatrie, Hospices civiles de Lyon, CHU Lyon-Sud, Pierre-Bénite, Lyon, France.
15. Service d'oncologie chirurgicale, Institut Claudius Regaud, IUCT Oncopole, Toulouse, France.
16. Service de radiologie, Hôpital Européen Georges Pompidou, AP-HP, Paris.
17. Service d'oncologie médicale, Institut Claudius Regaud, IUCT Oncopole, Toulouse, France.
18. Service de chirurgie, Institut Gustave Roussy, Villejuif, France.
19. Service de chirurgie, Institut Bergonié, Bordeaux, France.
20. Service de chirurgie, Institut Paoli Calmette, Marseille, France.
21. Service d'oncologie médicale, Institut Gustave Roussy, Villejuif, France.
22. Service de chirurgie gynécologique et oncologique, Hôpital Européen Georges Pompidou, AP-HP, Paris, France.
23. Service d'anatomo-pathologie, Hôpital Européen Georges Pompidou, AP-HP, Paris, France.
24. Service de chirurgie, Centre Oscar Lambret, Lille, France.
25. Service de chirurgie gynécologique, CHU de Tours, France.

26. Service de méthodologie, Institut Bergonié, Bordeaux, France.
27. Service de chirurgie, Curie (site Saint Cloud), Paris, France.
28. Service d'oncologie médicale, Centre Léon Bérard, Lyon, France.
29. Service de chirurgie gynécologique, CHI de Créteil, Créteil, France.
30. Service de radiologie, Hôpital Tenon, AP-HP, Paris, France.
31. Service de chirurgie et cancérologie gynécologique et mammaire, Hôpital Pitié Salpêtrière, Institut Universitaire de Cancérologie, Sorbonne Université, INSERM U938.
32. Service d'oncologie médicale, Institut de cancérologie des Hospices Civils de Lyon, Pierre-Bénite, Lyon, Paris.

*Auteur correspondant : Pr Vincent Lavoué, Service de chirurgie gynécologique, CHU Hôpital Sud, 16 Bd de Bulgarie, 35000 Rennes, France. Vincent.lavoue@chu-rennes.fr

Corresponding author: Pr Vincent LAVOUE. Vincent.lavoue@chu-rennes.fr. Service de chirurgie gynécologique. CHU Hôpital sud, 16 BD de Bulgarie, 35000 RENNES, FRANCE.

Summary:

An MRI is recommended for an ovarian mass that is indeterminate on ultrasound. The ROMA score (combining CA125 and HE4) can also be calculated (Grade A). In presumed early-stage ovarian or tubal cancers, the following procedures should be performed: an omentectomy (at a minimum, infracolic), an appendectomy, multiple peritoneal biopsies, peritoneal cytology (grade C), and pelvic and para-aortic lymphadenectomies (Grade B) for all histologic types, except the expansile mucinous subtypes, for which lymphadenectomies can be omitted (grade C). Minimally invasive surgery is recommended for early-stage ovarian cancer, when there is no risk of tumor rupture (grade B). Adjuvant chemotherapy by carboplatin and paclitaxel is recommended for all high-grade ovarian and tubal cancers (FIGO stages I-IIA) (grade A). For FIGO stage III or IV ovarian, tubal, and primary peritoneal cancers, a contrast-enhanced computed tomography (CT) scan of the thorax/abdomen/pelvis is recommended (Grade B), as well as laparoscopic exploration to take multiple biopsies (grade A) and a carcinomatosis score (Fagotti score at a minimum) (grade C) to assess the possibility of complete surgery

(i.e., leaving no macroscopic tumor residue). Complete surgery by a midline laparotomy is recommended for advanced ovarian, tubal, or primary peritoneal cancers (grade B). For advanced cancers, para-aortic and pelvic lymphadenectomies are recommended when metastatic adenopathy is clinically or radiologically suspected (grade B). When adenopathy is not suspected and when complete peritoneal surgery is performed as the initial surgery for advanced cancer, the lymphadenectomies can be omitted because they do not modify either the medical treatment or overall survival (grade B). Primary surgery (before other treatment) is recommended whenever it appears possible to leave no tumor residue (grade B). After primary surgery is complete, 6 cycles of intravenous chemotherapy (grade A) are recommended, or a discussion with the patient about intraperitoneal chemotherapy, according to her risk-benefit ratio. After complete interval surgery for FIGO stage III disease, hyperthermic intraperitoneal chemotherapy (HIPEC) can be proposed, in accordance with the modalities of the OV-HIPEC trial (grade B). In cases of postoperative tumor residue or in FIGO stage IV tumors, chemotherapy associated with bevacizumab is recommended (grade A).

Keywords: ovarian cancer; tubal cancer, primary peritoneal cancer, surgery; chemotherapy; guidelines

Introduction

Initial management of epithelial ovarian cancers is relatively heterogeneous in France, with treatment sequences that differ substantially between centers for primary or interval surgery. Similarly, the extent of surgery and the surgical staging procedures vary according to patient characteristics (young vs elderly women, for example). Perioperative management, whether it concerns early recovery or fertility preservation, has not been standardized, although it can cause physical or psychological morbidity. Finally, cancer centers vary widely in their use of chemotherapy (and how they administer it), as well as of targeted therapies; a national strategy remains to be defined, according to different clinical contexts. Work to develop

clinical practice guidelines is therefore necessary to enable practices to be homogenized in accordance with the best evidence and to improve prognosis for all patients.

Accordingly, the French research group for oncologic gynecologic surgery (FRANCOGYN), the French national college of gynecologists and obstetricians (CNGOF), the French society of gynecologic oncology (SFOG), and the national investigators' group for studies in ovarian and breast cancer (GINECO-ARCAGY) jointly brought together a working group to develop such guidelines. This text is a synthesis of clinical practice guidelines for the initial management of epithelial ovarian, tubal, or primary peritoneal cancers (excluding recurrence of ovarian cancer and borderline tumors).¹ The development of these clinical practice guidelines followed the standards set by the French national authority for health (HAS) and the national cancer institute (INCa), with reviews by experts both within and outside the working group.¹⁻³ INCa has endorsed these clinical practice guidelines.

Their aim is to aid professionals (gynecologic surgeons, surgeons specialized in gynecologic oncology, medical gynecologists, gynecologist-obstetricians, pathologists, medical oncologists, radiologists, anesthetist-critical-care specialists, nuclear physicians, general practitioners, midwives, and paramedical personnel) in managing women with ovarian cancer or with suspected ovarian, tubal, or primary peritoneal cancer.

I- Management of early-stage ovarian or tubal cancer (FIGO stages I-IIa)

Transvaginal and transabdominal (suprapubic) ultrasound are recommended for the analysis of an isolated ovarian mass (grade A).² Expert operators performing ultrasound should apply their subjective analysis to determine if the mass is benign or malignant (grade A). It is recommended that non-expert operators performing ultrasound use the Simple Rules (grade A). These rules must be combined with subjective analysis to equal

the performance of expert ultrasonographers (grade A). According to the Simple Ultrasound Rules (Table 1):

- The mass is classified as malignant if at least one M (malignant) rule applies and no B (benign) rule applies.
- The mass is classified as benign if at least one B rule applies and no M rule applies.
- It cannot be classified (or is indeterminate) if at least one M rule and one B rule both apply or if no rule applies.

Software is available without charge at the IOTA site (www.iotagroup.org), and an application is available for both Android and iOS. Around 25% of adnexal masses remain indeterminate with the Simple Rules and require a second-line examination.

When an adnexal mass is complex or indeterminate on ultrasound, a pelvic MRI is recommended (grade A). MRI to characterize an adnexal mass should use T2, T1, T1 Fat Sat, dynamic contrast-enhanced, diffusion-weighted, and gadolinium-enhanced sequences (grade B) to improve diagnostic sensitivity (grade B). It is recommended that an MRI report characterizing an adnexal mass include a malignancy risk score (such as ADNEX MR, Table 2) (grade C). Moreover, the use of the apparent distribution coefficient (ADC) makes it possible to differentiate borderline from invasive tumors, in particular to differentiate seromucinous borderline tumors from invasive cancers on endometriomas of endometrioid or clear cells. **A pathological hypothesis should be included in the MRI report of an adnexal mass (grade C).**

The ROMA score (based on serum assays of HE4 and CA125) can be used for an adnexal mass that is indeterminate on ultrasound (grade A).⁴ The CNAM-TS (French national health insurance fund) does not reimburse the HE4 serum assay.

When an adnexal mass is suspected to be an ovarian cancer, an intraoperative pathology examination can be performed to enable optimal surgical staging during a single surgical procedure and thus avoid the need for reintervention (grade B).³

In presumed early-stage ovarian cancer, the following procedures have to be performed: an omentectomy (at a minimum, infracolic), an appendectomy, peritoneal biopsies, peritoneal cytology (grade C), and pelvic and para-aortic lymphadenectomies (Grade B) except for the expansile mucinous subtypes, for which the lymphadenectomies can be omitted.⁵

If the initial staging was not performed or was incomplete (defined by any of: no omentectomy, no exploration or resection of the appendix, no pelvic or para-aortic lymphadenectomy or peritoneal biopsies) for a presumed early-stage ovarian cancer, surgical restaging is recommended, including omentectomy (at least infracolic) (grade C), appendectomy (grade C), pelvic and para-aortic lymphadenectomies (grade B) (except for expansile mucinous cancer), and peritoneal biopsies (grade C), especially in the absence of an indication for chemotherapy.⁵

In presumed early-stage ovarian cancer, a minimally invasive approach is recommended if complete surgery is possible without the risk of tumor rupture (grade B). Otherwise, a midline laparotomy is recommended (grade B). Every precaution must be taken to avoid the intraoperative rupture of an ovarian tumor, including an intraoperative decision to convert to open surgery (grade B). For surgical restaging, a minimally invasive approach have to be preferred when the ovarian mass has already been removed (grade B).⁵

Adjuvant chemotherapy is recommended for all high-grade ovarian and tubal cancers (FIGO stages I-IIA) (grade A).⁶ Adjuvant chemotherapy for early-stage ovarian or tubal cancer must include a platinum compound (grade A), preferably carboplatin (grade A).

For high-grade serous carcinomas, an additional drug is recommended rather than use of this single agent (grade B). The chemotherapy recommended for early-stage ovarian or tubal cancer is based on the combination of carboplatin (AUC 5-6) on D1 and paclitaxel (175 mg/m²) on D1 every 3 weeks (grade B). Chemotherapy for stage IA or IB ovarian or tubal cancer must include at least 3 cycles and a maximum of 6 (grade A). For stage I high-grade serous carcinoma of the ovary or fallopian tubes and for the other histologic types of FIGO stages \geq IC tumors, 6 cycles of chemotherapy are recommended (grade C).

No guidelines can be issued about chemotherapy indications for stage IA or IB ovarian carcinomas of the following types: low-grade serous, low-grade endometrioid, clear-cell or mucinous. It may be useful to refer to the guidelines of the network of rare ovarian tumors.

Modalities and strategies for fertility preservation for young women with FIGO stage I ovarian cancer⁷

Women of child-bearing age should be informed about the possibility of conservative management of their fertility in cases of stage IA epithelial ovarian cancer (Grade C). Conservative surgical management of the uterus and the contralateral adnexa after a unilateral adnexectomy for a low-grade serous, mucinous, or endometrioid stage IA ovarian cancer may be offered to women of child-bearing age, on condition that complete peritoneal and lymph node staging are negative, along with the findings of the uterine curettage for the endometrioid and mucinous histologic subtypes (Grade C). Women who wish for fertility preservation must be informed that there is a risk of recurrence in the contralateral ovary ranging between 6 and 13%.

For serous, mucinous, and endometrioid ovarian cancers that are either high-grade FIGO stage IA or low-grade stages IC1 or IC2, a bilateral adnexectomy may be proposed with uterine preservation, to envision a pregnancy later by oocyte donation

(Grade C). No data exist to justify guidelines about uterine preservation in women with FIGO stage IB tumors. **For FIGO stage I clear-cell cancer, preservation of the uterus and contralateral adnexa can be discussed on a case-by-case basis in a multidisciplinary meeting for consultation on rare tumors. Surgery to preserve the uterus is not recommended for women with epithelial ovarian cancers at FIGO stages \geq IIa (beyond the pelvis) (Grade C).**

Before any decision is made about conservative surgery of stage I ovarian cancer, it is recommended that the risk-benefit balance of fertility-preserving surgery be assessed in a multidisciplinary consultation with the oncologist and a physician specializing in reproduction (grade C).

II- Management of advanced ovarian, tubal, and primary peritoneal cancers (FIGO stages IIB-IV)

A contrast-enhanced CT scan of the thorax/abdomen/pelvis is recommended for the preoperative workup of the extension and resectability of ovarian, tubal, or primary peritoneal carcinomatosis (grade B).² The CT report should specify the presence of substantial ascites, the overall extent of the carcinomatosis, as well as involvement of the mesentery, the extended gastrointestinal tract, the lesser omentum, the hepatic hilum, suprarenal para-aortic adenopathy, abdominal parenchymal (hepatic etc.) or extra-abdominal metastases (umbilical or parietal, pulmonary, inguinal, or mediastinal lymph nodes).

If iodinated contrast agents are contraindicated (severe kidney failure, GFR < 30 mL/min, allergies), an abdominal/pelvic MRI supplemented by a CT scan without contrast enhancement can replace the thorax/abdomen/pelvis CT scan (grade C).

Data assessing the diagnostic performance of radiologic examinations to assess response to chemotherapy are sparse. **No guideline can be issued about the best type of imaging after neoadjuvant chemotherapy to assess the resectability of ovarian, tubal, or primary peritoneal carcinomatosis**

Laparoscopy is recommended to assess the feasibility of surgical resection that leaves no macroscopic tumor residue (i.e., complete surgery) in a woman with ovarian, tubal, or primary peritoneal carcinomatosis before laparotomic surgery (grade A).⁴

Several scores for assessing the extension of peritoneal carcinomatosis have been developed. The Fagotti score is a laparoscopic score based on 7 indicators rated 0 or 2 (Table 3).

For women with ovarian, tubal, or primary peritoneal carcinomatosis, the use of a carcinomatosis score (at least the Fagotti score) during laparoscopy is recommended to assess the risk of nonresectability during primary or interval surgery (grade C). A Fagotti score ≥ 8 is correlated with a low rate of complete primary surgery (LE4). A Fagotti score ≥ 4 is correlated with a low rate of complete interval surgery (LE4).⁴

In women undergoing laparotomy for ovarian, tubal, or primary peritoneal carcinomatosis, use of the Peritoneal Cancer Index (PCI) is recommended to assess the tumor burden (grade C).

The tumor residue after primary or interval surgery is an essential prognostic factor, regardless of histologic type (serous or other, high or low grade) (LE2). **Complete surgery (i.e., with no macroscopic tumor residue) of advanced ovarian, tubal, or primary peritoneal cancer is recommended (Grade B). Surgery for ovarian cancer should be**

performed in a high-volume hospital (defined by performance of at least 20 procedures for advanced ovarian cancer each year) (Grade C). Adjuvant chemotherapy should begin within 6 weeks after surgery for ovarian, tubal, or primary peritoneal cancer (Grade C).⁸

In FIGO stage IV ovarian, tubal, and primary peritoneal cancer, surgery is recommended when a complete peritoneal abdominal resection (i.e., with no macroscopic tumor residue) is possible (grade C).

Three published meta-analyses, including both published cohorts and 3 randomized trials, have assessed the systematic surgical dissection of pelvic and para-aortic lymph nodes in advanced cancer (LE2). They show a benefit from systematic dissection with an improvement in overall survival (HR=0.74; 95% CI 0.59-0.94, $P=0.01$) including for the procedures considered optimal (i.e., with a tumor residue 1 cm or less in maximum diameter). Nonetheless, the only prospective randomized trial (Panici et al.) currently published concerning advanced stages (and included in these meta-analyses) found no improvement in 5-year overall survival but only a prolongation of recurrence-free survival (LE2). These data are consistent with the published abstract of the LION trial presented at ASCO in 2017, which randomized women with ovarian carcinomatosis and no observed adenopathy (not visible on CT nor palpable at primary surgery after complete resection) to either systematic dissection or no dissection. This study found an identical overall survival rate among women who did and did not have dissections among the selected population, i.e., women with neither radiologic nor clinical adenopathy (LE2). On the other hand, benefits for both overall and recurrence-free survival were observed for systematic dissections when clinically or radiologically suspicious lymph nodes were present (LE2).

In advanced ovarian, tubal, or primary peritoneal cancer with no macroscopic tumor residue at the end of surgery, para-aortic and pelvic lymphadenectomies are

recommended when metastatic adenopathy is suspected, either clinically or radiologically (Grade B). In the absence of such suspected adenopathy and when complete peritoneal surgery is performed as the initial surgery for advanced ovarian, tubal, or primary peritoneal cancers, the lymphadenectomies can be omitted because they do not modify either the medical treatment or overall survival (grade B). The other lymphadenectomies (suprarenal, mesenteric, laparoscopic hepatic, cardiophrenic angle) are not recommended in the absence of clinical invasion (grade C). Finally, it is not possible to make specific recommendations about the role of lymphadenectomy according to histologic subtype or grade, due to the lack of data.

The treatment sequences of primary cytoreductive surgery and then adjuvant chemotherapy vs neoadjuvant chemotherapy and interval surgery after 3 or 4 treatments have not shown differences for overall or progression-free survival (LE1) (Table 4). The interval surgery strategies have shown a significant diminution of morbidity and mortality and an improved quality of life, especially in advanced stages with a high tumor burden (LE2). The 5-category classification by Makar et al. is useful for assessing the tumor burden in FIGO stage III carcinomatosis (LE2):

- Category 1: The tumor is localized in the pelvis, with little or no ascites and no need for gastrointestinal resection. Primary cytoreductive surgery is recommended

- Category 2: The tumor is localized in the pelvis, with little or no ascites. Gastrointestinal resection is necessary for complete cytoreduction. Primary cytoreductive surgery is recommended

- Category 3: A large portion of the tumor is localized in the supramesocolic space, with little or no ascites. No gastrointestinal resection is needed. Primary cytoreductive surgery is recommended

- Category 4: A large portion of the tumor is localized in the supramesocolic space,

with little or no ascites. Gastrointestinal resection is necessary for complete cytoreduction. Primary cytoreductive surgery is recommended. In cases of impaired general condition, comorbidities, or advanced age, interval surgery can instead be envisioned after 3 cycles of neoadjuvant chemotherapy.

- Category 5: A very large portion of the tumor is localized in the supramesocolic space, with abundant ascites or miliary patterns on the mesentery. Initial cytoreduction may require several gastrointestinal resections. Neoadjuvant chemotherapy is recommended. Primary surgery is not contraindicated for FIGO stage 4 disease.

Neoadjuvant chemotherapy and then interval surgery are recommended for multiple intrahepatic masses, or pulmonary metastases, or substantial ascites with miliary patterns (LE1).

In advanced ovarian, tubal, or primary peritoneal carcinomatosis, primary surgery is recommended when it appears that complete surgery (i.e., no macroscopic tumor residue in the abdomen) is possible on condition that the surgery is acceptable in terms of morbidity, given both the complexity of the procedure and the patient's comorbidities (grade B). If complete cytoreduction (no tumor residue) does not appear possible, neoadjuvant chemotherapy should be offered, to be followed by interval surgery (Grade B) after 3 or 4 courses of chemotherapy (grade C). Makar's five categories are useful for choosing between primary surgery and interval surgery after neoadjuvant chemotherapy as the treatment strategy (grade C).

The specific histologic subtype is important: chemotherapy response is significantly poorer in low-grade compared to high-grade serous carcinomas (23.1% vs 90.1%) (LE3). Indirect data also show that the mucinous and clear-cell histologic subtypes respond less well to chemotherapy by platinum compounds and taxanes. **For advanced ovarian, tubal, and primary peritoneal cancers of particular histologic subtypes (mucinous, clear-cell, and**

low-grade serous), primary surgery should be preferred over neoadjuvant chemotherapy when complete resection is possible from the start (grade C).

The surgical report for cytoreduction of advanced ovarian, tubal, or primary peritoneal cancer **should assess the tumor burden (grade C) according to the PCI (Peritoneal Cancer Index) score** and should indicate the reasons for tumor non resectability if no cytoreduction surgery was performed, indicate if the surgery was complete, and state the size and site of any tumor residue. Use of a standardized surgical report is helpful.

Role of the intraperitoneal approach for administering chemotherapy (hyperthermic (HIPEC) or normothermic) in advanced ovarian, tubal, or primary peritoneal cancers

Intraperitoneal (IP) chemotherapy without hyperthermia

Experienced teams can offer adjuvant intraperitoneal (IP) chemotherapy after primary surgery with tumor residue < 10 mm for ovarian, tubal, or primary peritoneal carcinomatosis. The recommended protocol is paclitaxel 135 mg/m² for 3 h or 24 h intravenous (IV) on D1, cisplatin 75 to 100 mg/m² IP on D2, and paclitaxel 60 mg/m² IP on D8, every 3 weeks for 6 cycles. The risk-benefit ratio of the IP versus the IV pathway should be discussed with the woman in view of the higher complication rate with IP. If IP chemotherapy must be interrupted, treatment must be continued by the IV pathway (Grade B). No data exist to propose a recommendation about the use of bevacizumab after IP chemotherapy.⁹

Intraperitoneal pathway with hyperthermia: HIPEC

As of today, one phase III randomized trial has assessed the role of HIPEC for ovarian cancer with interval surgery. It demonstrated that, with strict protocol adherence, median relapse-free survival in the surgery-only arm was 10.7 months and in the surgery + HIPEC arm, 14.2

months ($P=0.003$), with median overall survival 33.9 and 45.7 months ($P=0.02$), respectively, with a median follow-up of 4.7 years. Toxicity rates were equivalent in both arms (25% and 27%, $P=0.74$); the most frequent grade 3-4 toxicity reports concerned abdominal pain, infections, and ileus. Durations of hospitalization were similar (8 vs 10 days). The time to resumption of chemotherapy was almost the same in both arms (30 vs 33 days); 90% of the women in the surgery-only arm and 94% in the surgery + HIPEC arm received the 3 planned cycles of postoperative chemotherapy (LE1). These results underline the potential role of HIPEC but require confirmation, at a minimum by prospective registries.

In initially nonresectable FIGO stage III ovarian, tubal, and primary peritoneal cancers, hyperthermic intraperitoneal chemotherapy (HIPEC) can be offered after interval surgery expected to be complete or optimal (tumor residue < 1 cm), performed after 3 cycles of intravenous (IV) chemotherapy (grade B). The protocol must include cisplatin 100 mg/m² distributed at 50 mg/m² at the beginning of the procedure, 25 mg/m² at 30 min, and 25 mg/m² at 60 min, for a total duration of 90 min at 40-41° C, combined with hyperhydration and nephroprotection by IV sodium thiosulfate, by a bolus of 9 g/m² at the start of HIPEC, then 12 g/m² for 6 hours (grade B). At the publication of these guidelines, sodium thiosulfate is available only on temporary authorizations for a named patient (nominative ATU). No data exist to justify a recommendation about the use of bevacizumab after HIPEC.⁹

Role of systemic intravenous treatments of advanced (FIGO stages IIB-IV) ovarian, tubal, or primary peritoneal cancers.⁶

Chemotherapy is recommended for all advanced stage (FIGO stages IIB-IV) ovarian, tubal, and primary peritoneal cancers (Grade A). A platinum compound (Grade A), preferentially carboplatin (Grade A), together with another substance (Grade A), is recommended as the standard chemotherapy for these advanced cancers.

The preferential use of the combination of carboplatin (AUC 5-6) on D1 and paclitaxel (175 mg/m²) on D1 every 3 weeks is recommended and considered the standard regimen for advanced ovarian, tubal, and primary peritoneal cancers (Grade A).

The following alternatives to this standard regimen for these advanced cancers may be proposed:

- Weekly fractionation of chemotherapy with carboplatin (AUC 2) on D1, D8, and D15, and paclitaxel (60 mg/m²) on D1, D8, and D15 every 3 weeks to limit their adverse effects (reduction in both alopecia and neurological toxicity) (Grade B).**
- If paclitaxel is contraindicated, the combination of carboplatin (AUC 5) on D1 and pegylated liposomal doxorubicin (30 mg/m²) on D1 every 4 weeks can be proposed (Grade B), as can single-agent chemotherapy with carboplatin (AUC 5) every 3 weeks (Grade B).**
- If carboplatin is contraindicated, cisplatin (75 mg/m²) can be combined with paclitaxel (175 mg/m²) every 3 weeks (Grade A).**

A duration of at least 6 treatment cycles is recommended for chemotherapy for advanced ovarian, tubal, or primary peritoneal cancers (Grade A).

A regimen of carboplatin (AUC 5 or 6) and paclitaxel (175 mg/m²) every 3 weeks is recommended for neoadjuvant treatment for advanced ovarian, tubal, or primary peritoneal cancers (Grade A).

Interval surgery is recommended after 3 to 4 cycles of treatment for advanced ovarian, tubal, or primary peritoneal cancers (Grade C). The number of cycles of adjuvant chemotherapy after interval cytoreduction surgery will be 2 to 4, for a minimum total of 6 cycles and a maximum of 9 (Grade C).

Chemotherapy should begin less than 6 weeks after cytoreduction surgery in advanced ovarian, tubal, or primary peritoneal cancer (grade C).

Bevacizumab can be proposed together with chemotherapy by carboplatin and paclitaxel for up to 6 cycles of treatment and then alone as maintenance for a maximum of 15 months or until toxicity becomes unacceptable for women with FIGO stages III and IV cancers (FIGO 2014), especially those with the worst prognosis (stage IV, postoperative tumor residue, or no surgery) (grade A). Bevacizumab with chemotherapy must be omitted in cycle 1 if the treatment begins less than 4 weeks after primary (grade A) or interval (Grade B) cytoreduction surgery. In the absence of any demonstration of the clinical utility of bevacizumab together with neoadjuvant chemotherapy, no recommendation in this situation is currently justified. Interval surgery after bevacizumab is not contraindicated.

Olaparib is currently used for maintenance after chemotherapy in women with platinum-sensitive relapsed ovarian cancer who have a BRCA1/2 tumor or germline mutation. Its demonstrably high efficacy in this situation led to its authorization in 2014. The results of the SOLO-1 phase III randomized double-blinded, placebo-controlled trial that assessed olaparib as maintenance therapy after standard first-line treatment were published in the *New England Journal of Medicine*.¹⁰ The principal objective of this trial was to demonstrate the superiority

of olaparib as maintenance treatment for progression-free survival. Overall, 391 women with FIGO stages III-IV high-grade serous or endometrioid cancer with a BRCA1/2 mutation were included; they were randomized 2:1 between olaparib and placebo after the end of the initial treatment sequence including primary or interval surgery and carboplatin-based chemotherapy. The maintenance treatment continued until progression or for a maximum of 24 months in its absence. The median follow-up was 41 months. The principal objective of the study was largely achieved, with a median progression-free survival corresponding to around 3 years in the olaparib group vs 13.8 months in the placebo group; HR=0.30; 95% CI 0.23-0.41; $P<0.0001$. This corresponds to an improvement of around 3 years in the median progression-free survival. The analyses of second progression-free survival (PFS2) (time from randomization to second disease progression or death), first subsequent treatment or death, and second subsequent treatment or death were also positive and confirm the principal endpoint. The data for overall survival remain immature. The groups did not differ for quality of life. From the perspective of toxicity, no new signal was observed for patients treated at relapse.

Olaparib as maintenance treatment after primary or interval surgery and first-line chemotherapy is recommended at a dose of 300 mg tablets \times 2/24 h orally for 24 months or until progression in women with FIGO stages III-IV high-grade serous or endometrioid ovarian, tubal, or primary peritoneal cancer and a BRCA1/2 mutation. (Grade B). At the time these guidelines were drafted, olaparib is not yet authorized as first-line treatment. Rapid testing for BRCA mutations is necessary at diagnosis of ovarian cancer to determine if olaparib is indicated (Figure 4). *In view of French regulatory provisions (need for ANSM approval, possibility of ATU, etc.), INCa will not endorse this guideline until after olaparib has been authorized for this indication. As of now, no data are available about the combination of bevacizumab and olaparib.*⁶

III- Management of older women with ovarian, tubal, or primary peritoneal cancer¹¹

Women aged 70 years or older account for a constantly increasing portion of the population, given its continuous aging. Those with ovarian cancer have a poorer prognosis than younger women: overall survival at 1 year for women aged ≥ 80 years is 36.9%, from 75-79 years 59.3%, from 70-74 years 68.4%, and from 65-69 years 73.5% (LE4). Advanced age currently leads to especially heterogeneous management of ovarian cancer. The lower rates of complete and optimal surgery and of complete chemotherapy indicate undertreatment of elderly women with ovarian cancer. **Older women with ovarian, tubal, or primary peritoneal cancer should receive cytoreduction surgery in high-volume centers (performing more than 20 procedures for advanced ovarian cancer annually) (grade C). This surgery is recommended in elderly women (Grade B) provided that comorbidities and the likelihood of complete surgery allow it.**

The risk-benefit ratio of surgery for ovarian, tubal, and primary peritoneal cancer should be assessed on a case-by-case for the populations at the highest risk of complications (LE4), defined by:

- **Age ≥ 80 years, especially with albuminemia ≤ 37 g/L**
- **Age ≥ 75 years and FIGO stage IV**
- **Age ≥ 75 years, FIGO stage III and ≥ 1 comorbidity.**

A geriatric oncology assessment is recommended before the management of elderly women with ovarian, tubal, or primary peritoneal cancer (grade C).

Elderly with no frailty with ovarian, tubal, or primary peritoneal cancers should receive intravenous chemotherapy identical to that for younger women (i.e., two agents, platinum-based) (grade B).

Neoadjuvant chemotherapy was most cost-effective in elderly women at high risk of complications (i.e., age \geq 75 years and FIGO stage IV or age \geq 75 years and stage III and at least 1 comorbidity) in the SEER database (LE4); in the EORTC study, it was associated with a lower complication rate and a higher rate of optimal surgery for elderly women (LE4).

In advanced ovarian, tubal, and primary peritoneal cancers, neoadjuvant chemotherapy diminishes the complexity of the surgical procedure and the perioperative morbidity and mortality of the interval surgery (LE1). In these advanced stage cancers, starting with chemotherapy is a good alternative for those 70 years or older with comorbidities or with extensive peritoneal carcinomatosis requiring complex initial surgery (LE4).

IV- Perioperative prehabilitation for and recovery from ovarian cancer surgery¹²

Preoperative management

For women with ovarian, tubal, or primary peritoneal cancer, screening is recommended before surgery for nutritional deficiencies (Grade B) and anemia (grade C). No data justify recommendations about preoperative correction of nutritional deficiencies, immunonutritional deficiencies, or anemia in women with ovarian, tubal, or primary peritoneal cancers.

Similarly no specific data about these cancers justify guidelines for preoperative bowel preparation.

Intraoperative management

For women with advanced stage ovarian, tubal, or primary peritoneal cancers, individualized monitoring to ensure intraoperative goal-directed fluid management is recommended (Grade B).

Women undergoing surgery for ovarian, tubal, or primary peritoneal cancer may be offered an infusion of a single dose of tranexamic acid to reduce intraoperative blood loss (Grade C).

Epidural analgesia, in addition to general anesthesia, is recommended for the management of women undergoing laparotomic cytoreduction surgery for ovarian, tubal, or primary peritoneal cancer (Grade B). In the absence of epidural analgesia, patient-controlled administration of morphine is recommended, but without a continuous flow (Grade B).

No data justify a recommendation about intravenous administration of lidocaine or ketamine during surgery or the perioperative prescription of gabapentine or pregabalin.

Postoperative management

Early oral feeding is recommended, including after gastrointestinal resection for ovarian, tubal, or primary peritoneal cancer (Grade B).

The establishment of protocols for enhanced recovery after surgery (ERAS), including early mobilization, is recommended to reduce the length of stay after surgery for these cancers (Grade C).

V- Role of biopathology (pathology, intraoperative pathology examination, and biomarkers) in the management of ovarian, tubal, and primary peritoneal cancer³

Before any chemotherapy, it is recommended that ovarian carcinomas (histologic type and grade) be diagnosed positively from biopsy samples and not from cytology (grade C). A surgical biopsy with multiple samples from different tumor sites is recommended before neoadjuvant chemotherapy for women with carcinomatosis of a presumed ovarian, tubal, or primary peritoneal origin (Grade C). A needle larger than 16G is recommended for image-guided microbiopsies, and at least three biopsy cores should be taken (Grade C). If no immunohistochemical study has been performed on the sample before chemotherapy or in cases of major morphologic discordance, this examination can be performed on residual tumor material after chemotherapy (Grade C).

After a biopsy for suspected ovarian, tubal, or primary peritoneal carcinomatosis, the tissue samples should be fixed in neutral buffered formalin (with 4% formaldehyde) as rapidly as possible (<1 h after excision) (for optimal morphologic, immunohistochemical, and nucleic acid preservation) (grade C). Vacuum packing and storage at +4°C can be an alternative, but only for very large pieces of excised tissue, to prolong this delay to a maximum of 48 h (grade C). Tissue samples (for biopsies) should be fixed for at least 6 h (grade C).

For pathology examination of excised tissue containing ovarian, tubal, or primary peritoneal carcinomas, preferential sampling is recommended from the solid areas, the tumor capsule, and areas of different macroscopic appearance (Grade C). In view of the heterogeneous nature of mucinous ovarian masses, 1 to 2 tissue blocks should be collected for each cm of tumor (Grade C). To determine the origin of a high-grade

serous carcinoma (ovarian versus tubal versus peritoneal), the tube and the entire tubal infundibulum should be sampled (Grade C). When there is no macroscopic involvement of the omentum, 6 tissue blocks should systematically be taken to detect most of the microscopic damage (Grade B). When macroscopic involvement of the omentum is observed, only one block should be taken, from the bulkiest macroscopic tumor nodule (Grade B). For the histologic diagnosis of the histologic subtypes and grade of an ovarian, tubal, or primary peritoneal carcinoma, the WHO 2014 classification should be used (Grade C) and an immunohistochemical study should be performed with a panel of antibodies (selected among the following: EMA, CK7, CK20, PAX8, WT1, p53, RE, RP, HNF1b, and/or napsin A) (Grade B).

Women with somatic mutations of the BRCA genes must be referred for an oncogenetic consultation. A study by INCa published in 2017 describes the importance of looking for a constitutional BRCA mutation and its utility in monitoring women and their family members at risk.

The pathology report of excised tissue after chemotherapy for ovarian, tubal, or primary peritoneal cancers should state the size and the site of the bulkiest residual tumor nodule (Grade C). The pathology report should also state if there are no (or < 5%) residual tumor cells after chemotherapy (Grade C).

VI- Post-treatment follow-up of ovarian, tubal, and primary peritoneal cancers and the role of hormone therapy¹³

After the conclusion of treatment of epithelial ovarian, tubal, or primary peritoneal cancer, an assessment of symptoms is recommended at 3, 6, 12, 18, and 24 months, and then yearly (Grade B)

If paraclinical monitoring is indicated for a woman after treatment of an epithelial ovarian, tubal, or primary peritoneal cancer, HE4 serum assays can be recommended

(grade B). The CNAM-TS does not reimburse the HE4 serum assay. In the absence of possible HE4 monitoring, CA125 serum assays can also be proposed (grade B).

After treatment of epithelial ovarian, tubal, or primary peritoneal cancer, any finding of elevated serum HE4 or CA125 levels should be followed by an imaging examination (grade B).

Peritoneal cytology is not only invasive but also has poor sensitivity for the detection of a recurrence of ovarian cancer (LE4). **Unless ascites is present, routine peritoneal cytology is not recommended for the diagnosis of a recurrence of ovarian, tubal, or primary peritoneal cancer (grade C).**

After treatment of these cancers, the strategy of monitoring by CT thorax/abdomen/pelvis scan for the first two years is less effective and three times more expensive per diagnosis of recurrence than the CA125 assay alone (LE4). **After treatment of ovarian, tubal, or primary peritoneal cancer, routine monitoring by CT scan of the thorax/abdomen/pelvis is not recommended (Grade C).**

If epithelial ovarian, tubal, or primary peritoneal cancer recurs in asymptomatic women, treatment based solely on an elevated serum CA125 level does not increase overall survival, and it impairs their quality of life (LE1).

For the follow-up of ovarian, tubal, or primary peritoneal cancer, women with complete initial surgery (no macroscopic tumor residue, CC0) and in good overall condition (ECOG 0) should be monitored by serum assays (HE4 or CA125) starting 6 months after the end of chemotherapy, then every 6 months, if the serum markers were initially high (Grade C) (Figure 5).

Women younger than 45 years of age who have undergone nonconservative treatment for high-grade serous ovarian, tubal, or primary peritoneal cancer should be offered hormone replacement treatment (HRT) for menopause (grade C)

HRT does not increase the risks of recurrence or mortality in women older than 45 years (LE2). **HRT can be offered for menopausal symptoms to women with a history of high-grade serous ovarian, tubal, or primary peritoneal cancer, after an individual evaluation of her risk-benefit ratio (Grade B).**

Women younger than 45 years whose mucinous ovarian adenocarcinoma has been treated benefit from HRT in terms of cardiovascular and overall survival (LE4). **HRT should be offered to women younger than 45 years after nonconservative treatment of mucinous ovarian cancer (grade C). HRT can be offered to a woman older than 45 years with a history of mucinous ovarian cancer for menopause symptoms after an individual evaluation of her risk-benefit ratio.**

Low-grade serous or endometrioid adenocarcinomas are hormone-sensitive histologic types, for which HRT use is a potential risk (LE4). **Nonetheless, no specific data for these histologic types justify a guideline about HRT use in women with a history of low-grade serous or endometrioid ovarian cancer.**

In all cases, the prescription of HRT and its dosage and administration must follow the same guidelines as those for the general population (see, HAS guidelines 2014).

Declaration of interests

The authors' potential relationships of interests are listed at:

<https://www.transparence.sante.gouv.fr>.

Acknowledgments:

The authors want to thank Mme Marianne Duperray and Mme Sophie Morois for their valuable logistic support in the development of these clinical practice guidelines.

The authors thank the following professional societies: CNGOF, FRANCOGYN, SFOG, SFAR, GINECO-ARCAGY, SCGP, SFCO, and the RRC; the IMAGIN patient association, and the expert reviewers for their attentive review of these clinical practice guidelines: (list: <https://www.e-cancer.fr/Professionnels-de-sante/Recommandations-et-outils-d-aide-a-la-pratique>).

ACCEPTED MANUSCRIPT

References

1. Huchon C, Lavoue V, Daraï E. Tumeurs épithéliales de l'ovaire. Méthodes et organisation. Recommandations françaises communes du CNGOF, FRANCOGYN, SFOG, GINECO-ARCAGY et labellisées INCa. Gynécologie, Obstétrique, Fertilité, Sénologie 2018.
2. Thomassin-Naggara I, Daraï E, Lécuru F, Bellucci A, Fournier L. valeur diagnostique de l'imagerie (échographie, doppler, scanner, IRM, et PET scan) pour le diagnostic ET LE BILAN D'EXTENSION d'un cancer de l'ovaire. Recommandations communes dU FRANCOGYN, du CNGOF, d'ARCAGY-GINECO et de la SFOG, labelisée INCa. . Gynécologie, Obstétrique, Fertilité, Sénologie 2018.
3. Devouassoux M, Le Frère-Belda MA, Leary A. Biopathologie des carcinomes ovariens des stades précoces et avancés : Recommandations françaises communes du CNGOF, FRANCOGYN, SFOG, GINECO-ARCAGY et labellisées INCa. Gynécologie, Obstétrique, Fertilité, Sénologie 2018.
4. Bendifallah S, Akladios C, Senechal C, Ouldamer L. Pertinence des marqueurs tumoraux, scores (cliniques et biologiques) et algorithmes à visée diagnostique et pronostique devant une masse ovarienne suspecte d'un cancer épithélial: Recommandations de Pratique Clinique communes de FRANCOGYN, CNGOF, SFOG, ARCAGY-GINECO, labélisée par l'INCa. . Gynécologie, Obstétrique, Fertilité, Sénologie 2018.
5. Bolze PA, Bourgin C, Collinet P, Golfier F. Chirurgie des stades précoces des cancers ovariens. Recommandations françaises communes du CNGOF, FRANCOGYN, SFOG, GINECO-ARCAGY et labellisées INCa. Gynécologie, Obstétrique, Fertilité, Sénologie 2018.
6. De La Motte Rouge T, Ray-Coquard I, You B. Traitements médicaux des cancers de l'ovaire lors de la prise en charge initiale. Recommandations de Pratique Clinique communes de FRANCOGYN, CNGOF, SFOG et ARCAGY-GINECO, labélisées par l'INCa. Gynécologie, Obstétrique, Fertilité, Sénologie 2018.
7. Uzan C, Courbiere B, Chabbert-Buffet N. Tumeurs épithéliales de l'ovaire : préservation de la fertilité. Recommandations françaises communes du CNGOF, FRANCOGYN, SFOG, GINECO-ARCAGY et labellisées INCa. Gynécologie, Obstétrique, Fertilité, Sénologie 2018.
8. Ferron G, Narducci F, Pouget N, Touboul C. Chirurgie des cancers avancés de l'ovaire. Recommandations de Pratique Clinique communes de FRANCOGYN, CNGOF, SFOG et ARCAGY-GINECO, labélisées par l'INCa. Gynécologie, Obstétrique, Fertilité, Sénologie 2018.
9. Bakrin N, Gladieff L. Tumeurs épithéliales malignes de l'ovaire : place de la chimiothérapie intra-péritonéale et de la chimiothérapie hyperthermique intra-péritonéale (CHIP).
Recommandations françaises communes du CNGOF, FRANCOGYN, SFOG et GINECO-ARCAGY, labélisées par l'INCa. Gynécologie, Obstétrique, Fertilité, Sénologie 2018.
10. Moore K, Colombo N, Scambia G, et al. Maintenance Olaparib in Patients with Newly Diagnosed Advanced Ovarian Cancer. N Engl J Med 2018.
11. Falandry C, Gouy S. Tumeurs épithéliales de l'ovaire : les personnes âgées. Recommandations françaises communes du CNGOF, FRANCOGYN, SFOG, GINECO-ARCAGY et labellisées INCa. Gynécologie, Obstétrique, Fertilité, Sénologie 2018.
12. Alfonsi P, Bonnet F, Lambaudie E, Leblanc E, Lemoine A. Soins péri-opératoires dans le cancer de l'ovaire. Recommandations Françaises communes dU FRANCOGYN, du CNGOF, d'ARCAGY-GINECO et de la SFOG, labelisée INCa. Gynécologie, Obstétrique, Fertilité, Sénologie 2018.

13. Senechal C, Bendifallah S, Ouldamer L, Lecuru F, Akladios C, Rousset-Jablonski C. Surveillance après traitement initial d'une tumeur épithéliale de l'ovaire, possibilités de contraception et de traitement hormonal substitutif de la ménopause. Recommandations de Pratique Clinique communes de FRANCOGYN, CNGOF, SFOG et ARCAGY-GINECO, labélisées par l'INCa Gynécologie, Obstétrique, Fertilité, Sénologie 2018.

ACCEPTED MANUSCRIPT

Figure 1: Management of presumed early-stage ovarian cancer

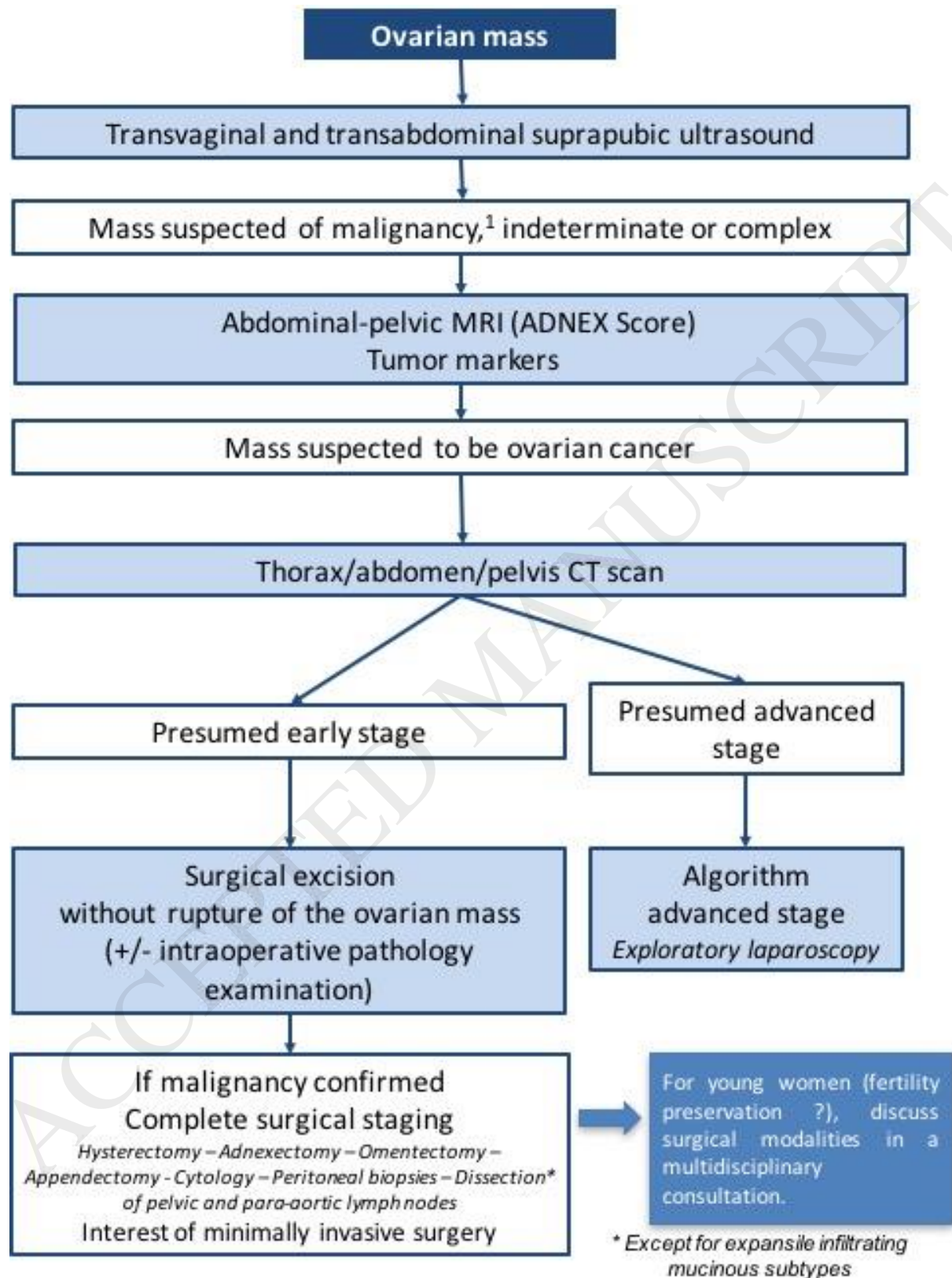


Figure 2: Management of a FIGO stage III ovarian, tubal, or primary peritoneal cancer

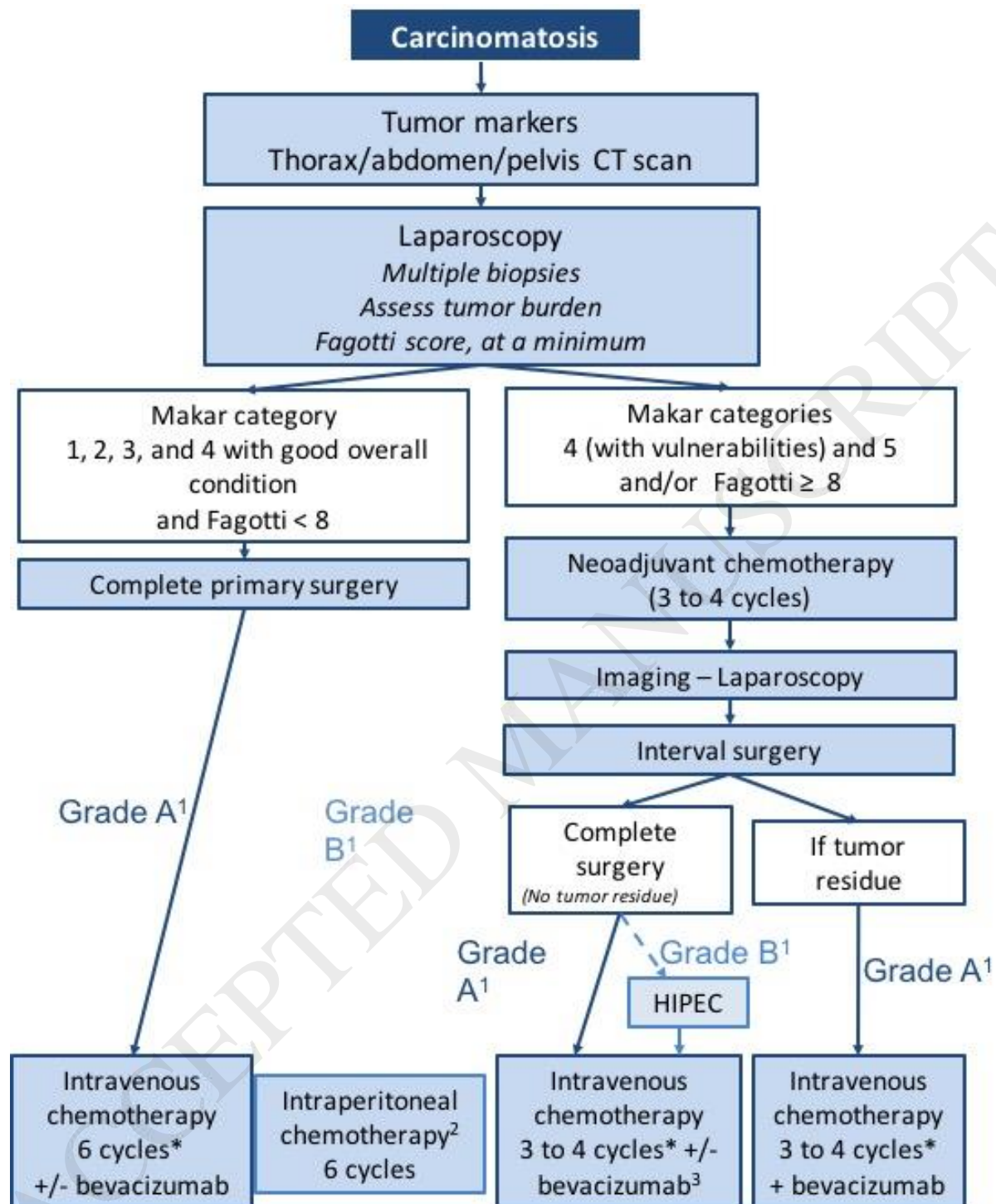
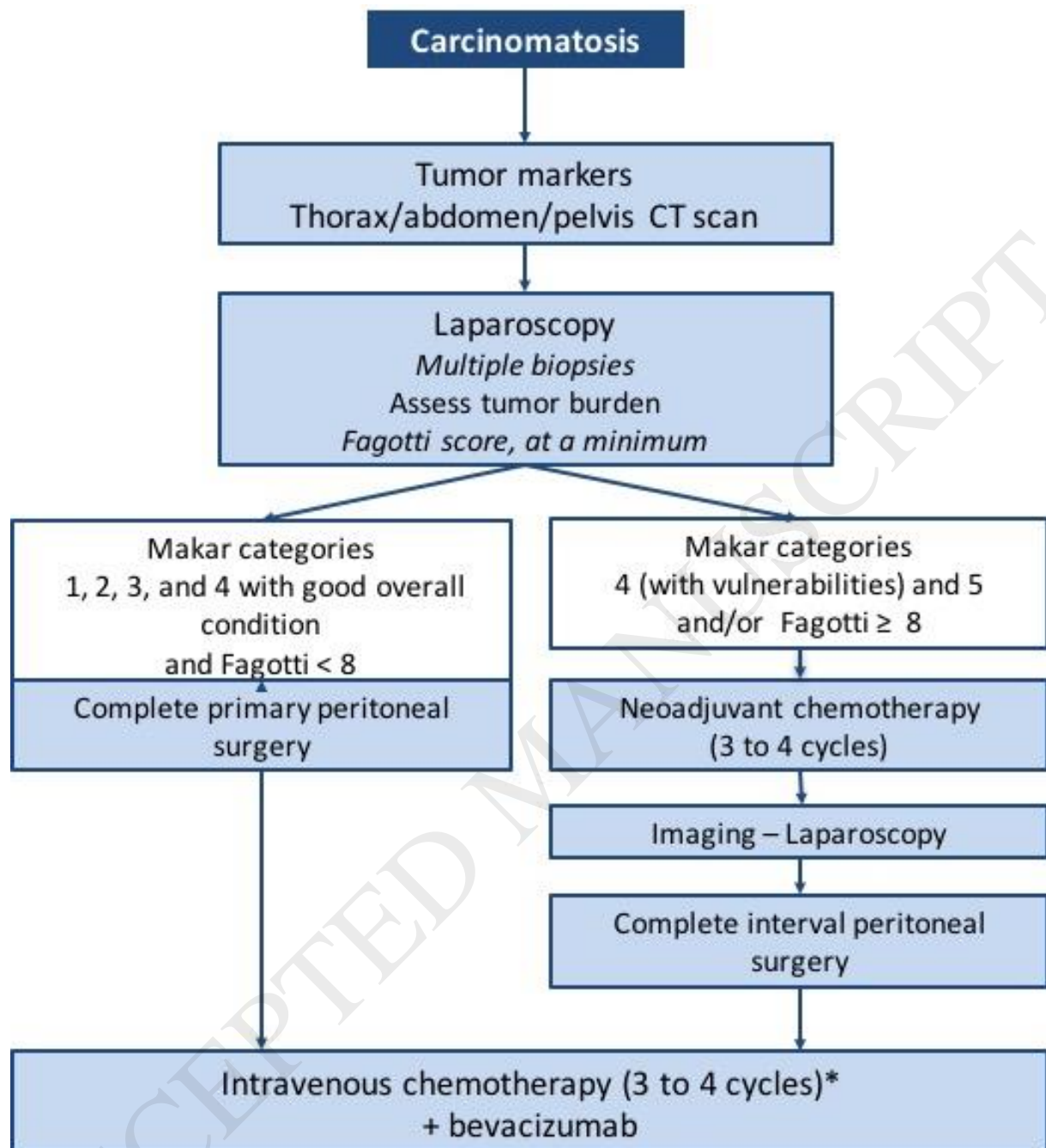


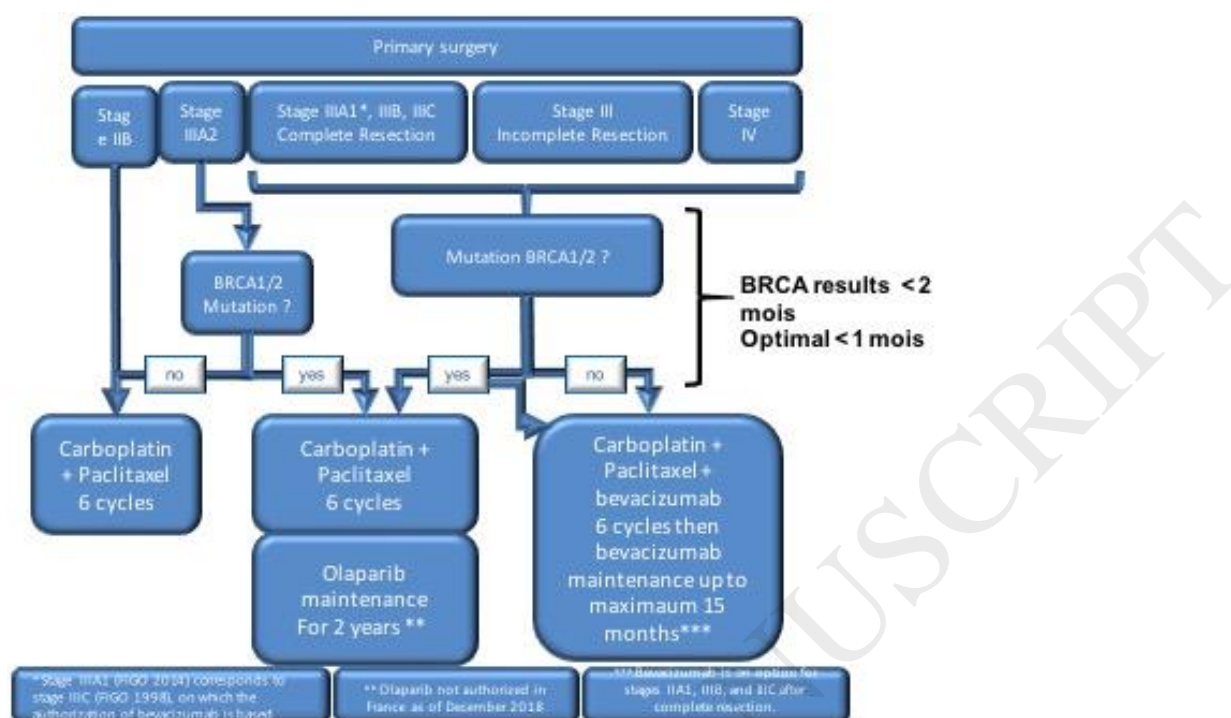
Figure 3: Management of a FIGO stage IV ovarian, tubal, or primary peritoneal cancer



Makar categories	
Category 1	Tumor located in pelvis Little or no ascites No need for gastrointestinal resection
Category 2	Tumor located in pelvis Little or no ascites Gastrointestinal resection is envisioned
Category 3	A large portion of the tumor is localized in the supramesocolic space Little or no ascites No need for gastrointestinal resection
Category 4	A large portion of the tumor is localized in the supramesocolic space Little or no ascites Gastrointestinal resection is envisioned
Category 5	A large portion of the tumor is localized in the supramesocolic space Abundant ascites or miliairy patterns on the mesentery. Need for several gastrointestinal resections

Figure 4: Management strategy in the era of first-line Olaparib

A: in cases of primary surgery



B: in cases of primary chemotherapy

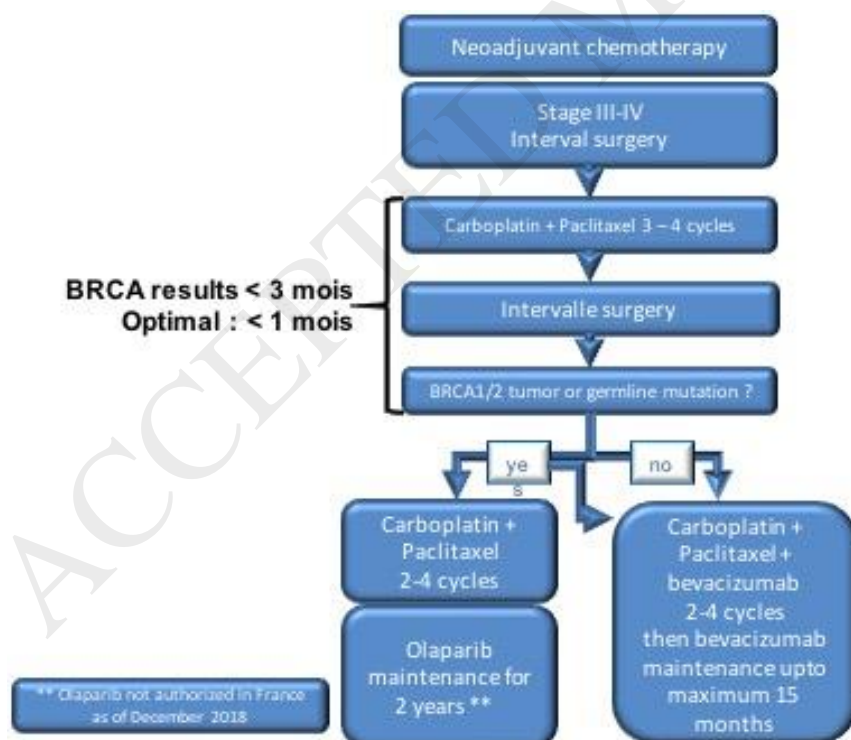


Figure 5: Post-treatment follow-up of women with ovarian, tubal, or primary peritoneal cancer

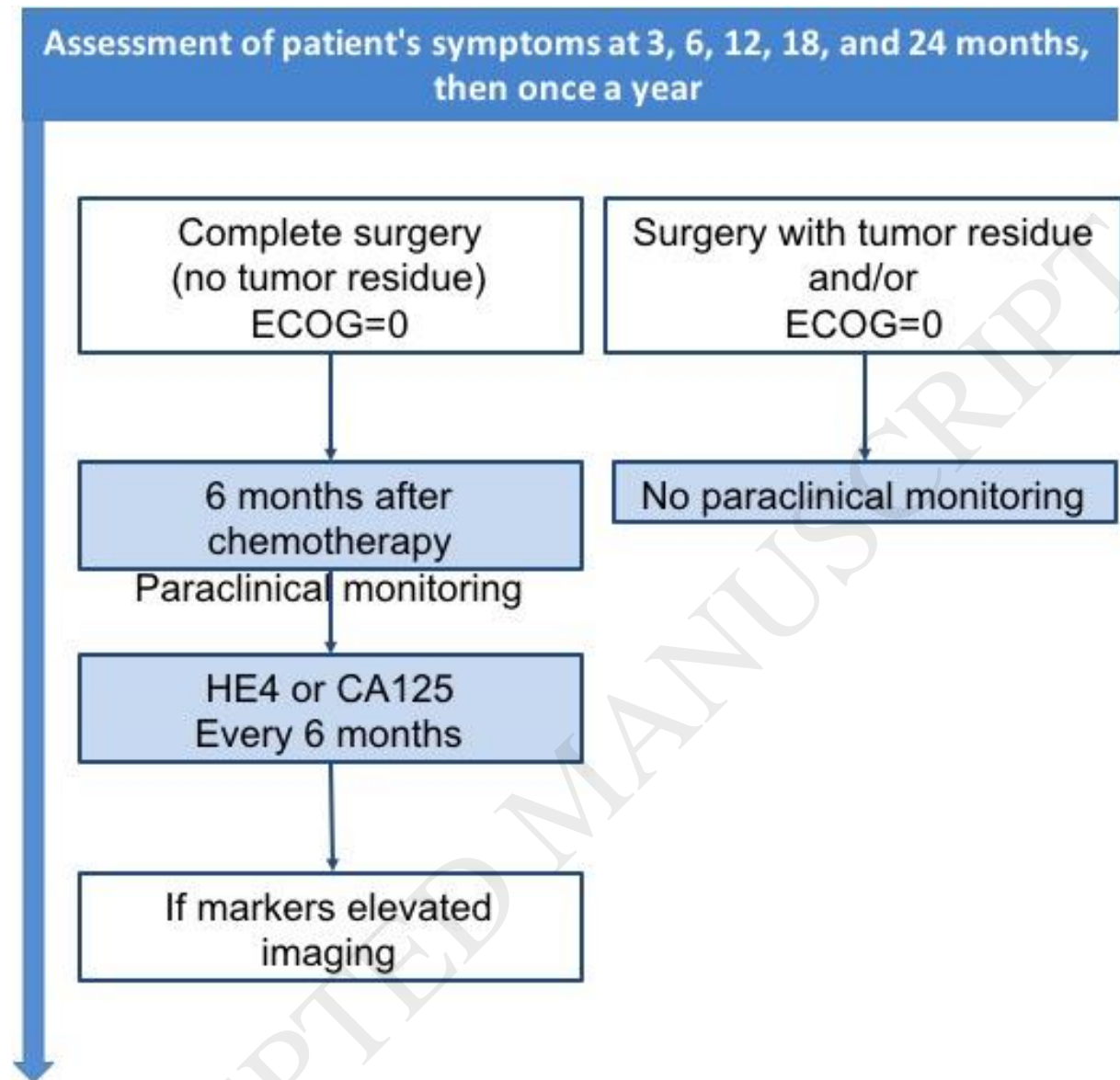


Table 1: The 10 simple ultrasound rules for an adnexal mass

Rules for predicting a benign tumor		Rules for predicting a malignant tumor	
B1	Unilocular	M1	Irregular solid mass
B2	The largest diameter of the largest solid component < 7 mm	M2	Ascites
B3	Acoustic shadow	M3	≥4 papillary structures
B4	Smooth multilocular tumor with largest diameter < 100 mm	M4	Irregular multilocular tumor with maximum diameter ≥ 100 mm
B5	No blood flow	M5	Intense vascularization on Doppler

ACCEPTED MANUSCRIPT

Table 2: ADNEX MR score to characterize the risk of malignancy of adnexal masses on MRI

	Risk of malignancy	Classification
No mass visible on MRI	0%	Very low risk
T2-weighted high signal intensity (type 5) unilocular cyst or tube without solid tissue Unilocular endometriotic cyst with no wall enhancement Purely fatty mass, without solid tissue No wall enhancement Low T2-weighted and low b (1000 sec/mm ²) -weighted signal intensity within solid tissue	0-1.7%	low risk
T1-weighted high signal intensity unilocular cyst (type 3-4) (not fatty or endometriotic) Multilocular cyst without solid tissue Type 1 time-signal intensity curve within solid tissue;	5.1-7.7%	Intermediate risk
Type 2 time-signal intensity curve within solid tissue	26.6-57.1%	Elevated risk
Type 3 time-signal intensity curve within solid tissue Peritoneal implants	68.3-100%	Very high risk

Table 3: Fagotti score

Parameters	Score
Omental cake (massive infiltration of the greater omentum)	2: diffuse stomach infiltration 0: isolated sites
Peritoneal carcinomatosis	2: massive NONRESECTABLE peritoneal carcinomatosis or miliary pattern of distribution 0: limited-area carcinomatosis (paracolic gutter or pelvic peritoneum, surgically resectable by peritonectomy)
Diaphragmatic carcinomatosis	2: widespread infiltration or confluent nodules infiltrating most of the diaphragm surface 0: all other cases
Mesenteric retraction	2 mesenteric retraction 0: Absence of mesenteric retraction
Bowel infiltration	2: gastrointestinal resection is envisioned 0: all other cases
Stomach infiltration	2: nodules infiltrating the stomach and/or spleen and/or lesser omentum 0: all other cases
Hepatic metastases	2: any tumor with an area >2 cm 0: all other cases

Table 4: Summary of survival according to tumor residue and primary or interval surgery in advanced ovarian, tubal, and primary peritoneal cancers.

STAGE III - IV	Primary surgery	Interval surgery	Primary surgery	Interval surgery
	Recurrence-free survival (months)		Overall survival (months)	
No residue	20.1-33	16.4	64.1-71.9	66.6
Residue < 1 cm	13-16.8	9.8	28.7-42.4	39.7
Residue > 1 cm	12.9-14.1	7.4	30.7-35	28.4