



## Fertility, Pregnancy, and Clinical Outcomes after Uterine Arteriovenous Malformation Management

Sophie Delplanque, Maela Le Lous, Maia Proisy, Yolaine Joueidi, Estelle Bauville, Céline Rozel, Eugénie Beraud, Bertrand Bruneau, Jean Leveque, Vincent Lavoué, et al.

### ► To cite this version:

Sophie Delplanque, Maela Le Lous, Maia Proisy, Yolaine Joueidi, Estelle Bauville, et al.. Fertility, Pregnancy, and Clinical Outcomes after Uterine Arteriovenous Malformation Management. Journal of Minimally Invasive Gynecology, 2018, 10.1016/j.jmig.2018.05.001 . hal-01952547

**HAL Id: hal-01952547**

**<https://univ-rennes.hal.science/hal-01952547>**

Submitted on 12 Dec 2018

**HAL** is a multi-disciplinary open access archive for the deposit and dissemination of scientific research documents, whether they are published or not. The documents may come from teaching and research institutions in France or abroad, or from public or private research centers.

L'archive ouverte pluridisciplinaire **HAL**, est destinée au dépôt et à la diffusion de documents scientifiques de niveau recherche, publiés ou non, émanant des établissements d'enseignement et de recherche français ou étrangers, des laboratoires publics ou privés.

**Title.**

**Fertility, pregnancy and clinical outcomes after uterine arteriovenous malformation  
management**

Sophie Delplanque, MD<sup>1,2</sup>, Maela Le Lous, MD<sup>1,2</sup>, Maïa Proisy, MD<sup>2,3</sup>, Yolaine Joueidi, MD<sup>1,2</sup>,  
Estelle Bauville MD<sup>1,3</sup>, Celine Rozel, MD<sup>3</sup>, Eugénie Beraud, MD<sup>3</sup>, Bertrand Bruneau, MD<sup>3</sup>,  
Jean Levêque, MD-PhD<sup>1,2</sup>, Vincent Lavoué, MD-PhD<sup>1,2</sup>, Krystel Nyangoh Timoh, MD<sup>1,2</sup>

<sup>1</sup> Department of Obstetrics and Gynecology, Rennes Hospital. Rennes University 1, Rennes, France.

<sup>2</sup> Université de Rennes 1 : 2 avenue de Professeur Léon Bernard, 35000

<sup>3</sup> Department of radiology, Rennes Hospital. Rennes University 1, Rennes, France.

**Correspondence :**

Doctor Nyangoh Timoh Krystel.  
Service de Gynécologie-Obstétrique. Hôpital Sud Rennes. 16 Boulevard de Bulgarie 35000  
Rennes. France.  
Tel: +3372136050  
Email: krystel.NYANGO.TIMOH@chu-rennes.fr

Disclosure statement: The authors declare that they have no conflicts of interest and nothing to disclose.

Précis: Uterine Arterial Embolization for uterine arteriovenous malformation is effective, safe and does not impair fertility.

**ABSTRACT**

**Study objective:** To evaluate fertility, pregnancy, and clinical outcomes after uterine arteriovenous malformation (UAVM) management.

**Design:** Single-center retrospective study from January 2000 to July 2017. (Canadian task force III).

**Setting:** One referral center.

**Patients:** Twenty-two patients with a UAVM diagnosed by Magnetic Resonance Angiography (MRA) or Computed Tomography (CT) angiography and managed by Expectant Management (EM) or Uterine Arterial Embolization (UAE) during the study period were included.

**Interventions:** Nine of the 22 patients underwent first intention EM and 13 first line UAE. Three of the nine EM patients (33.3%) required emergency second intention UAE for non-resolution of the UAVM and severe genital bleeding.

**Measurements and main results:** To analyze fertility according to management approach, we defined two groups: 1) EM only group (n=6), and 2) UAE group (n=16) i.e., women who underwent first or second intention UAE. Overall, the median age (range) was 29 years (17-43). The mean follow-up after UAVM management was 39 months (1-116). The success rate of the UAE procedure was 87.5% (14/16). Eight of the 12 women who wished to conceive (8/12, 66.7%) became pregnant: 2 (2/5, 33.3%) in the EM group and 6 (6/7, 85.7%) in the UAE group ( $p=1$ ). Overall, 11 (11/22, 50%) patients conceived: three in the EM group (50%), and eight in the UAE group (50%) ( $p=0.9$ ). The live-birth rate was 36.4 % (8/22) for the whole population. There were no miscarriages or ectopic pregnancies. The eight women wishing to conceive who became pregnant all delivered (8/11, 72.7%): one by caesarean section and seven by vaginal delivery. Median duration of pregnancy was 39 weeks and 5 days. The remaining three (i.e., women who conceived but who did not wish to become pregnant) had therapeutic abortions. One complication was experienced in the EM group (small for gestational age newborn) and none in the UAE group ( $p=0.3$ ). Limitations include retrospective design and small sample size.

**Conclusion:** UAE for UAVM is an effective and safe technique. It does not impair fertility and obstetric prognosis is good.

Key words: Embolization; Fertility; Pregnancy; Uterine arteriovenous malformation.

## Introduction

Uterus arteriovenous malformations (UAVM) are abnormal arteriovenous connections occurring in the uterus. It is a rare condition but its precise incidence is unknown [1]. UAVM can be congenital or acquired. Acquired UAVM is believed to be caused by a uterine trauma such as dilation and curettage, or caesarean section. Pregnancy plays a key role in the pathogenesis of UAVM during involution of chorioplacental villi [2]. The clinical expression is variable: from asymptomatic to profuse, life-threatening uterine bleeding.

No consensus exists for the therapeutic management. In asymptomatic women, expectant management (EM) is a valid option. However, women with abundant bleeding require active treatment. For these women there are two options: conservative radiologic management with uterine artery embolization (UAE); or radical surgery with hysterectomy. The choice between the two procedures depends on whether the patient wishes to conceive and on her hemodynamic tolerance. [3-6]. Data about fertility after management of UAVM based on case reports and literature review seems reassuring [2]. However, no study to date has analysed the subsequent fertility of patients with UAVM having undergone UAE or EM

approach according to the presence of prior infertility or the wish to conceive [5, 7, 8]. In a prospective study of patients with uterine fibroids having undergone UAE, Torre et al reported only one subsequent pregnancy which resulted in a miscarriage. UAE could thus be responsible for impaired fertility and for obstetric complications including early miscarriage and preterm delivery [9-11].

The aim of the present retrospective study was to analyze fertility, pregnancy and clinical outcomes after management of UAVM.

## **Materials and Methods**

### **Study Design**

We conducted a retrospective study from January 2000 to July 2017 at Rennes University Hospital, France. All the patients gave their consent to participate in the study before inclusion. The study was approved by the Ethics Committee of the National College of the French Gynaecologists and Obstetricians (reference number: 2017 A01760-53).

### **Patients**

The inclusion criteria were patients aged over 18 years having been diagnosed with UAVM by Doppler ultrasonography confirmed by second-line imaging (magnetic resonance angiography (MRA) or computed tomography (CT) angiography). The diagnosis was suspected by Doppler ultrasonography, generally realized by resident in gynecology and confirmed by a senior radiologist with a second line exam.

Patients were identified by using the radiologist software (Xplore®) searching for keywords “uterine arteriovenous malformation” or “arteriovenous fistula”.

The patients were managed by EM or UAE. Patients have to be affiliated to the French health care system and able to speak and read French.

Patients with congenital UAVM or uterine malformation were excluded. One patient had a hysterectomy to treat the UAVM and was although excluded.

The patient characteristics were recorded and included: age, body mass index (BMI), gravidity, parity, previous surgery, prior infertility, whether they wished to conceive before UAVM diagnosis, time to conception, history of cesarean section, myomectomy,

hysteroscopy or dilation and curettage antecedent, UAVM size on imaging, the symptoms and the serum level of human chorionic gonadotropin (HCG) if performed at the time of the UAVM diagnosis. Data about fertility were also collected either from the medical charts or by a patient questionnaire completed during a telephone interview. All patients were contacted by phone, 15 patients answered the questionnaire. The medical record of these patients completed until 2016, allowed analysis of missing data. During the phone interview, we asked questions in order to collect information about: the wish to conceive, prior infertility, use of assisted reproductive technology, number of pregnancies, obstetric complication, and the outcome of pregnancy (therapeutic abortion, miscarriage, ectopic pregnancy, obstetric complications, preterm labor, labor complication, term of delivery, delivery mode and the birth weight). Finally, patients who expressed a desire to conceive were asked for how long they had wished to conceive. These data were also collected from the medical charts and patient questionnaire. For each subsequent pregnancy we collected the year and the outcomes.

### **Diagnosis of UAVM**

UAVM is usually diagnosed on detection of a uterine mass by Doppler ultrasonography upon. In patients with UAVM, this mass appears as mildly echogenic tissue interspersed with multiple hypoechogenic spaces of varying sizes with a tangle of tortuous vessels with multidirectional, high-velocity and turbulent flow. (Figure 1 A)

Diagnosis is confirmed by MRA, by a focal uterine mass with serpiginous flow-related signal voids and disruption of the junctional zones between the myometrium and the endometrium (Figure 1B). On CT angiography, UAVM appears as a hypervascular mass in the myometrium with intense enhancement during the arterial phase and increased uterine blood flow, dilatation of the uterine arteries and early venous return. (Figure 1C et D)

### **Management of UAVM**

Data about UAVM management was collected from the patients' medical charts including mention of complications, and the outcome of the treatment. A successful outcome was defined by both the disappearance of the UAVM on imaging (pelvic ultrasound with or without MRA or CTA), and the disappearance of symptoms.

**Expectant management (EM)** Patients with no or few symptoms undergoing EM had a monthly clinical exam and ultrasounds, following the protocol in our institution.

**Uterine artery embolization (UAE)** Two radiologists experienced in UAE performed all the embolization procedures which consisted of uni- or bilateral femoral artery embolization. First, a 5-Fr Cobra catheter was used to perform non-selective angiograms of the internal iliac arteries to understand the vascularization of the UAVM. For lateralized UAVM, the dominant uterine artery ipsilateral to the lesion was selected using a micro catheter. The embolic agents used were coils (tornado®), resorbable microparticles (Gelitapson®), or non-resorbable microspheres (embosphere®). The size of agent was chosen according to the size and the localization of the UAVM. An angiogram was performed at the end to assess the effectiveness of the procedure. Embolization of the contralateral uterine artery was performed if necessary. One month after UAE, patients had a clinical exam and imaging (ultrasound or CT angiography). Then they had a clinical exam and imaging (ultrasound or CT angiography) until complete resolution of the UAVM.

### Statistical analysis

Statistical analysis was based on the Student's t test for continuous variables, the Chi-square test for categorical variables, and Fisher's exact test for categorical variables with  $n < 5$ , as appropriate. Values of  $p < 0.05$  were considered to denote significant differences. All analyses were performed with R software, version 2.15.2 (R Foundation for Statistical Computing, Vienna, Austria).

## Results

### Characteristics of the patient population

During the study period, out of the 26 patients with suspected UAVM, diagnosis was confirmed in 23 with a second line exam (19 patients by MRA and 4 patients by CT angiography). One of these patients underwent a hysterectomy leaving 22 patients with

confirmed UAVM who were included in the study. The mean follow-up after UAVM management was 39 months (1-116). (figure 2)

The characteristics of the study population are summarized in Table 1.

The median age (range) was 29.2 years (17-43), and the median BMI was 22 kg/m<sup>2</sup> (18-37.4). Eleven (50%) patients were nulliparous, and the median gravidity was 2.7 [1-6]. Twelve of the 22 patients (54.5%) wished to conceive. Four of these (4/12, 33.3%) had prior infertility.

Prior to the diagnosis of UAVM, 17 patients (77.3%) had undergone dilatation and curettage either for a spontaneous miscarriage or for an induced abortion; one (4.5%) had had a uterine revision after a vaginal birth; and one (4.5%) an *in-situ* injection of methotrexate. Three patients (13.6%) had experienced a spontaneous abortion but no uterine surgery. The mean time from the delivery or abortion to the diagnosis of UAVM diagnosis was 55 days (7-120).

Thirteen patients (59.1%) had genital bleeding alone as the first symptom, three (13.6%) genital bleeding with pelvic pain, and one (4.5%) pelvic pain only. Four (18.2%) patients had no symptoms. Four of the 16 patients with bleeding required a blood transfusion.

### **Characteristics of UAVM on imaging**

All the patients underwent an abdominal and transvaginal ultrasound examination which showed a typical UAVM. The median of the peak systolic velocity (PSV) was 31.6 cm/sec. The median size of the UAVM on transvaginal ultrasound was 26.3 mm (9-45). In four cases (18.2%), there was suspicion of associated trophoblastic retention.

To confirm diagnosis and further characterize the UAVM (localization and vascularization), patients had a second-line imaging examination: four (18.2%) had a CT angiography (Figure 4) and 18 (81.8%) an MRA. Associated trophoblastic retention was confirmed in two of the four suspected cases after MRA (11.1%). (Table 2)

### **UAVM management. (Table 3)**

***Expectant management (EM)***

Nine patients (40.9%) had a first intention EM. Among these, four (44.4%) were asymptomatic and five (55.6%) had mild genital bleeding. In six of these patients (6/9, 66.7%) the UAVM resolved spontaneously, and three patients (3/9, 33.3%) required emergency UAE because of profuse genital bleeding during the first month of the EM. Two of these three patients (2/3, 66.7%) had no symptoms on diagnosis of the UAVM. The median time for UAVM resolution was 2.8 months (1-6) after diagnosis for patients in whom EM was successful. In the six patients (66.7%) who had EM alone, one (16.6%) patient presented menorrhagia and one (16.6%) hot flushes. The median peak systolic velocity of the AVM was 24.9 cm/sec (Table 3).

***Uterine Artery Embolization (UAE) management***

Thirteen patients had first intention UAE because of abundant bleeding and three had second intention embolization because of failure of EM. Thus, 16 (72.7%) patients in all underwent UAE because of genital bleeding. The two patients with the associated trophoblastic retention confirmed by the MRA were managed by UAE and then monitoring with a clinical exam and imaging monthly. One of them need an additional vacuum aspiration one 1 month after UAE. The median peak systolic velocity of the AVM was 34.7 cm/sec. Six patients (6/16, 37.5%) had a bilateral UAE procedure due to UAVM with bilateral vascularization, while the others (10/16, 62.5%) underwent unilateral embolization. The UAE was not fully effective for three (3/16, 18.7%) patients: in one patient the UAVM was adjacent to a trophoblastic retention which was managed by vacuum aspiration after 1 month; the second patient required three successive UAEs due to persistence of profuse genital bleeding; the UAVM in the last patient, who was still being monitored 6 months after the procedure with a follow-up of 6 months (last examination in June 2017), failed to resolve although smaller in size with no bleeding.

Overall UAE was successful in 14 (14/16, 87.5%). In terms of complications, one patient (6.25%) had urinary irritation symptoms with spontaneous resolution, and another (6.25%) worsening of preexisting dysmenorrhea (6.25%) (Table 3).



In our study, pulsed Doppler sonography was realized for 9 patients (40,9%), 7 (7/13, 53,8%) in the EAU group and 3 (3/9, 33,3%) in the EM in first intention. For these 3 patients, the median pic systolic velocity was 24.88cm/sec (10-39.7) when the procedure was successful and 17cm/sec when it failed. In the UAE group, the median pic systolic velocity was 27cm/sec when the procedure failed and 39.8cm/sec (22-80) when the procedure was successful.

## **Fertility outcomes**

### ***Fertility and pregnancy outcomes for the whole population (Table 4)***

The median duration of follow up was 38 months [2-94]. Overall, there were 11 pregnancies (45.5%) after UAVM management: three (3/11, 27.3%) in the EM group (n=6) and eight (8/11, 72.7%) in the UAE group (n=16) (p=0.9). The median time to conception was 2.55 months for the whole population. Eight of the pregnancies (8/11, 72.7%) resulted in a live birth: one by cesarean section and seven by vaginal delivery. The remaining three women had an induced abortion (3/11, 27.3%) during the study period (Table 4).

There was no significant difference in the pregnancy rate or time to conception for all patients wishing to conceive and patients in the UAE and EM groups who wished to conceive (Table 4).

### ***Fertility and pregnancy outcomes for women wishing to conceive (Table 4)***

Twelve of the 22 patients (54.5%) wished to conceive after UAVM management: five (5/12, 41.7%) in the EM group and seven (7/12, 58.3%) in the UAE group (p=1.00). Among them, eight (8/12, 66.7%) became pregnant. None of the four patients with prior infertility became pregnant.

Out of the five patients in the EM group (5/6, 83.3%) who wished to conceive, two (2/5, 40%) became pregnant (time to conception: 2 months for one and 3 months for the other). They both had a vaginal delivery at term (39 and 40 gestational weeks, mean 39 weeks 6 days). One of the babies was small for gestational age (<10th percentile). Three of the patients in this group were infertile and did not conceive.

In the UAE group, eight (8/16, 50%) patients conceived with a median time of 19.5 months (9-33) after UAE. Among them, six (6/8, 75%) wished to conceive with a median time to conception of 2.6 months. No obstetric complications occurred. One patient had a cesarean section (1/8, 12.5%). Mean term of delivery was 39 weeks 5 days. Only one (1/8, 12.5%) patient did not become pregnant but had prior infertility.

No significant differences were observed between the UAE and EM groups in pregnancy course ( $p=0.3$ ), term of delivery ( $p=0.9$ ) and type of delivery.

### ***Fertility and pregnancy outcomes for women not wishing to conceive***

Three (3/22, 13.6%) patients had an abortion. This included one (1/6, 16.7%) patient in the EM group (medical termination of pregnancy 23 months after UAVM management) and two (2/16, 12.5%) in the UAE group (one medically induced and one surgically induced abortion with a period of 14 months and 6 months respectively after UAVM management).

### **Discussion**

This study, assessing the effect of UAVM management on fertility, suggests UAE does not affect subsequent fertility when compared with EM, and that the mean time to conception is short (less than 3 months). Moreover, UAE is effective and safe with a high success rate when compared with EM that required emergency UAE in a third of the cases.

To date, published evidence of fertility in this setting is relatively scarce [2, 4, 7, 8, 12, 13]. In the absence of guidelines for managing UAVM, especially for asymptomatic women or those with mild symptoms, the therapeutic approach is decided on between gynecologists and interventional radiologists. The two most frequent therapeutic attitudes are EM and selective UAE in women of childbearing age. Hysterectomy is radical and remains the treatment of choice in the case of life threatening hemorrhage [2]. In the present study, an EM was first attempted for nine patients (40.9%) but failed for three of them (33.3%). These results are consistent with the literature [4, 13-19]. In a series of 27 patients, Timor-Tritsch et al, adopted an EM approach in 48% of the women and selective UAE for around 30% with a success rate of 75%. The overall success rate for UAE is reported as being between 80-90% [13, 19]. In our study, UAE was selective and unilateral for 10 patients (62.5%) which

corresponds to the usual rate [2]. It should be noted that while unilateral UAE may pose less of a risk for fertility, it increases the risk of procedure failure due to revascularization. A repeat UEA, generally bilateral, is usually necessary [1,20-22]. This occurred in one of our patients. According to published data, the rate of repeated UAE ranges from 3 to 40% [18,20].

Some data suggests that the success rate of the EM is associated with a peak systolic velocity lower than 40 cm/sec [14,19]. In our study, pulsed Doppler sonography was realized for only 9 patients (40,9%), 7 (7/13, 53,8%) in the EAU group and 3 (3/9, 33,3%) in the EM in first intention. Results are not consistent with previous data but the sample size in this study is small. As this exam was not systematically realized, it did not part of the medical decision.

The use of hormones has been reported to treat AVM. Some data show a regression of the AVM with use of GnRH agonists or combination estrogen and progesterone [5,21]. Nevertheless, only few studies report the management of the AVM with hormones and none of them compare expectant management with medical treatment. In our study, 9 (40,9%) patients had a prescription of hormones as a contraception but not to treat the AVM, 5 (22,7%) have a combination of estroprogestative and 4 (18,2%) microprogestative. All patients with combination of estroprogestative were in the UAE group.

Some questions remain about the fertility and obstetric consequences of UAE. It has also been reported that UAE could induce ovarian insufficiency or endometrial atrophy, an increased risk of miscarriage, premature delivery, intrauterine growth retardation or postpartum hemorrhage [5, 25]. In 2004, the American College of Obstetrics and Gynecology contraindicated UAE for uterine fibroids in women wishing to conceive [25-27]. In the EMMY trial, patients had a significantly lower AMH value than age-adjusted levels in the general population based on age after EAU for symptomatic fibroid [28], but the median age of the population was 44.6 years old while patient suffering from AVM are often younger. Thus, some data with younger patients show no long-term decline of ovarian reserve after UAE [29-30]. Moreover, all of these cohorts included patient with UAE for symptomatic fibroids.

The size and the nature of the embolic agent are different from those used for AVM. In their review, Berkane et al show that the risk of occlusion of the ovarian arteries is low and with no incidence on fertility if the embolization agents are greater than 500 microns resorbable particles [25]. In the literature, it is difficult to assess the effect of the various embolic agents on fertility because multiple agents are used in the same study like in the present study. One explanation for discrepancy about fertility and pregnancy outcomes in UAE for UAVM and for uterine fibroids could be due to the number of particles used and the bilaterality of the occlusion. Delotte et al., reported on a sample of 13 patients who became pregnant after UAE for UAVM. Seven of these patients had bilateral UAE. Nevertheless, they did not take into account previous fertility. Eight of their patients had a normal pregnancy and five gave birth prematurely but no link was found between outcome and the management of the UAVM. Birth weight was within the normal range [2]. Goldberg et al reported six cases of normal pregnancy after UAE for UAVM in a review of 50 published cases of pregnancy after UAE [9]. However, few data exist on fertility outcomes according to prior fertility and the wish to conceive. In the present study, 66.7 % of the patients who wished to conceive had a pregnancy during a mean follow up of 39 months (1-116), similar in both UAVM management groups. Among these, four patients (4/12, 33.3%) had prior infertility. These results could indicate that the major factor of infertility after UAVM is previous infertility rather than UAVM management. All patients without prior infertility but who wished to conceive, became pregnant after UAVM management.

Another interest of present study is the results about the course of the pregnancy. Some data suggest the the risk of miscarriage was increased after UAE for fibroid [31]. Nevertheless, rates of preterm delivery and intrauterine growth restriction were similar in UAE group and in patient with fibroid. There were two possible confounding factors, the median age of the population which is generally older and the presence of fibroid. Nevertheless, other studies were reassuring about obstetrics outcome and pregnancies after UAE do not seem to be characterized by complications [2, 3, 7, 9, 17, 22, 32, 33]. In the present study, only one baby

(13%) was small for the gestational age and no births were preterm. Finally, UAE does not appear to affect the delivery.

One strength of the present study is the long follow-up period and the inclusion of pre-existing fertility disorders in the analysis. We also took into account the number of women who wished to conceive. Nevertheless, some limitations deserve to be mentioned. First, the retrospective nature of the study cannot exclude some biases. However, most of the data was collected from medical charts ruling out issues related to recall. Secondly, the sample size was relatively small. However, this is due to the relatively low incidence of UAVM. Third, as the patients within EM group had little to no symptoms indicating an inherently different AVM from patients within UAE group. The two groups being compared are inherently different. However, all patients in the two groups have AVM diagnosed by ultrasound and another second line exam. Moreover, the aim of this study was to compare fertility and pregnancy outcomes between UAE and EM and we demonstrate that no significant differences were observed between the UAE and EM groups in fertility, pregnancy course, term of delivery and type of delivery.

## Conclusion

Our study indicates that, compared to EM, UAE could be considered as an effective treatment UAVM and seems to be safe for women wishing to conceive and who have no fertility impairment. Furthermore, fetal prognosis seems favorable. Further studies with larger sample of population are needed to confirm these results. On the contrary, EM of UAVM may be associated with unsuspected risk implying an emergency UAE because of profuse bleeding onset that could threaten the patient's life.

## Acknowledgments

To Matrix Consultants for proofreading in English and the corrections made.

## References

- [1] Hoffman MK. Meilstrup JW. Shackelford DP. Kaminski PF. Arteriovenous malformations of the uterus: an uncommon cause of vaginal bleeding. *Obstet Gynecol Surv* 1997;52: 736-40.
- [2] Delotte J. Chevallier P. Benoit B. Castillon JM. Bongain A. Pregnancy after embolization therapy for uterine arteriovenous malformation. *Fertil Steril* 2006;85: 228.
- [3] Chen LK. Yang BL. Chen KC. Tsai YL. Successful Transarterial Embolization of Uterine Arteriovenous Malformation: Report of Three Cases. *Iran J Radiol* 2016;13: e15358.
- [4] Degani S. Leibovitz Z. Shapiro I. Ohel G. Expectant management of pregnancy-related high-velocity uterine arteriovenous shunt diagnosed after abortion. *Int J Gynaecol Obstet* 2009;106: 46-9.
- [5] Mekaru K. Oishi S. Akamine K. Heshiki C. Aoki Y. Spontaneous Regression of Uterine Arteriovenous Malformations with Conservative Management. *Case Rep Obstet Gynecol* 2017;2017: 6437670.
- [6] Molvi SN. Dash K. Rastogi H. Khanna SB. Transcatheter embolization of uterine arteriovenous malformation: report of 2 cases and review of literature. *J Minim Invasive Gynecol* 2011;18: 812-9.
- [7] Eling R. Kent A. Robertson M. Pregnancy after uterine arteriovenous malformation-case series and literature review. *Australas J Ultrasound Med* 2012;15: 87-96.
- [8] Grivell RM. Reid KM. Mellor A. Uterine arteriovenous malformations: a review of the current literature. *Obstet Gynecol Surv* 2005;60: 761-7.
- [9] Goldberg J. Pereira L. Berghella V. Pregnancy after uterine artery embolization. *Obstet Gynecol* 2002;100: 869-72.
- [10] Holub Z. Mara M. Kuzel D. Jabor A. Maskova J. Eim J. Pregnancy outcomes after uterine artery occlusion: prospective multicentric study. *Fertil Steril* 2008;90: 1886-91.
- [11] Torre A, Paillusson B, Fain V, Labauge P, Pelage JP, Fauconnier A. Uterine artery embolization for severe symptomatic fibroids: effects on fertility and symptoms. *Human reproduction (Oxford, England)*. 2014;29(3):490-501
- [11] Garner EI. Meyerovitz M. Goldstein DP. Berkowitz RS. Successful term pregnancy after selective arterial embolization of symptomatic arteriovenous malformation in the setting of gestational trophoblastic tumor. *Gynecol Oncol* 2003;88: 69-72.
- [12] Hugues C. Le Bras Y. Coatleven F. Brun JL. Trillaud H. Grenier N. Cornelis F. Vascular uterine abnormalities: Comparison of imaging findings and clinical outcomes. *Eur J Radiol* 2015;84: 2485-91.

- [13] Timmerman D. Van den Bosch T. Peeraer K. Debrouwere E. Van Schoubroeck D. Stockx L. Spitz B. Vascular malformations in the uterus: ultrasonographic diagnosis and conservative management. *Eur J Obstet Gynecol Reprod Biol* 2000;92: 171-8.
- [14] Yoon DJ. Jones M. Taani JA. Buhimschi C. Dowell JD. A Systematic Review of Acquired Uterine Arteriovenous Malformations: Pathophysiology. Diagnosis. and Transcatheter Treatment. *AJP Rep* 2016;6: e6-e14.
- [15] Ko JK. Cheung VY. Khongsni P. Management and outcome of sonographically diagnosed uterine enhanced myometrial vascularity / arteriovenous malformations following early pregnancy events: a single center experience. *Med Ultrason* 2016;18: 403-4.
- [16] Peitsidis P. Manolakos E. Tsekoura V. Kreienberg R. Schwentner L. Uterine arteriovenous malformations induced after diagnostic curettage: a systematic review. *Arch Gynecol Obstet* 2011;284: 1137-51.
- [17] Sanguin S. Lanta-Delmas S. Le Blanche A. Grardel-Chambenoit E. Merviel P. Gondry J. Fauvet R. [Uterine arteriovenous malformations: diagnosis and treatment in 2011]. *Gynecol Obstet Fertil* 2011;39: 722-7.
- [18] Timor-Tritsch IE. Haynes MC. Monteagudo A. Khatib N. Kovacs S. Ultrasound diagnosis and management of acquired uterine enhanced myometrial vascularity/arteriovenous malformations. *Am J Obstet Gynecol* 2016;214: 731 e1-731 e10.
- [19] Bazeries P. Paisant-Thouveny F. Yahya S. Bouvier A. Nedelcu C. Boussion F. Sentilhes L. Willoteaux S. Aube C. Uterine Artery Embolization for Retained Products of Conception with Marked Vascularity: A Safe and Efficient First-Line Treatment. *Cardiovasc Intervent Radiol* 2017;40: 520-529.
- [20] Oride A, Kanasaki H, Miyazaki K. Disappearance of a uterine arteriovenous malformation following long-term administration of oral norgestrel/ethinyl estradiol. *The journal of obstetrics and gynaecology research*. 2014;40(6):1807-10.
- [21] Maleux G. Timmerman D. Heye S. Wilms G. Acquired uterine vascular malformations: radiological and clinical outcome after transcatheter embolotherapy. *Eur Radiol* 2006;16: 299-306.
- [22] Rubod C. Mubiayi N. Robert Y. Vinatier D. [Uterine arteriovenous malformation. A rare cause of recurrent metrorrhagia]. *Gynecol Obstet Fertil* 2005;33: 511-3.
- [23] Ghai S. Rajan DK. Asch MR. Muradali D. Simons ME. TerBrugge KG. Efficacy of embolization in traumatic uterine vascular malformations. *J Vasc Interv Radiol* 2003;14: 1401-8.
- [24] Berkane N. Moutafoff-Borie C. Impact of previous uterine artery embolization on fertility. *Curr Opin Obstet Gynecol* 2010;22: 242-7.
- [25] ACOG Committee Opinion. Uterine artery embolization. *Obstet Gynecol* 2004;103: 403-4.
- [26] Ravina JH. Aymard A. Ciraru-Vigneron N. Clerissi J. Merland JJ. [Uterine fibroids embolization: results about 454 cases]. *Gynecol Obstet Fertil* 2003;31: 597-605.
- [27] Tropeano G. Di Stasi C. Amoroso S. Vizzielli G. Mascilini F. Scambia G. Incidence and risk factors for clinical failure of uterine leiomyoma embolization. *Obstet Gynecol* 2012;120: 269-76
- [28] Hehenkamp WJ, Volkers NA, Donderwinkel PF, de Blok S, Birnie E, Ankum WM, et al. Uterine artery embolization versus hysterectomy in the treatment of symptomatic uterine fibroids (EMMY trial): peri- and postprocedural results from a randomized controlled trial. *American journal of obstetrics and gynecology*. 2005;193(5):1618-29
- [29] McLucas B, Voorhees III WD, Snyder SA. Anti-Müllerian hormone levels before and after uterine artery embolization. *Minimally Invasive Therapy & Allied Technologies*. 2017;1-5
- [30] Torre A, Paillusson B, Fain V, Labauge P, Pelage JP, Fauconnier A. Uterine artery embolization for severe symptomatic fibroids: effects on fertility and symptoms. *Human reproduction (Oxford, England)*. 2014;29(3):490-501
- [31] Homer H, Saridogan E. Uterine artery embolization for fibroids is associated with an increased risk of miscarriage. *Fertility and sterility*. 2010;94(1):324-30
- [32] McLucas B. Pregnancy following uterine artery embolization: an update. *Minim Invas Ther Allied Technol*. 2013; 22:39-44

[33] Pron G, Mocarski E, Bennett J, Vilos G, Common A, Vanderburgh L, et al. Pregnancy after uterine artery embolization for leiomyomata: the Ontario multicenter trial. *Obstet Gynecol.* 2005; 105:67–76

Table legends

**Table 1: Patient characteristics of the study population**

**Table 2: UAVM Diagnosis.**

UAVM: Uterine arteriovenous malformation

NS: Not Significant

**Table 3: UAVM management.**

EM: expectant management.

UAE: Uterine artery embolization

UAVM: Uterine arteriovenous malformations

**Table 4: Fertility outcomes**

NS: Not Significant



**Table 1: Patient characteristics of the study population**

Characteristics	Patients (n=22)
Median age (min-max) years	29.2 [17-43]
Median BMI (min-max) kg/cm <sup>2</sup>	22.2 [18.3-37.4]
Median gravidity (min-max)	2.7 [1-6]
Median parity (min-max)	0.9 [0-3]
Prior infertility n (%)	2 (9.1)
Time to conceive > 2 years n (%)	3 (13.6)
Wish to conceive after UAVM n (%)	12 (54.5)
Previous surgery	
Transluminal artoplasty for aortic coarctation n (%)	2 (9.1)
Appendectomy n (%)	3 (13.6)
Previous cesarean delivery	4 (18.2)
One cesarean n	3
Two cesarean n	1
Uterine surgery before UAVM	
Dilatation and curettage n (%)	17 (77.3)
No surgery n (%)	3 (13.6)
Cesarean n (%)	1 (1/3, 33.3)
Uterine revision n (%)	1 (4.5)
Methotrexate <i>in situ</i> injection n (%)	1 (4.5)
Symptoms	
Genital bleeding n (%)	13 (59.1)
No symptoms n (%)	4 (18.2)
Genital bleeding and pelvic pain n (%)	3 (13.6)
Pelvic pain n (%)	1 (4.5)
Amenorrhea n (%)	1 (4.5)
Positive HCG n (%)	8 (36.4)
Median HCG at UAVM diagnosis (min-max)	65,4 (0-985)
Median time from delivery/abortion to UAVM diagnosis (min-max) days	55 (7-120)

**Table 2 UAVM Diagnosis**

Characteristics	Patients (n=22)	EM group (n=6)	UAE group (n=16)	P value
<b>Symptoms</b>				
Genital bleeding n (%)	13 (59.1)	4 (66.7)	9 (56.3)	NS
No symptoms n (%)	4 (18.2)	2 (33.4)	2 (12.5)	NS
Genital bleeding and pelvic pain n (%)	3 (13.6)	0	3 (18.8)	NS
Pelvic pain n (%)	1 (4.5)	0	1 (6.3)	NS
Amenorrhea n (%)	1 (4.5)	0	1 (6.3)	NS
Ultrasound n (%)	22 (100)	6 (100)	16 (100)	NS
Median peak systolic velocity in cm/sec (min-max)	31.6 [10-80]	24.9 [10-39]	34.7[17-80]	NS
Median resistance index (min-max)	0.51 [0.3-0.8]	0.51 [0.36-0.66]	0,51 [0.3-0.8]	NS
Median pulsatility index (min-max)	0.47 [0.36- 0.59]	0.46	0,47 [0.36-0.59]	NS
<b>Ultrasound report</b>				
UAVM only	18 (81.8)	6 (100)	10 (62,5)	NS
UAVM and trophoblastic retention	4 (18.2)	0	4 (25)	NS
Median size of UAVM (ultrasound) (mm) (min-max)	26.3 [9-45]	20.2 [15-34]	28.6 [9-45]	
MRA n (%)	18 (81.8)	4 (66.7)	14 (87.5)	NS
UAVM	16 (88.9)	4 (66.7)	12 (75)	NS
UAVM and trophoblastic retention	2 (11.1)	0	2 (12.5)	NS
CT angiography n (%)	4 (18.2)	2 (33.3)	2 (12.5)	NS

**Table 3 UAVM management**

EM management	
Characteristics	n=9
Success n (%)	6 (66.7)
Time to UAVM resolution (months) (min-max)	2.8 [1-6]
Failure n (%)	3 (33.3)
Mean time to failure (months)	1.22
Reason of failure	
Genital bleeding n (%)	3 (3/3. 100)
2 <sup>nd</sup> line treatment	
UAE n (%)	3 (3/3. 100)
Success n (%)	2 (2/3. 75)
Hormones	2 (33.3)
Combination estrogen-progestin	0
Microprogestative	2 (33.3)
UAE management	
Characteristics	n=16
First intention	13 (81.3)
Second intention	3 (18.8)
Bilateral n (%)	6 (37.5)
Success n (%)	13 (81.3)
Failure n (%)	3 (18.7)
2 <sup>nd</sup> line of treatment	
UAE n (%)	1 (33.3)
Expectant management n (%)	1 (33.3)
Curettage n (%)	1 (33.3)
Hormones	7 (43.8)
Combination estrogen-progestin	5 (31.6)
Microprogestative	2 (12.5)

**Table 4: Fertility outcomes**

Characteristics	Total (n=22)	EM group (n=6)	UAE group (n=16)	P value
Wish to conceive n (%)	12 (54.5)	5 (83.3)	7 (43.7)	NS
Pregnancy in women wishing to conceive n (%)	8 (66.7)	2 (40)	6 (85.7)	NS
Infertility n (%)	4 (18.2)	3 (50)	1 (6.3)	0.01
Prior to UAVM procedure n (%)	2 (9.1)	2 (33.3)	0 (0)	NS
Masculine infertility n (%)	2 (9.1)	2 (33.3)	0 (0)	NS
Female infertility n (%)	1 (4.5)	0 (0)	1 (6.3)	0.04
Median time of trying to conceive for infertile patients	24.5	23	26	NS
Median time to conception (months)	2.55	2.5	2.6	NS
Median time between UAVM management and pregnancy (months)	22	25	19.5	NS
Total pregnancies	11 (45.5)	3 (50)	8 (50)	NS

## Figure legends

## Figure 1:

A/ Sagittal view of pelvis shows a mass in the uterus with tortuous vessels with a multidirectional, high-velocity and turbulent flow on Color Doppler ultrasonography corresponding to the UAVM (arrow)

B/ Sagittal view MRA of the pelvis shows the UAVM as a focal uterine mass with a disruption of the junctional zones between the myometrium and the endometrium (arrow)

C/ CT angiography shows a marked visualized vascular tangle (arrow)

D/ MRA show the UAVM supplied by the two uterine arteries (arrow)

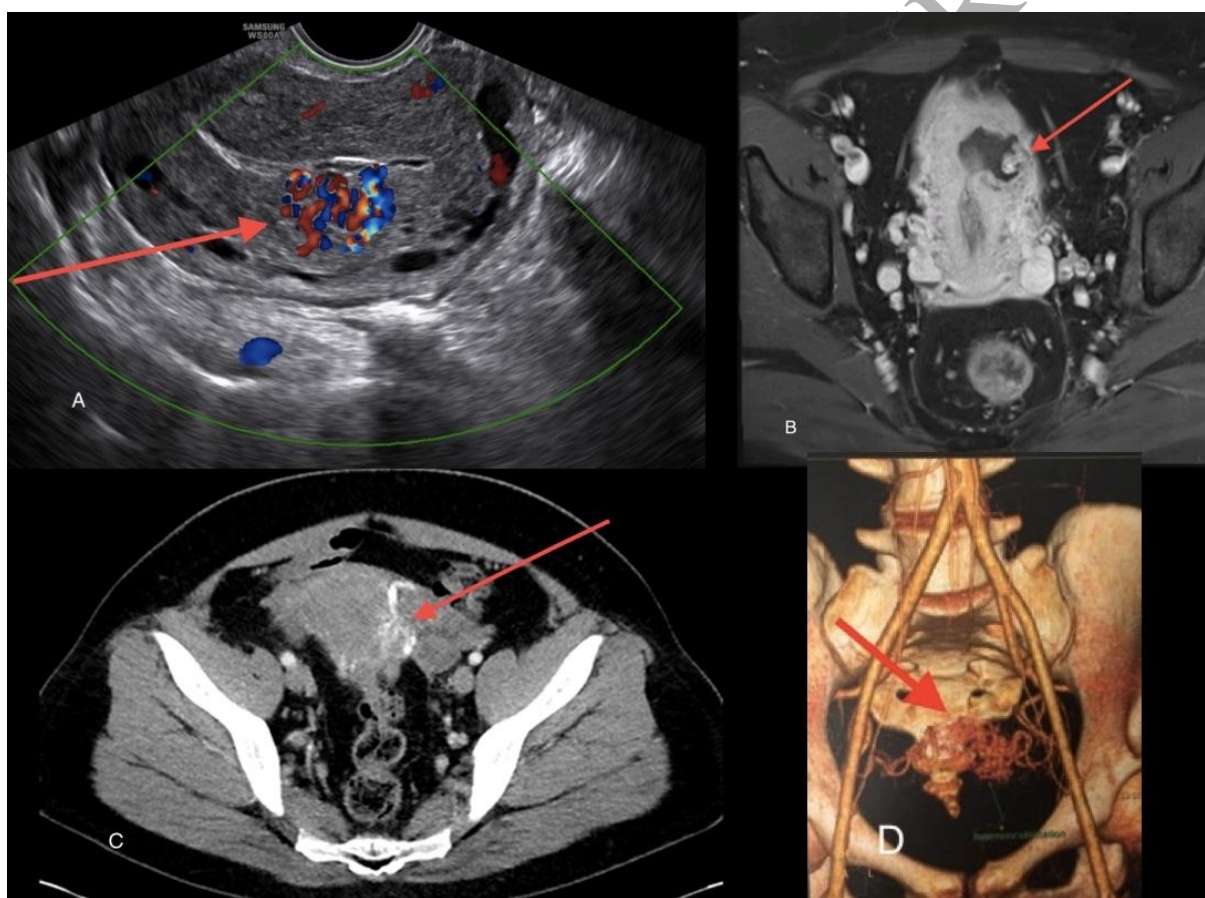


Figure 2: Flow chart



# CONSORT

TRANSPARENT REPORTING of TRIALS

## CONSORT 2010 Flow Diagram

**Figure 2**

