



HAL
open science

Thoracotomy and esophageal surgery: Key points to preserve the possibilities of flaps

N Bertheuil, N Isola, D Bergeat, C Mocquard, E Watier, S Rouze, B. Meunier

► To cite this version:

N Bertheuil, N Isola, D Bergeat, C Mocquard, E Watier, et al.. Thoracotomy and esophageal surgery: Key points to preserve the possibilities of flaps. *Annales de Chirurgie Plastique Esthétique*, 2019, 64 (2), pp.195-198. 10.1016/j.anplas.2018.08.005 . hal-01903468

HAL Id: hal-01903468

<https://univ-rennes.hal.science/hal-01903468>

Submitted on 14 Dec 2018

HAL is a multi-disciplinary open access archive for the deposit and dissemination of scientific research documents, whether they are published or not. The documents may come from teaching and research institutions in France or abroad, or from public or private research centers.

L'archive ouverte pluridisciplinaire **HAL**, est destinée au dépôt et à la diffusion de documents scientifiques de niveau recherche, publiés ou non, émanant des établissements d'enseignement et de recherche français ou étrangers, des laboratoires publics ou privés.

Thoracotomy and esophageal surgery: key points to preserve the possibilities of flaps.

Nicolas Bertheuil MD, PhD^{1,2,3}, Nicolas Isola MD¹, Damien Bergeat MD⁴, Camille Mocquard MD¹, Eric Watier MD, PhD¹, Simon Rouze MD⁵, Bernard Meunier MD, PhD⁴.

1 – Service de Chirurgie Plastique et Reconstructrice, Hôpital Sud, Université de Rennes 1, Rennes, France.

2 - INSERM U1236, Université de Rennes 1, Rennes, France.

3 – Laboratoire SITI, CHU de Rennes, Rennes, France.

4 – Service de chirurgie digestive et hépato biliaire, Hôpital Pontchaillou, CHU de Rennes, Rennes, France.

5 - Service de chirurgie thoracique, Hôpital Pontchaillou, CHU de Rennes, Rennes, France.

Auteur correspondant :

Dr Nicolas Bertheuil, MD, PhD .

Department of Plastic, Reconstructive and Aesthetic Surgery, Hospital Sud, Rennes, France.

16 Boulevard de Bulgarie, 35200, Rennes

SITI Laboratory, INSERM U1236, University of Rennes 1, Rennes, France.

Phone: 00 33 2 99 26 71 68

Fax: 00 33 2 99 26 67 18

E-mail: nbertheuil@gmail.com

Thoracotomy and esophageal surgery: key points to preserve the possibilities of flaps.

Abstract

Anastomotic leakage frequently complicates esophagectomy and can trigger a rare life-threatening complication, a tracheoesophageal fistula. No guideline has yet addressed this complication. Plastic surgeons play a crucial role for salvage surgery. When a re-operation is chosen the possibilities of flap interposition depend on how the thoracotomy was initially performed. This study tried to identify key techniques in order help thoracic or general surgeons to preserve all the local flaps available for TEF if it occurs. These techniques improve flap conservation, helping plastic surgeons when a later transposition flap is required.

Introduction

Esophageal cancer is the eighth most common cancer worldwide and has a poor prognosis (5-year survival < 51%) [1]. Surgery remains the best option when patients are operable. Neoadjuvant radiotherapy improves long-term survival but is associated with higher perioperative morbidity and mortality than surgery alone. Anastomotic leakage is a common complication after surgery, and may trigger a tracheoesophageal fistula (TEF). A perioperative TEF is defined as one caused by major airway injury during esophagectomy or one that develops soon after operation. Different fistula locations have been reported, explaining the variety of treatment strategies. The complication is rare and difficult to treat; hence, no guideline is available. Indeed, only a few case reports and case series have described successful fistula management. Unlike the procedure used to treat a tracheobronchial fistula that develops after lung cancer surgery, tracheal or bronchial resection and anastomosis of a TEF does not appear to be feasible. For salvage surgery, the plastic surgeon has a vital role within the multidisciplinary team. Surgical treatment using an interposition flap is an effective option that can be limited by the initial surgery. Indeed, if a

mini-invasive esophagectomy via a thoracoscopic approach is performed, most flaps are workable. However, an open approach via a right thoracotomy is still frequently performed in clinical practice, restricting the choice of flap. We identified key points to be noted when performing thoracotomy, to preserve all flap possibilities.

Technique

Our clinical experience of re-operation for TEF suggests that some key points need to be observed during initial surgery.

During primary surgery, it is important to spare all flap possibilities (Fig. 1). When a mini-invasive procedure is chosen, thoracoscopic trocars should be carefully placed at the upper edge of the rib, avoiding the sixth, seventh, and eighth intercostal spaces. This would preserve all flap possibilities. Special care should be taken not to use these spaces for thoracic drainage, to avoid damage of the intercostal vascular pedicle. A thoracic drain placed through the abdominal wall will serve well [6]. Indeed, such drainage seems less painful than the traditional thoracic drain.

In practice, open thoracotomy is still routinely performed for tumor resection. Particularly when using an open approach, some key points must be borne in mind to maximize the possibilities for later flap harvesting if a complication develops (Fig. 2).

Firstly, the latissimus dorsi should always be preserved (Fig. 3) but that was rarely the case in our series [7]. It reduces postoperative pain [7] without increasing surgical morbidity. In our experience, with muscle conservation, esophagectomy is no more difficult than with standard posterolateral thoracotomy; the latissimus dorsi is moved forward and backward on demand during operation. If this muscle is preserved, a muscular flap can be harvested if a complication develops (Fig. 1).

The second key point concerns rib plane closure. Usually, three or four absorbable stitches are placed. These should be placed for the inferior rib to the transcostal plane and a manual

perforator should be employed to preserve the intercostal vessels lying just under the thoracotomy site (Fig. 4 and 5). This allows later creation of skin perforator flap pedicled by intercostal muscle (Fig. 6). Special attention should be brought to the placement of drains.

Results

Between June 2016 and August 2017, we treated five patients with postoperative TEFs by placing interposition skin perforator flaps pedicled by the intercostal muscle, as previously described [2,3]. Four patients underwent thoracotomy through the fifth intercostal space during initial surgery. When an emergency interposition flap is placed to treat a TEF, we seek to avoid complications associated with flap harvesting; we perform intercostal muscle dissection through the seventh intercostal space because the sixth intercostal vessels are systematically ligatured when the general surgeon closes the thoracotomy. In one patient, during flap harvesting, we discovered that the initial thoracotomy had been closed with a wire ligating the vessels of the seventh space in a region posterior to the axillary line. For this patient, we created a second skin perforator flap pedicled by the intercostal muscle in the underlying space and used tension to close the donor site.

Discussion

Gastric-airways fistulas after resection of esophageal cancer are rare and have been little reported in the literature which explains why there is no guideline currently for their management. Endoprosthesis placement is often chosen as the first-line therapy because it is less invasive, using of an interposition flap is often reserved for a trained team. Only a few relevant case reports have appeared. Various interposition flaps have been used to treat TEFs. The choice depends on the location of the fistula. For an intrathoracic TEF, the most common options are latissimus dorsi [4], pectoralis major [5], intercostal muscle flaps, and skin

perforator flaps pedicled by an intercostal muscle flap [2,3]. Pericardial and pleural flaps have also been reported. If treating a cervical fistula, a neck muscle flap is also an option.

In our opinion, when treating an intrathoracic fistula, only two flaps can reach deep sites and thus cover all types of fistulae (in any area); these are a latissimus dorsi muscle flap and a skin perforator pedicled by an intercostal muscle flap (Fig. 6). Both flaps have a very long pedicle and a large surface. This is why it is essential to preserve the latissimus dorsi muscle during open surgery. The muscle is easily and rapidly harvested and can cover all types of fistulae (tracheal or bronchial). A disadvantage is that the flap is not readily malleable; waterproof closure is difficult. In addition, the flap is bulky, and may compress the gastric tract or the airway. In our experience, thoracotomy with preservation of the latissimus dorsi muscle can be performed without undermining, thus avoiding postoperative seroma formation [7]. An intercostal muscle flap is principally used to reinforce the anastomosis created during thoracic surgery [8]. The aim is to place well-vascularized tissue permitting good revascularization of the tracheobronchial anastomosis, but this flap is not sufficiently wide to cover a defect. Currently, to solve this problem, we add a skin perforator flap to the intercostal muscle. We have been forced to use skin perforator flaps pedicled by the intercostal muscle to treat TEFs because the latissimus dorsi muscle is often cut during initial surgery without any note in the operative record. Otherwise, the flap can be harvested using a surgical revision approach, thus allowing direct closure of the donor site. This flap is very plastic; tracheoesophageal compression is not a concern and preservation of gastric plasty is possible. During primary thoracotomy, if rib closure preserves the underlying pedicle because a transcostal approach is used, the flap can be harvested in the underlying space without undermining subcutaneous tissue.

In conclusion, we emphasize on some key points that thoracic or general surgeons should keep in mind when performing esophageal surgery. These optimally conserve flap options for the plastic surgeon who may later be required to create a transposition flap.

Conflict of interest statement

The authors have no conflict of interest to disclose.

References

1. Lubbers M, van Det MJ, Kreuger MJ, Hoekstra R, Hendriksen EM, Vermeer M, *et al.* Totally minimally invasive esophagectomy after neoadjuvant chemoradiotherapy: Long-term oncologic outcomes. *J Surg Oncol* 2018;117:651–8.
2. Bertheuil N, Cusumano C, Meal C, Harnoy Y, Watier E, Meunier B. Skin perforator flap pedicled by intercostal muscle for repair of a tracheobronchoesophageal fistula. *Ann Thorac Surg* 2017;103:e571–e3.
3. Bertheuil N, De Latour B, Meunier B. Skin perforator flap pedicled with intercostal muscle: Additional data. *Ann Thorac Surg* 2018;105:990.
4. Hayashi K, Ando N, Ozawa S, Tsujizuka K, Kitajima M, Kaneko T. Gastric tube-to-tracheal fistula closed with a latissimus dorsi myocutaneous flap. *Ann Thorac Surg* 1999;68:561–2.
5. Siu KF, Wei WI, Lam KH, Wong J. Use of the pectoralis major muscle flap for repair of a tracheoesophageal fistula. *Am J Surg* 1985;150:617–9.
6. Sun HB, Li Y, Liu XB, Zhang RX, Wang ZF, Lerut T, *et al.* Early oral feeding following McKeown minimally invasive esophagectomy: An open-label, randomized, controlled, noninferiority trial. *Ann Surg* 2018;267:435–42.
7. Akcali Y, Demir H, Tezcan B. The effect of standard posterolateral versus muscle-sparing thoracotomy on multiple parameters. *Ann Thorac Surg* 2003;76:1050–4.

8. Rendina EA, Venuta F, De Giacomo T, Ricci C. Intercostal pedicle flap in tracheobronchial surgery. *Ann Thorac Surg* 1996;62:630–1.

Figure legends

Fig. 1: The two main flap interposition possibilities for surgical repair of a TEF.

The Latissimus dorsi muscle harvesting and the skin perforator flap pedicled by intercostal muscle.

Fig. 2: Thoracotomy errors.

Thoracotomy without preservation of the latissimus dorsi muscle and without transcostal closure of the rib plane and consequently ligation of the subcostal pedicles.

Fig. 3: Thoracotomy with preservation of the latissimus dorsi muscle

Fig. 4: Thoracotomy closure with handle perforator

Fig. 5: Thoracotomy with preservation of the subcostal vessels

Fig. 6: Skin perforator flap pedicled by intercostal muscle harvesting.

A 62 years-old man with a TEF at day 6 post-operatively after a Lewis-Santý procedure. Primary surgery was performed by a thoracotomy in the 5th intercostal space with preservation of the latissimus dorsi muscle but without closure of the rib plane by transcostal points. The flap was harvested in the 7th intercostal plane.

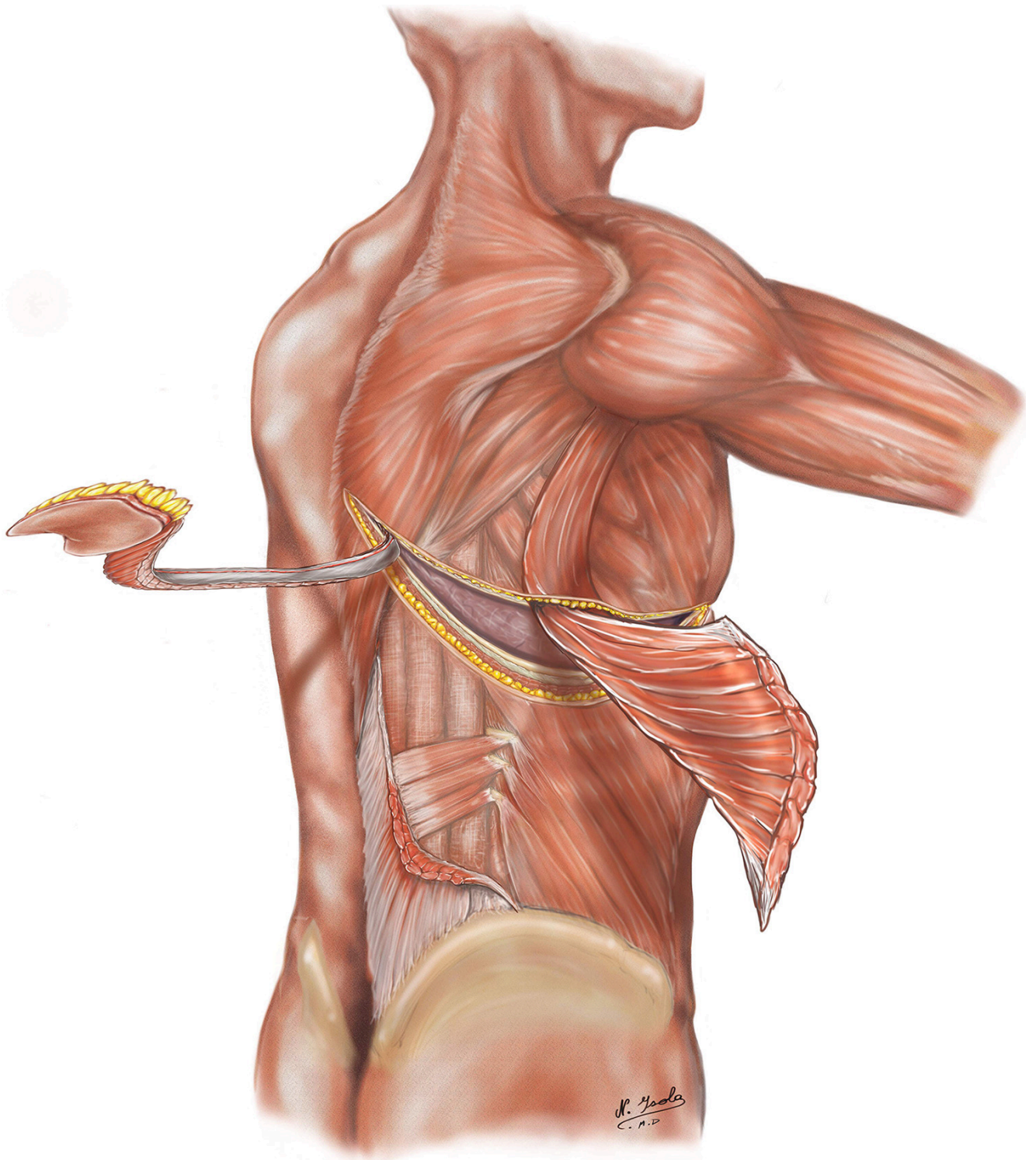


Figure 1. The two main flap interposition possibilities for surgical repair of a TEF. The Latissimus dorsi muscle harvesting and the skin [perforator flap](#) pedicled by [intercostal muscle](#).

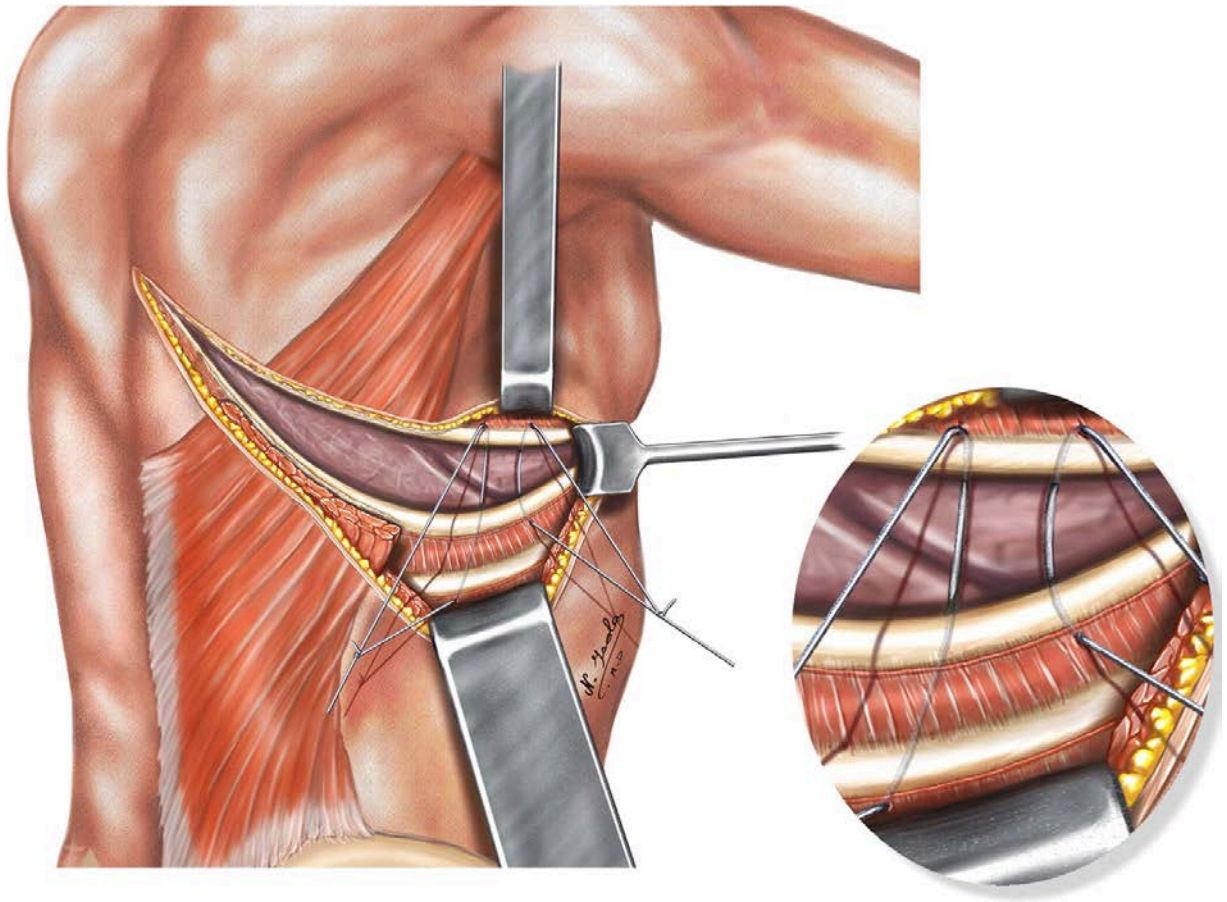


Figure 2. [Thoracotomy](#) errors. Thoracotomy without preservation of the latissimus dorsi muscle and without transcostal closure of the rib plane and consequently [ligation](#) of the subcostal pedicles.

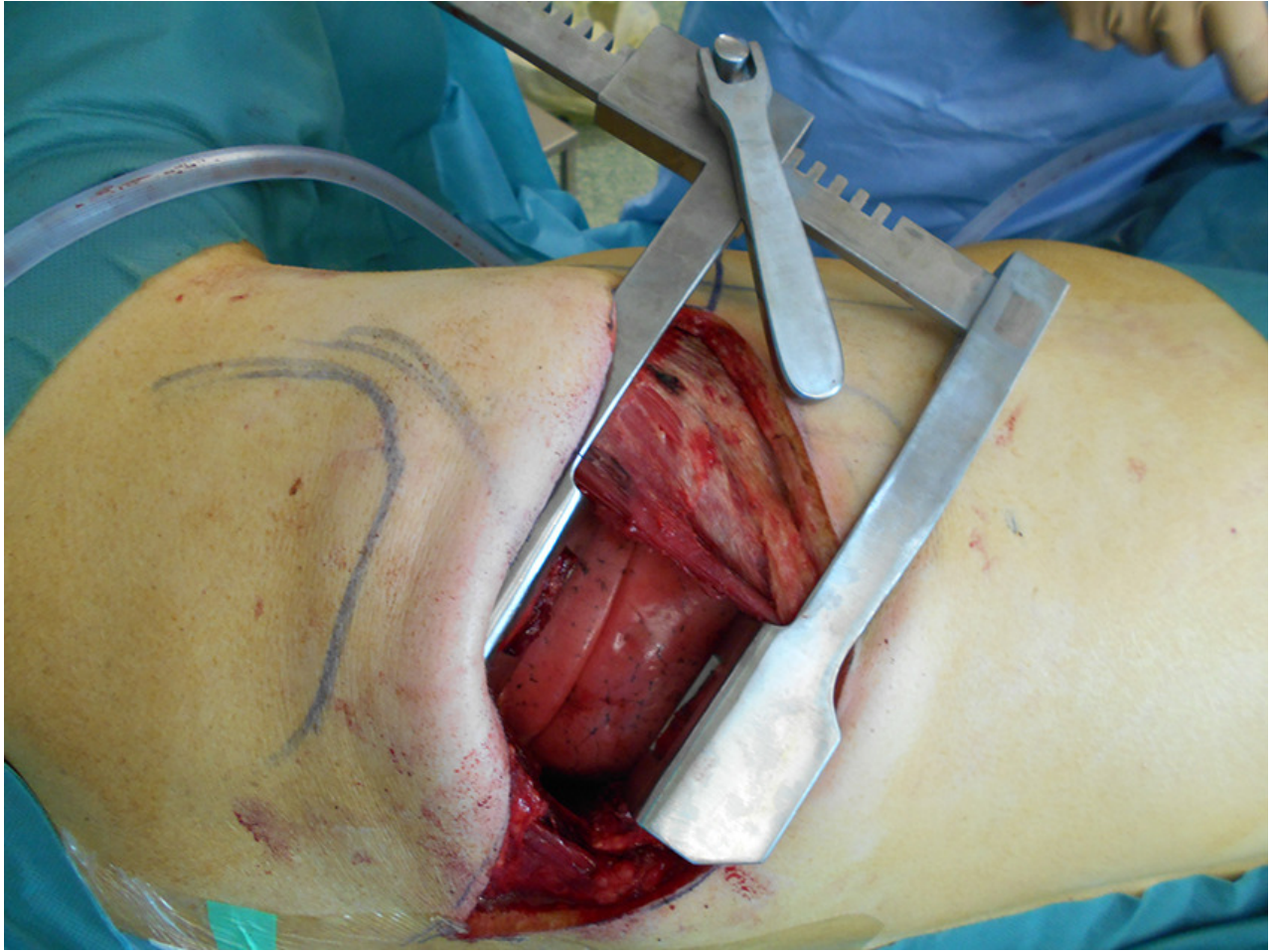


Figure 3. [Thoracotomy](#) with preservation of the latissimus dorsi muscle.

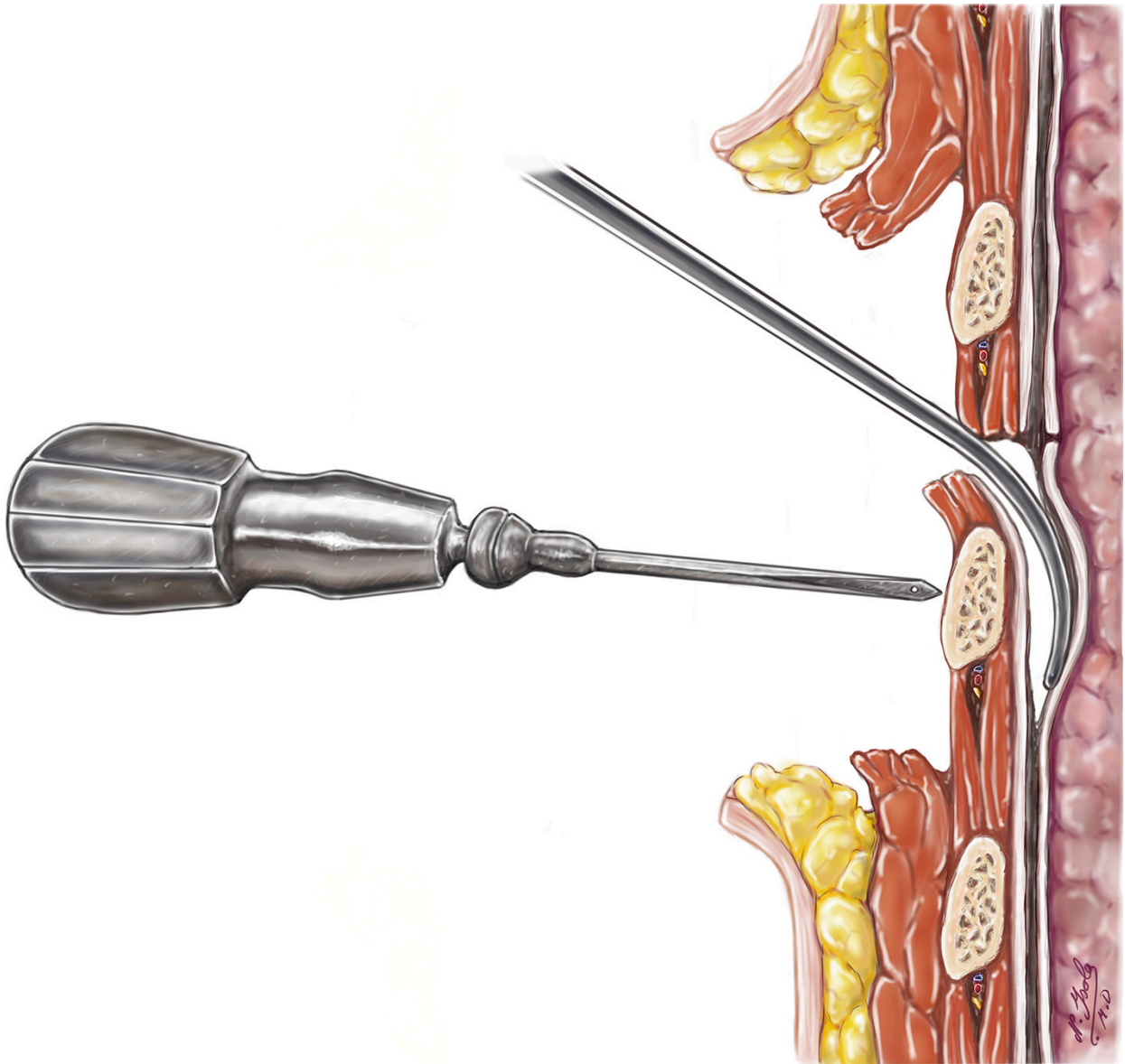


Figure 4. [Thoracotomy](#) closure with handle perforator.

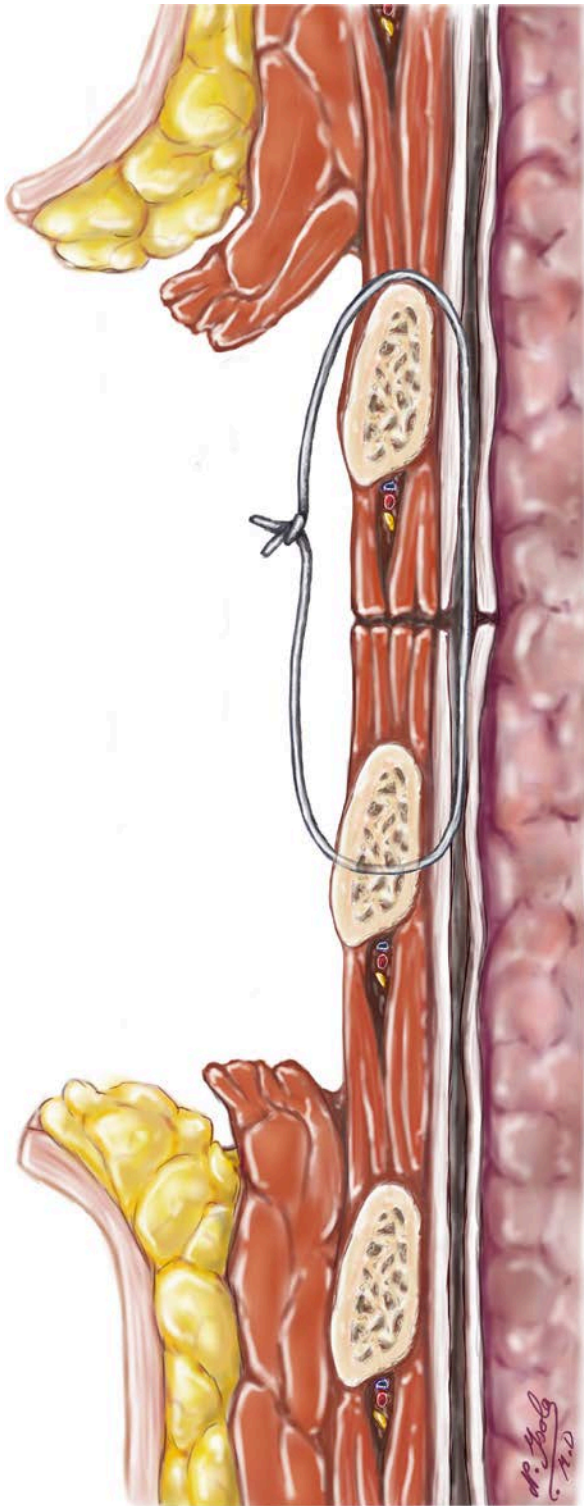


Figure 5. [Thoracotomy](#) with preservation of the subcostal vessels.

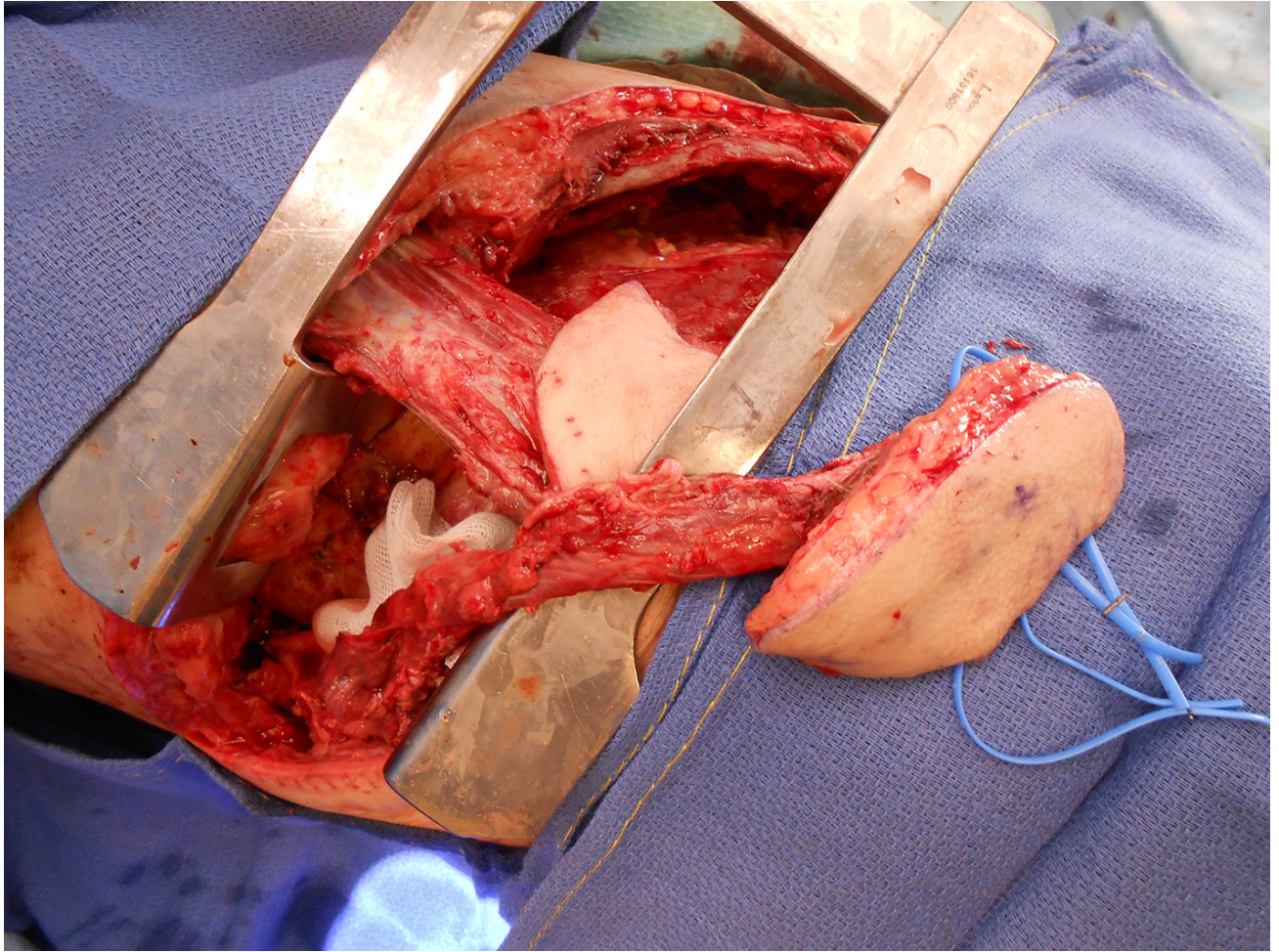


Figure 6. Skin [perforator flap](#) pedicled by [intercostal muscle](#) harvesting. A 62 years-old man with a TEF at day 6 postoperatively after a Lewis-Santny procedure. Primary surgery was performed by a [thoracotomy](#) in the 5th [intercostal space](#) with preservation of the latissimus dorsi muscle but without closure of the rib plane by transcostal points. The flap was harvested in the 7th intercostal plane.

The English in this document has been checked by at least two professional editors, both native speakers of English. For a certificate, please see:

<http://www.textcheck.com/certificate/Yyavne>