



HAL
open science

A pre-operative scoring system for adnexal mass in children and adolescents to preserve their future fertility

C Depoers, F A Lebaccon, K Nyangoh Timoh, J Morcet, M Proisy, S Henno,
V Lavoue, a P Arnaud

► To cite this version:

C Depoers, F A Lebaccon, K Nyangoh Timoh, J Morcet, M Proisy, et al.. A pre-operative scoring system for adnexal mass in children and adolescents to preserve their future fertility. *Journal of Pediatric and Adolescent Gynecology*, 2019, 32 (1), pp.57-63. 10.1016/j.jpag.2018.08.009 . hal-01880073

HAL Id: hal-01880073

<https://univ-rennes.hal.science/hal-01880073>

Submitted on 28 Sep 2018


HAL is a multi-disciplinary open access archive for the deposit and dissemination of scientific research documents, whether they are published or not. The documents may come from teaching and research institutions in France or abroad, or from public or private research centers.

L'archive ouverte pluridisciplinaire **HAL**, est destinée au dépôt et à la diffusion de documents scientifiques de niveau recherche, publiés ou non, émanant des établissements d'enseignement et de recherche français ou étrangers, des laboratoires publics ou privés.

Accepted Manuscript

A pre-operative scoring system for adnexal mass in children and adolescents to preserve their future fertility

C. Depoers, MD, F.A. Lebaccon, MD, K. Nyangoh Timoh, MD, J. Morcet, PhD, M. Proisy, MD, S. Henno, MD, V. Lavoue, MD PhD, A.P. Arnaud, MD



PII: S1083-3188(18)30303-6

DOI: [10.1016/j.jpag.2018.08.009](https://doi.org/10.1016/j.jpag.2018.08.009)

Reference: PEDADO 2273

To appear in: *Journal of Pediatric and Adolescent Gynecology*

Received Date: 11 February 2018

Revised Date: 28 August 2018

Accepted Date: 30 August 2018

Please cite this article as: Depoers C, Lebaccon F, Nyangoh Timoh K, Morcet J, Proisy M, Henno S, Lavoue V, Arnaud AP, A pre-operative scoring system for adnexal mass in children and adolescents to preserve their future fertility, *Journal of Pediatric and Adolescent Gynecology* (2018), doi: 10.1016/j.jpag.2018.08.009.

This is a PDF file of an unedited manuscript that has been accepted for publication. As a service to our customers we are providing this early version of the manuscript. The manuscript will undergo copyediting, typesetting, and review of the resulting proof before it is published in its final form. Please note that during the production process errors may be discovered which could affect the content, and all legal disclaimers that apply to the journal pertain.

1 **A pre-operative scoring system for adnexal mass in children and adolescents to preserve**
2 **their future fertility**

3

4 C.Depoers¹, MD, FA.Lebaccon^{1,2}, MD, K.Nyangoh Timoh¹, MD, J.Morcet³, PhD, M.Proisy⁴,
5 MD, S.Henno⁵, MD, V.Lavoue⁶, MD, PhD, A.P.Arnaud⁷, MD *.

6

7 Study was undertaken in Rennes, France.

8

9 1. Univ Rennes, CHU Rennes, Service de gynécologie, F-35000 Rennes, France

10 2. Univ Rennes, CHU Rennes, Service de chirurgie pédiatrique, F-35000 Rennes, France

11 3. Univ Rennes, CHU Rennes, Centre d'investigation clinique, INSERM 1414, F-35000
12 Rennes, France

13 4. Univ Rennes, CHU Rennes, Service de radiologie pédiatrique, F-35000 Rennes, France

14 5. Univ Rennes, CHU Rennes, Service d'anatomie pathologique, F-35000 Rennes, France

15 6. Univ Rennes, CHU Rennes, Service de gynécologie, Inserm, U1242, F-35000 Rennes,
16 France

17 7. Univ Rennes, CHU Rennes, Service de chirurgie pédiatrique, Inra, Inserm, Institut NU-
18 MECAN – UMR_A 1341, UMR_S 1241, F-35000 Rennes, France

19

20 All authors have no conflict of interest. The study was performed without any funding.

21

22 *Corresponding author (and for request for reprints and galley proofs):

23 Alexis P Arnaud, MD.

24 Telephone number: 0033 299265930

25 Fax number: 0033 299265932

26 E-mail: alexis.arnaud@chu-rennes.fr

27 Service de chirurgie pédiatrique, CHU Hôpital Sud

28 16 Bd de Bulgarie

29 35203 Rennes

30 France

31

32

33 **Word count:** 3192

34 **Abstract**

35 **STUDY OBJECTIVE:** To develop a predictive score for ovarian malignancy to avoid
36 unnecessary adnexectomy in cases of adnexal mass in pediatric and adolescent girls.

37 **DESIGN:** A population-based retrospective study on girls who underwent surgery for an
38 ovarian mass with normal levels of human chorionic gonadotrophin (hCG) and alpha
39 foetoprotein (aFP) between 1996 and 2016.

40 **SETTING:** Rennes University Hospital, Rennes, France.

41 **PARTICIPANTS:** Eighty-one patients operated on for ovarian tumor.

42 **MAIN OUTCOME MEASURES:** The main outcome measure was the rate of malignant and
43 borderline tumor. A pre-operative scoring system was constructed after multivariate analysis.

44 **RESULTS:** The rate of malignant ovarian tumor was 7%, borderline tumor was 9% (i.e.,
45 outcome measure: 16%), and benign tumor was 84%. In a univariate analysis, the
46 characteristics significantly associated with malignancy were early puberty, palpable mass,
47 size and content of the tumor, and positive epithelial tumor markers [CA 125, CEA, and CA
48 19-9]. The predictive malignancy score was based on two variables obtained after multivariate
49 analysis: tumor size and cystic content. The score defined 3 groups at risk for malignancy:
50 low risk, middle-risk and high-risk. The sensitivity for detecting malignancy was 1.3%
51 (95%CI: 0.1–18.4), 26.2% (95%CI: 11.6-49.0) and 53.1% (95%CI: 29.1–75.8), respectively.

52 **CONCLUSION:** We set up a simple predictive score of malignancy based on objective
53 criteria to help decision making on whether or not ovarian-sparing surgery is feasible in case
54 of children and adolescents with ovarian tumors and normal hCG and aFP levels while
55 ensuring oncologic safety.

56

57 **Key words:** Adnexal mass, children, adolescent, surgery, ovarian malignancy, score, ovarian
58 preservation.

59 **INTRODUCTION**

60 Ovarian tumors in children and adolescents are rare, with an estimated incidence in girls of
61 2.2/100,000¹⁻³. The majority of ovarian tumors in this population are benign and often
62 organic; only 10-20% are malignant^{4,5}. Among children and adolescents, only 1% of pediatric
63 cancers are malignant tumors of the ovary⁴⁻⁹. The age of the child does not change the risk of
64 malignant ovarian tumors. Germ-cell tumors represent most ovarian tumors and include
65 mature benign teratomas (dermoid cysts)¹⁰. Overall, patients with malignant germ-cell tumors
66 have a good prognosis¹¹. Sex-cord stromal tumors are regularly seen in pediatrics. The
67 prognosis of these tumors is related to the initial surgery, which must be complete¹².

68 The discovery of an ovarian mass in a child presents a dilemma regarding the optimal
69 treatment. An immediate oophorectomy, or adnexectomy, has the best oncological safety,
70 whereas an ovarian cystectomy better preserves the patient's fertility. Indeed, an ovariectomy
71 or adnexectomy in childhood is correlated with a lower spontaneous pregnancy rate (45,5%)
72^{13,14} and premature ovarian failure¹⁵, which is an ongoing concern. Of note, in Western
73 countries, because of societal evolution, pregnancy occurs later, with 22% of births occurring
74 in women over 35 years of age¹⁶. Thus, women who underwent ovariectomy in childhood are
75 particularly vulnerable to ovarian failure at the time of conception, and ovarian preservation
76 in children is crucial to protect their future fertility. However, oncologic surgery remains
77 mandatory for the treatment of ovarian cancer to avoid compromising an otherwise good
78 prognosis. Indeed, the main risk of ovarian-sparing surgery in case of malignant germ cell
79 tumor is either spillage or recurrence on the preserved parenchyma^{10,17}.

80 The rates of conservative surgery for ovarian mass in pediatric patients are from 18% to 72%
81^{1,18-20} depending on surgeon habits and cohort studies, reflecting the fact that a majority of
82 benign adnexal masses in children are removed via oophorectomy. Preoperative analysis of
83 the lesion remains crucial for tailoring surgical management, i.e., appropriately choosing

84 between oophorectomy and ovarian conservative management ²¹. Although International
85 Ovarian Tumor Analysis (IOTA) classification for adnexal masses is available for adult
86 women ²², there are no objective criteria or reproducible tools to preoperatively predict the
87 risk of malignancy in children with an adnexal mass.

88 The aim of this study was to determine the predictive factors of malignancy in pediatric pa-
89 tients with an adnexal mass and to develop a simple score for predicting malignancy.

90

91

92

93 **METHODS**

94 **Objective and design of the study**

95 This was a population-based retrospective study conducted from January 1996 to April 2016
96 in a tertiary hospital (Rennes Teaching Hospital, France). Inclusion criteria were patients aged
97 0 to 18 years with a diagnosis of ovarian mass who underwent surgical treatment. Exclusion
98 criteria were positive germinal tumor markers: alpha-fetoprotein (α FP) > 10 ng/mL, human
99 chorionic gonadotropin (HCG) > 5 mU/mL or a functional follicle on sonography or
100 pathological analysis. Indeed, positive germinal tumor markers are always associated with a
101 malignant germ cell tumor^{4,11,23,24}. We differentiated germinal tumor markers (α FP and HCG)
102 from epithelial tumor markers (cancer antigen (CA) 125 (CA125), carcinoembryonic antigens
103 (CEA), and CA 19-9).

104 The main outcome measure was defined as the finding of ovarian cancer or a borderline
105 ovarian tumor on the final pathological analysis because these findings usually required
106 adnexectomy. Ovarian borderline lesions were diagnosed upon pathological analysis
107 according to the 2014 World Human Organization criteria²⁵, as was ovarian cancer. All final
108 pathological analyses were reviewed by a certified pathologist (SH).

109 This study was approved by the local Institutional Review Board (CEROG 2016-GYN-1003).

110 **Data collection**

111 The medical database from the pediatric surgery department was used to select the patients.
112 The data were collected from the patients' medical records, which were stored in the
113 hospital's archiving system. Data regarding the patient's age at diagnosis, hormonal status
114 (puberty, defined by the presence of a menstrual cycle), medical history, and clinical
115 symptoms were collected. According to the symptoms, a palpable mass was defined as the

116 palpation of a mass by the patient or her physician, or as an increase in the abdominal
117 perimeter observed by the patient.

118 The characteristics of the ovarian lesions were obtained from preoperative imaging
119 [ultrasound, abdomino-pelvic computed tomography (CT) and/or pelvic magnetic resonance
120 imaging (MRI)] and described according to the International Ovarian Tumor Analysis (IOTA)
121 classification²² for pelvic ultrasound using the following ten criteria: maximum diameter of
122 the mass, the presence of a septum, the regularity of the wall, type of cyst (multilocular, solid
123 multilocular, unilocular, solid unilocular, solid), cyst content, solid papillary projection,
124 posterior shadow cone, Doppler signal strength, and the presence of ascites or a peritoneal
125 implant. All preoperative imaging were reviewed by a certified specialist in the imaging of the
126 female reproductive system who was blind to the final pathological analysis.

127 Data regarding elevated levels of tumor markers [α FP > 10 ng/ml, HCG > 5 mU/ml, CEA >
128 30 μ g/L, cancer antigen CA125 > 35 U/ml, and CA19-9 > 37 U/ml], the type of surgery
129 performed, association with an adnexal torsion, complications of the surgical procedure, and
130 pathological findings were also collected.

131 The lesions were classified as benign and non-benign comprising borderline and malignant
132 tumours.

133 **Statistical analysis**

134 For quantitative variables, data were expressed as mean \pm standard deviation (SD) if normally
135 distributed and median (min-max) if not normally distributed. For qualitative variables, data
136 were expressed as n (%). Comparisons between groups were performed using t-tests for nor-
137 mally distributed variables, Wilcoxon for non-normally distributed variables and chi-square
138 test or fisher exact test for categorical variables. A forward logistic regression analysis was
139 applied to the statistically significant variables to test their association with malignancy. All

140 variables for which statistical significance was <0.2 were introduced into models. Optimal
141 cut-off values were obtained by optimization of the Younden index from AUROC curve anal-
142 ysis. The predictive malignancy score was constructed from variables derived from the mul-
143 tivariate analysis. Sensitivity, specificity, negative predictive value (NPV), positive predictive
144 value (PPV) were also calculated. A P value of <0.05 was considered statistically significant.
145 Statistical analyses were performed using SAS V9.4 (SAS Institute, USA).

146

147

148

149

150

151

152

153

154

155

156

157

158

159

160

161

162 RESULTS

163 An adnexal mass was detected in 89 children during the study period. One patient was ex-
164 cluded because of follicle diagnosis, and seven others were excluded because of high levels of
165 serum α FP and HCG, which are known positive markers of germinal tumor (figure 1). All
166 seven of these patients underwent ovariectomy surgery and final ovarian germinal tumor di-
167 agnosis. Finally, 81 patients were included in the study.

168

169 Descriptive data

170 The characteristics of the patients are summarized in Table 1. The mean (\pm standard
171 deviation) age of the population was 13.1 (\pm 4.7) years, without significant difference
172 between the two groups ($p=0.40$). There were 36 (44%) right ovarian masses and 45 (56%)
173 left ovarian masses. There were 4 (31%) malignant tumors and 26 (38%) benign tumors
174 among the pre-pubescent patients ($p=0.76$).

175 Laparotomy was performed in 20 patients (25%), while 61 (75%) underwent laparoscopic
176 surgery, including 22 conversions to laparotomy. Among these 22 patients with conversions,
177 one tumor was borderline, and 21 were benign (7 adnexal masses had a size > 100 mm).
178 Finally, 42 (52%) laparotomies were performed (32 horizontal and 10 median laparotomies)
179 for 30 benign tumors (44.1%) and 12 malignant tumors (92.3%) ($p<0.0001$).

180 Of note, there were 14 adnexal torsions, all due to a benign mass. Ten underwent a non-
181 conservative treatment and 4 either tumorectomy or isolated adnexal detorsion.

182 The pathological results are presented in Table 2. Briefly, seven patients had an epithelial
183 borderline ovarian tumor and six had ovarian cancer (five non-epithelial tumors and one
184 epithelial tumor). Thus, 13 (16%) of the 81 patients had an adnexal tumor that required
185 oncologic surgical treatment, i.e., non-conservative treatment (primary outcome measure).

186 In the present study, all patients with malignant tumors were treated with non-conservative
187 surgery (oophorectomy or adnexectomy), and 3 out of the 7 patients with borderline tumors
188 underwent cystectomy.

189 **Data analysis**

190 Symptoms were significantly associated with malignancy ($p=0.01$), especially early puberty
191 and palpable mass (Table 1).

192 Preoperative ultrasound was performed for 79 patients; 24 patients underwent CT, and 22
193 underwent MRI. The size of the lesion was significantly associated with malignancy ($p <$
194 0.0003) as all malignant lesions exceeded 65 mm in diameter with a mean size of 166.1 mm
195 (70.3) vs. 86.3 mm (63.9) for benign lesions in the univariate analysis. A lesion size > 100
196 mm following the IOTA classification's cut-off was correlated with ovarian cancer ($p =$
197 0.003) as determinate in a univariate analysis (Table 1).

198 Among the morphological criteria used in echography to characterize a malignant tumor, the
199 type of ovarian mass was significantly associated with malignancy ($p=0.002$). In this study, a
200 solid multilocular mass was identified in 5/13 (38%) patients with malignant tumors vs. 5/68
201 (7%) patients with benign tumors (Table 1).

202 Tumor markers were significantly associated with ovarian malignancy ($p = 0.009$) and were
203 measured in 64/81 (79%) patients. Tumor markers were elevated in 7/13 (54%) patients with
204 malignant tumors vs. 9/51 (17%) patients with benign tumors.

205 Based on 72 patients who underwent preoperative sonography, the multivariate analysis
206 defined two predictive factors of malignancy and borderline tumor: the size of the tumor
207 (<65 mm, between 65-130mm, >130 mm) and the ultrasound aspect of the tumor (unilocular
208 cystic tumor or not) (Table 3).

209 Malignancy scoring system

210 A predictive score for malignancy (Table 4) was constructed using the two variables
211 associated with malignant ovarian tumor or borderline tumor derived from the multivariate
212 analysis. A receiver operating curve (ROC) was plotted to determine the sensitivity and
213 specificity of the score (Figure 2). The area under the curve (AUC) of the ROC was 0.88
214 [0.80 – 0.95].

215 Following the IOTA recommendations with a single cut-off at 100mm, the multivariate Odd
216 Ratio was 7.68 (1.96-30.07). To maximize the statistical significance of the “lesion size”
217 variable we selected two cut-offs: 65mm and 130mm. The choice of two cut-off points to
218 define a population at low risk (<65mm) and a population at high risk (>130mm) provided a
219 clinical prediction rule with a good diagnostic performance: the low risk cut-off point defined
220 a model with a sensitivity of 100% and the high risk cut-off point defined a model with a
221 specificity of 88%.

222 The score was constructed from the logistic model coefficients (Table 4). Using a score cut-
223 off >25, the sensitivity, specificity, positive predictive value and negative predictive value for
224 predicting malignancy were 100%, 63%, 37% and 100%, respectively.

225 Clinical utility of the score

226 The score stratified the population in 3 groups at low-risk, middle-risk and high-risk of malig-
227 nancy. This was applied to our study population following the rules that low-risk was due to
228 ovarian-sparing surgery, high-risk to non-sparing surgery and middle-risk to further investiga-
229 tions or discussion. This resulted in 46 (57%) patients who should be spared adnexectomies,
230 16 (20%) patients who would have been referred for non-conservative treatment, and 19
231 (23%) who would have required more investigations and discussion on the risk and benefits
232 of each option. This led to 80% of non-radical first line treatment (conservative treatment or
233 implement investigations).

234 **DISCUSSION**

235 In the present study, we created a simple score for predicting malignancy in children and
236 adolescents with adnexal mass and therefore helping to determine whether conservative or
237 radical surgery is the optimal treatment strategy. We built a scoring system using factors
238 found in the multivariate analysis: tumor size and cyst component. This tool provides ensured
239 oncologic safety while preserving fertility. In our series, fertility would be directly spared in
240 57% of children with adnexal mass, and 23% of the patients would require more
241 investigations before taking the decision on ovarian sparing surgery. All patients with ovarian
242 cancer (borderline or invasive) would undergo either non-conservative surgical treatment or
243 continuation of the work-up, which is, at present day, the correct oncologic decision.

244 Some weaknesses of present study must be mentioned, particularly in relation to the
245 misinterpretation of data, classification bias, or missing data because of the study's
246 retrospective nature. Nevertheless, our results are similar to those previously reported in
247 populations ranking from 41 to 112 patients with a malignancy prevalence of malignancy
248 between 10 to 20%. This prevalence might vary depending on the age at screening and the
249 availability of tertiary screening centers. Conservative surgery ratios vary between 15% and
250 87% according to recent studies^{1,18-20,26}.

251 Many studies have sought to identify predictive characteristics to guide the decision of con-
252 servative vs. radical surgery^{17,27-30}. The detection of α FP and HCG (marker of germinal tu-
253 mor) in blood testing strongly indicated that the tumor is malignant, which is why patients
254 with positive germinal markers were excluded from our study because required non-
255 conservative surgical treatment for oncologic purpose. To predict whether a tumor might be
256 benign or malignant, its characteristics are determined using pelvic echography or MRI. For
257 example, tumors > 7.5-8 cm are at high risk of being malignant, according to published data
258^{19,26,27,31}. The threshold varies depending on the studies and specificity and sensitivity levels

259 chosen: in the present study, a tumor size correlated with malignancy was 65 mm or larger (as
260 much as 100 mm or more). As opposed to adult women, there is no classification dedicated to
261 the pediatric population to differentiate benign from malignant tumors based on their ultra-
262 sound features (or MRI features). Thus, in present study, we used IOTA classification to sort
263 and interpret preoperative sonography pictures ^{22,32}. Using the simple rules proposed by the
264 IOTA classification, our study showed first that solid multilocular ovarian mass is significant-
265 ly associated with malignancy in children.

266 The Ueland Index, described by Stankovick, is an ultrasonographic algorithm tool specific to
267 the pediatric population ^{33,34}. Its two criteria are the volume and structural characteristics of
268 the tumor. A tumor is considered benign if it is < 5 cm and malignant if > 7 cm in diameter.
269 This tool predicted the risk of malignancy with a sensitivity of 90% and a specificity of 94%.
270 In another recent study, Stankovic showed that discrimination between benign and malignant
271 tumors in pediatric and adolescent patients was greater with the Ueland index than with the
272 search for the ovarian crescent sign (OCS). Indeed, there is a lack of reproducibility in the
273 ultrasonographic search for the OCS ³⁵, as it is difficult to spot when the mass is > 5 cm in
274 abdominal echography; therefore, it is unreliable as a discriminating sign. Nevertheless, the
275 Ueland Index had some weakness because it was determined as an algorithm and not based on
276 a statistical tool, such as logistic regression, as our proposed robust score. Both our score and
277 the Stanakovic algorithm still require external validation using multicenter prospective cohort.

278 Despite previous studies have shown that size and complexity were important predictors of
279 malignancy ^{19,20,26,36,37}, none of the different scoring system or preoperative stratification has
280 proven its clear utility. For example, following the recommendations published by Rogers et
281 al ²⁰, 15 patients in our series would have had a malignant tumor management because of the
282 size>8cm of their ovarian masses. We also applied the preoperative risk stratification
283 described by Madenci et al in 2016 on our series³⁶. This led to 54.5% ovarian sparing surgery,

284 10% non-sparing surgery and 35.5% of doubtful cases. Our score led to 57%, 20% and 23%
285 respectively. In their series, Madenci et al³⁶ reported less malignant tumors (8% vs 16%) and
286 included functional cyst (23%) that we did not consider as ovarian tumors and were excluded
287 in our study. As stated in many studies, every case should be unique and discussed between
288 family and surgeons. Thus, we propose a simple score to add an objective value to the
289 discussion and decision-making and improve the armamentarium that helps dealing with
290 ovarian tumors. Using this score in a daily manner would be easier and less tedious than
291 following most of the risk stratifications previously described. In practice, when seeing
292 children with adnexal mass, physicians should perform an ultrasound scan and the usual
293 work-up with tumor markers. In case of confirmed ovarian tumor with negative α FP and
294 HCG, one could apply this scoring system and adapt the strategy and the speech given to the
295 family following the predictive risk described in Table 4. Patients in the low-risk group could
296 undergo ovarian-sparing surgery, when possible after an MRI to guide the surgery. In the
297 middle-risk group, a complementary work-up comprising at least an MRI should be
298 mandatory taking into account the 26% predictive risk of malignancy. Patients belonging to
299 the high-risk group should be proposed a non-conservative treatment.

300 In our study, 10 out of 14 adnexal torsions were treated with oophorectomy or adnexectomy.
301 Since the introduction of the national or international recommendations in the gynecologic
302 society^{38,39}, this treatment strategy has to change. The revised approach is based on the
303 recognition that even if the ovary has an infarcted appearance, it may recover normal
304 endocrine function¹³; thus, conservative treatment should be attempted in all cases⁴⁰⁻⁴².
305 Indeed, in our study, adnexal torsion was never associated with a malignant or borderline
306 tumor, as confirmed by published data^{13,40}.

307 In the literature, the specialty of the surgeon was shown to influence the decision for ovarian
308 preservation^{31,43} with more conservative treatments performed by gynecologic surgeons and

309 less conservative treatment performed by a pediatric surgeon. This difference in care outcome
310 should be addressed. By using the score evaluated in this study, the probability of malignancy
311 can be better evaluated preoperatively, allowing a better-informed decision regarding ovarian
312 preservation. Our score allowed 57% of ovarian conservative surgeries and 23% of patients
313 requiring more investigations. The ovarian-sparing surgery rate must be improved in the fu-
314 ture and we need to work with radiologist to improve the care of the 23% of doubtful cases. It
315 is likely that adnexal mass in children should be explored systematically by MRI combined
316 with perfusion- and diffusion-weighted MR imaging as used in adult women with ovarian
317 mass⁴⁴. These new tools must be validated in children to improve the ovarian conservation
318 rate in case of adnexal mass since these approaches have only been recently described^{45,46}. It
319 could also help to visualize healthy ovarian tissue remnants in case of large tumors.

320

321

322 **CONCLUSION**

323 To our knowledge, this is the first published simple scoring system for predicting malignancy
324 in children and adolescents with an adnexal mass. It is based on easily obtained sonographic
325 data (size and echogenicity of the tumor) and can be applied in children with an adnexal mass
326 and normal germinal tumor marker levels. The score could be used to guide decision-making
327 regarding conservative vs. non-conservative ovarian surgical treatment and may therefore
328 increase the rate of fertility preservation while ensuring good oncologic safety in a larger
329 number of patients. In our study, 80% of the children with an adnexal mass may undergo
330 ovarian-sparing surgery (57% of first line conservative treatment and 23% requiring more
331 investigations before decision) based on reproducible criteria. However, this scoring system
332 still requires external validation in a prospective multicenter study before it can be routinely

333 used in a clinical setting. MRI combined with perfusion- and diffusion-weighted MR imaging
334 applied to the pediatric population could be the next step in improving the rate of ovarian
335 preservation surgery in children with adnexal mass. Of note, conservative management in
336 cases of adnexal torsion in children, as in adults, will also help to increase the rate of ovarian-
337 sparing surgery.

338

339 Disclosure of interest statement: Nothing to disclose.

340

ACCEPTED MANUSCRIPT

341 **REFERENCES**

- 342 1. Deligeoroglou E, Eleftheriades M, Shiadoes V, et al. Ovarian masses during
343 adolescence: clinical, ultrasonographic and pathologic findings, serum tumor markers
344 and endocrinological profile. *Gynecol Endocrinol Off J Int Soc Gynecol Endocrinol.*
345 2004 Jul;19(1):1–8.
- 346 2. Andrés MM, Costa E, Cañete A, et al. Solid ovarian tumours in childhood: a 35-year
347 review in a single institution. *Clin Transl Oncol Off Publ Fed Span Oncol Soc Natl*
348 *Cancer Inst Mex.* 2010 Apr;12(4):287–91.
- 349 3. von Allmen D. Malignant lesions of the ovary in childhood. *Semin Pediatr Surg.* 2005
350 May;14(2):100–5.
- 351 4. Gribbon M, Ein SH, Mancera K. Pediatric malignant ovarian tumors: a 43-year review. *J*
352 *Pediatr Surg.* 1992 Apr;27(4):480–4.
- 353 5. Yeap S-T, Hsiao C-C, Hsieh C-S, et al. Pediatric malignant ovarian tumors: 15 years of
354 experience at a single institution. *Pediatr Neonatol.* 2011 Jun;52(3):140–4.
- 355 6. von Allmen D, Fallat M. Chapter 39 - Ovarian Tumors A2. In: *Pediatric Surgery*
356 *(Seventh Edition).* Philadelphia; 2012. p. 592–548.
- 357 7. Taskinen S, Fagerholm R, Lohi J, Taskinen M. Pediatric ovarian neoplastic tumors:
358 incidence, age at presentation, tumor markers and outcome. *Acta Obstet Gynecol Scand.*
359 2015 Apr;94(4):425–9.
- 360 8. Mahadik K, Ghorpade K. Childhood ovarian malignancy. *J Obstet Gynaecol India.* 2014
361 Apr;64(2):91–4.

- 362 9. Baert T, Storme N, Van Nieuwenhuysen E, et al. Ovarian cancer in children and
363 adolescents: A rare disease that needs more attention. *Maturitas*. 2016 Jun;88:3–8.
- 364 10. Anteby EY, Ron M, Revel A, et al. Germ cell tumors of the ovary arising after dermoid
365 cyst resection: a long-term follow-up study. *Obstet Gynecol*. 1994 Apr;83(4):605–8.
- 366 11. Flamant F, Baranzelli MC, Kalifa C, Lemerle J. Treatment of malignant germ cell
367 tumors in children: experience of the Institut Gustave Roussy and the French Society of
368 Pediatric Oncology. *Crit Rev Oncol Hematol*. 1990;10(2):99–110.
- 369 12. Cecchetto G, Ferrari A, Bernini G, et al. Sex cord stromal tumors of the ovary in
370 children: a clinicopathological report from the Italian TREP project. *Pediatr Blood
371 Cancer*. 2011 Jul 1;56(7):1062–7.
- 372 13. Al-Turki HA. Fertility after oophorectomy due to torsion. *Saudi Med J*. 2015
373 Mar;36(3):368–70.
- 374 14. Palomba S, Zupi E, Russo T, et al. Comparison of two fertility-sparing approaches for
375 bilateral borderline ovarian tumours: a randomized controlled study. *Hum Reprod Oxf
376 Engl*. 2007 Feb;22(2):578–85.
- 377 15. Yasui T, Hayashi K, Mizunuma H, et al. Factors associated with premature ovarian
378 failure, early menopause and earlier onset of menopause in Japanese women. *Maturitas*.
379 2012 Jul;72(3):249–55.
- 380 16. V B. Statistiques d'état civil sur les naissances en 2013. Insee Résultats 2014; n° 157
381 Société.

- 382 17. Vaysse C, Delsol M, Carfagna L, et al. Ovarian germ cell tumors in children.
383 Management, survival and ovarian prognosis. A report of 75 cases. *J Pediatr Surg.* 2010
384 Jul;45(7):1484–90.
- 385 18. Piippo S, Mustaniemi L, Lenko H, et al. Surgery for ovarian masses during childhood
386 and adolescence: a report of 79 cases. *J Pediatr Adolesc Gynecol.* 1999 Nov;12(4):223–
387 7.
- 388 19. Cass DL, Hawkins E, Brandt ML, et al. Surgery for ovarian masses in infants, children,
389 and adolescents: 102 consecutive patients treated in a 15-year period. *J Pediatr Surg.*
390 2001 May;36(5):693–9.
- 391 20. Rogers EM, Casadiego Cubides G, Lacy J, et al. Preoperative risk stratification of
392 adnexal masses: can we predict the optimal surgical management? *J Pediatr Adolesc*
393 *Gynecol.* 2014 Jun;27(3):125–8.
- 394 21. Oue T, Uehara S, Sasaki T, N et al. Treatment and ovarian preservation in children with
395 ovarian tumors. *J Pediatr Surg.* 2015 Dec;50(12):2116–8.
- 396 22. Peces Rama A, Llanos Llanos MC, Sánchez Ferrer ML, et al. Simple descriptors and
397 simple rules of the International Ovarian Tumor Analysis (IOTA) Group: a prospective
398 study of combined use for the description of adnexal masses. *Eur J Obstet Gynecol*
399 *Reprod Biol.* 2015 Dec;195:7–11.
- 400 23. Ehren IM, Mahour GH, Isaacs H. Benign and malignant ovarian tumors in children and
401 adolescents. A review of 63 cases. *Am J Surg.* 1984 Mar;147(3):339–44.

- 402 24. Spinelli C, Pucci V, Buti I, et al. The role of tumor markers in the surgical approach of
403 ovarian masses in pediatric age: a 10-year study and a literature review. *Ann Surg*
404 *Oncol.* 2012 Jun;19(6):1766–73.
- 405 25. Whittom R. *WHO Classification of Tumours of Female Reproductive Organs.* WHO
406 Press. 2014;
- 407 26. Oltmann SC, Garcia N, Barber R, et al. Can we preoperatively risk stratify ovarian
408 masses for malignancy? *J Pediatr Surg.* 2010 Jan;45(1):130–4.
- 409 27. Papic JC, Billmire DF, Rescorla FJ, et al. Management of neonatal ovarian cysts and its
410 effect on ovarian preservation. *J Pediatr Surg.* 2014 Jun;49(6):990-993-994.
- 411 28. Amies Oelschlagel A-ME, Gow KW, Morse CB, Lara-Torre E. Management of Large
412 Ovarian Neoplasms in Pediatric and Adolescent Females. *J Pediatr Adolesc Gynecol.*
413 2016 Apr;29(2):88–94.
- 414 29. Templeman CL, Hertweck SP, Scheetz JP, Perlman SE, Fallat ME. The management of
415 mature cystic teratomas in children and adolescents: a retrospective analysis. *Hum*
416 *Reprod Oxf Engl.* 2000 Dec;15(12):2669–72.
- 417 30. Skiadas VT, Koutoulidis V, Eleytheriades M, et al. Ovarian masses in young
418 adolescents: imaging findings with surgical confirmation. *Eur J Gynaecol Oncol.*
419 2004;25(2):201–6.
- 420 31. Eskander RN, Bristow RE, Saenz NC, Saenz CC. A retrospective review of the effect of
421 surgeon specialty on the management of 190 benign and malignant pediatric and
422 adolescent adnexal masses. *J Pediatr Adolesc Gynecol.* 2011 Oct;24(5):282–5.

- 423 32. Timmerman D, Van Calster B, Testa A, S et al. Predicting the risk of malignancy in
424 adnexal masses based on the Simple Rules from the International Ovarian Tumor
425 Analysis group. *Am J Obstet Gynecol*. 2016 Apr;214(4):424–37.
- 426 33. Stankovic ZB, Djukic MK, Savic D, et al. Pre-operative differentiation of pediatric
427 ovarian tumors: morphological scoring system and tumor markers. *J Pediatr Endocrinol*
428 *Metab JPEM*. 2006 Oct;19(10):1231–8.
- 429 34. Stankovic ZB, Bjelica A, Djukic MK, Savic D. Value of ultrasonographic detection of
430 normal ovarian tissue in the differential diagnosis of adnexal masses in pediatric
431 patients. *Ultrasound Obstet Gynecol Off J Int Soc Ultrasound Obstet Gynecol*. 2010
432 Jul;36(1):88–92.
- 433 35. Stanković ZB, Sedlecky K, Savić D, et al. Ovarian Preservation from Tumors and
434 Torsions in Girls: Prospective Diagnostic Study. *J Pediatr Adolesc Gynecol*. 2017
435 Jun;30(3):405–12.
- 436 36. Madenci AL, Levine B-S, Laufer MR, et al. Preoperative risk stratification of children
437 with ovarian tumors. *J Pediatr Surg*. 2016 Sep;51(9):1507–12.
- 438 37. Ruttenstock EM, Saxena AK, Schwinger W, et al. Pediatric ovarian tumors--dilemmas in
439 diagnosis and management. *Eur J Pediatr Surg Off J Austrian Assoc Pediatr Surg Al Z*
440 *Kinderchir*. 2010 Mar;20(2):116–20.
- 441 38. Pienkowski C, Kalfa N. [Presumed benign ovarian tumors of childhood and adolescent].
442 *J Gynecol Obstet Biol Reprod (Paris)*. 2013 Dec;42(8):833–41.

- 443 39. French College of Gynecologists and Obstetricians. [Recommendations for clinical
444 practice: Presumed benign ovarian tumors--short text]. *J Gynecol Obstet Biol Reprod*
445 (Paris). 2013 Dec;42(8):856–66.
- 446 40. Aziz D, Davis V, Allen L, Langer JC. Ovarian torsion in children: is oophorectomy
447 necessary? *J Pediatr Surg*. 2004 May;39(5):750–3.
- 448 41. Wong YS, Tam YH, Pang KKY, et al. Oophorectomy in children. Who and why: 13-
449 year experience in a single centre. *J Paediatr Child Health*. 2012 Jul;48(7):600–3.
- 450 42. Maneschi F, Marasá L, Incandela S, et al. Ovarian cortex surrounding benign neoplasms:
451 a histologic study. *Am J Obstet Gynecol*. 1993 Aug;169(2 Pt 1):388–93.
- 452 43. Bristow RE, Nugent AC, Zahurak ML, et al. Impact of surgeon specialty on ovarian-
453 conserving surgery in young females with an adnexal mass. *J Adolesc Health Off Publ*
454 *Soc Adolesc Med*. 2006 Sep;39(3):411–6.
- 455 44. Thomassin-Naggara I, Toussaint I, Perrot N, et al. Characterization of complex adnexal
456 masses: value of adding perfusion- and diffusion-weighted MR imaging to conventional
457 MR imaging. *Radiology*. 2011 Mar;258(3):793–803.
- 458 45. Heo SH, Kim JW, Shin SS, et al. Review of ovarian tumors in children and adolescents:
459 radiologic-pathologic correlation. *Radiogr Rev Publ Radiol Soc N Am Inc*. 2014
460 Dec;34(7):2039–55.
- 461 46. Péroux E, Franchi-Abella S, Sainte-Croix D, et al. Ovarian tumors in children and
462 adolescents: a series of 41 cases. *Diagn Interv Imaging*. 2015 Mar;96(3):273–82.

463

464

465

466

467

468

469

470

471

472

473

474

475

476

477 Table 1: Preoperative patient characteristics

478

479 Table 2: Pathologic findings of pediatric ovarian masses

480

481 Table 3: Predictive factors of malignancy and borderline tumors in the multivariate analysis

482 OR, odds ratio, CI, confidence interval

483

484 Table 4: Score predictive of malignancy

485

486 Figure 1: Flow chart

487

488 Figure 2: ROC curve of the score to predict malignancy

	Study population N = 81	Malignant tumor N = 13 (16%)	Benign tumor N = 68 (84%)	p-value
Age				
Age (y), mean ±SD	13.1 ±4.7	13.8 ±5.2	13 ±4.6	
Age (y), median (min-max)	15 (0-19)	15 (3-18)	15 (0-19)	0.40
0 to 8	15 (19%)	2 (15%)	13 (19%)	0.68
9 to 13	14 (17%)	1 (8%)	13 (19%)	
>13	52 (64%)	10 (77%)	42 (62%)	
Hormonal status				
- Pre-pubescent	30 (37%)	4 (31%)	26 (38%)	0.76
BMI				
- Mean ±SD	21.7 ±3.6	20.6 ±3.0	22.0 ±3.7	0.41
Symptoms				
Palpable mass	13 (16%)	4 (31%)	9 (13%)	} 0.01
Acute pain	49 (60%)	6 (46%)	43 (63%)	
Other	17 (21%)	1 (8%)	16 (24%)	
Early puberty	2 (2%)	2 (15%)	0	
Sonography size				
Size (mm), mean ±SD	99.1 ±70.9	166.1 ±70.3	86.3 ±63.9	
Size (mm), median (min-max)	70 (19-360)	170 (65-260)	66 (19-360)	0.0003
>100 mm	30 (37%)	10 (77%)	20 (29%)	0.003

Type of ovarian mass				
Multilocular	7 (9%)	2 (15%)	5 (7%)	} 0.002
Solid multilocular	10 (12%)	5 (38%)	5 (7%)	
Unilocular	36 (44%)	3 (23%)	33 (49%)	
Solid unilocular	27 (33%)	2 (15%)	25 (37%)	
Solid	1 (1%)	1 (8%)	0	
Sonography characteristic				
Solid	38 (47%)	8 (62%)	30 (44%)	0.25
SPP*	37 (50%)	4 (44%)	33 (51%)	1.00
Calcification	20 (25%)	2 (15%)	18 (27%)	0.79
Cystic	29 (40%)	3 (23%)	26 (44%)	0.16
Ascites	4 (5%)	2 (15%)	2 (3%)	0.16
Peritoneal implant	1 (1%)	1 (8%)	0	0.17
Tumor markers				
Positive marker	16 (24%)	7 (54%)	9 (17%)	0.009
CA 125	13 (16%)	6 (46%)	7 (10%)	0.005
CA 19-9	7 (9%)	3 (23%)	4 (6%)	0.038
ACE	2 (3%)	2 (15%)	0	0.027
Torsion	14 (17%)	0	14 (21%)	0.11

Table 1: Preoperative patient characteristics

Pathologic	Patients	%
<i>Benign</i>	68	84
Germ-cell tumor	42	
Mature teratoma	42	
Epithelial	24	
Serous cystadenoma	16	
Mucinous cystadenoma	8	
Sex-cord stromal tumor	1	
Sclerosing tumor	1	
Indeterminate tumor	2	
<i>Borderline</i>	7	9
Serous	3	
Mucinous	4	
<i>Malign</i>	6	7
Germ-cell tumor	2	
Dysgerminoma	1	
Immature teratoma	1	
Epithelial	1	
Mucinous cystadenocarcinoma	1	
Sex-cord stromal tumor	2	
Juvenile granulosa tumor	2	
Secondary	1	

Table 2: Pathologic findings of pediatric ovarian masses

N=72	Malignant & borderline (N=13)	Benign (N=59)	Multivariate OR (95% CI)
Size <65 mm	0	27 (46%)	1
65<size<130 mm	5 (38%)	25 (42%)	10.89 [0.57–210.0]
Size>130 mm	8 (62%)	7 (12%)	74.54 [3.58–999.99]
Unilocular cystic tumor	3 (23%)	26 (44%)	1
Other type of tumor	10 (77%)	33 (56%)	3.63 [0.74–17.84]

Table 3: Predictive factors of malignancy and borderline tumors in the multivariate analysis

OR, odds ratio, CI, confidence interval

Variable	Score	Predictive risk (95% CI)
Size of lesion (mm)		
<65	0	
65 – 130	25	
>130	41	
Unilocular cystic tumor		
Yes	0	
No	9	
Total score		
Low-risk group	0 - 25	1.3% [0.1–18.4]
Middle-risk group	26 - 40	26.2% [11.6-49]
High-risk group	>40	53.1% [29.1–75.8]

Table 4: Score predictive of malignancy

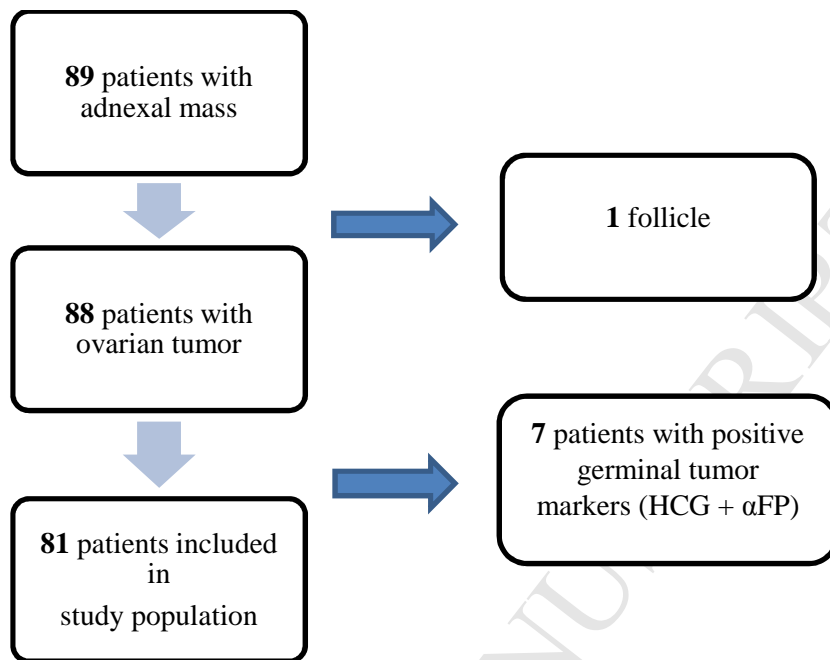
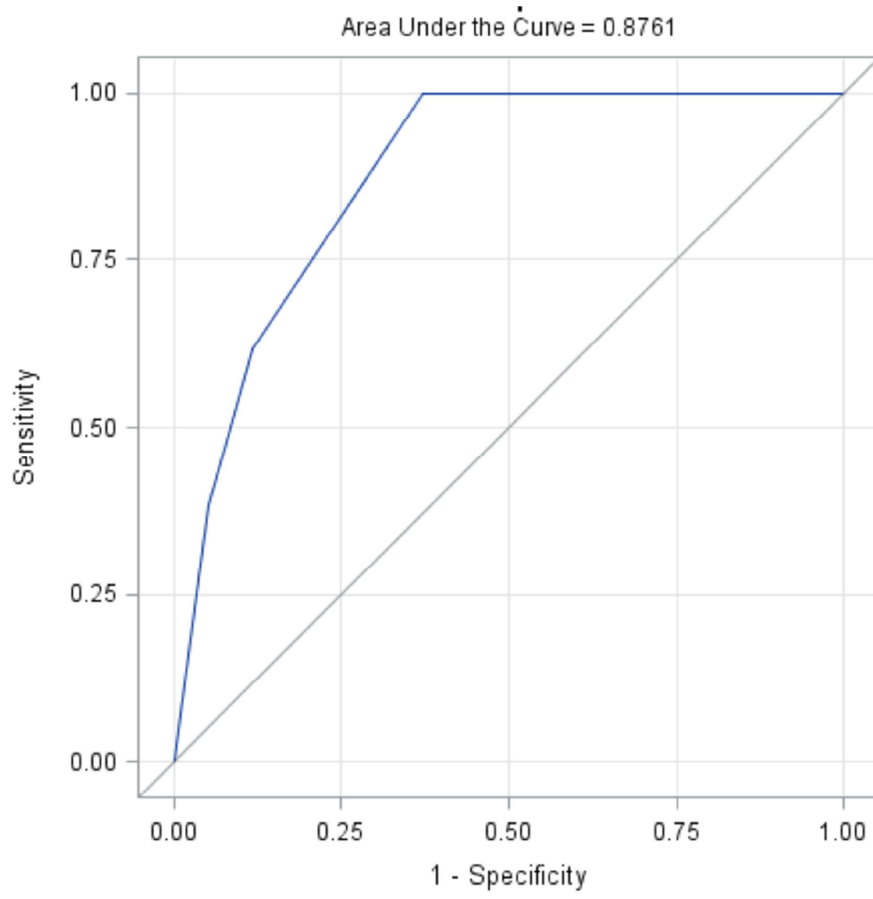


Figure 1: Flow chart



SCRIPT

ACCEPTED MANUSCRIPT