HAL
open science

The liver as an organ at risk for Toxoplasma transmission during transplantation myth or reality?

Brice Autier, Sarah Dion, Florence Robert-Gangneux

To cite this version:

Brice Autier, Sarah Dion, Florence Robert-Gangneux. The liver as an organ at risk for Toxoplasma transmission during transplantation myth or reality?. Journal of Clinical Pathology, 2018, 71 (9), pp.763-766. 10.1136/jclinpath-2018-205066 . hal-01874525

HAL Id: hal-01874525

https://univ-rennes.hal.science/hal-01874525

Submitted on 18 Sep 2018

HAL is a multi-disciplinary open access archive for the deposit and dissemination of scientific research documents, whether they are published or not. The documents may come from teaching and research institutions in France or abroad, or from public or private research centers.

L'archive ouverte pluridisciplinaire **HAL**, est destinée au dépôt et à la diffusion de documents scientifiques de niveau recherche, publiés ou non, émanant des établissements d'enseignement et de recherche français ou étrangers, des laboratoires publics ou privés.

The liver as an organ at risk for *Toxoplasma* transmission during transplantation: myth or reality?

Brice Autier[1], Sarah Dion[2], Florence Robert-Gangneux[1,2]

[1] Laboratoire de Parasitologie-Mycologie, Centre Hospitalier Universitaire de Rennes, France

[2] IRSET, Inserm U0185 ; [3] Université Rennes 1, Rennes, France

Corresponding author:

Prof Florence Robert-Gangneux

Laboratoire de Parasitologie-Mycologie, Centre Hospitalier Universitaire de Rennes

2 rue Henri Le Guilloux, F-35033 Rennes, France

Tel : +33 299 28 42 68

Fax : +33 299 28 41 21

e-mail. Florence.robert-gangneux@univ-rennes1.fr

2391 words

ABSTRACT

Aim Toxoplasmosis following liver transplant with donor-recipient mismatch is rare, but is often life-threatening. However, there is no data on the frequency of cyst carriage in the liver, nor consensual chemoprophylaxis guidelines. This study aimed at describing frequency and localization of *Toxoplasma* cysts in the liver in a mouse model of chronic infection, to predict the risk in liver transplantation.

Methods Heart, brain and liver lobes of twenty-one mice chronically infected with *Toxoplasma* were collected for DNA extraction and amplification of *T. gondii* rep529 sequence by real-time PCR.

Results Parasite DNA was detected in the liver of 19/21 mice (90.5%), with no preferential anatomical localization, but with higher parasite loads in the papillary process. Parasite loads in the liver were far lower than in brain and heart. The number of infected lobes was inversely correlated to the total liver weight, but was independent of the brain parasite load and of the parasite strain.

Conclusions The liver is a frequent site of cyst carriage, confirming that transplantation of an organ from a seropositive donor to seronegative recipient is at high risk for acquired toxoplasmosis. Systematic serological screening prior to transplantation and chemoprophylaxis in patients at risk are fully justified.

Keywords: *Toxoplasma*, liver, transplantation, infection

INTRODUCTION

Toxoplasma gondii is a worldwide spread *Apicomplexa*, which can infect a large diversity of warm-blooded animals. When infecting a new host, this intracellular parasite disseminates in the organism and then encysts in tissues, with a preferred localization in brain, muscles, myocardium and retina. As *Toxoplasma* can virtually invade all types of nucleated cells, these cysts can be found virtually in all organs. Cysts are structures containing hundreds of bradyzoites, quiescent forms with a slower metabolism. They persist lifelong in their host and are resistant to all current therapies.

Toxoplasmosis is usually benign for immunocompetent people, as it is most often asymptomatic. However, there are two conditions where disease can be severe, i.e. i) when primary infection is acquired during pregnancy, *T.gondii* can be responsible for congenital toxoplasmosis and ii) in case of immune cell deficiency, latent cysts may reactivate, in particular following Human Immunodeficiency Virus (HIV) infection or transplantation. In immunocompromised patients, reactivation infection often results in cerebral toxoplasmosis or disseminated toxoplasmosis and leads to death in the absence of treatment. *Toxoplasma* can be transmitted through organ transplantation, in case of donor-recipient mismatch (*Toxoplasma*-seropositive donor/*Toxoplasma*-seronegative recipient). This way of infection concerns essentially cardiac transplants, as cysts burden is known to be high in this tissue.[1] Organ-transmitted infection or reactivation infection can be prevented by chemoprophylaxis with cotrimoxazole. Infection through other types of transplants is also possible, although more rarely reported in the literature.[2]

Published cases of toxoplasmosis following liver transplantation are scarce. Indeed, 31 cases have been reported since 40 years and only about 10 were consecutive to a *Toxoplasma* mismatch.[2–11] Therefore, prophylaxis is irregularly prescribed after liver transplantation.[12] Even if this way of infection is unfrequently described, it is often life-threatening. Nevertheless, no data are available regarding the frequency of cyst carriage in the liver in patients with past immunity, nor regarding the precise hepatic localization.

This study approached these questions using a murine model in the aim to better characterize the *Toxoplasma*-associated risk in liver transplantation. In contrast to classical experimental models using standardized parasite inoculums of a given parasite strain, unlikely reflecting human contamination, we

used mice diagnosed with *Toxoplasma* infection in the framework of *in vivo* diagnosis of congenital toxoplasmosis. This *in vivo* assay has been routinely used in France since about 30 years. A few laboratories still use it together with quantitative PCR assays, mainly for epidemiological studies, although its sensitivity to detect viable parasites in placenta samples may have added value for the neonatal diagnosis of congenital toxoplasmosis.[13]

METHODS

Mice and organs

Four to six Swiss female mice (Janvier LABS, Saint-Berthevin, France) were inoculated intraperitoneally with previously digested placenta, as part of our routine diagnosis and epidemiological survey of congenital toxoplasmosis, as previously described.[13] Five to 6 weeks later, a blood sample was taken from the submandibular vein and *Toxoplasma* serology was performed using the Toxoscreen® assay (Biomérieux, Marcy L'Etoile, France) to screen infected animals. All seropositive mice were sacrificed. One brain was collected for each clinical sample to confirm the presence of cysts by microscopic examination and was sent to the National Reference Center for genotyping. Our animal facility follows the European regulations regarding animal experiments and this protocol was validated by the ethical committee and the Ministère de l'Enseignement Supérieur et de la Recherche (agreement no 2016121517337913).

For this study purpose, liver and heart were collected together with brain for 21 seropositive mice. Liver was perfused with 5 to 8 mL of Phosphate Buffered Saline (PBS) through the portal vein to flush all blood cells, then weighed, and lobes were separated following the anatomical structure presented in Figure 1. Lobes and heart specimens were weighed with precision scale and crushed in 3.6 mL (left lateral lobe) or 1.8 mL (other lobes and hearts) of Tris-EDTA buffer (50 mM Tris, 50 mM EDTA) and the entire volume was extracted as described in the following step. The entire brains were crushed in 2 mL of Tris-EDTA but only 900 µL were extracted. Samples not processed immediately were frozen at -80°C before DNA extraction.

Phenol-chloroform DNA extraction

DNA extraction was performed after a proteinase K pre-treatment consisting in overnight incubation with SDS (0.9%) and proteinase K (0.05 µM) at 56°C. After addition of phenol (V/V), samples were gently shaked during 10 min and centrifuged (10 min, 2500 *g*, room temperature). Supernatants were collected and a solution of phenol-chloroform-isoamyl alcohol (25/24/1) was added (V/V) to each sample before new gentle shaking and centrifugation. Supernatants were collected, added with chloroform-isoamyl alcohol (96/4) (V/V), shaked gently and centrifuged again. DNA present in aqueous phase was precipitated in 100% ethanol and sodium acetate 3 M, and DNA pellets were washed with 70% ethanol, then dried. Pellets were then dissolved in water in a final volume of 400 µL. Extracts were frozen at -80°C for later use.

Quantification of parasite loads by real-time PCR

Real-time PCR was performed in a final volume of 25 µL, using 5 µL of diluted DNA extracts (1/10 and 1/20), in an in-house TaqMan assay targeting the rep529 sequence and DNA-glycosylase anti-contamination system, as previously described.[13] Amplification consisted in 2 min at 50°C, initial denaturation 10 min at 95°C, then 45 cycles of 95°C for 15 sec and 60°C for 1 min. Each PCR reaction was validated by negative and positive controls. The positive control was obtained by dilution of DNA extract from a calibrated sample sent by the National Reference Center (NRC) for toxoplasmosis (Montpellier, France). The sample was a lyophilized amniotic fluid artificially infected with *T. gondii* tachyzoites (*RH* strain). Data were collected with StepOnePlus™ Software version 2.2.2. PCR results were expressed as cycle threshold (CT) of amplification.

Statistics

Qualitative data were analyzed using Chi-square test. Quantitative data were analyzed using Spearman *r* correlation test, Mann-Whitney test, or ANOVA and Tukey's Multiple Comparison tests. Calculations and graphs were realized with the GraphPad Prism version 5.03 software.

RESULTS

Twenty-one seropositive mice infected with placentas from 5 different mothers were analyzed. Three, one and one mothers acquired infection during the third, second, and first trimester of pregnancy, respectively. Brain specimens were missing for 4 mice (entirely sent to the NRC) and heart specimen was missing for 6 mice (not collected). The five *T. gondii* clinical isolates were genotyped and were all type II.

As expected, all heart and brain samples were positive for *T.gondii* with high parasite loads (Table 1). Surprisingly, 90.5% of livers were infected (19/21). No preferential localization was identified: the percentage of infected lobes for a given anatomical site, ranged from 33.3% to 47.6% (non-significant differences). For each type of lobe, there were no significant differences between the mean weight of infected and uninfected lobes (data not shown). Parasite loads of hepatic lobes (mean $C_T = 37.7 \pm 3.8$) were far lower than that of heart and brain specimens (30.1 ± 2.7 and 23.7 ± 1.2, respectively), even reported to the weight of each organ. However, the parasite load was higher in the papillary process than in the right median, the left lateral and the caudal lobes (p ranging from < 0.01 to < 0.05), but no differences were observed between other lobes (figure 2).

The mean number of positive lobes per mice was 2.5 ± 1.7. An inverse correlation between the number of positive lobes per mouse and the total liver weight ($p < 0.01$) was observed (Table 2), but no correlation was observed with the brain parasite load, nor with the delay between infection and sacrifice (ranging from 9 to 33 weeks). The number of positive lobes per mouse was not linked the clinical isolate (figure 3).

Table 1. Results of *Toxoplasma* DNA detection according to anatomical part

Anatomical part	Proportion of positive mice (n)	Weight (mg)	Organ parasite load (C_T)
Heart (N = 15)	100% (15)	158 ± 26	30.1 ± 2.7
Brain (N = 17)	100% (17)	472 ± 42	23.7 ± 1.2
Liver (N = 21)	90.5% (19)	1956 ± 450	
Left median lobe (LM)	42.9% (9)	189 ± 46	37.3 ± 3.5
Right median lobe (RM)	47.6% (10)	372 ± 95	39.9 ± 3.6
Papillary process (PP)	42.9% (9)	168 ± 54	34.0 ± 2.6
Left lateral lobe (LL)	47.6% (10)	707 ± 138	39.7 ± 2.7
Right lateral lobe (RL)	33.3% (7)	318 ± 98	35.6 ± 3.3
Caudal lobe (CL)	38.1% (8)	205 ± 57	38.7 ± 3.7

Table 2. Cerebral parasite loads and liver weight according to the number of infected lobes

No. of infected lobes per mouse	No. of mice	Total liver weight (mg)	Brain parasite load (C_T)
0	2	2289 ± 350	NA
1	5	2145 ± 587	24.0 ± 0.9
2	4	1878 ± 263	24.1 ± 1.2
3	4	1953 ± 464	23.8 ± 1.6
4	3	1831 ± 419	23.0 ± 1.7
5 - 6	3	1674 ± 337	23.4 ± 0.6

NA, not applicable

DISCUSSION

The aim of this study was to describe the prevalence of *Toxoplasma* cyst carriage in the liver during chronic toxoplasmosis and to search for a preferential localization of these cysts. We observed that the liver was a frequent target for *Toxoplasma* encystment, as DNA was detected in at least one hepatic lobe of 90% of mice (19/21). This observation confirms that liver transplantation from a seropositive donor to a seronegative recipient is at high risk for the recipient. Consequently, anti-*Toxoplasma* chemoprophylaxis should be systematically recommended after liver transplantation in case of donor-recipient mismatch, like for heart transplantation. It is likely that the small number of *Toxoplasma* infection consecutive to donor-recipient mismatch is rather due to the frequent chemoprophylaxis against *Pneumocystis jirovecii* (sulfamethoxazole-trimethoprim), than to a low infectivity of the liver. Parasite loads appeared to be much lower than in brain and heart, and was not correlated to the number of infected lobes. No lobe was predominantly infected in terms of frequency, but the papillary process had significantly higher parasite loads. These findings rule out the possibility to perform a systematic hepatic biopsy to detect *Toxoplasma* cysts before liver transplantation. The number of infected lobes in a liver could not be linked to the brain parasite load, which might reflect the initial parasitic inoculum. There was no difference according to the *Toxoplasma* isolate, suggesting that the intra-hepatic distribution is not strain-dependent. We also observed that the liver weight was inversely correlated to the number of positive lobes. This could be related to PCR inhibition by high DNA amount, also possibly explaining the higher parasite loads detected in the papillary process, which is the smallest lobe.

The liver has probably a central role in the pathophysiology of toxoplasmosis. In 2014, Dadimoghaddam *et al.* quantified parasite loads in various tissues of C57BL/6 mice after intraperitoneal inoculation of RH strain tachyzoites.[14] They observed high parasite loads in all tissues, particularly in the liver, which was the most rapidly infected organ. Twenty-four hours after infection, the hepatic parasite load was higher than in any other organ, including brain. Forty-eight and 72h later it decreased in the liver, while it was increasing in most other organs. In 2013, Unno *et al.* highlighted that mononuclear cells infected by tachyzoites rapidly accumulated in the liver of C57BL/6 mice.[15]

However, the frequency and the kinetics of parasite detection in tissues greatly depend on the model used: host species, route of infection, size of inoculum, time from infection to organ sampling, and *Toxoplasma* strain type. In a murine model using Swiss mice, the brain and the liver were the least infected organs after infection with RH strain and ME49 strain, respectively.[16] Also with the RH strain but using BALB/c mice, Wang *et al.* observed higher parasite loads in the liver than in the brain.[17] Juránková *et al.* quantified *Toxoplasma* in different tissues from artificially infected goats (ingestion of oocysts)[18] and showed that at 30 days post-infection (dpi) the liver was the least infected organ (50% of samples, with lowest parasite loads) but became one of the most infected ones at 90 dpi (100% of samples, fourth highest mean parasite load after lung, dorsal muscle and brain specimens). A study on pigs sacrificed at 76 dpi[19] showed 3/6 positive liver samples. Zöller *et al.* showed, on 30 turkeys sacrificed 6 to 12 weeks after intravenous injection of tachyzoïtes,[20] that liver and breast muscle were the most infected organs, with *Toxoplasma* DNA detection in 43.3% and 26.7% of samples, respectively. By contrast to the variability of these experimental models, here we provide a new insight into the natural prevalence of *Toxoplasma* cysts in the liver at distance from infection, using variable inoculum sizes and variable parasite strains, thus more likely reflecting the probable distribution of parasites in natural conditions. All strains were confirmed as genotype II by the NRC. This genotype is the far most frequently isolated in Europe and Northern America. Contrasting with previous works, we extracted DNA from the entire organ. Although this allows to avoid the bias induced by small biopsy, it is associated to a technical issue, i.e. the presence of PCR inhibitors due to the high amount of DNA. Therefore, all DNA extracts were diluted to 1:10 and 1:20 for amplification. Low parasite loads combined with PCR inhibitors make the detection of *T.gondii* in large animals a tricky task, as already underlined,[21] yet we could amplify parasite DNA in most organs. Recently, two studies showed that *Toxoplasma* induces modifications of the transcription and translation profile of hepatocytes during acute infection, modifying multiple cellular pathways.[22–24] These data are consistent with a major role of the liver during acute toxoplasmosis, like in other parasitic infections, in particular visceral leishmaniasis,[25 26] where the liver displays a peculiar immune response leading to parasite control. The specific hepatic micro-environment might also contribute to limit *Toxoplasma* replication, and could

explain the low density of *Toxoplasma* remaining cysts. Hence, our results are challenging the possibility to localize cysts by guided liver biopsy in humans to verify the frequency of cyst carriage.

In conclusion, together with the heart, the liver is also a frequent target organ for the chronic carriage of *Toxoplasma* cysts, thus liver recipients with *Toxoplasma*-mismatch transplantation should benefit from systematic chemoprophylaxis, which is not the rule in all countries. This preliminary study raises new questions: is this distribution of cysts similar in humans? Do *Toxoplasma* cysts have a long-term impact on the hepatic micro-environment and on the local response to infectious diseases or graft tolerance? Our observations open new perspectives of research to analyze the impact of long-term carriage of *Toxoplasma* cysts in the liver, even out of transplant context.

TAKE HOME MESSAGES

- Liver is a frequent site of cyst carriage in chronically infected mice, although with low density
- These findings justify systematic serologic screening of liver donors and recipients before transplantation, and chemoprophylaxis of seronegative recipients who would receive a liver from a seropositive donor, a practice not uniformly applied in Europe.

Contributors FRG and SD designed the study. FRG performed mouse dissection. BA, SD and FRG realized samples collection and storage. BA performed DNA extraction and real-time PCR. BA and FRG analyzed the results. BA, SD and FRG wrote the manuscript.

Competing interests The authors have no competing interests to declare.

Funding The Centre Hospitalier Universitaire de Rennes supports the animal facility for its routine use for toxoplasmosis diagnosis. Molecular analyses were funded by a grant of the European Society of Clinical Microbiology & Infectious Diseases, Study Group of Clinical Parasitology (ESGCP) (#P307-09).

Ethics approval Animal experiment was approved by the local Ethics Committee and the Ministère de l'Enseignement Supérieur et de la Recherche (agreement no 2016121517337913)

REFERENCES

1 Derouin F, Pelloux H, ESCMID Study Group on Clinical Parasitology. Prevention of toxoplasmosis in transplant patients. *Clin Microbiol Infect Off Publ Eur Soc Clin Microbiol Infect Dis* 2008;**14**:1089–101. doi:10.1111/j.1469-0691.2008.02091.x

2 Robert-Gangneux F, Dardé M-L. Epidemiology of and diagnostic strategies for toxoplasmosis. *Clin Microbiol Rev* 2012;**25**:264–96. doi:10.1128/CMR.05013-11

3 Assi MA, Rosenblatt JE, Marshall WF. Donor-transmitted toxoplasmosis in liver transplant recipients: a case report and literature review. *Transpl Infect Dis Off J Transplant Soc* 2007;**9**:132–6. doi:10.1111/j.1399-3062.2006.00187.x

4 Batista MV, Pierrotti LC, Abdala E, *et al.* Endemic and opportunistic infections in Brazilian solid organ transplant recipients. *Trop Med Int Health TM IH* 2011;**16**:1134–42. doi:10.1111/j.1365-3156.2011.02816.x

5 Campbell AL, Goldberg CL, Magid MS, *et al.* First case of toxoplasmosis following small bowel transplantation and systematic review of tissue-invasive toxoplasmosis following noncardiac solid organ transplantation. *Transplantation* 2006;**81**:408–17. doi:10.1097/01.tp.0000188183.49025.d5

6 Caner A, Döşkaya M, Karasu Z, *et al.* Incidence and diagnosis of active *Toxoplasma* infection among liver transplant recipients in Western Turkey. *Liver Transplant Off Publ Am Assoc Study Liver Dis Int Liver Transplant Soc* 2008;**14**:1526–32. doi:10.1002/lt.21558

7 Fernàndez-Sabé N, Cervera C, Fariñas MC, *et al.* Risk factors, clinical features, and outcomes of toxoplasmosis in solid-organ transplant recipients: a matched case-control study. *Clin Infect Dis Off Publ Infect Dis Soc Am* 2012;**54**:355–61. doi:10.1093/cid/cir806

8 Galván Ramírez ML, Castillo-de-León Y, Espinoza-Oliva M, *et al.* Acute infection of *Toxoplasma gondii* and cytomegalovirus reactivation in a pediatric patient receiving liver transplant. *Transpl Infect Dis Off J Transplant Soc* 2006;**8**:233–6. doi:10.1111/j.1399-3062.2006.00140.x

9 Miltgen G, Paillot J, Vanlemmens C, *et al.* Fatal acute respiratory distress by *Toxoplasma gondii* in a *Toxoplasma* seronegative liver transplant recipient. *New Microbiol* 2016;**39**:160–2.

10 Vaessen N, Verweij JJ, Spijkerman IJB, *et al.* Fatal disseminated toxoplasmosis after liver transplantation: improved and early diagnosis by PCR. *Neth J Med* 2007;**65**:222–3.

11 Webb GJ, Shah H, David MD, *et al.* Post-prophylaxis *Toxoplasma* chorioretinitis following donor-recipient mismatched liver transplantation. *Transpl Infect Dis Off J Transplant Soc* 2016;**18**:805–8. doi:10.1111/tid.12589

12 Robert-Gangneux F, Sterkers Y, Yera H, *et al.* Molecular diagnosis of toxoplasmosis in immunocompromised patients: a 3-year multicenter retrospective study. *J Clin Microbiol* 2015;**53**:1677–84. doi:10.1128/JCM.03282-14

13 Robert-Gangneux F, Dupretz P, Yvenou C, *et al.* Clinical relevance of placenta examination for the diagnosis of congenital toxoplasmosis. *Pediatr Infect Dis J* 2010;**29**:33–8. doi:10.1097/INF.0b013e3181b20ed1

14 Dadimoghaddam Y, Daryani A, Sharif M, *et al.* Tissue tropism and parasite burden of *Toxoplasma gondii* RH strain in experimentally infected mice. *Asian Pac J Trop Med* 2014;**7**:521–4. doi:10.1016/S1995-7645(14)60087-0

15 Unno A, Kachi S, Batanova TA, *et al. Toxoplasma gondii* tachyzoite-infected peripheral blood mononuclear cells are enriched in mouse lungs and liver. *Exp Parasitol* 2013;**134**:160–4. doi:10.1016/j.exppara.2013.03.006

16 Djurković-Djaković O, Djokić V, Vujanić M, *et al.* Kinetics of parasite burdens in blood and tissues during murine toxoplasmosis. *Exp Parasitol* 2012;**131**:372–6. doi:10.1016/j.exppara.2012.05.006

17 Wang H-L, Wen L-M, Pei Y-J, *et al.* Recombinant *Toxoplasma gondii* phosphoglycerate mutase 2 confers protective immunity against toxoplasmosis in BALB/c mice. *Parasite Paris Fr* 2016;**23**:12. doi:10.1051/parasite/2016012

18 Juránková J, Opsteegh M, Neumayerová H, *et al.* Quantification of *Toxoplasma gondii* in tissue samples of experimentally infected goats by magnetic capture and real-time PCR. *Vet Parasitol* 2013;**193**:95–9. doi:10.1016/j.vetpar.2012.11.016

19 Juránková J, Basso W, Neumayerová H, *et al.* Brain is the predilection site of *Toxoplasma gondii* in experimentally inoculated pigs as revealed by magnetic capture and real-time PCR. *Food Microbiol* 2014;**38**:167–70. doi:10.1016/j.fm.2013.08.011

20 Zöller B, Koethe M, Ludewig M, *et al.* Tissue tropism of *Toxoplasma gondii* in turkeys (Meleagris gallopavo) after parenteral infection. *Parasitol Res* 2013;**112**:1841–7. doi:10.1007/s00436-013-3337-z

21 Jauregui LH, Higgins J, Zarlenga D, *et al.* Development of a real-time PCR assay for detection of *Toxoplasma gondii* in pig and mouse tissues. *J Clin Microbiol* 2001;**39**:2065–71. doi:10.1128/JCM.39.6.2065-2071.2001

22 He J-J, Ma J, Elsheikha HM, *et al.* Proteomic profiling of mouse liver following acute *Toxoplasma gondii* infection. *PloS One* 2016;**11**:e0152022. doi:10.1371/journal.pone.0152022

23 He J-J, Ma J, Elsheikha HM, *et al.* Transcriptomic analysis of mouse liver reveals a potential hepato-enteric pathogenic mechanism in acute *Toxoplasma gondii* infection. *Parasit Vectors* 2016;**9**:427. doi:10.1186/s13071-016-1716-x

24 Sun H, Zhuo X, Zhao X, *et al.* The heat shock protein 90 of *Toxoplasma gondii* is essential for invasion of host cells and tachyzoite growth. *Parasite Paris Fr* 2017;**24**:22. doi:10.1051/parasite/2017023

25 Rodrigues V, Cordeiro-da-Silva A, Laforge M, *et al.* Regulation of immunity during visceral *Leishmania* infection. *Parasit Vectors* 2016;**9**:118. doi:10.1186/s13071-016-1412-x

26 Soulard V, Bosson-Vanga H, Lorthiois A, *et al. Plasmodium falciparum* full life cycle and *Plasmodium ovale* liver stages in humanized mice. *Nat Commun* 2015;**6**:7690. doi:10.1038/ncomms8690

FIGURE LEGENDS

Figure 1. Mouse liver anatomy

CL : caudal lobe ; G : gallbladder ; LL : left lateral lobe ; LM : left median lobe ; PP : papillary process; RL : right lateral lobe ; RM : right median lobe

Figure 2. Results of parasite detection according to hepatic lobes

Proportion of infected lobes was not significantly different among localizations, but parasite loads in PP were higher than in lobes RM, LL and CL. Grey bars represent the % of infected lobes for a given anatomical site (left y-axis). Scattered values represent each PCR result obtained with positive lobes of each anatomical category and refer to the right y-axis. Standard error types and significant comparisons between groups are indicated, *; $p<0.05$, **; $p<0.01$.

Figure 3. Distribution of the number of infected lobes per *Toxoplasma* isolate

Three to 6 mice (out of 6 inoculated with each placenta tissue) were diagnosed with *Toxoplasma* infection. The number of hepatic infected per clinical isolate is depicted on the graph.

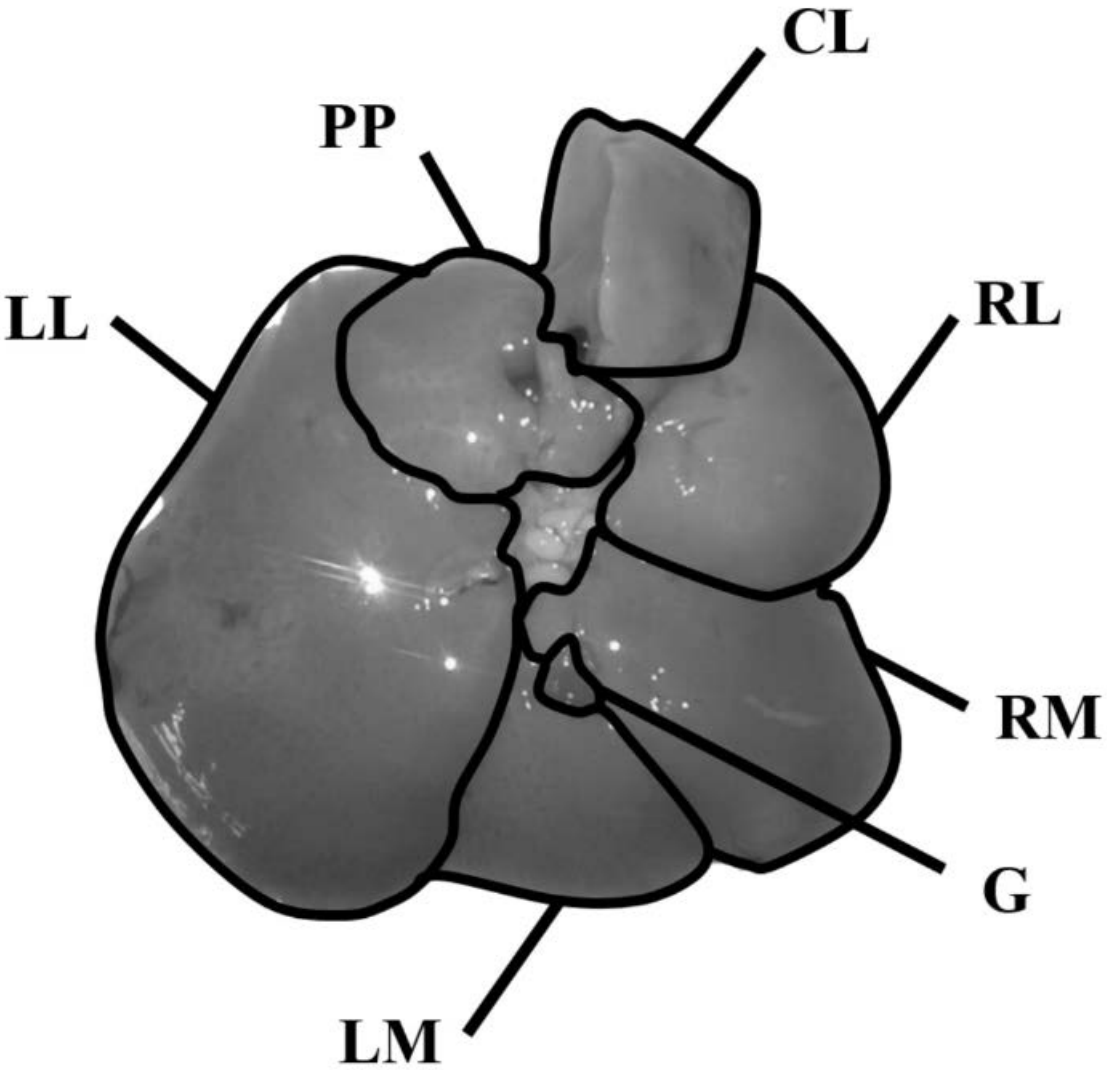

Figure 1 Mouse liver anatomy. CL, caudal lobe; G, gallbladder; LL, left lateral lobe; LM, left median lobe; PP, papillary process; RL, right lateral lobe; RM, right median lobe.

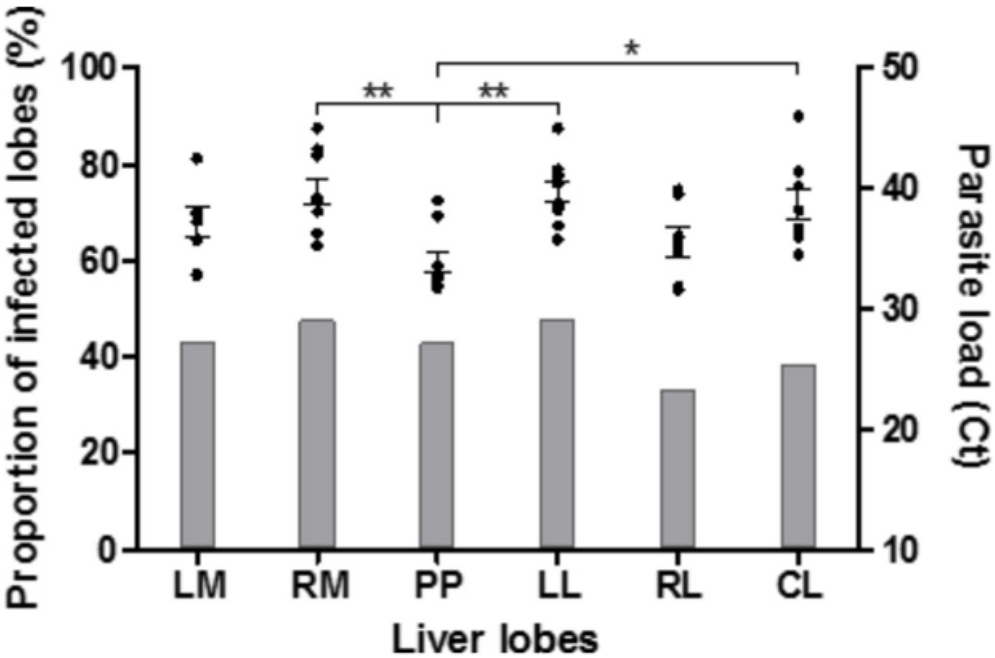

Figure 2 Results of parasite detection according to hepatic lobes. Proportion of infected lobes was not significantly different among localisations, but parasite loads in PP were higher than in lobes RM, LL and CL. Grey bars represent the % of infected lobes for a given anatomical site (left y-axis). Scattered values represent each PCR result obtained with positive lobes of each anatomical category and refer to the right y-axis. SE types and significant comparisons between groups are indicated, *$p<0.05$; **$p<0.01$. CL, caudal lobe; LL, left lateral lobe; LM, left median lobe; PP, papillary process; RL, right lateral lobe; RM, right median lobe.

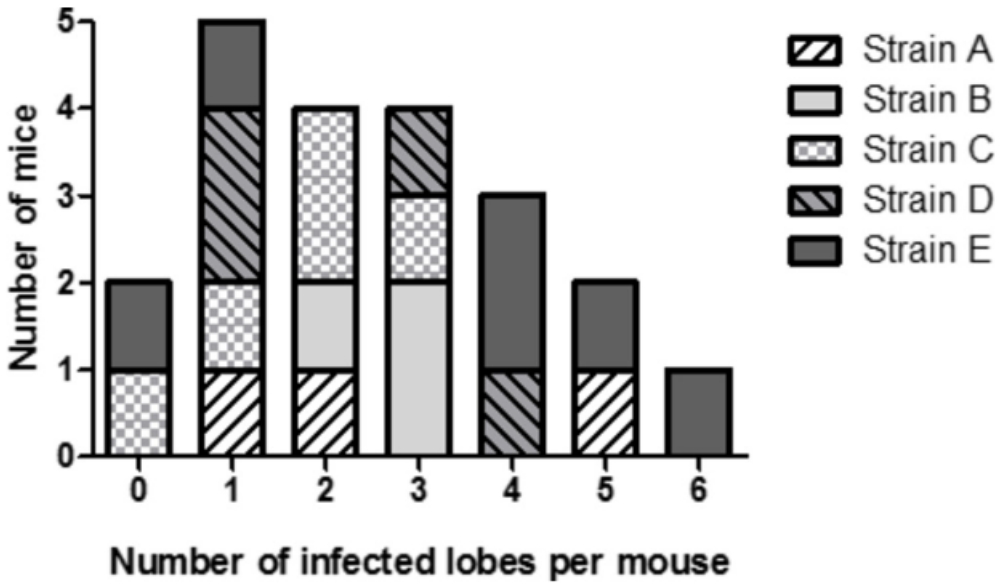

Figure 3 Distribution of the number of infected lobes per *Toxoplasma* isolate. Three to six mice (out of six inoculated with each placenta tissue) were diagnosed with *Toxoplasma* infection. The number of hepatic-infected per clinical isolate is depicted on the graph.