



Exercise Oximetry and Laser Speckle Contrast Imaging to Assess Microvascular Function in Lower Extremity Peripheral Artery Disease

D Lanéelle, O Stivalet, Guillaume Mahé, V Jaquinandi, L Omarjee

► To cite this version:

D Lanéelle, O Stivalet, Guillaume Mahé, V Jaquinandi, L Omarjee. Exercise Oximetry and Laser Speckle Contrast Imaging to Assess Microvascular Function in Lower Extremity Peripheral Artery Disease. Cardiovascular Drugs and Therapy, 2018, 32 (4), pp.405-407. 10.1007/s10557-018-6806-x . hal-01862283

HAL Id: hal-01862283

<https://univ-rennes.hal.science/hal-01862283>

Submitted on 3 Oct 2018

HAL is a multi-disciplinary open access archive for the deposit and dissemination of scientific research documents, whether they are published or not. The documents may come from teaching and research institutions in France or abroad, or from public or private research centers.

L'archive ouverte pluridisciplinaire **HAL**, est destinée au dépôt et à la diffusion de documents scientifiques de niveau recherche, publiés ou non, émanant des établissements d'enseignement et de recherche français ou étrangers, des laboratoires publics ou privés.

Title: Exercise oximetry and laser speckle contrast imaging to assess microvascular function in lower extremity peripheral artery disease.

A letter to the editor regarding the recently published paper in *Cardiovascular Drugs and Therapy* entitled: « Systematic review of methods used for the microvascular assessment of peripheral artery disease »

Authors

Lanéelle D.¹, Stivalet O.^{2,3}, Mahé G.^{2,3}, Jaquinandi V.^{2,3}, Omarjee L.^{2,3}

Affiliations

¹ CHU Caen Normandie, Unité de médecine vasculaire, 14033 Caen.

² INSERM, Centre d'investigation clinique, CIC 1414, F-35033 Rennes. France.

³ CHU Rennes, Unité de médecine vasculaire, Imagerie Coeur-Vaisseaux, F-35033 Rennes. FRANCE.

Corresponding author

Prof. Guillaume MAHE.

Pôle imagerie médicale et explorations fonctionnelles. Unité de médecine vasculaire. Hôpital Pontchaillou, 2 rue Henri Le Guilloux. Rennes, F-35033. France. Tel : +33 (0)2 9928 4321. Fax : +33 (0)2 9928 4364. E-mail : maheguillaume@yahoo.fr Twitter : @GMahe_

Dear Editor,

We read with interest the paper from Chen and Rosenson entitled “Systematic review of methods used for the microvascular assessment of peripheral artery disease.”[1] In this paper, the authors detail the different means to assess microvascular function in lower extremity peripheral artery disease (LEPAD). We agree with the authors that resting ankle brachial index (ABI) can be falsely normal (i.e ABI>0.90) in specific populations (renal insufficiency, diabetes, isolated internal iliac artery stenosis...) and thus other techniques should be used[2,3]. However, we would like to present two methods for microvascular assessment that are not discussed in this paper. The first one is Exercise Transcutaneous Oxygen pressure (Exercise-TcPO₂). The method that has been proposed in 2003 by Abraham and colleagues allows with the calculation of the Delta from Rest Oxygen Pressure (DROP) to detect arterial stenosis of the lower limbs[4]. In brief, in a controlled room temperature, PO₂ changes are assessed during exercise using five Clark electrodes that are placed on the chest, on each buttock, and each calf (Figure 1; Panels A1, A2 and A3). Then, patient has to walk on a treadmill (3.2km/h; 10%grade) up to his/her maximal pain. During the test, the O₂ pressure changes are recording on each site using the DROP that is calculated in real-time with a dedicated software. A DROP \leq -15 mmHg is the cut-off to detect arterial stenosis \geq 60%[5]. This method is of particular interest for patients who experience proximal claudication or in case of diabetes or incompressible arteries[3,6].

The second method is the laser speckle contrast imager that allows the assessment in real-time on the skin microcirculation[7]. This technique that has a lower spatial variability than laser Doppler flowmetry (LDF) has been used in patients with LEPAD and seems of interest especially in patients with a severe disease[8–10]. This is a noncontact technique that is very interesting in case of wounds when the LDF probe cannot be placed (stuck) on the skin. In

the Figure 1 (Panels B1, B2, B3), we present a recording with a laser speckle imager performed on a patient with an ischemia on the right toe.

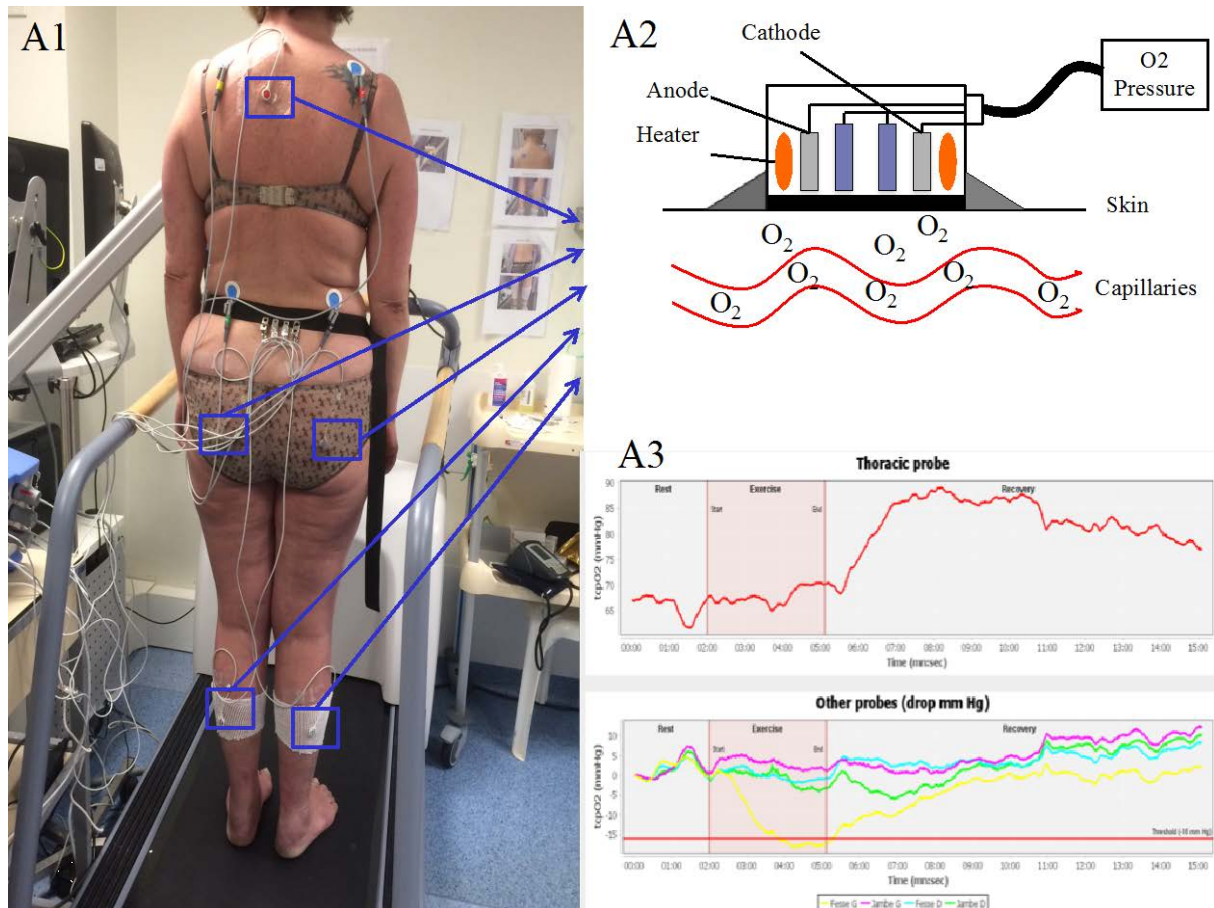
In conclusion, several techniques that measure microvascular flow might be of interest in patients with lower extremity peripheral artery disease. However, their role in the diagnosis algorithms should be clarified since they are not currently recommended in the international guidelines[2].

References

1. Chen Q, Rosenson RS. Systematic Review of Methods Used for the Microvascular Assessment of Peripheral Arterial Disease. *Cardiovasc Drugs Ther.* 2018;
2. Gerhard-Herman MD, Gornik HL, Barrett C, Barshes NR, Corriere MA, Drachman DE, et al. 2016 AHA/ACC Guideline on the Management of Patients With Lower Extremity Peripheral Artery Disease: A Report of the American College of Cardiology/American Heart Association Task Force on Clinical Practice Guidelines. *Circulation.* 2017;135:e726–79.
3. Mahé G, Kaladji A, Le Faucheur A, Jaquinandi V. Internal Iliac Artery Stenosis: Diagnosis and How to Manage it in 2015. *Front Cardiovasc Med.* 2015;2:33.
4. Abraham P, Picquet J, Vielle B, Sigaud-Roussel D, Paisant-Thouveny F, Enon B, et al. Transcutaneous oxygen pressure measurements on the buttocks during exercise to detect proximal arterial ischemia: comparison with arteriography. *Circulation.* 2003;107:1896–900.
5. Koch C, Chauve E, Chaudru S, Le Faucheur A, Jaquinandi V, Mahé G. Exercise transcutaneous oxygen pressure measurement has good sensitivity and specificity to detect lower extremity arterial stenosis assessed by computed tomography angiography. *Medicine (Baltimore).* 2016;95:e4522.

6. Mahe G, Kalra M, Abraham P, Liedl DA, Wennberg PW. Application of exercise transcutaneous oxygen pressure measurements for detection of proximal lower extremity arterial disease: a case report. *Vasc Med*. 2015;20:251–5.
7. Mahé G, Humeau-Heurtier A, Durand S, Leftheriotis G, Abraham P. Assessment of skin microvascular function and dysfunction with laser speckle contrast imaging. *Circ Cardiovasc Imaging*. 2012;5:155–63.
8. Katsui S, Inoue Y, Yamamoto Y, Igari K, Kudo T, Uetake H. In Patients with Severe Peripheral Arterial Disease, Revascularization-Induced Improvement in Lower Extremity Ischemia Can Be Detected by Laser Speckle Contrast Imaging of the Fluctuation in Blood Perfusion after Local Heating. *Ann Vasc Surg*. 2018;48:67–74.
9. Katsui S, Inoue Y, Igari K, Toyofuku T, Kudo T, Uetake H. Novel assessment tool based on laser speckle contrast imaging to diagnose severe ischemia in the lower limb for patients with peripheral arterial disease. *Lasers Surg Med*. 2017;49:645–51.
10. Puissant C, Abraham P, Durand S, Humeau-Heurtier A, Faure S, Lefthériotis G, et al. Reproducibility of non-invasive assessment of skin endothelial function using laser Doppler flowmetry and laser speckle contrast imaging. *PLoS ONE*. 2013;8:e61320.

Figure 1 title: Exercise oximetry (A) and Laser speckle imaging (B) in peripheral artery disease.



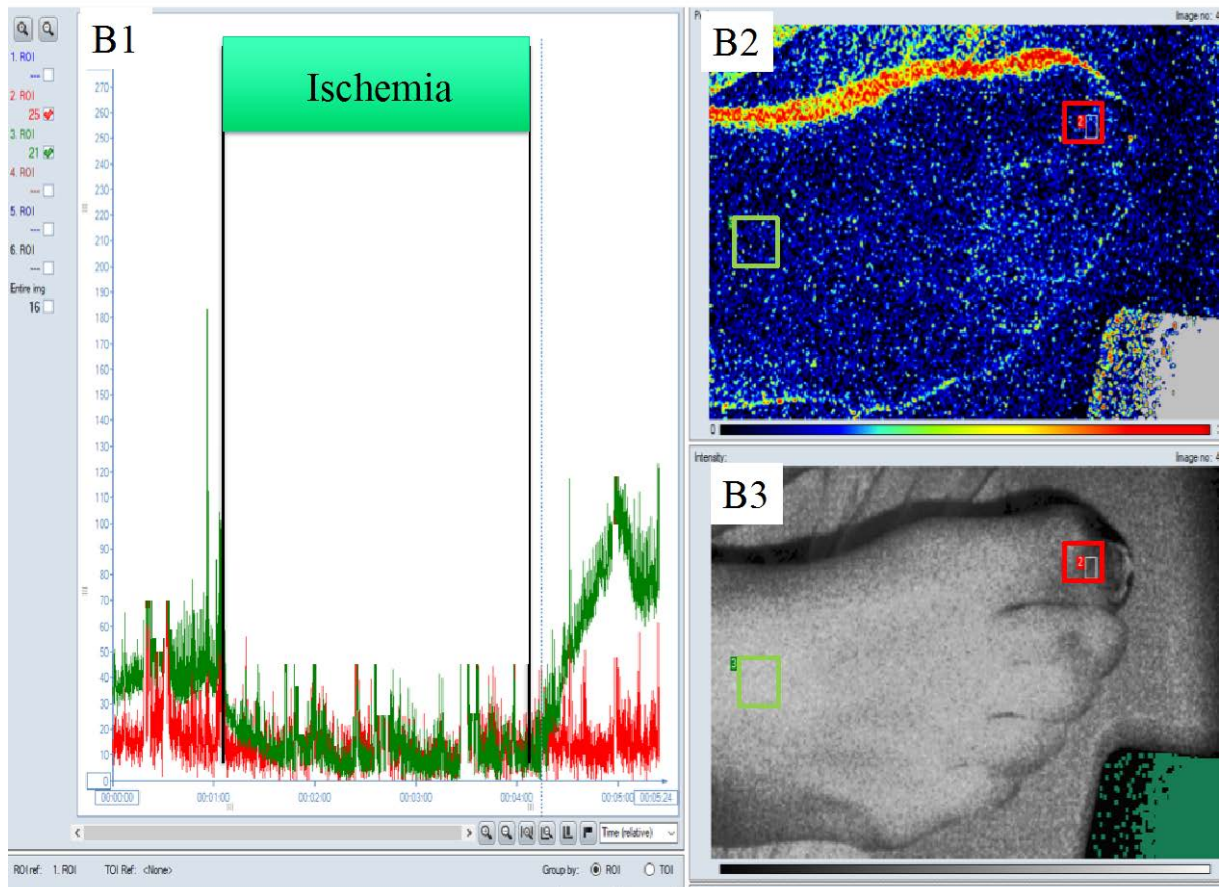


Figure 1 legend: Panel A1: procedure of exercise oximetry; Panel A2: Clark electrode; Panel A3: recordings of the DROP at each site during the test. Yellow line: DROP of the left buttock; Pink line: DROP of the left calf; Blue line: DROP of the right buttock; Green line: DROP of the right calf. In this case the patient had a left buttock ischemia ($\text{DROP} \leq -15$ mmHg). Panel B1: Changes of the microvascular flow during a reactive hyperaemia on the right foot of a patient with severe PAD. The reactive hyperaemia is recorded after the 3-min period of ischemia. The redline represents the microvascular flow recorded at the toe level. The green line represents the microvascular flow recorded on the top of the foot. Note that there is no increase of blood flow after the release of the inflated cuff at the toe whereas there is an increase of the blood flow at the top of the foot.