



The advantage of Flash radiotherapy confirmed in mini-pig and cat-cancer patients

Marie-Catherine Vozenin, Pauline de Fornel, Kristoffer Petersson, Vincent Favaudon, Maud Jaccard, Jean-François Germond, Benoit Jean-Marie Petit, Marco Burki, Gisèle Ferrand, David Patin, et al.

► To cite this version:

Marie-Catherine Vozenin, Pauline de Fornel, Kristoffer Petersson, Vincent Favaudon, Maud Jaccard, et al.. The advantage of Flash radiotherapy confirmed in mini-pig and cat-cancer patients. *Clinical Cancer Research*, 2019, 25 (1), pp.35-42. 10.1158/1078-0432.CCR-17-3375 . hal-01812514v2

HAL Id: hal-01812514

<https://univ-rennes.hal.science/hal-01812514v2>

Submitted on 6 Sep 2018

HAL is a multi-disciplinary open access archive for the deposit and dissemination of scientific research documents, whether they are published or not. The documents may come from teaching and research institutions in France or abroad, or from public or private research centers.

L'archive ouverte pluridisciplinaire **HAL**, est destinée au dépôt et à la diffusion de documents scientifiques de niveau recherche, publiés ou non, émanant des établissements d'enseignement et de recherche français ou étrangers, des laboratoires publics ou privés.

The advantage of FLASH radiotherapy confirmed in mini-pig and cat-cancer patients

Marie-Catherine Vozenin^{1&}, Pauline De Fornel^{2&}, Kristoffer Petersson^{1,3&}, Vincent Favaudon⁴, Maud Jaccard^{1,3}, Jean-François Germond³, Benoit Petit¹, Marco Burki⁵, Gisèle Ferrand⁶, David Patin³, Hanan Bouchaab¹, Mahmut Ozsahin¹, François Bochud³, Claude Bailat³, Patrick Devauchelle^{2*} and Jean Bourhis^{1, 6*}

¹Radio-Oncology Laboratory, Department of Radiation Oncology, Lausanne University Hospital, Lausanne, Switzerland.

²Micen-vet, Créteil, France.

³Institute of Radiation Physics (IRA), Lausanne University Hospital, Switzerland.

⁴Institut Curie, INSERM U1021/CNRS UMR3347, Université Paris-Sud, 91405 Orsay, France.

⁵Service de Chirurgie Expérimentale, Département de chirurgie et anesthésie, Lausanne University Hospital, Lausanne, Switzerland.

⁶UNIL, Lausanne, Switzerland.

&, * Equal contribution

Corresponding author: MC. Vozenin. Laboratoire de Radio-Oncologie, Centre Hospitalier Universitaire Vaudois, Bugnon 46, 1011 Lausanne, Switzerland.

Telephone:

E-Mail: marie-catherine.vozenin@chuv.ch

Total number of pages: 22

Total number of Tables: 2 + 2 sup

Total number of Figures: 2 + 1 sup

Running head: The advantage of FLASH radiotherapy

Keywords: FLASH-RT, normal tissue protection, differential effect, cat-patients, phase I trial

Word count: 3416 words

Abstract-

Background: Previous studies using FLASH radiotherapy (RT) in mice showed a marked increase of the differential effect between normal tissue and tumors. To stimulate clinical transfer, we evaluated whether this effect could also occur in higher mammals.

Methods: Pig skin was used to investigate a potential difference in toxicity between irradiation delivered at ultra-high dose rate called FLASH-RT and irradiation delivered at conventional dose rate called Conv-RT. A clinical-phase-I single-dose escalation trial (25-41 Gy) was performed in six cat-patients with locally-advanced T2/T3N0M0 squamous-cell-carcinoma of the nasal planum, to determine the maximal tolerated dose and progression-free survival of single-dose FLASH-RT.

Results: Using respectively depilation and fibroncrosis as acute and late endpoints, a protective effect of FLASH-RT was observed ($\geq 20\%$ dose-equivalent difference vs Conv-RT). Three cats experienced no acute toxicity, whereas three exhibited moderate/mild transient mucositis and all cats had depilation. With a median follow-up of 13.5 months, the progression free survival (PFS) at 16 months was 84%.

Conclusion: Our results confirmed the potential advantage of FLASH-RT and provide a strong rational for further evaluating FLASH-RT in human patients.

Introduction

Radiotherapy (RT) is an essential part of cancer treatment; more than half of cancer patients are treated with RT, mostly with curative potential. In the last decade, major advances in high precision treatment delivery and multimodal imaging allowed RT to be better tolerated with an increased proportion of patients living longer, free of tumour and with fewer side effects. Despite of these progresses, radiation resistance remains an unmet clinical need, since an important proportion of solid tumours can be resistant to conventional radiation therapy. For patients harbouring those tumours, a more effective radiotherapeutic strategy is needed. Radiation-induced side effects limit dose escalation and compromise quality of life, therefore a more powerful and better-tolerated radiation therapy remains a major need to improve the ratio tolerance / efficacy of radiotherapy. With the objective of fostering innovation in radiation therapy, we have been the first to propose a completely novel modality of irradiation, named FLASH radiotherapy (FLASH-RT), that markedly increases the differential effect between tumours and normal tissues and is able to destroy tumours, while better protecting normal tissues and preventing side effects in experimental models (1,2). We also developed accurate and traceable dosimetry methods to compare irradiation performed at dose rates ranging from conventional to FLASH (3,4). Then, we started to delineate the physical parameters required for FLASH-induced protection of normal tissue and defined the threshold dose rate required to start observing some protective effect at 30 Gy/s, whereas this protective effect was more pronounced above 100 Gy/s } (2).

FLASH-RT delivery uses irradiators with a high radiation output. We performed our studies using two experimental linear accelerators (linacs), specifically constructed to deliver pulsed electron beam irradiation at ultra-high dose rates (≥ 100 Gy/s), but also able to operate at conventional dose rates commonly used in radiotherapy (a few Gy/min) (5). Interestingly, the group of B. Loo at Stanford University recently published a procedure on how to modify a clinical linac into an irradiator capable of delivering FLASH-RT, with dose rates exceeding 200 Gy/s (6) and produced preliminary data showing gut protection in mice (7). This does stimulate the research possibilities on FLASH-RT, and will help to investigate the radiobiological advantage of increasing the RT dose rate. An additional potential interest of these ultra-high dose rates with treatment times generally shorter than 0.1 s, is the possibility to minimize treatment delivery uncertainties caused by intra-fraction motion.

Given both its potential radiobiological and delivery advantages, FLASH-RT could revolutionize the field of RT. In order to advance the clinical transfer of the modality, it was essential to evaluate whether the increased differential effect of FLASH-RT could also be observed in higher mammals. Consequently, we

compared the effect of FLASH-RT to radiotherapy at conventional dose rate (Conv-RT) on the skin of a mini-pig, which represents a well characterized radiobiological model, mimicking the reactions of human skin to RT and used high dose and single fraction as previously described (8-11). This experience confirmed our results obtained in mice, showing an important protective effect of FLASH-RT (at least 20% dose difference), compared to Conv-RT. These data prompted us to perform a clinical trial in domestic animals with spontaneous cancer. The model of locally advanced squamous-cell carcinoma (SCC) of the nasal planum of cats was selected since the tumors are generally treated with RT but with a relatively poor tumor control rate (12). Surgery is mostly restricted to early stage tumors (Tis and T1) because of the poor cosmetic and functional outcome in more advanced cases (13). Brachytherapy has been used with favorable results in Tis/T1 tumors (14,15), whereas fractionated orthovoltage irradiation has also been used for relatively superficial invasive tumors (16,17). Similarly, fractionated RT using electron (18,19) or proton beams (20) at conventional dose rates showed 1-year progression-free survival (PFS) rates ranging from 50-60% in locally-advanced cases. These treatments also induced substantial acute and late side effects, and required multiple fractions with multiple anesthesia. In contrast to these observations, in our study, an excellent normal tissue tolerance to the high single dose of FLASH-RT was found along with a high tumor control rate.

Materials and Methods

FLASH-RT linacs

Irradiation was performed using two prototype linacs of type Kinetron (4.5 MeV electrons) and Oriatron 6e (6 MeV electrons) (PMB-Alcen, Peynier, France) (5). These machines are able to produce electron beams at a mean dose rate ranging from a few Gy/min (i.e. similar to dose rates conventionally used for RT) to thousands of Gy/s (2). These wide ranges of dose rates are made possible by varying the linac gun-grid tension, the pulse-repetition frequency, pulse width, and the source-to-surface distance (SSD).

Response of pig skin to FLASH-RT

The study was approved by the Swiss “Ethics Committee for Animal Experimentation”, and performed within institutional guidelines. One female Göttingen mini-pig (43 kg) entered the study, and was housed at the animal research facilities of the University of Lausanne. Irradiation took place under general anesthesia. The irradiation was performed on the back of the pig using a graphite applicator, with a 26 mm diameter circular aperture, in direct contact with the skin. The doses at 12 mm (5), which ranged from 22-34 Gy, were delivered in two ways. Some doses were delivered with a conventional RT dose rate (≈ 5 Gy/min), each dose to a different skin patch (one side of back), and then the same doses were delivered to other skin patches (the other side of back) with FLASH-RT (≈ 300 Gy/s). In vivo dosimetry

was performed with film (Gafchromic™ EBT3) and alanine pellets (2,3) positioned on the skin surface in the center of the beams. A reconstruction of the dose distribution (Figure 1A) was performed using a CT-scan of the pig and dose calculation in XiO® (Elekta AB, Stockholm, Sweden) treatment planning system (TPS).

The skin response to irradiation was carefully monitored weekly through visual examination, with any toxicity scored (Table 1) and photographed for 48 weeks' time post-irradiation. At 36 weeks, skin biopsies were performed and analyzed by histology.

Cat patient population

From September 2015 to October 2016, six previously untreated cats (five male and one female) with histologically confirmed SCC of the nasal planum non eligible for surgery were enrolled in the FLASH-RT trial. Written consent was obtained from each cat's owner before inclusion in the trial. Pre-treatment evaluation included a complete physical examination, a complete blood and platelet count, serum chemistry profile, urine analysis, LDH, CT-scan and three-dimensional measurements of the primary tumor. All cat-patients were clinically staged according to the WHO scoring system (Table S1). Four patients had a stage T2 tumor and two had a stage T3 (Table S2) with no evidence of nodal (N0) or metastatic tumor spread (M0). Exclusion criteria included FELV/FIV serum positivity, treatment with corticoids, anti-Cox1/ Cox2 drugs, or an anesthesia contra-indication.

Cat-patient treatments

The cats were given a single fraction radiotherapy while under general anesthesia. The doses followed a dose escalation scheme, and were prescribed to the surface of the nose with a margin of about 0.5 cm around the gross tumor mass (Table 1). The treatments were planned (set-up, treatment angle, field size, and with/without bolus) for optimally achievable dose distribution using XiO® TPS. Graphite applicators with different rectangular apertures were used to limit the treatment field size (Table S2), and the cats were in direct contact with the applicator during treatment. In vivo dosimetry was performed using either thermoluminescent dosimeters (TLD-100) or alanine pellets (3), with dosimeters positioned on the cats' noses in the center of the beams.

Trial design

This study was designed as a phase I dose escalation trial of FLASH-RT. The first dose level was set at 25 Gy, which is a dose expected to be well tolerated according to the results observed following the pig skin irradiation (see "Results" section). The escalation criteria were as follows: the first cat-patient was included at the first dose level and if no dose limiting toxicity (DLT) was observed, the next cat patient would be included with an increased treatment dose. For safety purposes, a minimal interval of four

weeks between two dose levels was recommended as per protocol along with no evidence of DLT during this follow-up period.

Clinical Response and follow-up evaluations

The primary endpoint of this phase I study was to determine the maximal tolerated dose (MTD), which was defined as the highest dose level at which a cat-patient did not experience a DLT within the four weeks post-RT. Normal-tissue toxicity was assessed as the primary endpoint according to the VCOG-CTCAE v1.1 (21) implemented with the toxicity score (Table 1) used for the pig (22). A DLT was defined as any acute toxicity above or equal to A5 occurring in four weeks post-RT in the treatment field, including stomatitis, mucositis, dysphagia, skin ulceration, or any grade equal or above A6 toxicity outside the RT field. In the case of DLT, dedicated analgesia and intensive supportive care were planned.

The secondary endpoint encompasses the late normal tissue tolerance in the RT field and progression-free survival (PFS) at 12 months. The following criteria were used for evaluating the anti-tumor efficacy: macroscopic complete response (CR) was defined as the disappearance of all clinical evidence of tumor on physical examination; partial response represents more than 50% decrease of tumor volume on physical examination; stable disease represents a tumor volume change observed on physical examination between a 50% decrease and a 25% increase. In case of doubtful clinical examination, a CT-scan and/or biopsies were recommended whenever possible. The overall survival (OS) and metastatic dissemination were recorded by the veterinarian along with any acute or late toxicity. These endpoints were checked every day during the first 15 days post-RT, and at 21 and 28 days post-RT and then every 3 months post-RT. If applicable, any symptomatic medications used after RT was recorded.

Results

Reduced pig skin toxicity with FLASH-RT

The film and alanine pellet in vivo dosimetry verified the doses delivered to the pig skin surface (mean and maximum deviation of 0 and -3%, respectively). The reconstruction of the delivered dose distributions visualized the irradiated volumes (Figure 1A). Acute toxicity was macroscopically evaluated and found to be limited to depilation, which occurred three weeks later for the skin patches exposed to FLASH-RT and was transient (lasting only four weeks) for doses ≤ 31 Gy FLASH-RT (Table 1a and b). Hair follicles were preserved within the skin patches exposed to FLASH-RT, whereas in the skin patches exposed to Conv-RT, the hair follicles appeared to be permanently destroyed and no hair regrowth was observed >6 months (Figure S1). No other acute toxicity was observed (no erythema or moist desquamation). More interestingly, severe late skin fibroncrosis was observed only with Conv-RT and associated with skin contraction appeared 32 weeks post-treatment with 34 Gy and 36 weeks post-treatment with lower doses of 31 and 28 Gy (Table 1). Figure 1B shows macroscopic view of FLASH-RT and Conv-RT irradiated spots, 36 weeks post-RT. At this time point, histological analysis revealed that skin fibroncrosis in Conv-irradiated spots was associated with epithelial ulceration and hyperkeratosis located at the margin of the wound as well as inflammatory infiltration and severe dermal remodeling (Figure 1C). In contrast, none of the FLASH-irradiated spots showed skin alteration and histological analysis was comparable to the non-irradiated skin (Figure 1C); the cutaneous tissue remained soft and healthy during the 48 weeks of follow-up, whereas some depilation occurred 36 weeks post-treatment and remained stable. Sirius Red staining and quantification confirmed fibrotic remodeling in Conv-irradiated samples (Figure 1D). Quantification of hair follicle showed preservation of the follicles' number in biopsies taken from the FLASH-RT patches 36 weeks post-RT whereas they were destroyed in the biopsies taken from Conv-RT spots at the same time point (Figure 1D). Using the same biopsies, immunofluorescence staining revealed preservation of CD34+ cells defined as epidermal stem cell in the bulge of the hair follicle in FLASH-irradiated biopsies (Figure 1D). All fibroncrotic scabs fell off around 42 weeks post-treatment and retractile scars remained stable over the time of follow up (48 weeks).

These results are consistent with our previous observations performed in mice and confirm that FLASH-RT is a non-fibrosing radiotherapy compared to Conv-RT. Further, it shows a dose modifying factor of at least 20% for single-fraction treatment in favor of FLASH-RT for the protection of normal tissue and prevention of fibrosis development as endpoints.

Cat-patient trial – DLT and Maximal Tolerated Dose (MTD)

The TLD/alanine pellet in vivo dosimetry measured the absorbed doses delivered to the skin surface of the cats' noses. It showed a deviation between prescribed and measured doses of 6% for cat N°1 (measured dose higher) and cat N°4 (measured dose lower). For the remaining four cats the deviations were <1%. The deviations between prescribed and measured dose values were compatible with the uncertainty of our dose determination with TLD, which is 8% ($k=2$). As per protocol, cat N°1 received a single dose of 25 Gy with a 25x34 mm field size. Moderate and transient A4 acute mucosal/skin toxicity was scored, including stomatitis of the upper oral cavity (Table 2A). Since DLT (\geq A5 toxicity) was not reached, cat N°2 with a deeply infiltrating tumor was included but only a moderate dose escalation was used with a dose of 27 Gy and a field size 25x34 mm (Figures 2A and B). Cat N°2 displayed no detectable signs of “in-radiation field” acute toxicity (no mucositis and no skin erythema). Cat N°3 had a large ulcerative tumor, requiring a field size of 34 x 45 mm. A single dose of 28 Gy was applied, representing a moderate dose escalation. This cat (N°3) displayed no detectable signs of acute toxicity (no mucositis and no skin erythema). Cat N°4 had a bi-focal deeply ulcerative tumor, requiring a treatment field size of 18 x 26 mm. A dose escalation to 31 Gy was applied. This cat (N°4) displayed no detectable signs of acute toxicity (no mucositis and no skin erythema). Cat N°5 required an irradiation with the same field size (18 x 26 mm) and a dose escalation to 34 Gy was applied. This cat displayed transient grade A4 “in-radiation field” moist desquamation that healed. Lastly, a considerable dose escalation to 41 Gy (field size of 18 x 26 mm) was applied for cat N°6, who had a deeply infiltrating and ulcerative tumor. Cat N°6 developed a relatively strong “in radiation field” mucositis with an exsudative component that was scored A4. Complete healing of the mucosa was obtained 5 weeks after irradiation. Although A4 toxicity observed at 41 Gy was transient and manageable, i.e. not considered as a DLT, we did not continue to escalate the dose since CR was observed at all the lower dose levels. Regarding the other side effects observed during the acute phase, no smell and nutrition problems were observed for cats 2, 3, 4, 5, and 6. Due to a stomatitis, Cat N°1 had difficulties swallowing during weeks 2 to 4 after irradiation. For all the cats, depilation in the irradiation field was observed, starting about 3 weeks after FLASH-RT (Table 2).

With a median follow-up of 18 months, all the cats revealed permanent depilation that was restricted to the field of irradiation. No other permanent, late toxicity, or “outside-radiation field” side effect has been observed. All six cat patients had an excellent functional result, with no limitation of food uptake or smelling capability.

Antitumor efficacy and overall survival

All six cat-patients had tumor assessments performed at inclusion and during follow-up. CR was observed for all cats (100%) at 6 months (Table 2B). Cat N°3 exhibited a recurrence not confirmed by biopsy but with a clinical tumor progression leading to euthanasia at 8 months. At 16 months, cats N°1, 2, 4, 5 and 6

were disease free and cats N°1, 2, 4 were disease free at 18 months. For cat N°4, a biopsy was performed 21 months post-FLASH-RT, and showed a SCC corresponding to a local recurrence, the cat is still alive and was proposed for salvage surgery.

Discussion

The markedly better normal tissue tolerance to FLASH-RT as compared to Conv-RT has been a serendipitous observation, obtained a few years ago in mice exposed to electron-beam irradiation delivered at ultra-high dose rates. This enhanced tolerance of normal tissues appears at irradiation dose rates above 30-40 Gy/s, whereas on all the tumor models tested so far, FLASH-RT has been shown to be as effective for tumor control as Conv-RT (1) (Montay-Gruel and Vozenin, in preparation). The mechanisms underlying this effect are under investigation, and not yet fully elucidated but the observed increase of the differential effect between tumors and normal tissues appeared to be very promising, and might significantly enhance the RT therapeutic index.

To prepare the transfer of FLASH-RT in human patients, we tested to which extent the effect obtained with FLASH-RT in mice could be a cross-species observation reproducible in higher mammals. For this purpose, we used two well-characterized models: mini-pig and cat patients. Pig skin was chosen as a suitable model for various reasons: 1) it is known to be very close in structure to human skin (8); 2) it is a well-characterized radiobiological model (8-11); 3) the size of the pig enabled us to directly compare at the same time and same conditions response to FLASH-RT versus Conv-RT with several spots/dose levels; and 4) our 6-MeV electron-beam linac is appropriate for skin irradiation. The results obtained when using radiation-induced depilation as acute/delayed endpoint and skin fibrosis as late endpoint were very consistent with our previous observations in mice. Our results show that FLASH-RT minimize normal tissue damages at the skin level even when large high doses are applied. Using CD34 as a surrogate marker of the epidermal stem cells (23), our results suggest that FLASH-irradiated skin area retain the expression of CD34 supporting the idea that FLASH-RT has minimal impact on stem cell consistently with what was already reported for neural (2) and intestinal stem cells (7). We could estimate a dose protective factor of at least 20% in favor of FLASH-RT as 28 Gy administered with Conv-RT induced fibroncrosis whereas 34 Gy administered FLASH-RT only induced depilation.

In parallel, the effect of FLASH-RT was explored in cat-patients, allowing us to evaluate normal-tissue toxicity in the frame of a dose-escalation study. The cohort was too small to allow definitive conclusion for tumor control and, the anti-tumor effect of FLASH-RT was evaluated as a secondary endpoint. SCC of the nasal planum is an appropriate model for which surgery can be functionally devastating and for

which conventional RT is commonly used in clinical practice, albeit with relatively poor outcome and severe toxicity (16,17,24). An obvious interest of FLASH-RT is the possibility to use a single curative fraction whereas conventional RT requires relatively complex logistics with several fractions and multiple anesthesia that impair the cats' quality of life. The results obtained in our small cohort of T2/T3N0M0 cat-patients showed that a MTD was not reached even at 41 Gy single dose. In fact, no DLT was scored and normal tissues exhibited a very good tolerance when irradiated with such a high single dose (25 to 41 Gy). Indeed, three out of the six cats exhibited no acute/late side effects except depilation, and the three others had only mild/moderate and manageable acute mucositis/dermatitis and no late toxicity was seen. Interestingly, a durable tumor control was obtained in 5/6 cats at 16 months. Among the most advanced cases of this series, two cats (N°2 and N°3) had a T3 disease, and were treated with 27 Gy and 28 Gy, respectively. Two cats (N°3 and N°4) showed a recurrence suggesting that a dose above 31 Gy would be required for the control of such invasive and spread out tumors.

The good tumor response rate that was observed is in agreement with previous (15-17) and recent publications (24) that used accelerated fractionation (10 x 4.8 Gy). However, the main improvement due to FLASH-RT was the good tolerance profile offering a further opportunity for dose escalation to enhance tumor control probability. This observation needs to be extended in a larger cohort of cats but it is in contrast with all previously mentioned studies where frequent grade 2/3 (21) toxicity (> 30% of patients in (24)) was reported, along with PFS at one year of between 50-80% (16,24). A second superiority of FLASH-RT for the treatment of domestic animals is its very convenient single-dose administration.

In conclusion, single dose FLASH-RT shows promise as a new treatment option for cat patients with locally-advanced SCC of the nasal planum. Our results in pig and cats provide a strong rationale for further evaluating FLASH-RT in human patients.

Acknowledgments

We would like to thank Eric Pavillard for pig care-taking; Manuel Santos, Sandrine Zufferey Pidoux and Corinne Moratal from Institute of Radiation Physics (IRA) (Lausanne, Switzerland). The study was supported by the ISREC Foundation, thanks to a donation from the Biltema Foundation; by a grant from the Fond'Action (Lausanne); Lead agency grant FNS/ANR CR32I3L_156924 for medical physics and dosimetry parts and Institut Curie support for Cat patients irradiation.

References

1. Favaudon V, Caplier L, Monceau V, Pouzoulet F, Sayarath M, Fouillade C, *et al.* Ultrahigh dose-rate FLASH irradiation increases the differential response between normal and tumor tissue in mice. *Sci Transl Med* **2014**;6(245):245ra93 doi 10.1126/scitranslmed.3008973.
2. Montay-Gruel P, Petersson K, Jaccard M, Boivin G, Germond JF, Petit B, *et al.* Irradiation in a flash: Unique sparing of memory in mice after whole brain irradiation with dose rates above 100Gy/s. *Radiother Oncol* **2017** doi 10.1016/j.radonc.2017.05.003.
3. Jaccard M, Petersson K, Buchillier T, Germond JF, Duran MT, Vozenin MC, *et al.* High dose-per-pulse electron beam dosimetry: Usability and dose-rate independence of EBT3 Gafchromic films. *Med Phys* **2017**;44(2):725-35 doi 10.1002/mp.12066.
4. Petersson K, Jaccard M, Germond JF, Buchillier T, Bochud F, Bourhis J, *et al.* High dose-per-pulse electron beam dosimetry - A model to correct for the ion recombination in the Advanced Markus ionization chamber. *Med Phys* **2017**;44(3):1157-67 doi 10.1002/mp.12111.
5. Jaccard M, Duran MT, Petersson K, Germond JF, Liger P, Vozenin MC, *et al.* High dose-per-pulse electron beam dosimetry: Commissioning of the Oriatron eRT6 prototype linear accelerator for preclinical use. *Med Phys* **2018**;45(2):863-74 doi 10.1002/mp.12713.
6. Schuler E, Trovati S, King G, Lartey F, Rafat M, Villegas M, *et al.* Experimental Platform for Ultra-high Dose Rate FLASH Irradiation of Small Animals Using a Clinical Linear Accelerator. *Int J Radiat Oncol Biol Phys* **2017**;97(1):195-203 doi 10.1016/j.ijrobp.2016.09.018.
7. Loo BW, Jr., Schuler E, Lartey F, M., Rafat M, King GJ, Trovati S, *et al.* Delivery of Ultra-rapid Flash radiation Therapy and demonstration of Normal tissue sparing after abdominal irradiation of mice. *Int J Radiation Oncology Biology Physics* **2017**;98(2 sup):E16.
8. Hopewell JW, van den Aardweg GJ. Current concepts of dose fractionation in radiotherapy. Normal tissue tolerance. *Br J Radiol Suppl* **1988**;22:88-94.
9. Lefaix JL, Martin M, Tricaud Y, Daburon F. Muscular fibrosis induced after pig skin irradiation with single doses of ¹⁹²Ir gamma-rays. *Br J Radiol* **1993**;66(786):537-44.
10. Lefaix JL, Mignot J. Effects of radiation on skin surface contour: A study of immediate effects in pig skin. *Skin Res Technol* **1996**;2(4):177-81 doi 10.1111/j.1600-0846.1996.tb00147.x.
11. Lefaix JL, Daburon F. Diagnosis of acute localized irradiation lesions: review of the French experimental experience. *Health Phys* **1998**;75(4):375-84.
12. Murphy S. Doing our best for cats with cancer. *J Feline Med Surg* **2013**;15(5):363 doi 10.1177/1098612X13483234.

13. Lana SE, Ogilvie GK, Withrow SJ, Straw RC, Rogers KS. Feline cutaneous squamous cell carcinoma of the nasal planum and the pinnae: 61 cases. *J Am Anim Hosp Assoc* **1997**;33(4):329-32 doi 10.5326/15473317-33-4-329.
14. Goodfellow M, Hayes A, Murphy S, Brearley M. A retrospective study of (90)Strontium plesiotherapy for feline squamous cell carcinoma of the nasal planum. *J Feline Med Surg* **2006**;8(3):169-76 doi 10.1016/j.jfms.2005.12.003.
15. Hammond GM, Gordon IK, Theon AP, Kent MS. Evaluation of strontium Sr 90 for the treatment of superficial squamous cell carcinoma of the nasal planum in cats: 49 cases (1990-2006). *J Am Vet Med Assoc* **2007**;231(5):736-41 doi 10.2460/javma.231.5.736.
16. de Vos JP, Burm AG, Focker BP. Results from the treatment of advanced stage squamous cell carcinoma of the nasal planum in cats, using a combination of intralesional carboplatin and superficial radiotherapy: a pilot study. *Vet Comp Oncol* **2004**;2(2):75-81 doi 10.1111/j.1476-5810.2004.00040.x.
17. Theon AP, Madewell BR, Shearn VI, Moulton JE. Prognostic factors associated with radiotherapy of squamous cell carcinoma of the nasal plane in cats. *J Am Vet Med Assoc* **1995**;206(7):991-6.
18. Melzer K, Guscetti F, Rohrer Bley C, Sumova A, Roos M, Kaser-Hotz B. Ki67 reactivity in nasal and periocular squamous cell carcinomas in cats treated with electron beam radiation therapy. *J Vet Intern Med* **2006**;20(3):676-81.
19. Cunha SC, Carvalho LA, Canary PC, Reisner M, Corgozinho KB, Souza HJ, *et al.* Radiation therapy for feline cutaneous squamous cell carcinoma using a hypofractionated protocol. *J Feline Med Surg* **2010**;12(4):306-13 doi 10.1016/j.jfms.2009.10.005.
20. Fidel JL, Egger E, Blattmann H, Oberhansli F, Kaser-Hotz B. Proton irradiation of feline nasal planum squamous cell carcinomas using an accelerated protocol. *Vet Radiol Ultrasound* **2001**;42(6):569-75.
21. Veterinary cooperative oncology group - common terminology criteria for adverse events (VCOG-CTCAE) following chemotherapy or biological antineoplastic therapy in dogs and cats v1.1. *Vet Comp Oncol* **2011** doi 10.1111/j.1476-5829.2011.00283.x.
22. Daburon F. Irradiation aigues localisées: Base radiobiologiques du diagnostic et du traitement. EDP sciences
1997.
23. Blanpain C, Fuchs E. Epidermal stem cells of the skin. *Annu Rev Cell Dev Biol* **2006**;22:339-73 doi 10.1146/annurev.cellbio.22.010305.104357.
24. Gasymova E, Meier V, Guscetti F, Cancedda S, Roos M, Rohrer Bley C. Retrospective clinical study on outcome in cats with nasal planum squamous cell carcinoma treated with an accelerated radiation protocol. *BMC Vet Res* **2017**;13(1):86 doi 10.1186/s12917-017-1018-3.

2 Tables

Table 1a: Skin toxicity scoring (from (22)).

Acute/subacute toxicity	Description	Late toxicity	Description
A0	Depilation	L0	Depilation
A1	Erythema	L1	Atrophy
A2	Pigmentation	L2	Flaky appearance
A3	Dry desquamation	L3	Pigmentation
A4	Moist desquamation that heals	L4	Fibrosis
A5	Moist desquamation that partially heals	L5	Telangiectasia
A6	Moist desquamation that does not heal	L6	Necrosis

Table 1b: Pig skin toxicity follow-up- w=week; - =no alteration of the skin; R=regrowth of hair, N/A=results are not yet available. Dashed line indicates the time of biopsy (at 36w).

RT	Dose (Gy)	7w	10w	14w	20w	24w	32w	36w	42w	48w
Conv	22	L0	L0	L0	L0	R	R	N/A	N/A	N/A
Conv	25	L0	L0	L0	L0	L0	L0	N/A	N/A	N/A
Conv	28	L0	L0	L0	L0	L0	L0+L4	L0+L4+L6	L0+L4	L0+L4
Conv	31	L0	L0	L0	L0	L0	L0+L4	L0+L4+L6	L0+L4	L0+L4
Conv	34	L0	L0	L0	L0	L0	L0+L1+L4	L0+L4+L6	L0+L4	L0+L4
FLASH	22	-	L0	R	R	R	R	N/A	N/A	N/A
FLASH	25	-	L0	R	R	R	R	N/A	N/A	N/A
FLASH	28	-	L0	R	R	R	R	L0	L0	L0
FLASH	31	-	L0	R	R	R	R	L0	L0	L0
FLASH	34	-	L0	L0	L0	L0	L0	L0	L0	L0

Table 2: Follow up of cats

A- Adverse events defined by dermatologic/skin scoring system; A=acute toxicity; L=late toxicity; -: no toxicity; N/A: not available cat n°3 is dead.

Cat n°	Dose (Gy)	Acute toxicity <10 days	Acute toxicity <20 days	Late toxicity 3 months-6 months	Late toxicity 6 months-12 months	Late toxicity >12 months
1	25	A1+A4	A1+A4	L0	L0	L0
2	27	-	-	L0	L0	L0
3	28	-	-	L0	L0	N/A
4	31	-	-	L0	L0	L0
5	34	-	A4	L0	L0	L0
6	41	A1+A4	A1+A4	L0	L0	L0

B- Tumor response (CR = macroscopic complete response).

Cat n°	Dose (Gy)	Response at 3 months	Response at 6 months	Response at 16 months
1	25	CR	CR	CR
2	27	CR	CR	CR
3	28	CR	Clinical recurrence Euthanasia at 8 mo	dead
4	31	CR	CR	CR
5	34	CR	CR	CR
6	41	CR	CR	CR

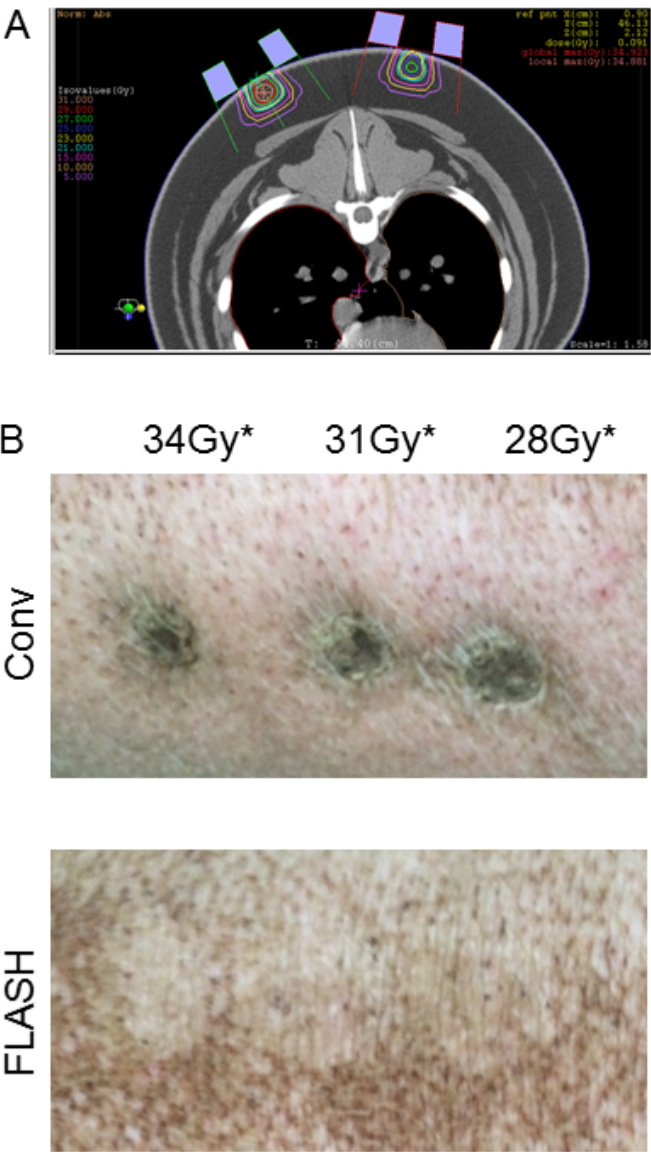
2 Figures

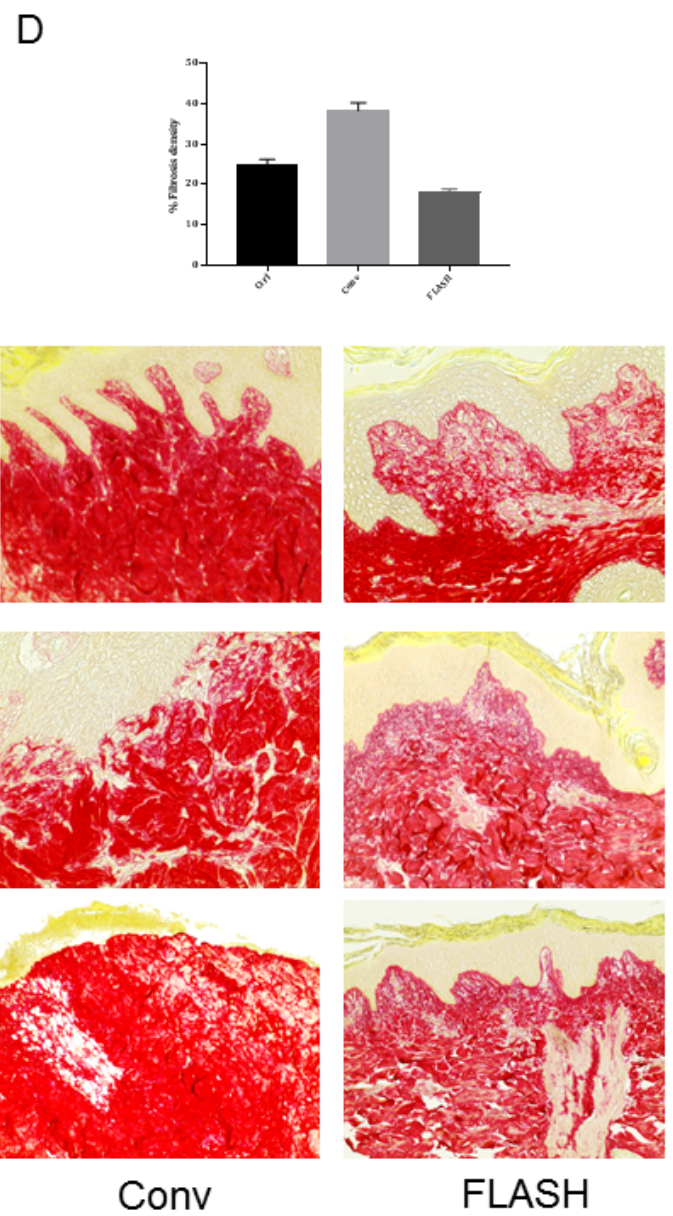
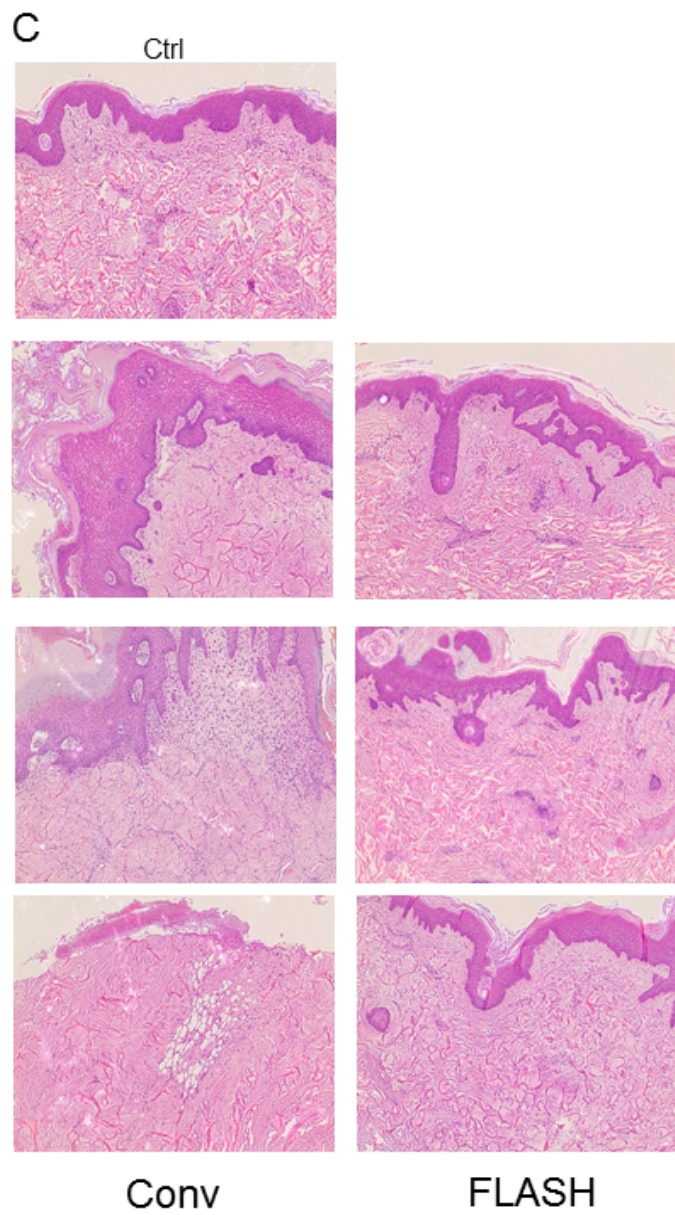
Figure 1: **A-** Dose distributions calculated in XiO[®] for the mini-pig irradiation, a transversal slice reconstructed from the CT-scan showed beam apertures and dose distributions. **B-** 36 weeks post-RT, macroscopic visualization showed severe fibronectin lesions in Conv-irradiated spots and the normal appearance of the skin in FLASH-irradiated spots (* maximal dose at 12mm)(5). **C-** HE staining sections cut from 6 mm punch biopsies sampled in irradiated spots 36 weeks post-RT, magnification X40. **Ctrl**=Normal pig skin sampled in non-irradiated area. **Conv**= Punch biopsies taken from Conv-irradiated spots show necrotic area, hyperkeratosis and dermis remodeling. **FLASH**=Punch biopsies taken from FLASH-irradiated spots show normal histology with stratified epidermis, papillary dermis and intact skin appendages. **D-** Sirius Red staining of sections cut from 6mm punch biopsies sampled in irradiated spots 36 weeks post-RT, magnification X40 and densitometric analysis. Enhanced collagen deposition in Conv-RT biopsies as compared with FLASH-RT and control is measured. **E-** 36 weeks post-RT, quantification of hair follicles per tissue sections has been performed on sections cut from 6 mm punch biopsies taken from non-irradiated, Conv-RT and FLASH-RT patches (data are presented as number of hair follicle per tissue sections+SE). **F-** CD34+ cells were detected by immunofluorescence (green intracellular staining) in the preserved hair follicles of FLASH-RT skin, a representative picture taken from 34 Gy FLASH-RT spot is shown.

Figure 2:

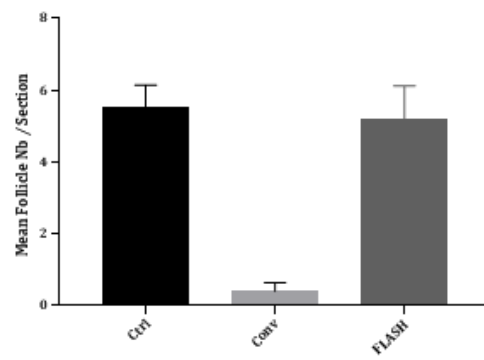
A- Picture of cat N°2 at diagnosis. **B-** Histological diagnosis of SCC (magnification X40). **C-** Dose distributions calculated in XiO[®] for the treatment of cat N°2, with a transversal slice (left) a reconstructed sagittal slice from the CT, a coronal slice and a 3D view showing the beam apertures, dose distributions and applicator position directed towards the tumor. **D-** Macroscopic evolution of the lesion in Cat N°2 over time

Figure 1





E



F

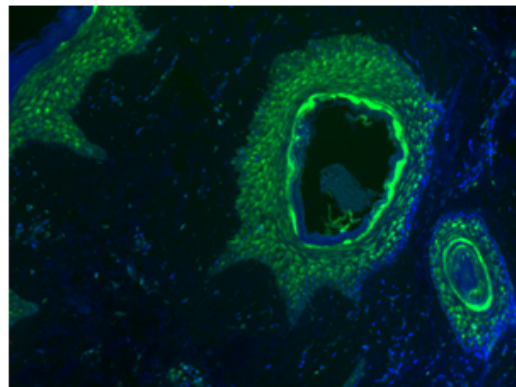
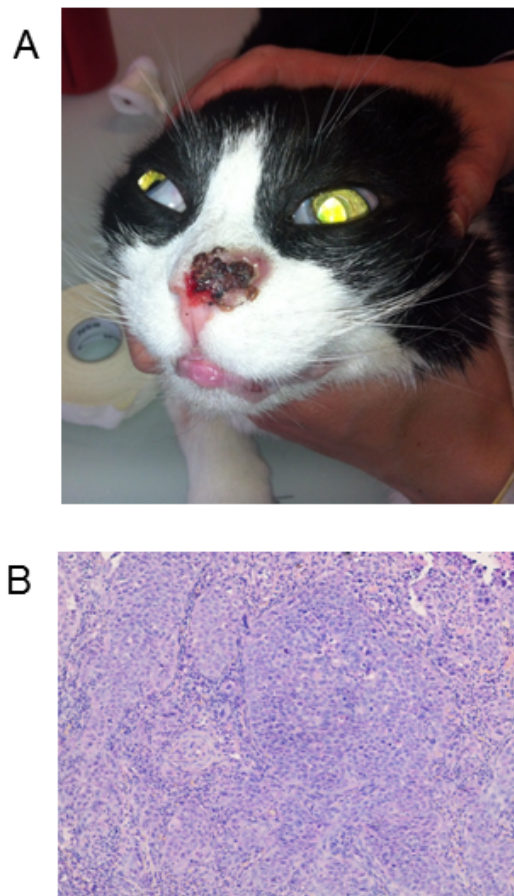


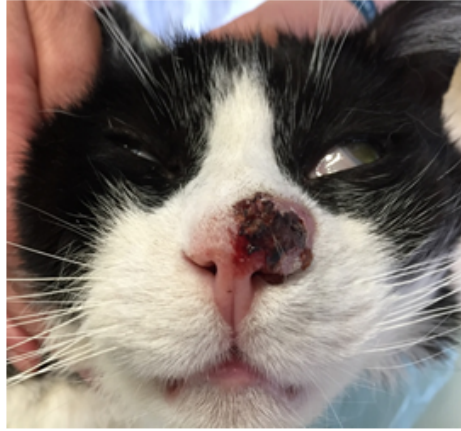
Figure 2



C



D



Before RT



7 months post-FLASH



14 months post-FLASH