



HAL
open science

Cardiac electronic implantable devices after tricuspid valve surgery

Raphaël P Martins, Vincent Galand, Christophe Leclercq, Jean-Claude Daubert

► **To cite this version:**

Raphaël P Martins, Vincent Galand, Christophe Leclercq, Jean-Claude Daubert. Cardiac electronic implantable devices after tricuspid valve surgery. *Heart Rhythm*, 2018, 15 (7), pp.1081-1088. 10.1016/j.hrthm.2018.01.015 . hal-01812224

HAL Id: hal-01812224

<https://hal-univ-rennes1.archives-ouvertes.fr/hal-01812224>

Submitted on 20 Sep 2018

HAL is a multi-disciplinary open access archive for the deposit and dissemination of scientific research documents, whether they are published or not. The documents may come from teaching and research institutions in France or abroad, or from public or private research centers.

L'archive ouverte pluridisciplinaire **HAL**, est destinée au dépôt et à la diffusion de documents scientifiques de niveau recherche, publiés ou non, émanant des établissements d'enseignement et de recherche français ou étrangers, des laboratoires publics ou privés.

1 **Cardiac electronic implantable devices after**
2 **tricuspid valve surgery**

3

4

5 **Authors:**

6 Raphaël P. Martins, MD, PhD^{1,2,3} Vincent Galand, MD,^{1,2,3} Christophe Leclercq, MD, PhD,
7 ^{1,2,3} Jean-Claude Daubert, MD,^{1,2,3}

8

9 **Working group address:**

10 1 CHU Rennes, Service de Cardiologie et Maladies Vasculaires, Rennes, F-35000, France

11 2 Université de Rennes 1, CIC-IT 1414, F-35000, France

12 3 INSERM, U1099, Rennes, F-35000, France

13

14 **Corresponding author:**

15 Raphaël P. Martins, Service de Cardiologie et Maladies Vasculaires, CHU de Rennes, 2 rue
16 Henri Le Guilloux, 35000 Rennes, France. Tel: + 33 299 282 507, Fax: +33 299 282 529,
17 email : raphael.martins@chu-rennes.fr

18

19 **Short title:** Device implantation after tricuspid valve surgery

20 **Word counts:** 5508

21 **Type:** Contemporary Review

22 **Conflicts of interests:** None.

23

24 **Abstract**

25 The demand for tricuspid valve (TV) surgery has increased continuously these last years.
26 Recent registry data have confirmed that TV repair or replacement carry an increased risk of
27 conduction disorders requiring permanent pacemaker implantation, specifically for patients
28 having multivalve surgery. The implantation of an endocardial right ventricular lead in those
29 patients may impair TV function, and some other approaches may be discussed to avoid
30 traversing the valve. This contemporary review describes the different options currently
31 available for patients requiring pacemaker or defibrillation leads implantation after TV
32 surgery.

33

34 **Keywords**

35 Tricuspid valve; Implantation; Pacemaker; Implantable Cardioverter-Defibrillator; Surgery

36 **INTRODUCTION**

37 Following the evolution of clinical indications,^{1, 2} the demand for surgery of the tricuspid
38 valve (TV) has increased continuously. In the United States, the annual number of TV
39 surgical procedures almost tripled between 2000 and 2010, the majority combined with left-
40 sided valve surgery.³ Treatment options include TV repair and TV replacement with a
41 bioprosthesis or a mechanical valve when repair is not feasible¹. Recent registry data have
42 confirmed that TV surgery carries an increased risk of conduction disorders leading to
43 permanent pacemaker implantation.^{4, 5} The risk is doubled among patients undergoing
44 multivalve surgery. The implantation of cardiac implantable electronic devices, mostly
45 pacemakers after TV surgery involves technical difficulties which must be known to the
46 implanters in order to select the best technical option in the individual patient. Several
47 approaches have been reported: epicardial leads, standard endocardial leads, his-bundle
48 pacing, leadless pacing, or coronary sinus leads. This paper reviews the current trends in
49 tricuspid valve surgery, the need for permanent pacing after surgery including clinical
50 indication and timing, and the technical options for device implantation, discussing the
51 advantages and disadvantages of each technique. Practical recommendations are provided.

52

53 **TRICUSPID VALVE SURGERY: CURRENT TRENDS**

54 Based on expert opinion (Level of evidence: C), the 2017 ESC¹ and 2014 AHA/ACC²
55 guidelines for the management of patients with valvular heart disease gave a class I
56 recommendation for TV surgery for i) patients with severe primary or secondary tricuspid
57 regurgitation (TR) undergoing left-side valve surgery; ii) symptomatic patients with severe
58 isolated primary TR without severe right ventricular (RV) dysfunction; iii) symptomatic
59 patients with severe tricuspid stenosis (TS) or patients with severe TS undergoing left-side
60 valve surgery. In addition, surgery should be considered (Class IIa) for iv) patients with
61 moderate TR undergoing left-side valve surgery patients; v) patients with mild to moderate
62 secondary TR with tricuspid annular dilatation or prior evidence of right heart failure
63 undergoing left-side valve surgery; vi) patients with asymptomatic or mildly symptomatic
64 severe isolated primary TR and progressive RV dysfunction. As TV disease is rarely isolated,
65 most surgical procedures are combined with left-side valve surgeries.

66 Treatment options for TV surgery include valve repair with or without annuloplasty ring and
67 in case of unrepairable valvular lesions or late failed repair, TV replacement with a
68 bioprosthesis or a mechanical valve. The two types of valves have similar long-term clinical
69 outcome.⁶⁻⁹ In clinical practice, like for left-heart valves, bioprostheses are generally preferred

70 in patients over 65 years and mechanical valves in younger patients with need to continuous
71 anticoagulation. Temporal trends of TV surgery were recently analysed in the STS (Society of
72 Thoracic Surgeons) database.³ Over the last decade, 54735 patients underwent TV surgery in
73 the US. The annual number of TV surgeries almost tripled between 2000 and 2010, the
74 majority combined with other major surgical procedures (85.7%), mainly mitral valve
75 surgery. The proportion of valve repairs increased from 84.6% in 2000 to 88.9% in 2010 with
76 a parallel decline in TV replacements. The most common type of valve repair was
77 annuloplasty alone (75.5%) and most TV replacements were performed using bioprostheses
78 (81.5%). Despite increasing age and comorbidity, there was a gradual decrease in operative
79 mortality from 10.6% to 8.2% during the study period, although concomitant procedures
80 involving multiple valves or CABG were associated with an increased risk of mortality
81 compared with isolated TVS.

82

83 **NEED FOR PERMANENT PACING AFTER TRICUSPID VALVE SURGERY**

84 *Trends and indication of permanent pacemaker implantation*

85 Tricuspid valve surgery carries a significant risk of conduction disorders requiring permanent
86 pacemaker implantation (PPI). The implantation rate tended to decrease over time from 13-
87 22% before 2000⁴ to 5-11% in the recent years,¹⁰ but rates as high as 27% have been recently
88 described after TV replacement.¹¹ Multivalve surgery,^{4, 5} redo-TV surgery¹² and the use of a
89 ring annulus for TV repair^{10, 13} are independent surgical predictors of PPI need. In the study
90 by Koplán,⁴ TV surgery doubled the risk of PPI in patients with multivalve surgery. Similar
91 observations were recently reported in a large UK multicentre registry of more than 135,000
92 patients with valve replacement. Using single aortic valve replacement as reference, hazard
93 ratio for PPI was 2.22 (95%CI 1.40-3.53, $p < 0.001$) for multivalve surgery including TV
94 replacement, compared to 1.52 (95%CI 1.40-1.65), $p < 0.001$) without TV replacement.⁵
95 (Figure 1). In the whole registry population, age, male gender, renal impairment and heart
96 failure were identified as independent clinical predictors of PPI requirement. However, these
97 clinical risk factors have not been found in specific populations of TVS patients. In the same
98 groups, no preoperative ECG characteristics were identified to predict postoperative PPI
99 need.^{10, 13}

100 The leading ECG indication for PPI after TV surgery is atrial fibrillation with slow ventricular
101 response (57%¹⁰), followed by complete heart block (28%) and sinus node dysfunction.
102 Indeed, most of the patients undergoing TV surgery are in permanent atrial fibrillation

103 (76%¹⁰), explaining why a majority of TV surgery patients needing PPI are implanted with a
104 single-chamber VVI/VVIR device (75%¹⁰)

105

106 *Timing of PPI: immediate versus late implantations*

107 To date, only one single study brought insights about the timing of PPI after TV surgery.¹⁰
108 Fifty four percent of the pacemakers were implanted before hospital discharge after a
109 minimum follow-up time of 5 days; most of these patients needed temporary pacing
110 immediately after the surgery. The other 46% patients had delayed implantation up to 8 years
111 post-operatively (Figure 1). A similar increased risk of late conduction disturbances after TV
112 surgery compared to other valve interventions was also shown in the UK registry.⁵

113 Some teams, mainly in the US, made the choice of immediate PPI using epicardial leads in
114 case of perioperative heart block. In the STS database, 4.2% of the patients with TV repair
115 and 5.6% with TV replacement received permanent epicardial pacemaker at the operative
116 time.³ This strategy is debatable since it is well known that a significant proportion of patients
117 with PPI after cardiac surgery are no longer PM-dependent at long-term follow-up. The
118 proportion is higher for patients implanted for sinus node dysfunction (60-70%) than those
119 implanted for AV block (0-35%).¹⁴ Such observation was also demonstrated in the specific
120 group of TVS patients where up to 65% were no longer PM-dependent during long-term
121 follow-up.^{10, 11} This observation is an additional argument for delaying PPI if possible. Thus,
122 it seems reasonable to apply to TV surgery patients the general guidelines recommendation on
123 PPI indications after cardiac surgery, i.e. a period of clinical observation up to 7 days to assess
124 whether the rhythm disturbance is transient and spontaneously resolves. Temporary epicardial
125 leads should be maintained during this observation period. However, in case of complete AV
126 block with low rate escape rhythm, this observation period can be shortened since resolution
127 is unlikely (Class I, level of evidence C).¹⁴

128

129 *Long-term outcomes*

130 There are very few data in the literature on long-term clinical outcomes after PPI in TV
131 surgery patients. In the series of Jokinen et al on 136 patients with a mean follow-up time of
132 7.9+4.1 years, survival was better in patients with pacemaker implantation than in patients
133 without pacemaker (P=0.05).¹⁰ However, PPI was significantly associated with a higher
134 incidence of cerebrovascular events (stroke or transient ischemic attack) and of worse
135 functional status (NYHA Class III-IV).

136

137 **APPROACHES FOR DEVICE IMPLANTATION AFTER TRICUSPID VALVE**
138 **SURGERY**

139

140 **1. Pacemaker implantation in patients with TV surgery**

141 Five different options can be discussed i) implant epicardial leads; ii) implant a standard
142 transvenous RV lead; iii) implant a parahissian lead for His-bundle pacing (HBP); iv) implant
143 a coronary sinus lead for left ventricular (LV) pacing only; and v) implant a leadless
144 pacemaker.

145

146 *Epicardial pacing*

147 Data regarding epicardial pacing after TV surgery in adults are scarce. Indeed, most of the
148 available data are about epicardial device implantation in patients after congenital heart
149 disease repair. Although epicardial devices are efficient to ensure pacing, the reliability of
150 endocardial leads has been shown to be superior compared to epicardial systems.^{15, 16} This is
151 particularly true if patients already had open-heart surgeries, since operators may have a hard
152 time to find a portion of ventricle with acceptable pacing thresholds. Although this option has
153 been widely used in the STS registry,³ perioperative implantation of permanent epicardial
154 pacing leads should be reserved for very specific cases of immediate AV block with very low
155 probability of secondary resumption (see paragraph *Timing of PPI*). An example of epicardial
156 pacemaker implanted after tricuspid valve replacement is shown in Figure 2A.

157

158 *RV transvenous leads*

159 Cardiac implantable electronic device leads can interfere with the function of native tricuspid
160 valves, leading to a significant morbidity and mortality through hemodynamic impairment. In
161 a series published by the Mayo Clinic group, 41 device recipients required TV surgery for
162 severe TV regurgitation caused by previously placed RV transvenous pacemaker or ICD
163 lead.¹⁷ All patients were found to have morphologically normal TV with malfunction caused
164 by the lead, mostly lead adherence or impingement. The TV was repaired or replaced, and the
165 lead removed or positioned and sutured in the posteroseptal or anteroposterior commissure.
166 Recent data suggest that PM leads are associated with a higher risk of TV regurgitation grade
167 3-4 after adjustment for LV systolic dysfunction and pulmonary hypertension, and that PM-
168 related regurgitation was associated with a 40% increased mortality.¹⁸ Thus, a thorough
169 consideration has to be made in the decision of implanting transvenous RV leads.

170 The mechanisms leading to lead-induced TV dysfunction are various, either mechanical (TV
171 obstruction, perforation or laceration; lead adherence due to fibrosis causing incomplete TV
172 closure; lead entrapment in the TV apparatus) or functional (pacing-induced dyssynchrony
173 leading to myocardial dysfunction and TV annular dilatation),¹⁹ and requiring a specific
174 management based on lead removal/relocation/replacement associated with TV
175 repair/replacement if needed, depending on clinical and echocardiographic data.²⁰
176 Data regarding the interaction of RV transvenous leads with TV apparatus after valvular
177 repair or replacement are scarce and controversial. Mazine et al reported their experience on
178 791 patients with TV repair between 1997 and 2008, 176 of them having or requiring a
179 subsequent pacemaker implantation.²¹ The presence of a transvenous pacemaker was found to
180 be an independent risk factor for recurrence of TR during follow-up. The presence of a
181 transvenous lead was also found to be a significant independent predictor of late mortality.
182 Conversely, Eleid et al did not find any clear evidence of increased risk of post-operative
183 severe TR in a cohort of 58 patients who underwent a bioprosthetic TV implantation prior to
184 PM/ICD transvenous lead implantation.²² Although more data would be required to clarify the
185 safety of such method, transvalvular lead implantation may appear an acceptable approach for
186 patients after TV repair or with a bioprosthetic TV or/and requiring a permanent pacemaker or
187 defibrillator placement. Examples of transvenous lead implantation after bioprosthetic valve
188 replacement or repair are shown in Figure 2 (Panel B and panels C and D, respectively).
189 However, we firmly do not recommend, even done and published,²³ positioning a RV
190 transvenous lead through a mechanical valve due to a high risk of complications, including,
191 obviously, the risk of lead fracture and valve obstruction.

192

193 *His-bundle pacing*

194 Compared to ventricular pacing, HBP is a more physiologic form of pacing supposed to
195 preserve normal electrical activation of the ventricles and prevent ventricular dyssynchrony.²⁴
196 This could be an interesting alternative for treating post-TVS AV blocks, especially as the
197 conduction disorder is nodal in the majority of cases. HBP has been described to be feasible in
198 a majority of patients after prosthetic valve surgery,²⁴ but in the series published so far, only
199 10 patients with TV rings were included and none with TV replacement. From a technical
200 point of view, the TV ring may act as a radiographic marker of the his-bundle and facilitate
201 the identification of the successful site. Interestingly, successful sites of HBP appeared to be
202 at an average distance of 19 mm from the TV ring.²⁴ Further studies will be required to
203 analyze the safety and efficacy of HBP specifically in patients after TV surgery.

204

205 *Coronary sinus leads*

206 Before the advent of transvenous CRT in late 90s', few manuscripts reported cases of
207 permanent ventricular pacing through coronary veins, either due to inadvertent placement of
208 the "RV" lead into the middle cardiac vein with a revised diagnosis obtained from paced
209 RBBB pattern and from the chest-X ray in sagittal view,²⁵⁻²⁷ or with a deliberate CS
210 positioning due to inaccessible RV in patients with congenital heart diseases²⁸⁻³⁰ or after TV
211 replacement.^{26, 31, 32}

212 Since CRT emerged as a cornerstone therapy for heart failure patients, rare supplementary
213 data have been published in the literature regarding CS pacing after TV surgery. Only one
214 small series of 17 patients (11 TV repairs and 6 TV replacements, including 2 mechanical
215 ones) was recently published. The time interval for PM implantation after TV surgery was
216 around one week. Pacing threshold at implantation was $1.9\pm 0.3V$ and remained stable after a
217 2-year follow-up.³³ Due to the right atrial dilatation and resulting malposition of the CS
218 ostium, CS catheterization and lead placement may be more challenging in this specific
219 situation compared to typical CRT patients.

220 The long-term effects of VVI pacing using only one single LV lead are not very well known.
221 In observational studies in CRT patients, LV pacing with a single lead seemed to have similar
222 clinical efficacy and safety compared with biventricular pacing.³⁴

223 However, there is currently no data regarding the consequences of lateral or postero-lateral
224 LV-only pacing in patients with TV regurgitation-induced pre-existing RV dysfunction and/or
225 pulmonary hypertension. The risk of pacing-induced inverted mechanical dyssynchrony
226 would be theoretically possible, although not clinically demonstrated. Thus, targeting the
227 great cardiac vein might be a good option in such patients, since QRS duration is often shorter
228 and ventricular activation sequence is more homogeneous when pacing from this position
229 (Figure 3). In every case, the CS lead should be positioned in a stable and harmless position.

230

231 *Leadless pacemaker*

232 There are currently no large data about the safety and efficacy of leadless pacemakers in
233 patients after TV surgery. In the Nanostim registry, Reddy et al report that 6 (1.1%) out of the
234 526 patients included had a history of TV repair or bioprosthetic replacement, but, to the best
235 of our knowledge, no specific data was reported yet,³⁵ while in the Micra registry, Reynolds et
236 al do not specify if any of the patients included had prior TV surgery.³⁶ To date, cases
237 reporting a Micra implantation after TV repair³⁷ and TV bioprosthesis surgery^{38, 39} were

238 reported (Figure 4). The procedures were straightforward, with no complications, and patients
239 did not have any valvular dysfunction after the intervention.

240 To note, leadless pacing can only provide single-chamber ventricular pacing, which can be a
241 limitation for those patients necessitating dual-chamber pacing. However, a high proportion of
242 patients after TV surgery is in atrial fibrillation and will not require the implantation of an
243 atrial lead. Lastly, one major concern of this technique would be the issue of damaging a
244 newly repaired/replaced TV with the delivery tools. Thus, although attractive, this approach
245 will need further evidence regarding its safety profile and the potential need to have a post-
246 operative blanking period, before being largely used in clinical practice.

247

248 **2. ICD implantation in patients with TV surgery**

249 Four approaches can be discussed for ICD implantation after TV surgery.

250 The implantation of an epicardial ICD can be proposed, but is of high operative risk in frail
251 patients. A transvenous ICD RV lead implantation may be preferred for those patients after
252 TV repair or bioprosthetic valve replacement (Figure 5, panel A).

253 Some cases initially reported the safety and efficacy of ICD lead implantation in the coronary
254 sinus (Figure 5, panels B and C),^{40,41} confirmed by a small study of 6 patients with congenital
255 heart diseases contra-indicated for transvenous RV lead implantation. Lopez et al ICD lead
256 was placed in the middle-cardiac vein, with a defibrillation threshold safety margin of at least
257 10J in all patients.⁴² During follow-up, 1 patient was successfully shocked and 2 had
258 successful antitachycardia pacing and the remaining ones. The only concern of such approach
259 remains the extractability of an ICD lead, with a coil positioned in a tributary vein of the
260 coronary sinus. Further studies will be needed to prove the safety of such approach.

261 Alternatively, an approach associating the implantation of a ventricular sensing lead in the CS
262 and a defibrillation lead floating free in the inferior vena cava has been described in a patient
263 with Ebstein's disease and a bioprosthetic heart valve (Figure 5, panel D), with a stable
264 defibrillation threshold after 1-year follow-up.⁴³

265 To avoid the potential future issue of TV dysfunction and lead extraction, an attractive option
266 could be the implantation of a subcutaneous ICD (S-ICD) if the patient is eligible and has no
267 indication for pacing (Figure 5, panels E and F). Indeed, S-ICD eliminates the need for
268 vascular access, and therefore, the risk of lead-induced TV dysfunction.⁴⁴ Evidences
269 regarding the safety and efficacy of S-ICD are increasing,⁴⁵⁻⁴⁷ and this major breakthrough in
270 the defibrillation topic could be considered as a perfect alternative for patients after TV
271 surgery, as described in a case recently published.⁴⁸

272

273 3. The problem of patients with pre-existing transvenous RV leads

274 In case of a pre-existing RV transvenous lead in a patient requiring TV replacement, two
275 different options may be discussed. First, surgeons may choose to cut the lead, unscrew and
276 remove the distal part of the lead, and leave the proximal part for a percutaneous extraction.
277 Pacing is ensured by implanting an epicardial pacemaker. This solution is suboptimal since
278 extractability of the remaining lead is hampered by the impossibility of using standard
279 dedicated techniques (wires, laser, mechanical tools, ...). Alternatively, a conservative
280 technique can be used, by removing the native TV, and position the prosthesis in the annulus,
281 leaving the RV lead undisturbed outside the TV.^{17, 49, 50} The main concern of this technique
282 would be the occurrence of a device infection. Indeed, percutaneous extraction would be
283 theoretically impossible, and such patients would require a surgical approach for lead
284 removal. The same approach can be used for patients with pre-existing ICD leads, although
285 the risk of lead fracture and subsequent inappropriate therapy may be a serious issue.

286 In case of TV repair not requiring a replacement, the technique recently described by Raman
287 can be used, where ICD or PM leads are mobilized and detached if needed from the TV
288 leaflets, then repositioned in the cleft between the septal and the inferior/posterior leaflets
289 with suture approximation of the leaflets above the cleft, and eventually an annuloplasty can
290 be performed if needed.^{20, 51}

291

292 PRACTICAL RECOMMENDATIONS - CONCLUSION

293 The annual number of TV surgeries is continuously increasing, and some of these patients
294 will require immediately after the surgery or later on a PM or ICD device implantation.
295 Therefore, one has to be prepared to consider all the benefits and drawbacks of the potential
296 options in these situations, aiming to obtain a safe and efficient pacing/defibrillation without
297 damaging the surgical effort. We propose the following recommendations (Tables 1 and 2):

- 298 - In case of immediate AVB with a low chance of AV conduction resumption
299 (multivalve surgery,^{4, 5} redo-TV surgery¹² and the use of a ring annulus for TV
300 repair^{10, 13}), an epicardial pacemaker should be implanted.
- 301 - If the AVB occurs late, the preferred options in patients with repaired/bioprosthetic
302 TV would be to implant either a regular transvenous lead or a CS lead. Although
303 assumed to be an attractive solution, leadless PM implantation will require further
304 safety evidence before it can be largely used in this type of patients. In patients with

305 mechanical prosthesis, the only options are the implantation of an epicardial PM or a
306 regular PM with a CS lead.

307 - For patients requiring ICD implantation after TV surgery, we recommend implanting a
308 S-ICD if the patient is eligible and does not require pacing. Otherwise, a regular RV
309 transvenous lead should be implanted in patients with repaired/bioprosthetic TV, while
310 an epicardial ICD should be proposed for those with mechanical prosthesis.

311

312 **REFERENCES**

313

- 314 **1.** Baumgartner H, Falk V, Bax JJ, et al. 2017 ESC/EACTS Guidelines for the
315 management of valvular heart disease: The Task Force for the Management of
316 Valvular Heart Disease of the European Society of Cardiology (ESC) and the
317 European Association for Cardio-Thoracic Surgery (EACTS). *Eur Heart J.* 2017.
- 318 **2.** Nishimura RA, Otto CM, Bonow RO, et al. 2014 AHA/ACC guideline for the
319 management of patients with valvular heart disease: executive summary: a report of
320 the American College of Cardiology/American Heart Association Task Force on
321 Practice Guidelines. *J Am Coll Cardiol.* 2014;63:2438-2488.
- 322 **3.** Kilic A, Saha-Chaudhuri P, Rankin JS, Conte JV. Trends and outcomes of tricuspid
323 valve surgery in North America: an analysis of more than 50,000 patients from the
324 Society of Thoracic Surgeons database. *Ann Thorac Surg.* 2013;96:1546-1552;
325 discussion 1552.
- 326 **4.** Koplan BA, Stevenson WG, Epstein LM, Aranki SF, Maisel WH. Development and
327 validation of a simple risk score to predict the need for permanent pacing after cardiac
328 valve surgery. *J Am Coll Cardiol.* 2003;41:795-801.
- 329 **5.** Leyva F, Qiu T, McNulty D, Evison F, Marshall H, Gasparini M. Long-term
330 requirement for pacemaker implantation after cardiac valve replacement surgery.
331 *Heart Rhythm.* 2017;14:529-534.
- 332 **6.** Hwang HY, Kim KH, Kim KB, Ahn H. Mechanical tricuspid valve replacement is not
333 superior in patients younger than 65 years who need long-term anticoagulation. *Ann*
334 *Thorac Surg.* 2012;93:1154-1160.
- 335 **7.** Rizzoli G, Vendramin I, Nesseris G, Bottio T, Guglielmi C, Schiavon L. Biological or
336 mechanical prostheses in tricuspid position? A meta-analysis of intra-institutional
337 results. *Ann Thorac Surg.* 2004;77:1607-1614.

- 338 **8.** Said SM, Burkhart HM, Schaff HV, Johnson JN, Connolly HM, Dearani JA. When
339 should a mechanical tricuspid valve replacement be considered? *J Thorac Cardiovasc*
340 *Surg.* 2014;148:603-608.
- 341 **9.** Scully HE, Armstrong CS. Tricuspid valve replacement. Fifteen years of experience
342 with mechanical prostheses and bioprostheses. *J Thorac Cardiovasc Surg.*
343 1995;109:1035-1041.
- 344 **10.** Jokinen JJ, Turpeinen AK, Pitkanen O, Hippelainen MJ, Hartikainen JE. Pacemaker
345 therapy after tricuspid valve operations: implications on mortality, morbidity, and
346 quality of life. *Ann Thorac Surg.* 2009;87:1806-1814.
- 347 **11.** Mar PL, Angus CR, Kabra R, Migliore CK, Goswami R, John LA, Tu Y,
348 Gopinathannair R. Perioperative predictors of permanent pacing and long-term
349 dependence following tricuspid valve surgery: a multicentre analysis. *Europace.* 2017.
- 350 **12.** Jeganathan R, Armstrong S, Al-Alao B, David T. The risk and outcomes of
351 reoperative tricuspid valve surgery. *Ann Thorac Surg.* 2013;95:119-124.
- 352 **13.** Jouan J, Mele A, Florens E, Chatellier G, Carpentier A, Achouh P, Fabiani JN.
353 Conduction disorders after tricuspid annuloplasty with mitral valve surgery:
354 Implications for earlier tricuspid intervention. *J Thorac Cardiovasc Surg.* 2016;151:99-
355 103.
- 356 **14.** Brignole M, Auricchio A, Baron-Esquivias G, et al. 2013 ESC guidelines on cardiac
357 pacing and cardiac resynchronization therapy: the task force on cardiac pacing and
358 resynchronization therapy of the European Society of Cardiology (ESC). Developed in
359 collaboration with the European Heart Rhythm Association (EHRA). *Europace.*
360 2013;15:1070-1118.
- 361 **15.** Esperer HD, Mahmoud FO, von der Emde J. Is epicardial dual chamber pacing a
362 realistic alternative to endocardial DDD pacing? Initial results of a prospective study.
363 *Pacing Clin Electrophysiol.* 1992;15:155-161.
- 364 **16.** McLeod CJ, Attenhofer Jost CH, Warnes CA, Hodge D, 2nd, Hyberger L, Connolly
365 HM, Asirvatham SJ, Dearani JA, Hayes DL, Ammash NM. Epicardial versus
366 endocardial permanent pacing in adults with congenital heart disease. *J Interv Card*
367 *Electrophysiol.* 2010;28:235-243.
- 368 **17.** Lin G, Nishimura RA, Connolly HM, Dearani JA, Sundt TM, 3rd, Hayes DL. Severe
369 symptomatic tricuspid valve regurgitation due to permanent pacemaker or implantable
370 cardioverter-defibrillator leads. *J Am Coll Cardiol.* 2005;45:1672-1675.

- 371 **18.** Delling FN, Hassan ZK, Piatkowski G, Tsao CW, Rajabali A, Markson LJ,
372 Zimetbaum PJ, Manning WJ, Chang JD, Mukamal KJ. Tricuspid Regurgitation and
373 Mortality in Patients With Transvenous Permanent Pacemaker Leads. *Am J Cardiol.*
374 2016;117:988-992.
- 375 **19.** Al-Bawardy R, Krishnaswamy A, Bhargava M, Dunn J, Wazni O, Tuzcu EM, Stewart
376 W, Kapadia SR. Tricuspid regurgitation in patients with pacemakers and implantable
377 cardiac defibrillators: a comprehensive review. *Clin Cardiol.* 2013;36:249-254.
- 378 **20.** Chang JD, Manning WJ, Ebrille E, Zimetbaum PJ. Tricuspid Valve Dysfunction
379 Following Pacemaker or Cardioverter-Defibrillator Implantation. *J Am Coll Cardiol.*
380 2017;69:2331-2341.
- 381 **21.** Mazine A, Bouchard D, Moss E, Marquis-Gravel G, Perrault LP, Demers P, Carrier
382 M, Cartier R, Pellerin M. Transvalvular pacemaker leads increase the recurrence of
383 regurgitation after tricuspid valve repair. *Ann Thorac Surg.* 2013;96:816-822.
- 384 **22.** Eleid MF, Blauwet LA, Cha YM, Connolly HM, Brady PA, Dearani JA, Espinosa RE.
385 Bioprosthetic tricuspid valve regurgitation associated with pacemaker or defibrillator
386 lead implantation. *J Am Coll Cardiol.* 2012;59:813-818.
- 387 **23.** Sierra J, Rubio J. Transvenous right ventricular pacing in a patient with tricuspid
388 mechanical prosthesis. *J Cardiothorac Surg.* 2008;3:42.
- 389 **24.** Sharma PS, Subzposh FA, Ellenbogen KA, Vijayaraman P. Permanent His-bundle
390 pacing in patients with prosthetic cardiac valves. *Heart Rhythm.* 2016;14:59-64.
- 391 **25.** Kemp A, Kjersgaard Johansen J, Kjaergaard E. Malplacement of endocardial
392 pacemaker electrodes in the middle cardiac vein. *Acta Med Scand.* 1976;199:7-11.
- 393 **26.** Lee ME. Special considerations in ventricular pacing in patients with tricuspid valve
394 disease. *Ann Thorac Surg.* 1983;36:89-92.
- 395 **27.** Shettigar UR, Loungani RR, Smith CA. Inadvertent permanent ventricular pacing
396 from the coronary vein: an electrocardiographic, roentgenographic, and
397 echocardiographic assessment. *Clin Cardiol.* 1989;12:267-274.
- 398 **28.** Blackburn ME, Gibbs JL. Ventricular pacing from the coronary sinus of a patient with
399 a Fontan circulation. *Br Heart J.* 1993;70:578-579.
- 400 **29.** Goldstein DJ, Rabkin D, Spotnitz HM. Unconventional approaches to cardiac pacing
401 in patients with inaccessible cardiac chambers. *Ann Thorac Surg.* 1999;67:952-958.
- 402 **30.** Rosenthal E, Qureshi SA, Crick JC. Successful long-term ventricular pacing via the
403 coronary sinus after the Fontan operation. *Pacing Clin Electrophysiol.* 1995;18:2103-
404 2105.

- 405 **31.** Bai Y, Strathmore N, Mond H, Grigg L, Hunt D. Permanent ventricular pacing via the
406 great cardiac vein. *Pacing Clin Electrophysiol.* 1994;17:678-683.
- 407 **32.** Conti S, Liotta C, Virgilio A, Tamburino C, Calvi V. Left ventricular pacing in a
408 patient with a mechanical tricuspid prosthesis and high surgical risk. *World J*
409 *Cardiovasc Dis.* 2014;4:567-569.
- 410 **33.** Sideris S, Drakopoulou M, Oikonomopoulos G, Gatzoulis K, Stavropoulos G,
411 Limperiadis D, Toutouzas K, Tousoulis D, Kallikazaros I. Left Ventricular Pacing
412 through Coronary Sinus Is Feasible and Safe for Patients with Prior Tricuspid Valve
413 Intervention. *Pacing Clin Electrophysiol.* 2016;39:378-381.
- 414 **34.** Touiza A, Etienne Y, Gilard M, Fatemi M, Mansourati J, Blanc JJ. Long-term left
415 ventricular pacing: assessment and comparison with biventricular pacing in patients
416 with severe congestive heart failure. *J Am Coll Cardiol.* 2001;38:1966-1970.
- 417 **35.** Reddy VY, Exner DV, Cantillon DJ, et al. Percutaneous Implantation of an Entirely
418 Intracardiac Leadless Pacemaker. *N Engl J Med.* 2015;373:1125-1135.
- 419 **36.** Reynolds D, Duray GZ, Omar R, et al. A Leadless Intracardiac Transcatheter Pacing
420 System. *N Engl J Med.* 2016;374:533-541.
- 421 **37.** Tang GH, Kaple R, Cohen M, Dutta T, Undemir C, Ahmad H, Poniros A, Bennett J,
422 Feng C, Lansman S. First percutaneous Micra leadless pacemaker implantation and
423 tricuspid valve repair with MitraClip NT for lead-associated severe tricuspid
424 regurgitation. *EuroIntervention.* 2017;12:e1845-e1848.
- 425 **38.** Kerwin SA, Mayotte MJ, Gornick CC. Transcatheter pacemaker implantation in a
426 patient with a bioprosthetic tricuspid valve. *J Interv Card Electrophysiol.* 2015;44:89-
427 90.
- 428 **39.** Boveda S, Durand P, Combes S, Mariottini CJ. Leadless pacemaker surrounded by
429 three valvular prostheses. *Heart Rhythm.* 2017;14:1421.
- 430 **40.** Gradaus R, Eckardt L, Wedekind H, Loher A, Bocker D. Transvenous ICD
431 implantation after artificial tricuspid valve replacement. A new approach placing a
432 transvenous ICD lead in the mid cardiac vein of the coronary sinus. *Z Kardiol.*
433 2005;94:588-591.
- 434 **41.** Srinivasan NT, Segal OR. Biventricular pacing and coronary sinus ICD lead
435 implantation in a patient with a mechanical tricuspid valve replacement. *J Cardiol*
436 *Cases.* 2015:180-182.
- 437 **42.** Lopez JA. Implantable cardioverter defibrillator lead placement in the middle cardiac
438 vein after tricuspid valve surgery. *Europace.* 2012;14:853-858.

- 439 **43.** Grimard C, May MA, Mabo P, Babuty D. An original defibrillation lead implantation
440 to avoid tricuspid prosthesis damage. *Europace*. 2009;12:589-590.
- 441 **44.** Lewis GF, Gold MR. Clinical experience with subcutaneous implantable cardioverter-
442 defibrillators. *Nat Rev Cardiol*. 2015;12:398-405.
- 443 **45.** Bardy GH, Smith WM, Hood MA, et al. An entirely subcutaneous implantable
444 cardioverter-defibrillator. *N Engl J Med*. 2010;363:36-44.
- 445 **46.** Burke MC, Gold MR, Knight BP, et al. Safety and Efficacy of the Totally
446 Subcutaneous Implantable Defibrillator: 2-Year Results From a Pooled Analysis of the
447 IDE Study and EFFORTLESS Registry. *J Am Coll Cardiol*. 2015;65:1605-1615.
- 448 **47.** Weiss R, Knight BP, Gold MR, Leon AR, Herre JM, Hood M, Rashtian M, Kremers
449 M, Crozier I, Lee KL, Smith W, Burke MC. Safety and efficacy of a totally
450 subcutaneous implantable-cardioverter defibrillator. *Circulation*. 2013;128:944-953.
- 451 **48.** Arias MA, Pachon M, Akerstrom F, Puchol A, Sanchez-Perez A, Rodriguez-Padial L.
452 Subcutaneous Defibrillator: Role in the Prevention of Sudden Cardiac Death in the
453 Setting of Mechanical Tricuspid Prosthesis. *Rev Esp Cardiol*. 2016;69:343-345.
- 454 **49.** Aris A, Callejo F, Cobiella J, Maestre ML. Tricuspid valve replacement in the
455 presence of an endocardial pacemaker electrode. *J Heart Valve Dis*. 2004;13:523-524.
- 456 **50.** Molina JE, Roberts CL, Benditt DG. Long-term follow-up of permanent transvenous
457 pacing systems preserved during tricuspid valve replacement. *Ann Thorac Surg*.
458 2010;89:318-320.
- 459 **51.** Raman J, Sugeng L, Lai DT, Jeevanandam V. Complex Tricuspid Valve Repair in
460 Patients With Pacer Defibrillator-Related Tricuspid Regurgitation. *Ann Thorac Surg*.
461 2016;101:1599-1601.
- 462
463

464 **TABLES**

465

466 **Table 1: Practical recommendations for patients requiring pacemaker implantation**
467 **after tricuspid valve surgery.**

	Immediate AVB with low chance of AV conduction resumption	Post-operative AVB				
		Epicardial leads	RV transvenous leads	CS leads	Leadless PM	His-bundle pacing
TV repair	Consider implanting an epicardial PM	+	++	+	+ (*)	+
TV bioprosthesis		+	++	++	+ (*)	+
TV mechanical prosthesis		++	0	++	0	0

468

469 * after a post-operative blanking period of 1-3 months before considering implantation

470

471

472 **Table 2: Practical recommendations for patients requiring an implantable cardioverter-**
473 **defibrillator after tricuspid valve surgery.**

	Post-operative need for an ICD			
	Epicardial ICD	RV transvenous ICD lead	CS lead	ICD S-ICD
TV repair	+	+++ (*)	0/+	+++ (**)
TV bioprosthesis	+	+++ (*)	0/+	+++ (**)
TV mechanical prosthesis	++ (*)	0	0/+	+++ (**)

474

475 * indication for pacing, ** no indication for pacing

476

477 **FIGURES**

478

479 **Figure 1: Incidence of a new permanent pacemaker implantation during long-term**
480 **follow-up after cardiac surgery.** Adapted from Leyva et al.⁵ Published with permission of
481 the Publisher.

482

483 **Figure 2: X-ray showing an epicardial pacemaker after TV (arrow) and mitral valve**
484 **replacement (panel A) and a dual chamber pacemaker with transvenous leads after TV**
485 **annuloplasty (arrow, panel B) and TV replacement (arrow, panel C).**

486

487 **Figure 3: LV-pacing only through a CS lead placed in the great cardiac vein in a patient**
488 **with mechanical TV and mitral valve replacement.** Adapted from Conti et al.³² Published
489 with permission of the Publisher.

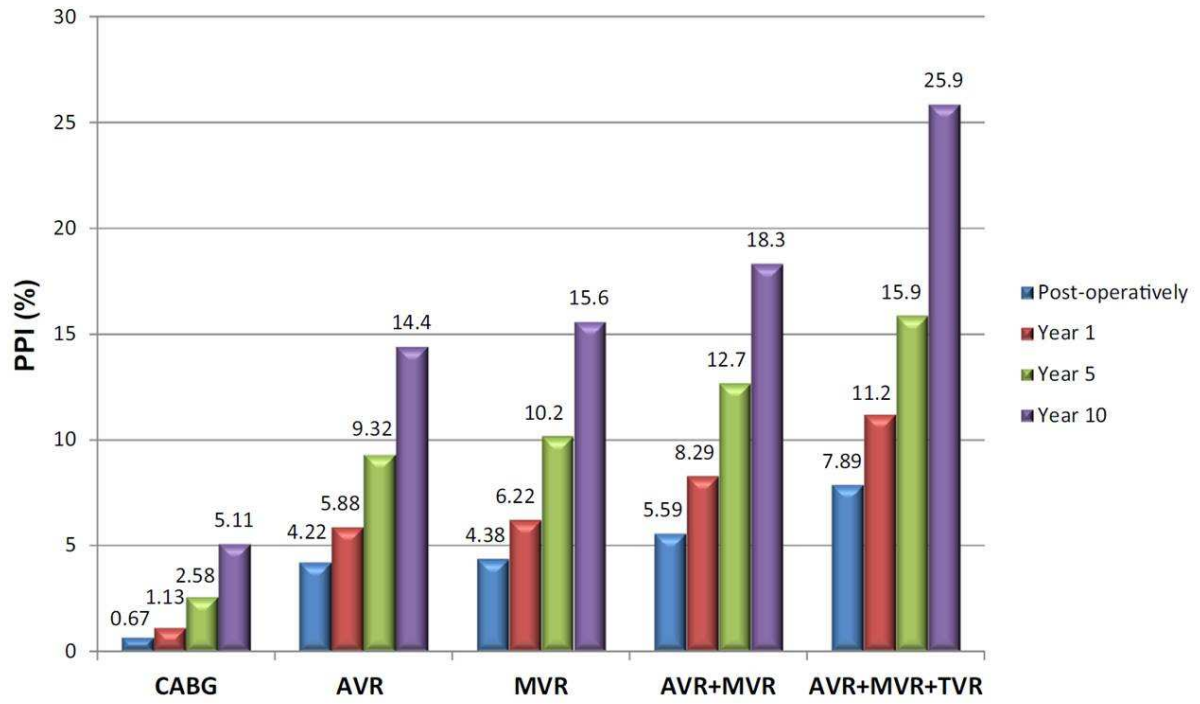
490

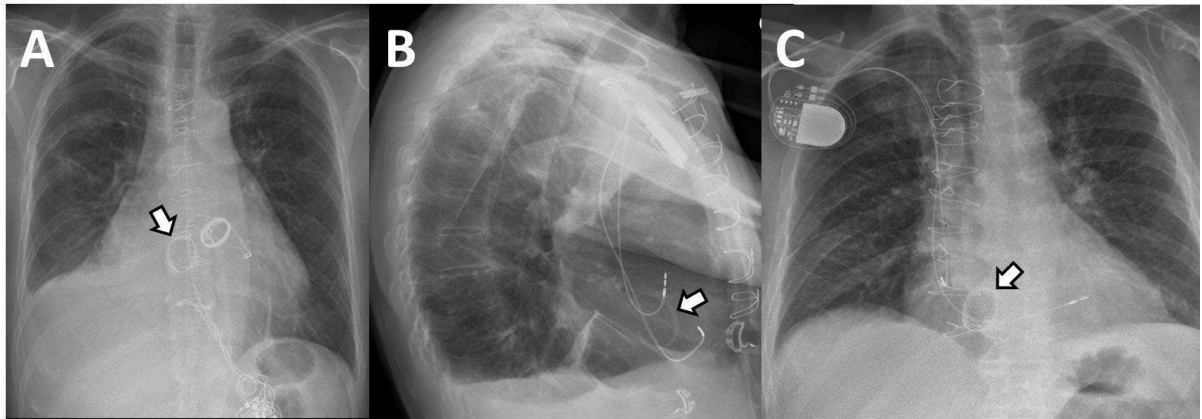
491 **Figure 4: Implantation of Micra leadless pacemaker in two patients with bioprosthetic**
492 **TV.** Adapted from Kerwin SA et al³⁸ and from Boveda S et al.³⁹ Published with permission
493 of the Publishers.

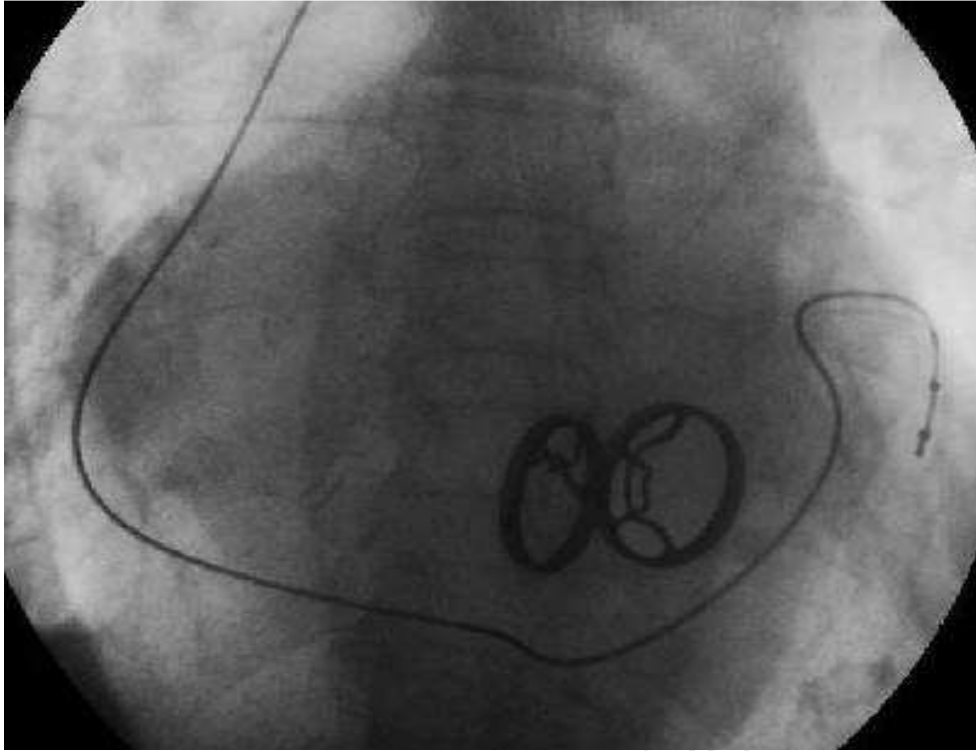
494

495 **Figure 5: ICD implantation after TV surgery.** Transvenous lead implantation after TV
496 repair and annuloplasty (arrow, panel A). Implantation of a CS-ICD lead: selective
497 angiography of the coronary sinus in left anterior oblique projection, with mechanical TV and
498 mitral valve; an ICD lead was positioned in the mid-lateral branch of CS (panels B and C,
499 adapted from Srinivasan et al⁴¹, Published with permission of the Publisher.). Example of a
500 defibrillation lead positioned with the proximal coil in the inferior vena cava associated with a
501 pacing and sensing lead in the CS (panel D, full and dotted arrow, respectively, adapted from
502 Grimard C et al⁴³, Published with permission of the Publisher.). Implantation of a
503 subcutaneous ICD in a patient with a mechanical TV (panel E and F, adapted from Arias MA
504 et al⁴⁸, Published with permission of the Publisher. Copyright © 2015 Sociedad Española de
505 Cardiología. Published by Elsevier Spain, S.L. All rights reserved).

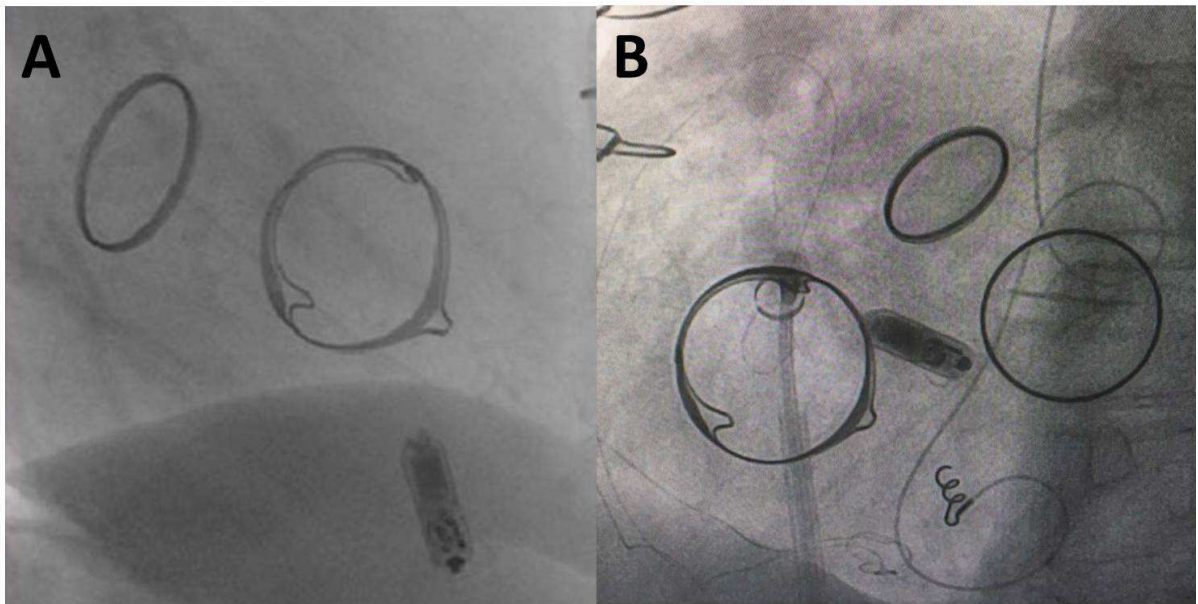
506



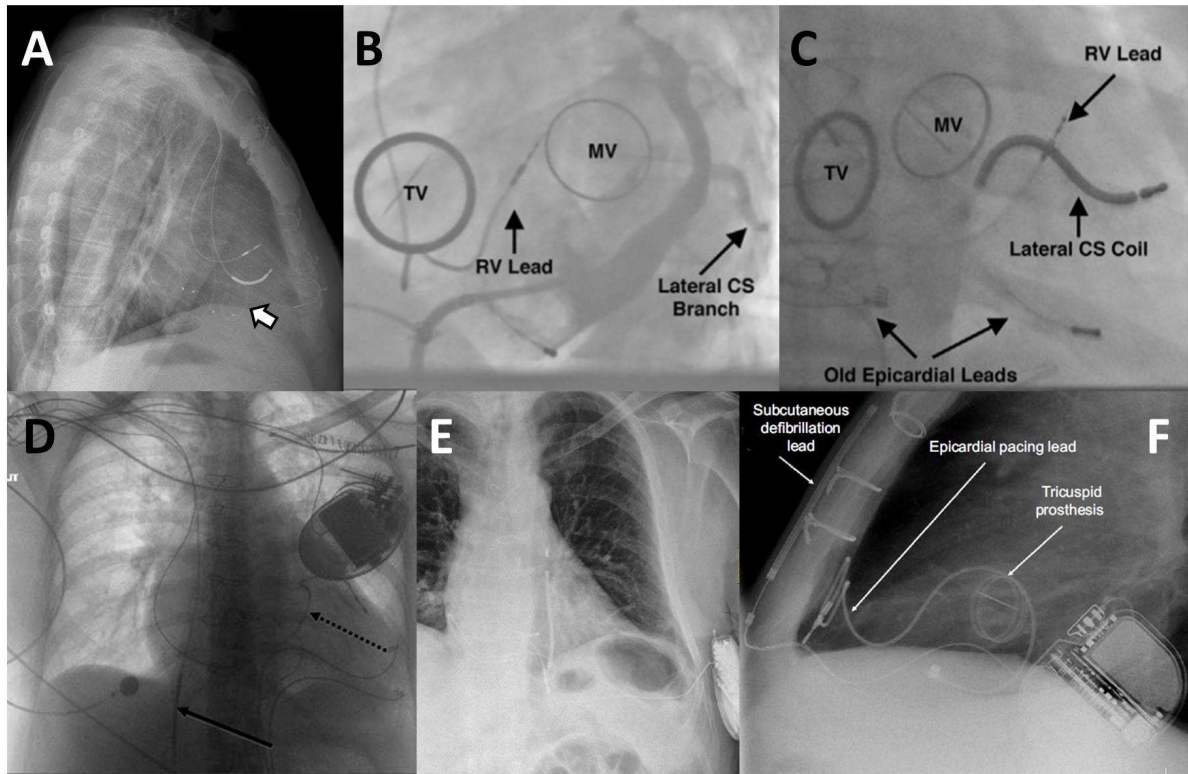




ACCEPTED MANUSCRIPT



ACCEPTED MANUSCRIPT



ACCEPTED MANUSCRIPT