



## Diffusion MRI as an imaging marker of depression from a large and homogenous population study

Julie Coloigner, Jean-Marie Batail, Isabelle Corouge, Jean-Christophe Ferré,  
Dominique Drapier, Christian Barillot

### ► To cite this version:

Julie Coloigner, Jean-Marie Batail, Isabelle Corouge, Jean-Christophe Ferré, Dominique Drapier, et al.. Diffusion MRI as an imaging marker of depression from a large and homogenous population study. ISMRM 2018 - International Society for Magnetic Resonance in Medicine, Jun 2018, Paris, France. pp.1-2. hal-01812093

**HAL Id: hal-01812093**

**<https://hal.science/hal-01812093>**

Submitted on 11 Jun 2018

**HAL** is a multi-disciplinary open access archive for the deposit and dissemination of scientific research documents, whether they are published or not. The documents may come from teaching and research institutions in France or abroad, or from public or private research centers.

L'archive ouverte pluridisciplinaire **HAL**, est destinée au dépôt et à la diffusion de documents scientifiques de niveau recherche, publiés ou non, émanant des établissements d'enseignement et de recherche français ou étrangers, des laboratoires publics ou privés.

# Diffusion MRI as an imaging marker of depression from a large and homogenous population study

Julie Coloigner<sup>1</sup>, Jean-Marie Batail<sup>1,2,3</sup>, Isabelle Corouge<sup>1</sup>, Jean-Christophe Ferré<sup>1,4</sup>, Dominique Drapier<sup>2,5</sup>, and Christian Barillot<sup>1</sup>

<sup>1</sup>Univ Rennes, Inria, CNRS, Inserm, IRISA UMR 6074, VISAGES ERL U-1228, F-35000, Rennes, France, <sup>2</sup>Academic Psychiatry Department, Centre Hospitalier Guillaume Régnier, Rennes, France, <sup>3</sup>EA 4712 Behavior and Basal Ganglia, CHU Rennes, Rennes 1 University, Rennes, France, Metropolitan, <sup>4</sup>Department of Neuroradiology, University Hospital of Rennes, Rennes, France, <sup>5</sup>EA 4712 Behavior and Basal Ganglia, CHU Rennes, Rennes, France

## Synopsis

**Despite the extensive therapy options available for depression, up to 80% of patients will suffer from a relapse. Consequently, understanding the neural correlates underlying the depression will optimize the diagnosis and treatment of individual depressed patients. The purpose of our study was to investigate alterations of white matter integrity in a large cohort of patients suffering from depression using diffusion tensor imaging. Our findings provide robust evidence that the reduction of white-matter integrity in the interhemispheric connections and fronto-limbic neuronal circuits may play an important role in depression pathogenesis.**

## Introduction

The mood depressive disorder (MDD) is a common chronically psychiatric disorder with an estimated lifetime prevalence reported to range from 10% to 15% worldwide. This disease is characterized by an intense dysregulation of affect and mood as well as additional abnormalities including cognitive dysfunction, insomnia, fatigue and appetite disturbance. Despite the extensive therapy options available for depression, up to 80% of patients will suffer from a relapse<sup>1</sup>. Consequently, exhibiting imaging biomarkers of this disease will support both a better understanding of the neural correlates underlying the depression, and a better diagnosis and treatment of individual depressed patients.

Previous studies of structural and functional magnetic resonance imaging have reported several microstructural abnormalities in the prefrontal cortex, anterior cingulate cortex, hippocampus and thalamus<sup>2</sup>. These observations suggest a dysfunction of the circuits connecting frontal and subcortical brain regions, leading to a "disconnection syndrome"<sup>3</sup>. Given the small sample size used in the past studies, we proposed a more robust analysis using a larger cohort of patients suffering from depression. We aimed to investigate alterations of white matter integrity using a voxel-based analysis based on fractional anisotropy (FA) and the apparent diffusion coefficient (ADC) in patients with depression.

## Material and Methods

LONGIDEP is a routine care cohort of patients suffering from mood depressive disorder who underwent a clinical evaluation, neuropsychological testing and brain MRI. The population sample consists of 125 patients suffering from depression and 65 healthy age and gender-matched, control subjects. A composite measure of medication load for each patient was assessed using a previously established method<sup>4</sup>.

T1-weighted and diffusion tensor imaging (DTI) were acquired on a 3T Siemens Verio scanner with a 32-channel head coil. The diffusion scans were obtained in 30 directions using an EPI sequence with a b-value of 1000s/mm<sup>2</sup>. The DTI data were processed with the open source medical image processing toolbox Anima<sup>5</sup>. All the diffusion images underwent (1) eddy current distortion correction, (2) blockwise non-local means filtering and (3) skull stripping followed by (4) a voxel-wise calculation of FA and ADC. We normalized all of the b = 0 images to the standard Montreal Neurological Institute (MNI) space to estimate the normalization parameters using nonlinear registration<sup>6</sup>. Then, we applied these parameters to the FA and ADC maps to normalize them to the MNI space. All maps derived from the DTI images of the MDD and control groups were compared by Student's t-test, with age, gender, duration of disease and medication load as nuisance covariates. The results were corrected for multiple comparisons using FDR correction.

## Results

Results of the FA and ADC analysis comparing MDD and CTL subjects are shown in Figures 1 and 2. FA was significantly lower in MDD patient (p<0.05) than in controls in the anterior corona radiata, the sagittal stratum, the corpus callosum, the posterior thalamic radiation, the inferior longitudinal fasciculus, the cingulum and the superior longitudinal fasciculus. Relative to the widespread pattern of FA reduction, ADC abnormalities follow a more restricted distribution, as displayed in Figure 2. As shown in Figure 1, there was only one brain white matter tract (the posterior limb of the internal capsule) with FA increase and ADC decrease in MDD relative to healthy controls.

## Discussion

This is the first study analyzing diffusion metrics in such a large and homogeneous depression cohort. We observed widespread white matter abnormalities in patients with MDD. As previously reported in many studies, FA reductions were observed in the genu of the corpus callosum (CC) extending to the body of the CC and left anterior limb of the internal capsule in MDD patients relative to healthy controls. However, this analysis also revealed other patterns with decreased FA and increased ADC values in the anterior corona radiata, the sagittal stratum, the posterior thalamic radiation and the cingulum, in patients with depression.

These findings in this large MDD cohort contrast with the previous results obtained with small and heterogeneous samples of patients suffering from depression. Our analysis also revealed increased FA in the bilateral posterior limbs of the internal capsule in patients with depression. Although the changes in FA and MD had a similar spatial distribution (see Figures 2 and 3), FA distribution is more widespread than the one of ADC. However, FA characterizes the shape of the diffusion tensor, while the ADC is an anisotropic measure of the mean diffusivity; therefore, FA is more likely to capture microstructure-induced diffusion differences than ADC<sup>7</sup>.

Our findings provide robust evidence that the reduction of white-matter integrity in the interhemispheric connections and fronto-limbic neuronal circuits may play an important role in MDD pathogenesis. These results are consistent with an overall hypothesis that depression involves a disconnection of prefrontal, striatal, and limbic emotional areas.

## Acknowledgements

Julie Coloigner was supported by INCR fellowship.

MRI data acquisition was supported by the Neurinfo MRI research facility from the University of Rennes I. Neurinfo is granted by the the European Union (FEDER), the French State, the Brittany Council, Rennes Metropole, Inria, Inserm and the University Hospital of Rennes.

## References

1. Gotlib, I. H., & Hamilton, J. P. (2008). Neuroimaging and depression: current status and unresolved issues. *Current Directions in Psychological Science*, 17(2), 159-163.
2. Drevets, W. C. (2001). Neuroimaging and neuropathological studies of depression: implications for the cognitive-emotional features of mood disorders. *Current opinion in neurobiology*, 11(2), 240-249.
3. Liao, Y., Huang, X., Wu, Q., Yang, C., Kuang, W., Du, M., ... & Gong, Q. (2013). Is depression a disconnection syndrome? Meta-analysis of diffusion tensor imaging studies in patients with MDD. *Journal of psychiatry & neuroscience: JPN*, 38(1), 49.
4. Sackeim, H. A. (2001). Functional brain circuits in major depression and remission. *Archives of General Psychiatry*, 58(7), 649-650.
5. ANIMA: open-source software for medical image processing, <https://github.com/Inria-Visages/Anima-Public/wiki>.
6. Commowick, O., Wiest-Daesslé, N., & Prima, S. (2012). Automated diffeomorphic registration of anatomical structures with rigid parts: Application to dynamic cervical MRI. *Medical Image Computing and Computer-Assisted Intervention–MICCAI 2012*, 163-170.
7. Westin, C. F., Maier, S. E., Mamata, H., Nabavi, A., Jolesz, F. A., & Kikinis, R. (2002). Processing and visualization for diffusion tensor MRI. *Medical image analysis*, 6(2), 93-108.

## Figures

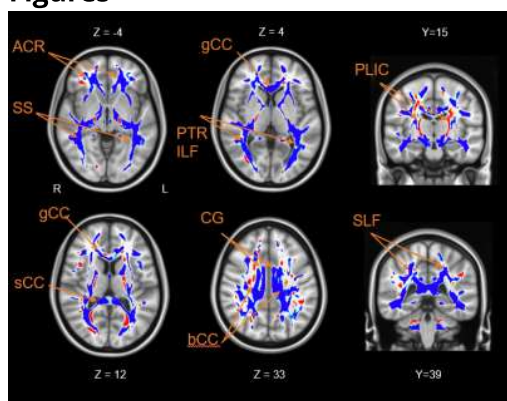


Figure 1: Axial and coronal brain slices showing significant differences of the FA values between MDD and control groups. Voxels with negative t-values (MDD<Control) are shown in blue colors and positive values (MDD>Control) with red colors. Ten clusters are indicated by arrows: ACR: anterior corona radiate, SS: sagittal stratum, gCC, sCC and bCC: genu, splenium and body of corpus callosum, PTR: posterior thalamic radiation, ILF: inferior longitudinal fasciculus, PLIC: posterior limb of internal capsule, CG: cingulum and SLF: superior longitudinal fasciculus. The background image is the standard MNI152 brain template.

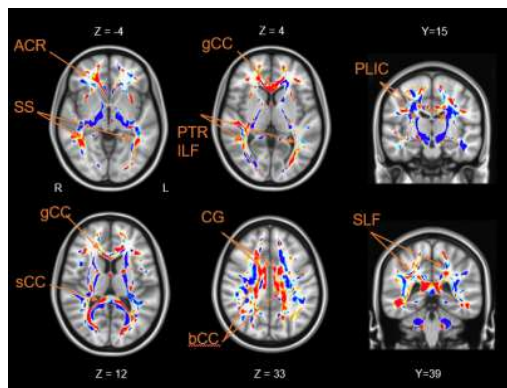


Figure 2: Axial and coronal brain slices showing significant differences of the ADC values between MDD and control groups. Voxels with negative t-values (MDD<Control) are shown in blue colors and positive values (MDD>Control) with red colors. Ten clusters are indicated by arrows: ACR: anterior corona radiate, SS: sagittal stratum, gCC, sCC and bCC: genu, splenium and body of corpus callosum, PTR: posterior thalamic radiation, ILF: inferior longitudinal fasciculus, PLIC: posterior limb of internal capsule, CG: cingulum and SLF: superior longitudinal fasciculus. The background image is the standard MNI152 brain template.