

Supplemental material

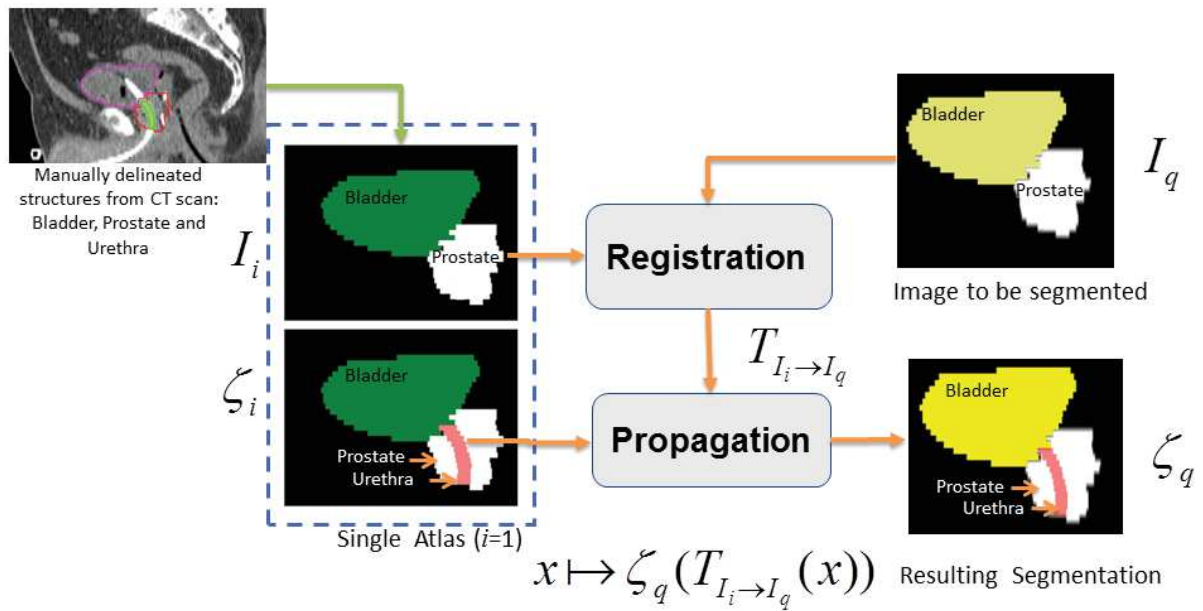


Figure A1. Atlas segmentation framework of intraprostatic urethra if a single atlas image is used

Manually delineated structures including the prostate, the bladder and the urethra are extracted from a CT scan to form the atlas. For a given bladder/prostate query image I_q , the urethra segmentation is obtained via registration of the single manually delineated template to a query image by applying the obtained transformation to the label $\zeta_i = \{urethra\}$.

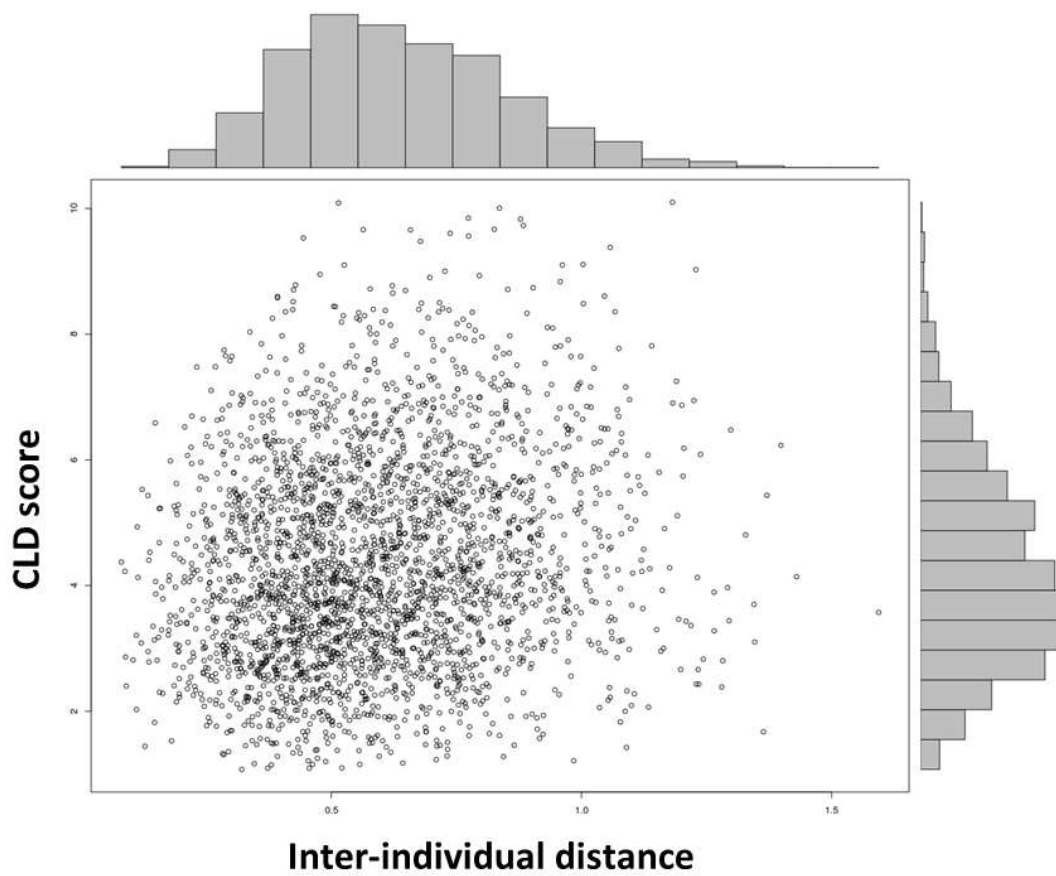


Figure A2. CLD Score vs inter-individual distance for single atlas segmentation

Point distribution show the relationship between the inter-individual distance based on the described features and the Centerline Distance (CLD) score obtained after segmentation when only a single atlas is used. There is trend showing that the shorter the distance the better the score.

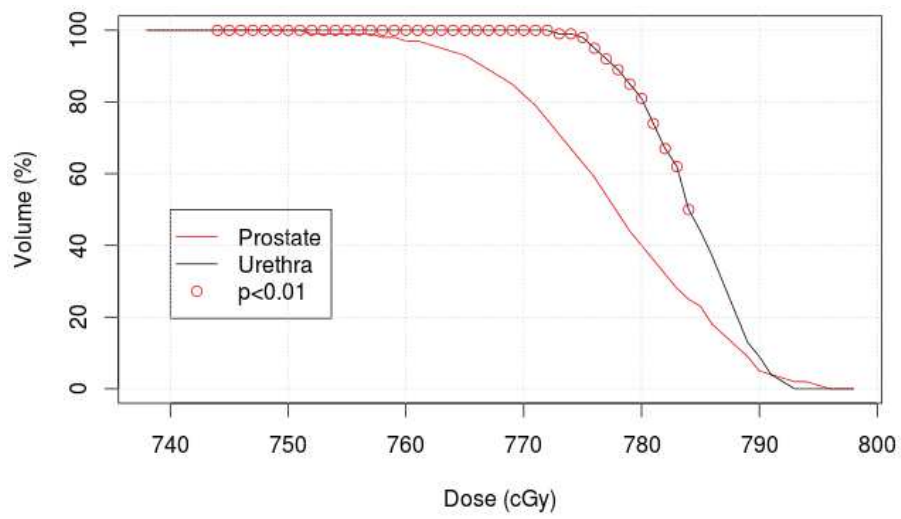


Figure A3. DVH differences between urethra and prostate in case of IMRT delivering 80Gy to the prostate (Zoom of the Figure 6)

Significant differences appear mainly in the high DVH values (red circles)

Code C++/ Atlas database to be released