

Technical note - Work of the *SOO* (the Orthopedics and Traumatology Society of Western France)

A new approach for endoscopicneurolysis of the supra-scapular nerve at the spinoglenoidnotch: a preliminary cadaver study

Marc-AlexandreLoirat M.D.¹²

MaximeTierny M.D.¹

AnthonyHervé M.D.¹

ArthurLignel M.D.¹

Eric Berton³

MickaëlRopars M.D., Ph.D.¹²³

HervéThomazeau M.D. ¹,

And the Orthopedics and Traumatology Society of Western France (*SOO*)⁴

Affiliations:

1Service de ChirurgieOrthopédique et Traumatologique, CHU Ponchaillou, Université de Rennes 1, 2 Rue Henri le Guilloux, 35033 Rennes, France.

2 Laboratoire M2S (Mouvement Sport Santé), Université Rennes 2 - EcoleNormaleSupérieure Bretagne-UniversitéEuropéenne de Bretagne, Campus de Ker Lann, Bruz, France

3 Laboratoire d'Anatomie, Université de Rennes 1, 2 Avenue du Professeur-Léon-Bernard, 35000 Rennes, France.

Corresponding author:

Marc-Alexandre Loirat, Service deChirurgieOrthopédique et Traumatologique, CHU Ponchaillou, Université de Rennes 1, 2 Rue Henri le Guilloux, 35033 Rennes, France.

E-mail: marc-alexandre.loirat@chu-rennes.fr

⁴ Article issued from the *SOO* (the Orthopedics and Traumatology Society of Western France)

Conflicts of interest:none

Abstract :**Introduction:**

The suprascapular nerve (SSN) can become compressed at its 2 scapular attachments: the suprascapular and the spinoglenoid notch. The objective of this study was to describe a new arthroscopic approach for SSN neurolysis at the spinoglenoid notch.

Method:

10 cadaver shoulders were used. Two were dissected to simulate the "classical" arthroscopic approach and to help in the creation of a new "direct medial retrospinal" approach. Eight other shoulders were used to validate this new approach, with control of the whole juxta-glenoid course of the SSN as criterion of success.

Results:

The retrospinal posterior approach allowed the entire juxta-glenoid segment of the SSN to be explored in 6 cases out of 8. One exploration was incomplete, another not feasible.

Conclusion:

SSN neurolysis at the spinoglenoid notch was feasible in cadavers on a retrospinal approach.

Key-words:

Nerve anatomy; shoulder arthroscopy; suprascapular nerve; decompression; spinoglenoid notch

INTRODUCTION

Suprascapular nerve (SSN) compression was first described by Thompson and Kopell(1)in 1959. It is implicated in 1-2% of cases of shoulder pain(2-5). Diagnosis has been improved by progress in MRI, enabling detection of early sign of neurogenic muscle injury (6). Neurolysis at the suprascapular (7)and spinoglenoid notches (8), however, is controversial. Treatment is now often arthroscopic. SSN compression may occur at 2 anatomic points in the scapula: at the suprascapular notch, due to the suprascapular ligament, and at the spinoglenoid notch, due to the spinoglenoid ligament. Neurolysis at the suprascapular notch is well codified; it was first described by Bhatia(9)in 2006, and satisfactory results were reported by Lafosse (10) in 2007. Neurolysis at the spinoglenoid notch, on the other hand, has been little studied (11-14);all reported techniques seem complex, which was the rationale behind the present study.

The study objective was to develop a simple approach to the spinoglenoid notch for SSN neurolysis, by dissection, and to confirm feasibility arthroscopically.

METHODS

Five fresh cadavers free of scapulohumeral region surgery or trauma were used (Rennes-1 University, Faculty of Medicine, Anatomy Laboratory). Mean age was 80.2 ± 12.9 years, with 4 out of 5 females (Table 1).

The first subject was used to dissect the shoulder to locate the SSN at the spinoglenoid notch. A wide superolateral approach was made, with release of the deltoid, supraspinatus and infraspinatus muscles (Fig. 1). Three combinations of viewing and instrumental portals were simulated to check feasibility with respect to bone structures. Digital photographs were taken. Feasibility of arthroscopy was then tested in 8 shoulders (4 cadavers) in semi-seated position, using an arthroscopy column, arthroscopy box, motorized shaver, radiofrequency electrocoagulation probe and arthropump. The column was equipped with a high-definition recording system for intraoperative photography and video.

- *Open surgery study:*

Three combinations of arthroscopic approach were simulated.

- The first was that most often used in shoulder arthroscopy, with a posterior viewing portal and anterior instrumental portal in the rotator interval (Fig. 2). This proved

unsuitable for SSN neurolysis, as the anterior instruments came up against the posterosuperior edge of the glenoid. The posterior viewing portal, however, was optimal for visualizing the spinoglenoid notch.

- The second combined the posterior viewing portal and a trans-tendon instrument portal (Fig. 2). The instrument approached the SSN, but was hindered by posterosuperior edge of the glenoid, allowing only vertical movement. This trans-tendon portal was used in Millet's technique (14), but with the instrumental and viewing portals inverted.
- The third combination, specific to this study, associated the usual posterior viewing portal to an extra-articular retrospinal instrumental portal (Fig. 2). This new approach gave direct access to the SSN at the spinoglenoid notch, without conflict with the scapular bone structures, notably the glenoid. The bone landmarks for the skin incision lay 15 mm perpendicularly posterior to the spine and 45 mm medially to the posterolateral angle of the acromion (Fig. 2). We therefore called it the "45/15 retrospinal approach", with reference to its posteromedial position and the measurements.

- Arthroscopic SSN neurolysis by the new "45/15 retrospinal approach"

The subject was in a semi-seated position. The arthroscope was introduced via the usual posterior portal. A lateral trans-tendon portal, as described by Millet (14), was performed. Location was by needle, at 45° to the posterior edge of the long head of the biceps tendon, with the needle passing in the axis of the supraspinatus fibers within the rotator crescent, without penetrating Burkhart's anteroposterior fibrous ring (15). This portal allowed posterior capsulotomy by radiofrequency probe between the 8 o'clock and 12 o'clock positions around the glenoid edge, sparing the labrum. The portal could be in conflict with the glenoid, as in combination 2 in subject 1; in that case, the objective was to create a work-space for the extracapsular retrospinal approach. The radiofrequency probe was then replaced by a blunt instrument introduced via the lateral trans-tendon portal to retract the soft tissue.

The retrospinal approach to the work-space was then performed using a needle introduced horizontally up to the scapular spine and slid downward into the work-space. It then guided the skin incision by an 11 blade then Kocher's forceps to complete the approach. The radiofrequency probe was introduced via the retrospinal portal, and release was

continued posteriorly in contact with the glenoid bone. The probe was used "back to the nerve" to protect the latter, and could thus be used for palpation to locate the spinoglenoid notch and the blunt instrument. The first item heralding discovery of the SSN was the suprascapular artery, which runs alongside then laterally. Neurolysis was performed by electrocoagulation of the spinoglenoid ligament and/or thickening of the supraspinatus fascia as described by Duparc(16) (fig. 3). Neurolysis was considered satisfactory when palpation could be pursued right around the neurovascular pedicle, with complete visualization of all the bone landmarks of the spinoglenoid notch.

RESULTS

The 2 "open" tests confirmed the inefficacy of combinations 1 and 2 for SSN neurolysis, whereas combination 3 appeared feasible. Six of the 8 arthroscopic tests of combination 3 were able to be completed (Table 2).

DISCUSSION

Neurolysis at the spinoglenoid notch is indicated for an isolated infraspinatus lesion showing as T2 hypersignal on MRI (17-19), involving only the infraspinatus, with no associated paralabral cyst. This is a rare situation, generally brought about by high-risk sports activity with iterative microtrauma (20-23).

SSN release at the spinoglenoid notch is rarely performed and thus less well described in the literature than neurolysis at the suprascapular notch; it is also more difficult technically. Ianotti and Ramsey(11) described an arthroscopic procedure, but for compression caused by a cyst in the spinoglenoid region. Romeo et al. (12) explored the SSN at both the suprascapular and spinoglenoid notches, on classical approaches, but once again for treatment of a paralabral cyst. Soubeyrand et al. (13) described an original extra-articular technique, with portals along the scapular spine and an arthroscopic work-space under the supraspinatus muscle, providing access to the suprascapular and spinoglenoid notches; the technique developed on cadavers was implemented on 3 patients, but without long-term assessment. It was Millet et al. (14) who described the viewing and instrumental portals through the supraspinatus tendon which inspired the present study.

The present approach was novel, and seemed easily reproducible. There was a single case of failure. The approach is comfortable for the operator, as arthroscope and instruments are

situated posteriorly, with about 60° triangulation between the instruments. Unlike in Millet et al.'s study(14), in which the arthroscope used the lateral trans-tendon portal, we used the posterior portal for viewing and the lateral trans-tendon portal for the instruments. In our preliminary arthroscopic test, Millet et al.'s configuration (14) was tried out, but the instrument was in conflict with the posterior edge of the glenoid, as in combination 2.

The main limitation of the present study is that it was exclusively a cadaver study, on a small number of elderly subjects, not representative of shoulders actually treated by SSN neurolysis. A particular problem thus arose in 1 case in which osteoarthritis prevented arthroscopy from the outset. Neurolysis quality was assessed only on anatomic criteria, by palpation around the neurovascular pedicle. The small number of subjects perhaps meant that other difficulties that may be associated with this approach were not encountered, notably variation in the "45/15" landmarks according to individual morphology, although these landmarks serve only to locate the incision site and it is the needle location that is essential.

The present study should be followed up by a clinical study of isolated decompression at the spinoglenoid notch.

CONCLUSION

This cadaver study confirmed the feasibility of complete SSN neurolysis at the spinoglenoid notch, avoiding all bone obstacles, using 2 posterior portals including a so-called "45/15" medial retrospinal portal.

References:

1. Thompson WA, Kopell HP. Peripheral entrapment neuropathies of the upper extremity. *The New England Journal of Medicine*. 1959;260(25):1261-5.
2. Clavert P, Thomazeau H. Peri-articular suprascapular neuropathy. *Orthopaedics & Traumatology, Surgery & Research : OTSR*. 2014;100(8 Suppl):S409-11.
3. Kannan U, Kannan NS, Anbalagan J, Rao S. Morphometric study of suprascapular notch in Indian dry scapulae with specific reference to the incidence of completely ossified superior transverse scapular ligament. *Journal of Clinical and Diagnostic Research : JCDR*. 2014;8(3):7-10.
4. Lichtenberg S, Habermeyer P. Nerve compression syndrome of the shoulder: Arthroscopic decompression procedures. *Der Orthopade*. 2011;40(1):70-8.
5. Zehetgruber H, Noske H, Lang T, Wurnig C. Suprascapular nerve entrapment. A meta-analysis. *International Orthopaedics*. 2002;26(6):339-43.
6. Ludig T, Walter F, Chapuis D, Mole D, Roland J, Blum A. MR imaging evaluation of suprascapular nerve entrapment. *European Radiology*. 2001;11(11):2161-9.
7. Collin P, Abdullah A, Kherad O, Gain S, Denard PJ, Ladermann A. Prospective evaluation of clinical and radiologic factors predicting return to activity within 6 months after arthroscopic rotator cuff repair. *Journal of Shoulder and Elbow Surgery*. 2015;24(3):439-45.
8. Schroder CP, Skare O, Stiris M, Gjengedal E, Uppheim G, Brox JI. Treatment of labral tears with associated spinoglenoid cysts without cyst decompression. *The Journal of Bone and Joint Surgery, American volume*. 2008;90(3):523-30.
9. Bhatia DN, de Beer JF, van Rooyen KS, du Toit DF. Arthroscopic suprascapular nerve decompression at the suprascapular notch. *Arthroscopy*. 2006;22(9):1009-13.
10. Lafosse L, Tomasi A, Corbett S, Baier G, Willems K, Gobezie R. Arthroscopic release of suprascapular nerve entrapment at the suprascapular notch: technique and preliminary results. *Arthroscopy*. 2007;23(1):34-42.
11. Iannotti JP, Ramsey ML. Arthroscopic decompression of a ganglion cyst causing suprascapular nerve compression. *Arthroscopy*. 1996;12(6):739-45.
12. Romeo AA, Ghodadra NS, Salata MJ, Provencher MT. Arthroscopic suprascapular nerve decompression: indications and surgical technique. *Journal of Shoulder and Elbow Surgery*. 2010;19(2 Suppl):118-23.
13. Soubeyrand M, Bauer T, Billot N, Lortat-Jacob A, Gicquelet R, Hardy P. Original portals for arthroscopic decompression of the suprascapular nerve: an anatomic study. *Journal of Shoulder and Elbow Surgery*. 2008;17(4):616-23.
14. Millet PJ, Barton RS, Pacheco IH, Gobezie R. Suprascapular Nerve Entrapment: Technique for Arthroscopic Release. *Techniques in Shoulder and Elbow Surgery*. 2006;7(2):000-.
15. Burkhart SS, Esch JC, Jolson RS. The rotator crescent and rotator cable: an anatomic description of the shoulder's "suspension bridge". *Arthroscopy*. 1993;9(6):611-6.
16. Duparc F, Coquerel D, Ozeel J, Noyon M, Gerometta A, Michot C. Anatomical basis of the suprascapular nerve entrapment, and clinical relevance of the supraspinatus fascia. *Surgical and Radiologic Anatomy: SRA*. 2010;32(3):277-84.
17. Beeler S, Ek ET, Gerber C. A comparative analysis of fatty infiltration and muscle atrophy in patients with chronic rotator cuff tears and suprascapular neuropathy. *Journal of Shoulder and Elbow Surgery*. 2013;22(11):1537-46.
18. Kamath S, Venkatanarasimha N, Walsh MA, Hughes PM. MRI appearance of muscle denervation. *Skeletal Radiology*. 2008;37(5):397-404.

19. Kim SJ, Hong SH, Jun WS, Choi JY, Myung JS, Jacobson JA, et al. MR imaging mapping of skeletal muscle denervation in entrapment and compressive neuropathies. *Radiographics*. 2011;31(2):319-32.
20. Ferretti A, Cerullo G, Russo G. Suprascapular neuropathy in volleyball players. *The Journal of Bone and Joint Surgery, American volume*. 1987;69(2):260-3.
21. Ferretti A, De Carli A, Fontana M. Injury of the suprascapular nerve at the spinoglenoid notch. The natural history of infraspinatus atrophy in volleyball players. *The American Journal of Sports Medicine*. 1998;26(6):759-63.
22. Lajtai G, Pfirrmann CW, Aitzetmuller G, Pirkel C, Gerber C, Jost B. The shoulders of professional beach volleyball players: high prevalence of infraspinatus muscle atrophy. *The American Journal of Sports Medicine*. 2009;37(7):1375-83.
23. Plancher KD, Peterson RK, Johnston JC, Luke TA. The spinoglenoid ligament. Anatomy, morphology, and histological findings. *The Journal of Bone and Joint Surgery, American volume*. 2005;87(2):361-5.

Figure legends

Figure 1: Posterior view of left spinoglenoid notch in subject 1.

Figure 2: Left to right and top to bottom. 1st combination: posterior optical and anterior instrumental portals. 2nd combination: posterior optical and lateral instrumental portals. 3rd combination: posterior optical and retrospinal instrumental portals. Bone landmark 45 mm from posterolateral acromion edge. "No-entry" sign indicates access to spinoglenoid notch prevented by impingement with posterior glenoid edge. Blue arrows show possible movements in spinoglenoid notch. (Inst: instrumental; Opt: optical; SN: spinoglenoid notch; G: glenoid; A: acromion; S: spine)

Figure 3: Suprascapular nerve release in spinoglenoid notch on retrospinal approach. (N, A: suprascapular nerve and artery, respectively; SN: spinoglenoid notch; G: glenoid; S: spine; L: spinoglenoid ligament).

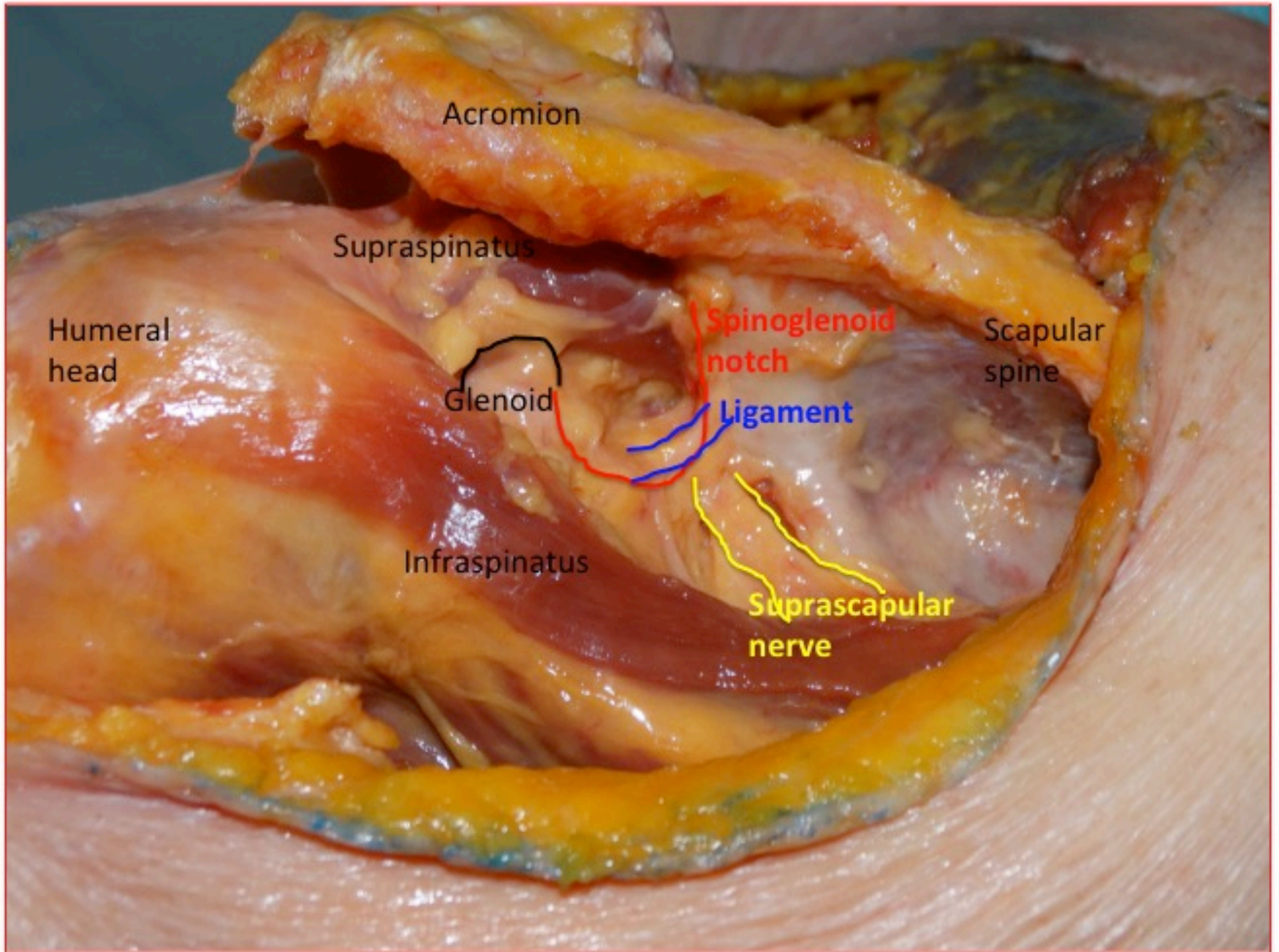
Accepted Manuscript

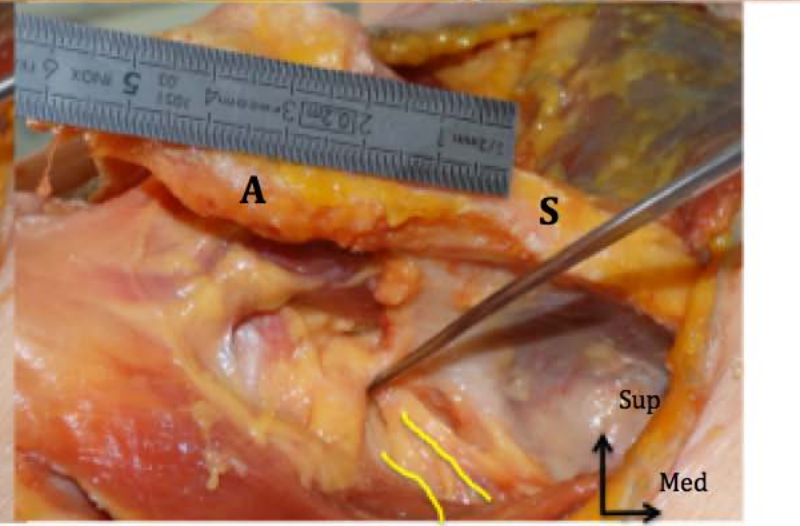
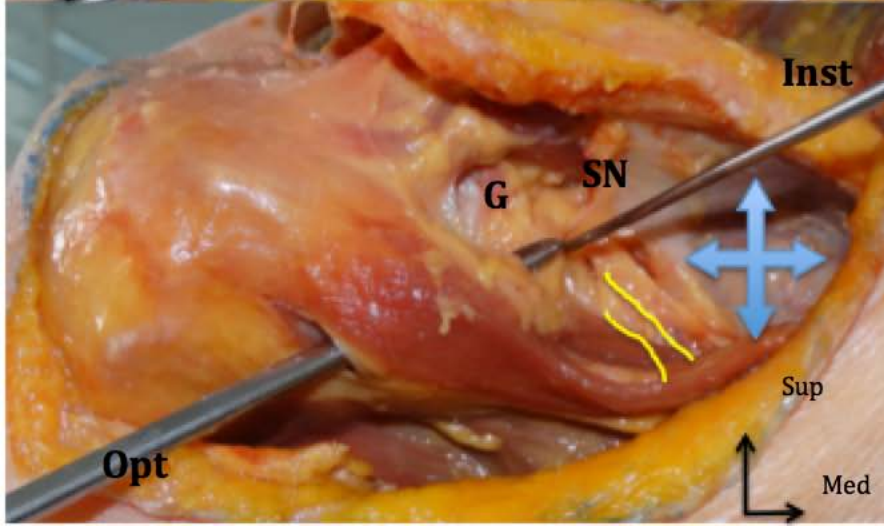
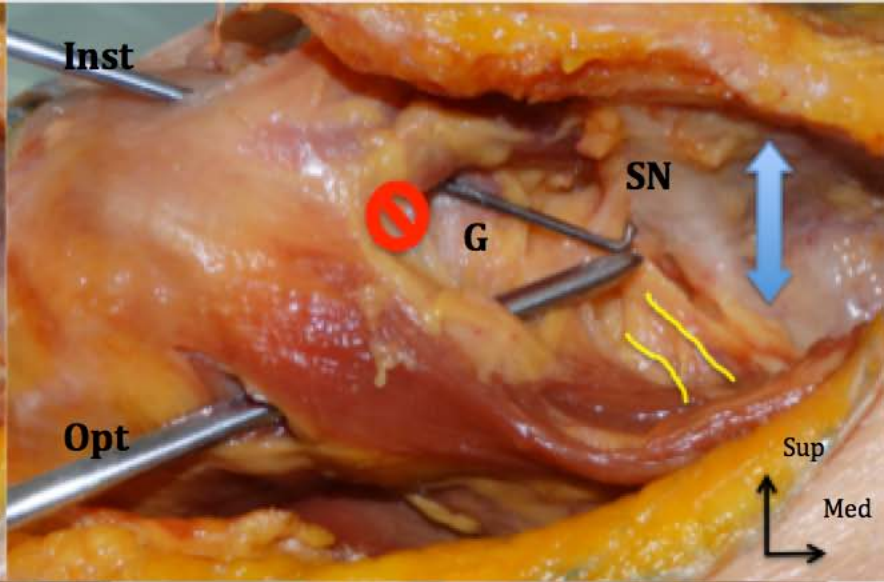
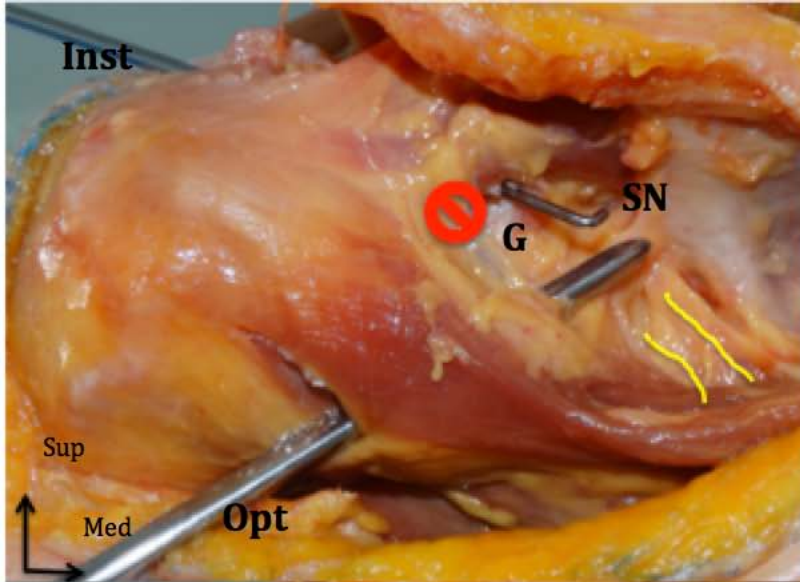
Table 1: Subject characteristics and manipulations

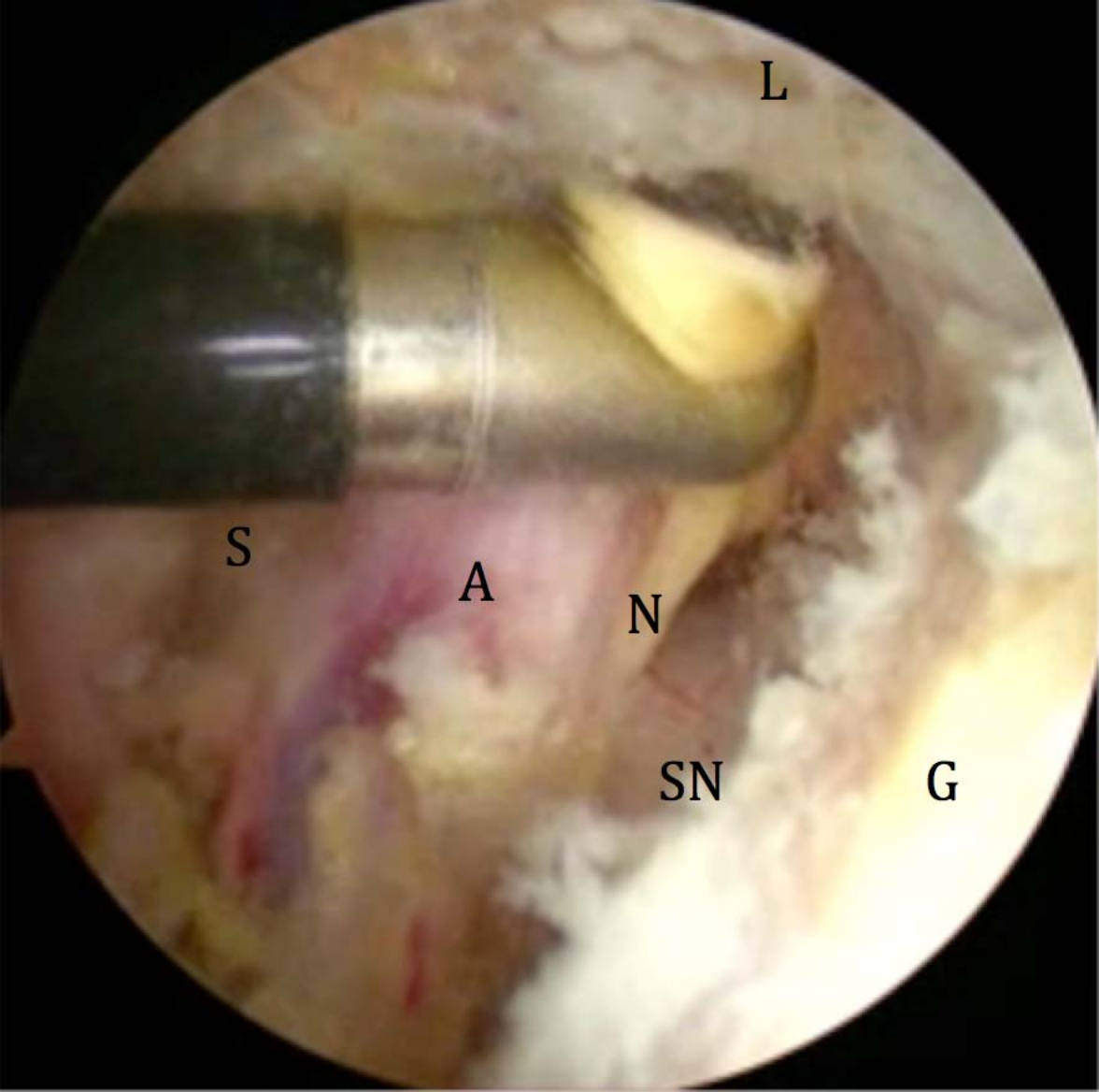
	Gender	Age (years)	Manipulation
Subject 1	Female	92	Dissection
Subject 2	Female	88	Arthroscopy
Subject 3	Male	63	Arthroscopy
Subject 4	Female	88	Arthroscopy
Subject 5	Female	70	Arthroscopy

Table 2: Results of arthroscopic neurolysis

	Subject	Side	Neurolysis (1) / Failure (0)	Remarks
Shoulder1	2	Right	1	
Shoulder2	2	Left	0	Eccentric severe glenohumeral osteoarthritis : arthroscopy not possible
Shoulder3	3	left	1	
Shoulder4	3	Right	0	Misuse of blunt retractor, visualization of the nerve but neurolysis not performed
Shoulder5	4	Right	1	
Shoulder6	4	Left	1	
Shoulder7	5	Right	1	
Shoulder8	6	Left	1	Suprascapular artery sectioning







L

S

A

N

SN

G