HAL
open science

Fetal anomalies associated with HNF1B mutations: report of 20 autopsy cases

Hélène Duval, Laurence Michel-Calemard, Marie Gonzales, Philippe Loget, Claire Beneteau, Annie Buenerd, Madeleine Joubert, Marielee Denis-Musquer, Alix Clemenson, Anne-Laure Chesnais, et al.

To cite this version:

Hélène Duval, Laurence Michel-Calemard, Marie Gonzales, Philippe Loget, Claire Beneteau, et al.. Fetal anomalies associated with HNF1B mutations: report of 20 autopsy cases. Prenatal Diagnosis, 2016, 36, pp.744-751. 10.1002/pd.4858 . hal-01494111

HAL Id: hal-01494111

https://univ-rennes.hal.science/hal-01494111

Submitted on 25 Sep 2017

HAL is a multi-disciplinary open access archive for the deposit and dissemination of scientific research documents, whether they are published or not. The documents may come from teaching and research institutions in France or abroad, or from public or private research centers.

L'archive ouverte pluridisciplinaire **HAL**, est destinée au dépôt et à la diffusion de documents scientifiques de niveau recherche, publiés ou non, émanant des établissements d'enseignement et de recherche français ou étrangers, des laboratoires publics ou privés.

Original article - Title Page

Title: **Fetal anomalies associated with *HNF1B* mutations: report of 20 autopsy cases**

Running head: Prenatal pathological findings of renal cysts and diabetes syndrome

Word count: manuscript: 2382, abstract: 153, bulleted statement: 65

1 table & 2 figures

Names of authors:

Duval Hélène [1,2], Michel-Calemard Laurence [3], Gonzales Marie [2,4], Loget Philippe [2,5], Beneteau Claire [6], Buenerd Annie [2,7], Joubert Madeleine [2,8], Denis-Musquer Marie[8], Clemenson Alix [2,9], Chesnais Anne-Laure [2,10], Blesson Sophie [2,11], De Pinieux Isabelle [12], Delezoide Anne-Lise [2,13], Bonyhay Gheorghe [14], Bellanné-Chantelot Christine [14], Heidet Laurence [15], Dupré Florence [1], Collardeau-Frachon Sophie [2,7,16].

Names of institutions

1. Service de Pathologie, Centre Hospitalier Princesse Grace, Monaco

2. SOFFOET, Société Française de Fœtopathologie, France

3. Service d'Endocrinologie Moléculaire et Maladies Rares, Centre de Biologie et Pathologie Est, BRON, France

4. Service de Génétique et d'Embryologie Médicales, Hôpital Armand Trousseau, APHP, UPMC, France

5. Laboratoire d'Anatomie et de Cytologie Pathologiques, Hôpital Pontchaillou, Rennes, France

6. Service de Génétique Médicale, CHU de Nantes, Institut de Biologie, Nantes, France

7. Centre de pathologie Est, Hôpital Femme-Mère-Enfant, Groupement Hospitalier Est, Hospices Civils de Lyon, Lyon, France

8. Service d'Anatomie Pathologique, CHU Hôtel Dieu, Nantes, France

9. Service d'Anatomie et Cytologie Pathologiques, CHU Saint-Etienne, Saint-Etienne, France

Accepted Article

10. Laboratoire d'Anatomie Pathologique-Neuropathologique, Hôpital de la Timone, Marseille, France

11. Service de Génétique, Centre Olympes de Gouges, CHRU de Tours, Hôpital Bretonneau, Tours, France

12. Cabinet de Pathologie Léonard de Vinci Chambray Les Tours, France

13 Service de Biologie du Développement, Hôpital Robert Debré, APHP, Université Paris Diderot, France

14. Département de Génétique, Université Pierre et Marie Curie, Paris, France

15. Centre de Référence des Maladies Rénales Héréditaires de l'Enfant et de l'Adulte (MARHEA), Hôpital Necker, AP-HP Paris, France

16. Université Claude Bernard Lyon 1, Lyon, France

Corresponding author: Dr Hélène Duval. Service de Pathologie, Centre Hospitalier Princesse Grace, avenue Pasteur, 98000 MONACO

Telephone number: +377 97 98 98 33

E-mail: helene.duval@chpg.mc

No funding sources supported the work.

All authors of this article have no conflict of interest.

All parents gave their consent for genetic'studies, autopsy and inclusion of the case in this study.

Bulleted statements :

HNF1B mutations are associated with congenital anomalies of the kidney and urinary tract, pancreatic hypoplasia and genital malformations, but few data about frequency and microscopic anomalies in fetuses.

Accepted Article

Our retrospective study of twenty fetal autopsies, the largest fetal cohort to date, describes all macroscopic and microscopic abnormalities encountered in this syndrome, their frequency. It also discusses genotype/phenotype correlations, and makes a comparison to literature data.

Abstract:

Objective: To describe macroscopic and microscopic anomalies present in fetuses carrying *HNF1B* mutation, their frequency, genotype/phenotype correlations.

Methods: Clinical data, ultrasound findings, genetic studies and autopsy reports of 20 fetal autopsies were analysed. Histology was reviewed by two pathologists.

Results: Macroscopic findings were typically unilateral or bilateral renal enlargement and cortical cysts. Renal lesions were associated with congenital anomalies of the kidney and urinary tract (CAKUT) in 25% of cases. Microscopic renal anomalies were dominated by glomerulocystic kidney and renal dysplasia. Extra-renal manifestations such as pancreatic hypoplasia (75%) and genital anomalies (68%) were only detected at autopsy. In 40% of cases, there was heterozygous deletion of the whole gene. There were *de novo* mutations in 40%.

Conclusion: This study underlines the importance of considering *HNF1B* mutations in fetuses with CAKUT, especially when associated with pancreatic hypoplasia. No correlation between phenotype and genotype was found, highlighting high intra-familial variability in cases with inherited mutations.

Accepted Article

Introduction

Mutations of *HNF1B (*Hepatocyte Nuclear Factor-1 β gene formerly called *TCF2*) on chromosome 17q21.3 are responsible of the Renal Cysts and Diabetes Syndrome (RCAD, OMIM 137920) characterized by an autosomal dominant inheritance. Mutations of *HNF1B* were first described in the maturity onset diabetes of the young type 5 (MODY5), a monogenic form of diabetes with a primary defect of insulin secretion [1]. Extra-pancreatic manifestations involving the kidneys, the liver and the genital tract are frequently observed because of expression of HNF1B in these organs [2, 3]. The spectrum of renal manifestations is large and includes renal cysts, glomerular tufts, aberrant nephrogenesis, primitive tubules, irregular collecting systems, oligomeganephronia, hypoplastic glomerulocystic kidney disease, renal malformations such as single kidney, enlarged renal pelvises, abnormal calyces, small kidney, horseshoe kidney, and hyperuricemic nephropathy [2-5]. The renal anomalies observed in the RCAD syndrome are part of a spectrum of malformations known as congenital anomalies of the kidney and urinary tract (CAKUT) [6] . *HNF1B* mutations are responsible for ~10% of CAKUT cases both in children and in adults[7]. Affected individuals may also have anomalies of the genital tract, especially females, including vaginal aplasia, rudimentary or bicornuate uterus. Epididymal cysts and atresia of the vas deferens have been described in males[2-4, 7-9]. Indeed, *HNF1B* plays a crucial role in early development and is involved in organogenesis of several tissues, such as kidney, pancreas, liver and gut, thus explaining the phenotype [10]. The prevalence of HNF1B mutations was 31% in a pediatric cohort reported by Ulinski *et al* [11] including children with anomalies of the kidneys, bilateral or not, but without diabetes. In terms of prenatal anomalies associated to HNF1B mutations, Decramer *et al* [12] reported *HNF1B* mutations in 29% of_cases with hyperechogenic kidneys with or without cysts detected on prenatal ultrasounds. Severe pancreatic hypoplasia, anomalies of the kidney and the urinary tract and genital malformations have also been

Accepted Article

described in fetuses with *HNF1B* mutations. However few data about the frequency of certain associations and microscopic anomalies are reported [13-16]. The aims of our retrospective study of twenty cases of fetal autopsy with *HNF1B* mutations were: to describe all macroscopic and microscopic features of fetuses with *HNF1B* mutations, to assess their frequency, genotype/phenotype correlations and to compare to findings in the literature.

Materials and methods

A call for collaboration was launched among the French Society of Fetal Pathology (SOFFOET, Société Française de Fœtopathologie) to collect data on all fetuses with *HNF1B* mutations. All parents gave their consent for genetic studies, autopsy and inclusion of the cases in this study. For each case, family and fetal data were collected from medical and autopsy reports and all available slides were reviewed independently by two pathologists.

The following data were retrieved: family history of diabetes and/or renal anomalies, ethnic origin, consanguinity, antenatal ultrasound findings (kidneys, pancreas and other anomalies), gestational age at termination of pregnancy or death and circumstances (spontaneous abortion, medical termination of pregnancy, stillbirth), sex, karyotype and fetal B2 microglobulinemia.

Gross anomalies on fetal examination were characterized with specific attention to renal weight and anomalies (agenesis, hypoplasia, cysts, uni or bilateral, symmetrical pattern or not), urinary and genital tract (agenesis, hypoplasia, dilatation, duplicity), pancreas (weight, agenesis, hypoplastic segment: head, body or tail) and liver. Any other macroscopic anomalies were recorded.

Available slides were stained with Hematoxylin Phloxine Saffron (HPS). Fibrosis was assessed with Masson's trichrome staining. The following features on microscopic sections from the kidneys were evaluated: architecture (preserved or not), glomerular count,

Accepted Article

persistence of blastema above 35 weeks of gestation (GW), presence of cysts (glomerular or tubular-type) and their location (cortical or medullary, focal or diffuse), presence of renal dysplasia (primitive tubules surrounded by concentric rings of collagen with or without cartilaginous islands or other dysplastic elements), aspect of the interstitium (fibrosis, edema, inflammation) and aspect of the vessels. For the pancreas, we specially focused on fibrosis and aspects of the endocrine and the exocrine components (hypoplasia, cysts). The genital and urinary tracts were carefully examined as well as the gonads. Liver anomalies were also assessed, especially portal fibrosis and ductal plate anomalies. If any other lesions were detected they were also described.

Genomic DNA was extracted by standard procedures from frozen tissue (fetuses) and peripheral blood leukocytes (parents). *HNF1B* anomalies were screened by 1) looking for heterozygous gene deletion using MLPA (multiplex ligation-dependent probe amplification) (SALSA KIT P241) or quantitative multiplex PCR, 2) direct sequencing of the 9 coding exons.

Results

Twenty autopsies of fetuses carrying *HNF1B* mutations, performed between 1995 and 2012, were identified. All conceptions were from unrelated parents without history of consanguinity. Gestationnal age ranged between 16 and 40 weeks (GA) (average 27 GA). One case was stillborn and 19 underwent termination of pregnancy (TOP). Indications for TOP were severe oligohydramnios and renal anomalies and/or increased fetal Beta-2 microglobulinemia (cases 1, 2, 4, 6, 7, 11) reflecting a poor renal function. *HNF1B* mutation was detected before TOP in two cases because of previous index cases (cases 5 and 10).

The sex ratio was 1.2 (11 males and 9 females).

Prenatal ultrasound anomalies were mainly detected during the second trimester (Figures 1a,

Accepted Article

1c). Oligohydramnios occurred in 14 cases out of 20 (70%). Other anomalies were identified in 18 cases. Renal cysts were present in 15 cases (83%), unilateral renal enlargement in 3 cases and bilateral 9 cases (total of renal enlargement 67%). Hyperechogenic kidneys were mentioned in 8 cases (44%). No pancreatic or genital and urinary tract anomalies were seen on prenatal ultrasound. No other significant ultrasound anomalies were noted.

Family medical history was available in 14 cases. Chronic renal failure was noted in 6 families, occurring in one or more relatives. It was associated with diabetes in two relatives.

All results are summarized in Table 1.

Gross anatomical findings:

None had growth restriction. Anomalies suggestive of oligohydramnios_were noted in 18 fetuses (90%), including pulmonary hypoplasia in 4 cases, dysmorphic facies (Potter facies) in 16 cases, and arthrogryposis in 4 cases. Head circumference was at the 5th percentile in 3 cases and at the 95th percentile in 1 case. Brain examination was performed in 15 cases yet there was no mention of weight, mensuration or maturation anomalies including the 4 cases with either an increased or a decreased head circumference.

Gross findings of the kidneys were available in 17 cases. Unilateral left renal agenesis was noted in one case and bilateral hypoplastic kidneys, with a weight below 2SD, in two cases (Figure 1e). Twelve cases presented with larger kidneys (70.5%), unilateral in two (figure 1f) and bilateral in 10 cases (Figure 1h). A multicystic appearance was noted in 14 cases (82,3%), unilateral in two cases and bilateral in 12 cases. Cysts involved the renal cortex in all cases, and were described as translucent and of variable sizes. (Figures d,g,h,i).

Anomalies of the urinary tract were were noted in five cases (25%) and consisted in two cases in unilateral ureteral duplication, in two with unilateral dilated pelvis and two case with unilateral ureteropelvic junction obstruction with hydronephrosis (Figures 1b, 1e).

Accepted Article

Anomalies of the pancreas were seen in 15 cases (75 %), including two agenesis and 13 cases of hypoplasia: 12 with absence of the caudal portion and one case with an annular appearance (Figure 1j).

Genital tract anomalies occurred in 4 female fetuses out of 9 (44%) and consisted in a bicornuate uterus associated with vaginal atresia in one case (Figure 1k). No macroscopic genital anomalies were reported amongst male fetuses.

No other macroscopic anomalies were recorded.

Microscopic findings:

Microscopic renal anomalies were constant and dominated by glomerulocystic kidneys. All cases presented with at least 5% of cystic glomeruli, defined as urinary space dilatation greater than 2 or 3 times the normal size. Absence of cortico-medullar differentiation (loss of normal architecture) occurred in 65 %. Renal dysplasia, with primitive tubules was present in 13 cases (65%) and contained cartilaginous islets in 12 cases. No persistence of blastema was observed in cases aged of 35 GW or more. Bilateral renal microscopic anomalies were observed in all cases, with a symmetrical pattern in 15 cases (85%).

Renal anomalies were divided in 3 groups:

- group 1 (40%) (Figure 2a): glomerulocystic kidney with glomerular cysts only. No associated anomalies such as pyelocalyceal cavities dilatation or loss of corticomedullary differentiation were present in this group. Glomerular cysts involved the renal cortex and were most often of small size. A significant decreased number of nephrons were also observed in this group

- group 2 (35%) (Figures 2b, 2c): diffuse multicystic dysplasia characterized by large cysts widespread over the entire parenchyma involving both glomeruli and tubules, loss of corticomedullary differentiation and renal dysplasia. Some dysplastic tubules were lined by

Accepted Article

squamous epithelium. A mild inflammatory fibrous interstitium was interspersed between dysplastic elements and cysts. Vessels were often enlarged and lined by a thick wall.

- group 3 (25%) (Figure 2d): focal anomalies interspersed with preserved areas of the renal parenchyma. The abnormal areas were characterized by loss of corticomedullary differentiation, large glomerular and tubular cysts and renal dysplasia. Small glomerular cysts were sometimes present in the renal cortex of the preserved areas.

No significant microscopic anomaly was observed on examination of pancreas samples: neither fibrosis nor cyst or anomalies of the endocrine or the exocrine components.

Microscopic examination of the male genital tract revealed tubular ectasia of the epididymis in 9 cases out of 10 available samples (90 %) (Figure 2f).

Lesions suggestive of intrahepatic biliary fibroadenomatosis were observed in one case with a diffuse pattern (Figure 2e). They were characterized by expanded portal tracts with abnormal cystic and branched bile ducts at their vicinity. Minor anomalies of the ductal plate were noted in 3 other cases among the 19 liver available samples.

No microscopic anomalies were noted on examination of the other organs.

Genetic data and HNF1B molecular analysis:

The karyotype, available in 10 cases, was normal. A complete heterozygous gene deletion was identified in 8 fetuses, and a partial deletion of exons 5-9 was observed in one case. Heterozygous point mutations were noted in 11 fetuses (6 frameshift, 3 missense and 2 splicing mutations).

Parents were tested in 15 families. The mutations were inherited in 9 cases: 7 from the mother and 2 from the father. One of the inherited mutations was linked with a maternal somatic mosaicism. Four out of the six *de novo* mutations were complete deletions.

We did not find any relation between the genotype and phenotype.

Accepted Article

Discussion

The genetic data from this large cohort of fetuses with *HNF1B* mutations highlight the frequency of heterozygous deletions of the entire gene, which was 40% whereas it is more than two thirds described in the pediatric literature[10, 17].

The prevalence of *de novo* mutations varies from 25 to 59% in the literature [4, 10] and it was 40 % in our study. The majority of maternal inheritance in our series seemed to be by chance, as it has never been reported in previous studies.

In the series of Decramer *et al.*[12], *HNF1B* anomalies were present in 61% of cases with antenatal hyperechogenic cystic kidneys and renal cysts. The most frequent anomalies in our study were also renal cysts (83 % on prenatal ultrasound and 82.3% at autopsy), as well as enlargement of one or both kidneys (67 % on prenatal ultrasound and 70.5% at autopsy). However hyperechogenic kidneys were present in only 8 cases (44%), which is comparable to what was described by Raaijmaker *et al* [7].

Congenital anomalies of the kidney and urinary tract (CAKUT) are the most frequent developmental disorders. Raaijmakers *et al*[7] demonstrated that *HNF1B* mutations were responsible for 10% of CAKUT cases[7]. Indeed, mutations of *HNF1B, EYAl, SIX1, SALLl1* and *PAX2* are detected in 5-15 % of European children with non-syndromic CAKUT [18, 19]. Urinary tract anomalies were noted in 25% of our cases. *HNF1B* mutations must be systematically searched when facing a CAKUT phenotype.

Extra-renal manifestations including genital anomalies (68%) and pancreatic hypoplasia (75%) were frequent in our series but were only revealed at autopsy, as previously reported [13-16].

Pancreatic anomalies such as hypoplasia or agenesis, has to be systematically looked for when cystic or hyperechogenic kidneys or anomalies of urinary tract are detected. Conversly, such association should prompt testing for *HNF1B* mutations. *Hnf1b* was shown to be

Accepted Article

required for normal pancreas morphogenesis in mice, as a critical regulator of transcriptional network that controls specification, growth and differentiation of the embryonic pancreas[13, 20]. Genital tract anomalies were present in 44 % of our female cases highlighting the role of HNF1B in female genital tract development [2, 21]. Epididymal ectasia, present in 90 % of our male cases needs to be explored because of potential subfertility in males carrying *HNF1B* mutations.

Ductal plate anomalies were present in 21% of our liver samples, suggesting involvement of the primary cilium in some cases. Indeed, in the study of Coffinier *et* al[22], *Hnf1b* knocked out mice have ductopenia and bile duct dysplasia. Other studies showed that *Hnf1b* deficiency was associated with primary cilium anomalies in cholangiocytes and could manifest as a paucity of intra-hepatic bile ducts leading to cholestatic jaundice in some neonates [2, 3, 23, 24].

As previous studies, we did not find correlations between the phenotype and the genotype. This underlines high intra-familial variability in cases with inherited mutation, particularly with respect to severity of renal disease [2, 7, 11-16].

Conclusion

Our retrospective study on twenty fetuses with mutations in *HNF1B* allowed describing the prenatal phenotype of RCAD syndrome. Renal anomalies were present in all cases but variable (from small glomeruli cysts to complete renal architecture distortion with renal dysplasia), whereas pancreatic hypoplasia or agenesis were present in 75%. All extra-renal manifestations were systematically identified on autopsy. Associated anomalies of the urinary tract, defining CAKUT, were present in 25%. Extra-renal manifestations also included genital tract anomalies (68%) and liver anomalies (21%). *HNF1B* mutations should be looked for when discovering one or more of those anomalies at autopsy. There was no obvious correlation between the phenotype and genotype, underlining high intra-familial variability in this syndrome.

Accepted Article

Acknowledgements

We particularly thank the SOFFOET members (Société Française de Fœtopathologie) who provided most of the cases of this series, especially F Jossic, F Guimot, B Le Fiblec, H Le Guern, as well as all the geneticists implied in the follow-up of the families included in this study.

References

1- Horikawa Y, Iwasaki N, Hara M, *et al.* Mutation in hepatocyte nuclear factor-1 beta gene (TCF2) associated with MODY. Nat Genet. 1997;17:384-5.

2- Clissold RH, Hamilton AJ, Hattersley AT *et al.* HNF1B-associated renal and extra-renal disease - an expanding clinical spectrum. Nat Rev Nephrol.2015;11:102-12.

3- Bockenhauer D, Jaureguiberry G. HNF1B-associated clinical phenotypes: the kidney and beyond. Pediatr Nephrol. 2016;31(5):707-14.

4- Edgill EL, Binghal C, Ellard S, *et al.* Mutations in hepatocyte nuclear factor-1beta and their related phenotypes. J Med Genet.2006;43:84-90.

5- Owen K, Hattersley AT. Maturity-onset diabetes of the young: from clinical description to molecular genetic characterization. Best Pract Res Clin Endocrinol Metab.2001; 15(3):309-23.

6- Nakayama M, Nozu K, Goto Y, *et al.* HNF1B alterations associated with congenital anomalies of the kidney and urinary tract. Pediatr Nephrol. 2010;25(6):1073-9.

7- Raaijmakers A, Gorveleyn A, Devriendt K, *et al.* Criteria for HNF1B analysis in patients with congenital anomalies of kidney and urinary tract. Nephrol Dial Transplant. 2015;30:835-42.

8- Fajans SS, Bell GI, Polonsky KS. Molecular mechanisms and clinical pathophysiology of maturity-onset diabetes of the young. N Engl J Med. 2001;345(13):971-80.

Accepted Article

9- Bellanné-Chantelot C, Chauveau D, Gautier JF, *et al.* Clinical spectrum associated with hepatocyte nuclear factor-1beta mutations. Ann Intern Med. 2004;140(7):510-7.

10- Coffinier C, Barra J, Babinet C, *et al.* Expression of the vHNF1/HNF1beta homeoprotein gene during mouse organogenesis. Mech Dev.1999;89: 211-3.

11- Ulinski T, Lescure S, Beaufils S, *et al.* Renal phenotypes related to hepatocyte nuclear factore-1beta (TCF2) mutations in a pediatric cohort. J Am Soc Nephrol.2006; 17:497-503.

12- Decramer S, Parant O, Beaufils S, *et al.* Anomalies of the TCF2 gene are the main cause of fœtal bilateral hyperechogenic kydneys. J Am Soc Nephrol.2007;18:923-33.

13- Haumaitre C, Fabre M, Cormier S, *et al.* Severe pancreas hypoplasia and multicystic renal dysplasia in two human fetuses carrying novel HNF1β/MODY5 mutations. Hum Mol Genet.2006;15(15):2363-2375.

14- Rasmussen M, Ramsing M, Petersen OB, *et al.* A description of a fetal syndrome associated with HNF1β mutation and a wide intrafamilial disease variability. Am J Med Genet. 2013; part A 9999:1-5.

15- Madariaga L, Morinière V, Jeanpierre C, *et al.* Severe prenatal renal anomalies associated with mutations in HNF1B or PAX2 genes. Clin J Am Soc Nephrol. 2013;8(7):1179-87.

16- Body-Bechou D, Loget P, D'Herve D, *et al.* TCF2/HNF-1beta mutations: 3 cases of fetal severe pancreatic agenesis or hypoplasia and multicystic renal dysplasia. Prenat Diagn. 2014;34(1):90-3.

17- Chauveau D, Decramer S, Guigonis V, *et al.* Le spectre des maladies par mutations de TCF2 : de la période anténatale à l'âge adulte. Actualités néphrologiques.2007; 11:113-28.

18- Weber S, Morinière T, Knüppel T, *et al.* Prevalence of mutations in renal developmental

Accepted Article

genes in children with renal hypodysplasia: results of the ESCAPE study. J Am Soc Nephrol. 2006;17: 2864-70.

19- Yosypiv IV. Congenital anomalies of the kidney and urinary tract: a genetic disorder? Int J of Nephrol. 2012; 2012:909083.

20- Maestro MA, Cardalda C, Boj SF, *et al.* Distinct roles of HNF1β, HNF1α and HNF4α in regulating pancreas development, β-cell function and growth. Endocr dev. 2007;12:33-45.

21- Lindner TH, Njolstad PR, Horikawa Y, *et al.* A novel syndrome of diabetes mellitus and genital malformation associated with a partial deletion of the pseudo-POU domain of hepatocyte nuclear factor-1β. Hum Mol Genet. 1999;8(11):2001-8.

22- Coffinier C, Gresh L, Fiette L, *et al.* Bile system morphogenesis defects and liver dysfunctions upon targeted deletion of HNF-1β. Development. 2002;129:1829-38.

23- Roelandt P, Antoniou A, Libbrecht L, *et al.* HNF1β deficiency causes ciliary defects in human cholangiocytes. Hepatology.2012;56(3):1178-1181.

24- Beckers D, Bellané-Chantelot C, Maes M. Neonatal cholestatic jaundice as the first symptom of a mutation in the HNF-1β. J Pediatr. 2007;150:313-4.

Accepted Article

Figures legends:

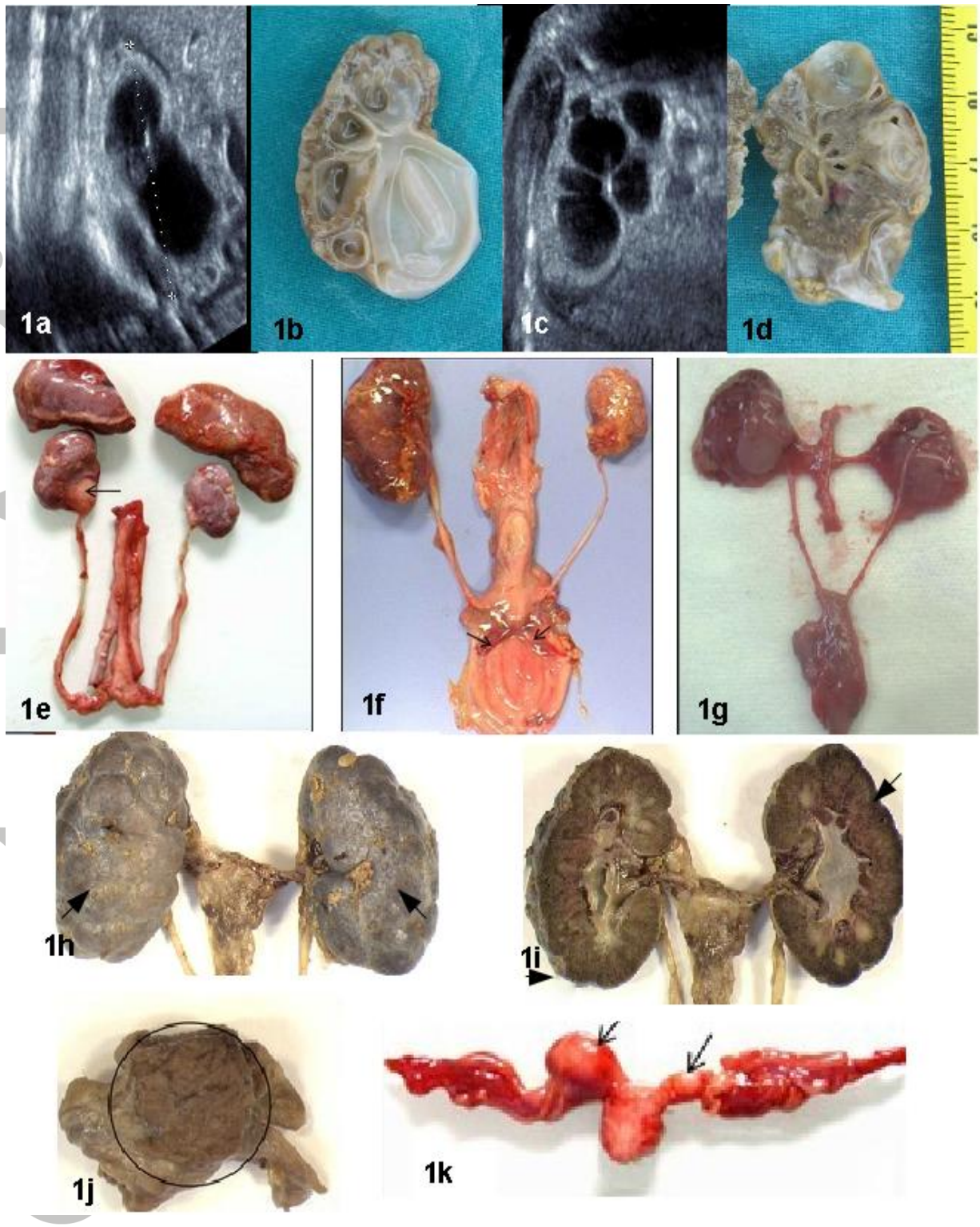

Figure 1 : prenatal ultrasound findings and macroscopic features.

1a: prenatal ultrasound (case number 6) : right dilated pelvis.

1b: cut section of the right kidney after formalin fixation (case number 6) : dilatation of the

renal pelvis and calyces (hydronephrosis).

1c: prenatal ultrasound (case number 6) : hyperechogenic and multicystic left kidney.

1d: cut section of the left kidney after formalin fixation (case number 6) : large cysts involving the renal cortex.

1e: macroscopic features of the kidneys and the urinary tract at autopsy of case number 2 : bilateral hypoplastic kidneys (compare to adrenals above) and right dilated pelvis (arrow).

1f: macroscopic features of the kidneys and the urinary tract at autopsy of case number 12 : right enlarged kidney and left hypoplastic kidney.

1g: macroscopic features of the kidneys and the urinary tract at autopsy of case number 16 : bilateral multicystic kidneys with large and translucent cysts.

1h: macroscopic features of the kidneys at autopsy of case number 3 : bilateral enlarged kidneys with small cysts (arrows) in the sub capsular area.

1i: cut section of the kidneys after formalin fixation (case number 3) : bilateral small cysts in the cortex and the sub capsular area (arrows).

1j: pancreatic hypoplasia with the absence of caudal segment (case number 12) : pancreas tissue is surrounded by a circle).

1k: bicornuated uterus (arrows) of case number 2.

Accepted Article

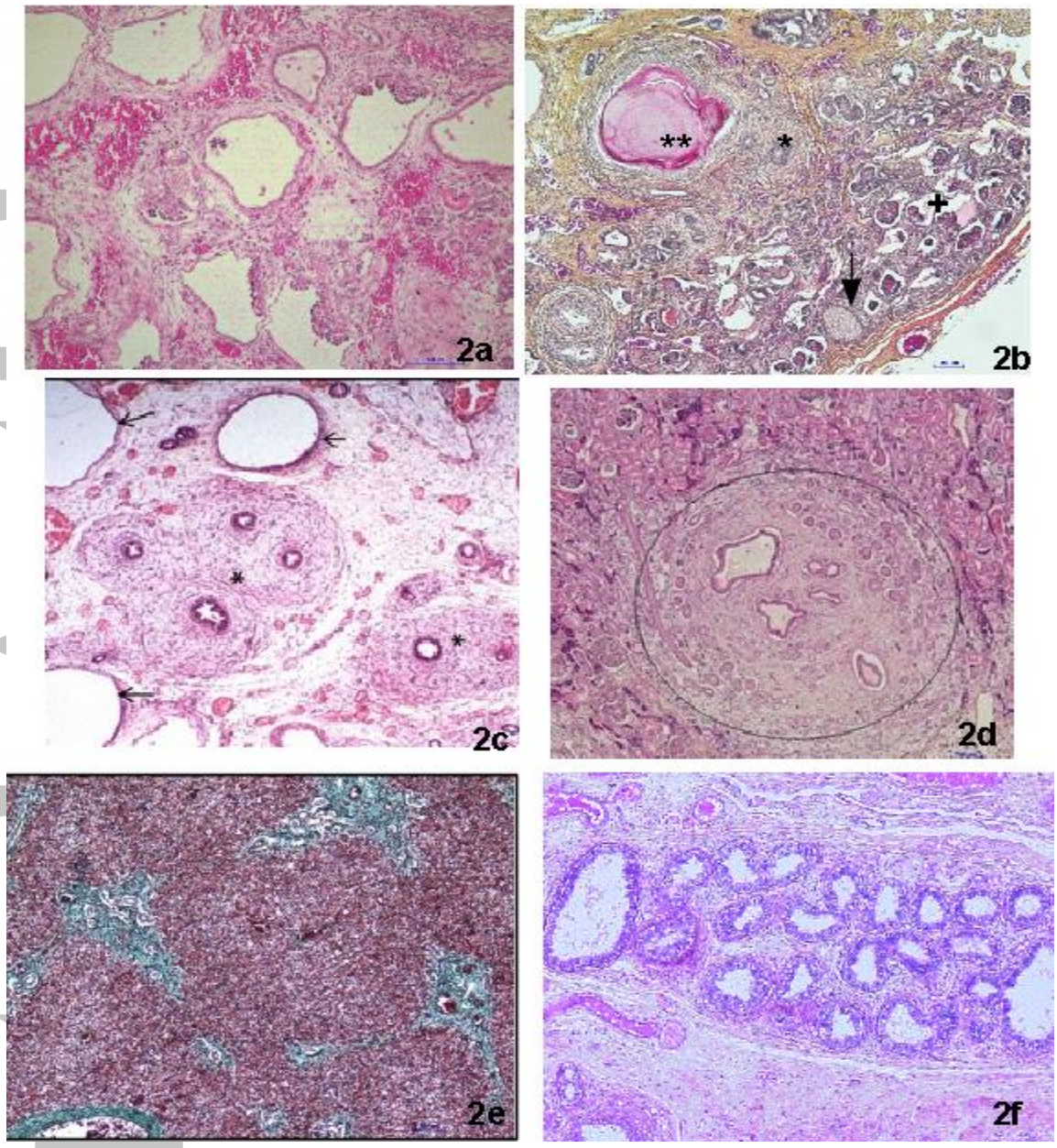

Figure 2 : microscopic anomalies.

2a: renal anomalies group 1 : glomerulocystic kidney (HPSx100, case number 3).
2b: renal anomalies group 2 : diffuse multicystic dysplasia : renal dysplasia with cartilage islet (arrow) and primitive tubules (*) surrounded by concentric fibrosis. Some of them are lined by squamous epithelium (**). Note also glomerular cysts (+) (HPS x 40).
2c: renal anomalies group 2 (case number 19) : other area with dilated tubules (arrows) and primitive dysplastic tubules (*) (HPSx40).
2d: renal anomalies group 3 : focal renal dysplasia (in the circle) surrounded by a preserved area of the renal parenchyma (case number 14, HPSx40).
2e: liver anomalies (case number 2) with diffuse liver fibroadenomatosis : enlarged and fibrous portal tracts (in green color) which contain numerous dilated and connected bile ducts (Masson trichrome x25).
2f: tubular epididymal ectasia : dilated tubules (arrows) (HPSx200).

cases	Gestational Age GW+Days	Sex	Family medical history	HNF1B Mutations	Inheritance	Prenatal US findings	OH sequence	Macroscopic renal anomalies	Group of microscopic renal anomalies	Urinary tract Anomalies	Pancreatic hypoplasia	Genital tract anomalies	Liver anomalies
1	28+1	F	Diabetes and CRF (grandfather, father), RC (brother)	Complete deletion	Paternal	OH,CK	DF	Bilateral C L : H	R 2 L 3	-	+	-	focal LBF
2	40+ 3 (stillborn)	F	RC (paternal grandfather)	c.1206+1G>C IVS5 - Splicing	unknown	OH, HK	DF, A, PH	Bilateral H	R&L 3	R dilated pelvis	+	Bicornuate uterus, vaginal atresia	diffuse LBF
3	35	M	RC (father, grandfather)	Complete deletion	De novo	CK, HK	-	Bilateral E & C	R&L 1	-	+	TEE	-
4	27	M	Unknown	c.335_342del, p.Arg112Glnfs*2 Exon 1 - Frameshift	De novo	CK	DF	Bilateral E & C	R&L 3	-	+	TEE	unknown
5	33+6	M	CRF (brother)	c.850del, p.His284Thrfs*43 Exon 4 - Frameshift	Maternal	CK, HK	DF	Bilateral C	R&L 1	-	+	TEE	-
6*♦	30+4	M	Unknown	c.840del, p.Ser281Profs*46 Exon 4 - Frameshift	unknown	CK, HK	DF, CF	Bilateral E & C	R&L 3	L ureteral duplication, R dilated pelvis	Agenesis	TEE	-
7*♦	35+5	M	No	c.827-G>A, p.Arg276Gln Exon 4 - Missense	De novo	OH, CK	DF	Bilateral C L : E	R 1 L 2	L ureteral duplication	+	TEE	-
8*♦	22+3	M	CRF and RC (father)	Exon 5 to 9 deletion Partial deletion	Paternal	OH, CK	DF, CF, PH	Bilateral E & C	R 3 L 2	-	Agenesis	TEE	-
9	34	F	Unknown	Complete deletion	De novo	CK	CF	no anomalies mentioned	R&L 1	-	-	-	-
10♦	22+3	F	Diabetes(mother) CRF (mother, maternal grandfather)	c.949del, p.Ala317Profs*10 Exon 4 - Frameshift	Maternal	OH, CK	DF	Bilateral E & C	R&L 2	-	-	-	-

Accepted Article

11	31	F	No	P472fsinsTGCAGCCC, p.Thr158Metfs*6 Exon 7 - Frameshift	unknown	CK, HK	-	Bilateral E & C	R&L 3	-	+	Bicornuate uterus	-
12	35+2	F	Unknown	Complete deletion	De novo	OH, CK, HK	PH	L : H R : E & C	R 2 L 3	-	+	Bicornuate uterus	
13♦	21	M	No	Complete deletion	unknown	OH, CK	DF	Bilateral E& C	R&L 2	-	+	-	focal LBF
14	23+3	F	No	c.1206+1G>A IVS5 - Splicing	unknown	OH, HK	DF, CF	Bilateral H& C	R&L 2	-	-	-	-
15	25+2	F	Unknown	Complete deletion	Maternal	OH	DF	L: agenesis R: C	R 2 L 3	-	+	Bicornuate uterus	-
16	24+3	F	CRF (father, no link)	c.517G>C, p.Val173Leu Exon 2 - Missense	Maternal	OH, CK	DF, A, PH	Bilateral E& C	R&L 2	-	-	-	-
17	22+3	M	No	c.493C>T, p.Arg165Cys Exon 2 - Missense	Maternal	OH	DF, A	no anomalies mentioned	R&L 1	Bilateral dilated pelvis	+	TEE	-
18	25	M	CRF (brother)	c.324_340del , - p.Glu109Glnfs*2 Exon 1 - Frameshift	Maternal mosaïcism	OH, CK, HK	DF	Bilateral E& C	R&L 3	R hydronephrosis	+ annular	TEE	focal LBF
19	22	M	Unknown	Complete deletion	unknown	OH, CK	DF, A	Bilateral E& C	R&L 2	-	+	TEE	-
20	16	M	No	Complete deletion	De novo	OH	DF, CF	no anomalies mentioned	R&L 1	-	-	unknown	-

Table 1: phenotype and genotype of *HNF1B* mutation carriers.
* Cases also reported by *Body Bechou et al.* ♦ Cases also reported by *Madariaga et al.*
Abbreviations: RC: renal cysts, CRF: chronic renal failure, DF: dysmorphic facies, A: arthrogryposis, CB: club foot, PH: pulmonary hypoplasia, E: enlargement, H: hypoplastic, C: cysts, TEE: tubular ectasia of the epididymis, LBF: liver biliary fibroadenomatosis, OH: oligohydramnios, HK: hyperechogenic kidneys, CK: cystic kidneys, R: right, L: left

Accepted Article