



HAL
open science

Scalp Tissue Expansion Above a Custom-Made Hydroxyapatite Cranial Implant to Correct Sequelar Alopecia on a Transposition Flap

R. Carloni, C. Herlin, B. Chaput, A. de Runz, E. Watier, N. Bertheuil

► **To cite this version:**

R. Carloni, C. Herlin, B. Chaput, A. de Runz, E. Watier, et al.. Scalp Tissue Expansion Above a Custom-Made Hydroxyapatite Cranial Implant to Correct Sequelar Alopecia on a Transposition Flap. World Neurosurgery, 2016, 95, pp.616.e1-616.e5. 10.1016/j.wneu.2016.08.116 . hal-01416158

HAL Id: hal-01416158

<https://univ-rennes.hal.science/hal-01416158>

Submitted on 28 Mar 2018

HAL is a multi-disciplinary open access archive for the deposit and dissemination of scientific research documents, whether they are published or not. The documents may come from teaching and research institutions in France or abroad, or from public or private research centers.

L'archive ouverte pluridisciplinaire **HAL**, est destinée au dépôt et à la diffusion de documents scientifiques de niveau recherche, publiés ou non, émanant des établissements d'enseignement et de recherche français ou étrangers, des laboratoires publics ou privés.

1 **Scalp tissue expansion above a custom-bone hydroxyapatite cranial implant to**
2 **correct sequelar alopecia on a transposition flap: a case report.**

3
4
5
6 Raphael Carloni, M.D.^{1,2,*}, Christian Herlin, M.D., Ph.D.³, Benoit Chaput, M.D.^{4,5}, Antoine De Runz,
7 M.D.^{6,7}, E. Watier, M.D., Ph.D.², Nicolas Bertheuil, MD.,^{2,8,9}

8
9
10
11 *1. Department of Plastic, Reconstructive and Aesthetic Surgery, Hospital Charles Nicolle, University of*
12 *Rouen, Rouen, France.*

13
14 *2. Department of Plastic, Reconstructive and Aesthetic Surgery, Hospital Sud, University of Rennes 1,*
15 *Rennes, France.*

16
17 *3. Department of Plastic Surgery and Burn Surgery, Hopital Lapeyronie, Montpellier University*
18 *Hospital, Montpellier, France.*

19
20 *4. STROMA lab, UMR5273 CNRS/UPS/EFS - INSERM U1031, Rangueil Hospital, Toulouse, France.*

21
22 *5. Department of Plastic, Reconstructive and Aesthetic Surgery, Rangueil Hospital, Paul Sabatier*
23 *University, Toulouse, France.*

24
25 *6. Department of Maxillofacial, Plastic, reconstructive and Cosmetic Surgery, Nancy University Hospital,*
26 *5400, Nancy, France.*

27
28 *7. EA 7299, ETHOS, Faculté de Médecine, Université de Lorraine, France.*

29
30
31 *8. INSERM U917, University of Rennes 1, Rennes, France.*

32
33 *9. SITI Laboratory, Etablissement Français du Sang Bretagne, Rennes University Hospital, Rennes,*
34 *France.*

35
36
37 *corresponding author:

38
39 Dr Raphael Carloni, MD.
40 Department of Plastic, Reconstructive and Aesthetic Surgery, Hospital Charles Nicolle, Rouen, France.
41 1 rue de Germont, 35200, Rouen
42 Phone: 00 33 2 32 88 80 63
43 Fax: 00 33 2 32 88 80 07
44 E-mail: raphaelcarloni@hotmail.com

45
46
47
48 **DISCLOSURE**

49 The authors have no financial interest to declare in relation to the content of this communication.

50
51 **Scalp tissue expansion above a custom-made hydroxyapatite cranial implant**
52 **to correct sequelar alopecia on a transposition flap: a case report**
53

54
55 **ABSTRACT**
56

57 **BACKGROUND:** Resection of cranial tumors involving both bone and scalp tissue may need
58 the recruitment of soft tissue using a flap above the bone reconstruction. When a transposition
59 flap has been chosen, the alopecia zone on the donor site may be difficult to treat afterwards.
60 Scalp expansion is the gold standard in these situations but has never been described above
61 cranial implants. We report the first case of a patient who underwent a scalp tissue expansion
62 above a custom-bone hydroxyapatite cranial implant to correct sequelar alopecia.
63

64 **CASE PRESENTATION:** A 30-year-old man presented with a dermatofibrosarcoma of the
65 scalp with bone invasion. A cranioplasty with a custom-made hydroxyapatite implant and a
66 transposition flap were performed. Although healing was achieved, the donor site of the
67 transposition flap left a 9x13 cm sequelar alopecia area on the vertex. To correct it, a rectangular
68 340 cc expander was partially placed above the cranial implant and under the transposition flap.
69 A second 120 cc expander was put on the contralateral temporal region. The expansion was
70 successful, with neither expander infection, nor cranial implant displacement, nor fracture on the
71 scans performed during the follow-up. Thanks to this procedure, the alopecia zone was entirely
72 excised. The patient was very satisfied about the cosmetic result.
73

74 **CONCLUSION:** Tissue expansion above hydroxyapatite implants may be of concern to the
75 physician because of the risk of infection and rupture of the cranial implant. With this clinical
76 case we aim to emphasize some precautions to prevent these issues.
77

78 **KEYWORDS:** cranioplasty; tissue expansion; alopecia; transposition flap; calvarial
79 reconstruction.
80

81 **MANUSCRIPT**

82

83 **INTRODUCTION**

84 Tissue expansion of the scalp is a well-codified technique used to improve success before
85 cranioplasty after previous infection, tissue avulsion, and/or radiotherapy,¹ and to correct sequelar
86 alopecia during second-step surgery.² The scalp is particularly suitable for expansion because the
87 cranial bone provides a solid basis for the expander. No data are available in the literature
88 regarding the safety of expansion above the implant when an alloplastic material (e.g.,
89 hydroxyapatite³, titanium⁴, methyl metacrylate⁵) is used to replace the cranial bone after
90 cranioplasty.

91 We present the case of a patient who underwent scalp tissue expansion above a custom-made
92 hydroxyapatite implant to correct sequelar alopecia after cranioplasty for dermatofibrosarcoma
93 protuberans.

94

95 **CASE REPORT**

96 This 30-year-old man had previously undergone a right temporo-frontal craniotomy for resection
97 of temporo-frontal dermatofibrosarcoma protuberans with bone invasion. Coverage of the dura
98 with a transposition flap and no bone reconstruction was performed at the same time. The donor
99 site of the flap, on the vertex, was covered with a skin graft, leaving a sequelar alopecia zone that
100 measured 9 × 13 cm (Fig. 1). Histological findings showed complete excision of the tumor.

101 Six months later, cranioplasty with a custom-made hydroxyapatite implant was decided on. An
102 incision at the medial edge of the transposition flap provided access to the cranial defect. A
103 rectangular periosteal flap was dissected over the cranial bone defect to expose the dura. Bony
104 edges were sharpened to expose healthy cancellous bone, and the implant was fixed on the bone
105 defect. Dural tenting sutures were performed on the edges of the defect to prevent epidural
106 hemorrhage after the surgery, by fixing dura to the native bone with silk sutures. The
107 postoperative course was free of complications. Although the reconstruction was successful,
108 sequelar alopecia on the vertex remained a major social, psychological, and esthetic concern for
109 the patient.

110 At 7 months after the cranioplasty, we decided to perform soft tissue expansion, with two smooth
111 rectangular expanders placed in the two temporal regions between the galea and the periosteum

112 through incisions placed at the lateral edges of the alopecia area of the vertex; a 120-cc expander
113 was used on the left side and a 240-cc expander was used on the right side (Fig. 2). The expander
114 on the right side was partially placed above the cranial implant and under the previous
115 transposition flap. In both cases, filling reservoirs were internal, placed in the subcutaneous layer.
116 The expanders were filled with normal saline (90 cc on the right side, 40 cc on the left side) at the
117 end of the surgery. Two drains were inserted in the subgaleal pockets and kept in place until the
118 amount of drainage had decreased to 20 cc per day. Antibiotic prophylaxis (cefazolin, 2 g) was
119 administered intraoperatively. Healing was achieved in 15 days. The expanders were filled once
120 per week for 3 months postoperatively. The expanders on the right and left sides were inflated to
121 355 cc and 130 cc, respectively (Fig. 3). CT was performed before expander placement, 1 day
122 postoperatively, and at the end of the expansion to confirm the absence of fracture or dislocation
123 of the hydroxyapatite implant (Fig. 4). At 1 week after the last inflation, the expanders were
124 removed and two advancement flaps were used to remove the entire alopecic zone of the vertex
125 (Fig. 5). The galea was scored to allow further advancement. No complication occurred during
126 the expansion or postoperatively. The patient was very satisfied with the cosmetic result (Fig. 6).

127

128 **DISCUSSION**

129 The choice between autologous bone and alloplastic material for bone reconstruction in
130 cranioplasty remains under debate.⁶ Debate also exists concerning techniques for soft tissue
131 recruitment when tissue is lacking over the scalp.^{1,7,8} Among techniques, tissue expansion has
132 been demonstrated to be safe when performed over the cranial bone, either before the
133 cranioplasty procedure to increase the rate of success^{1,9} or after cranioplasty, away from the
134 implant, to correct sequellar alopecia.^{2,10} However, no application of this technique above a
135 cranial implant has been described, due to the supposed risk of the procedure. Through this case
136 report, we aimed to show that safe expansion is possible, even in situations in which the only
137 stretchable tissue is partially situated above a cranial implant.

138 Alopecia of the scalp after cranioplasty is a frequent complaint of patients. It can be created by
139 radiotherapy and infection prior to scalp reconstruction, or as a consequence of soft tissue
140 reconstruction with local or free flaps. Except for the rotational scalp flap, which does not cause
141 alopecia but can be used when only slight tissue recruitment is necessary,⁷ these flaps are often
142 unesthetic. For large tissue needs, the choice between flaps⁸ and tissue expansion¹ must be

143 discussed because both options have advantages and disadvantages. Based on our experience, we
144 recommend that scalp expansion be attempted first, except in situations in which an open wound
145 still exists or rapid coverage is necessary.¹¹ This choice allows the achievement of a more esthetic
146 reconstruction after the first surgery, providing natural hair-bearing skin to correct a tissue defect.
147 When large local flaps of the scalp, such as transposition flaps or bipediced flaps, have been
148 used in the first surgery, most of the hairy tissue lies above the cranial implant and the only
149 solution for the treatment of alopecia with expansion is to place an expander above the cranial
150 implant.

151 Hydroxyapatite implants have been demonstrated to have osteoconductive properties that lead to
152 good osteointegration with the cranial vault. In clinical practice, osteointegration can be checked
153 on cranial scans during patient follow up and is defined as the absence of a radiolucent line at the
154 interface between the living bone and the surface of the implant.³ The porous nature of the
155 implant is supposed to allow ingrowth of osteoprogenitor cells, and increased resistance of the
156 implant. Because hydroxyapatite has the same density as bone on CT scans, this process is
157 difficult to confirm and we cannot say that the implant acquires the same resistance as bone in the
158 months following cranioplasty. However, dislocation or fracture of the implant is very rare.^{12,13}
159 These properties allowed us to attempt expansion over this kind of implant, with a successful
160 outcome. Indeed, in our patient, the implant provided sufficient strength to support a 355-cc
161 expansion. The main condition to verify before expansion was osteointegration of the implant on
162 the preoperative scan.

163 The risk of infection associated with expansion, which could contaminate the underlying cranial
164 implant, was prevented by respecting some simple rules: (1) intraoperative administration of a
165 prophylactic antibiotic, (2) rapid drain removal, and (3) separation of the implant and the
166 expander by a periosteal flap during cranioplasty. No specific alloplastic material has been shown
167 to be more sensitive to infection in the literature.^{14,15} Estimated infection rates are 2% for
168 hydroxyapatite implants³ and 24% for expanders.¹⁶

169 Tissue expansion must be chosen only in situations in which the scalp has healed completely
170 because wounds could be the port of entry for bacteria, which could contaminate the expander.¹¹
171 When the scalp has not yet healed, waiting for complete healing with dressings or the choice of
172 another reconstructive method is preferable, with tissue expansion performed once healing is

173 achieved. Other reported complications of tissue expansion include exposure, rupture of the
174 expander, and hematoma.¹⁶

175 The choice of expander size depends on the size of the defect and the location of the alopecia
176 zone to treat. For round expanders, the tissue gain obtained with expansion corresponds
177 approximately to the radius of the expander.¹ For rectangular expanders, the gain is more difficult
178 to predict. For the present patient, we chose two rectangular expanders to expand the two
179 temporal regions. No difference in complications according to expander shape has been reported.
180 However, the use of fewer expanders seems to be associated with a lower frequency of
181 complications.^{7,17}

182 Expanders must be placed as high as possible on the scalp for two reasons: the higher temporal
183 regions and the vertex are easier to stretch, and such placement avoids the patient's sleeping on
184 the expanders during the night, thereby diminishing the risk of exposure.

185 Although the filling reservoir can be placed externally, placement under the skin is more
186 comfortable for the patient. Our expansion protocol did not differ from the protocols described in
187 the literature. In our case, we stopped expander inflation when the filled volume slightly
188 exceeded 150% of its capacity on the right side and 100% of capacity on the left side. Expanders
189 can be overinflated to 150% of their capacity to improve tissue gain.¹ Another option to improve
190 tissue gain consists of scoring of the galea. This procedure could compromise the perfusion of the
191 advancement flaps. Thus, we perform it only when necessary.

192 Other techniques described in the literature to correct sequelar alopecia of the scalp include
193 external tissue expansion¹⁸ and hair grafting in the alopecia zone.¹⁹ In our experience, the
194 outcome of hair grafting is very disappointing in large zones of scar tissue, but this technique can
195 be attempted in small zones, such as enlarged scars. Two possibilities exist in this situation.
196 When possible, a tricophytic technique should be attempted first.²⁰ When scar enlargement is
197 important, making a tricophytic suture difficult, or when a new suture in the area is risky for
198 healing reasons, a hair graft with follicular unit extraction¹⁹ should be attempted.

199 CONCLUSION

200 Tissue expansion remains the gold standard for the treatment of sequelar alopecia after
201 cranioplasty. This procedure may be of concern to the physician when performed above
202 hydroxyapatite implants because of the risk of infection and rupture of the cranial implant.
203 Precautions to prevent these issues include a preoperative check of the osteointegration of the

204 implant; a 6-month interval between cranioplasty and expansion; separation of the expander from
205 the implant using periosteum; antibiotic prophylaxis and rapid drain removal.

206

207 **DISCLOSURES**

208

209 The authors have no disclosures to declare.

210

211

212

213

214 **REFERENCES**

215

216

217

218 1. Carloni R, Hersant B, Bosc R, Le Guerinel C, Meningaud JP. Soft tissue expansion and
219 cranioplasty: For which indications? *J Cranio-Maxillo-fac Surg Off Publ Eur Assoc Cranio-*
Maxillo-fac Surg 2015;43:1409-1415.

220

221

222

223

224

225

226

227

228

229

230

231

232

233

234

235

2. Bilkay U, Kerem H, Ozek C, Erdem O, Songur E. Alopecia treatment with scalp expansion: some surgical fine points and a simple modification to improve the results. *J Craniofac Surg* 2004;15:758-765.
3. Stefani R, Esposito G, Zanotti B, Iaccarino C, Fontanella MM, Servadei F. Use of “custom made” porous hydroxyapatite implants for cranioplasty: postoperative analysis of complications in 1549 patients. *Surg Neurol Int* 2013;4:12.
4. Cabraja M, Klein M, Lehmann T-N. Long-term results following titanium cranioplasty of large skull defects. *Neurosurg Focus* 2009;26:E10.
5. Greene AK, Warren SM, McCarthy JG. Onlay frontal cranioplasty using wire reinforced methyl methacrylate. *J Cranio-Maxillo-fac Surg Off Publ Eur Assoc Cranio-Maxillo-fac Surg.* 2008;36:138-142.
6. Schwarz F, Dünisch P, Walter J, Sakr Y, Kalff R, Ewald C. Cranioplasty after decompressive craniectomy: is there a rationale for an initial artificial bone-substitute implant? A single-center experience after 631 procedures. *J Neurosurg* September 2015:1-6.
7. Leedy JE, Janis JE, Rohrich RJ. Reconstruction of acquired scalp defects: an algorithmic approach. *Plast Reconstr Surg* 2005;116:54e - 72e.

- 236 8. Fong AJ, Lemelman BT, Lam S, Kleiber GM, Reid RR, Gottlieb LJ. Reconstructive
237 approach to hostile cranioplasty: A review of the University of Chicago experience. *J Plast*
238 *Reconstr Aesthetic Surg JPRAS* 2015;68:1036-1043.
- 239 9. Merlino G, Carlucci S. Role of systematic scalp expansion before cranioplasty in patients
240 with craniectomy defects. *J Cranio-Maxillo-fac Surg Off Publ Eur Assoc Cranio-Maxillo-fac*
241 *Surg* 2015;43:1416-1421.
- 242 10. Azzolini A, Riberti C, Cavalca D. Skin expansion in head and neck reconstructive
243 surgery. *Plast Reconstr Surg* 1992;90:799-807.
- 244 11. Carloni R, Hersant B, Bosc R, Bertheuil N, Meningaud J-P. Re: "Reconstructive approach
245 to hostile cranioplasty: A review of the University of Chicago experience." *J Plast Reconstr*
246 *Aesthetic Surg JPRAS* 2015;68:1616-1617.
- 247 12. Lindner D, Schlothofer-Schumann K, Kern B-C, Marx O, Müns A, Meixensberger J.
248 Cranioplasty using custom-made hydroxyapatite versus titanium: a randomized clinical trial. *J*
249 *Neurosurg*. February 2016:1-9.
- 250 13. Iaccarino C, Viaroli E, Fricia M, Serchi E, Poli T, Servadei F. Preliminary Results of a
251 Prospective Study on Methods of Cranial Reconstruction. *J Oral Maxillofac Surg Off J Am Assoc*
252 *Oral Maxillofac Surg* 2015;73:2375-2378.
- 253 14. Yadla S, Campbell PG, Chitale R, Maltenfort MG, Jabbour P, Sharan AD. Effect of early
254 surgery, material, and method of flap preservation on cranioplasty infections: a systematic
255 review. *Neurosurgery* 2011;68:1124-1129.
- 256 15. Reddy S, Khalifian S, Flores JM, et al. Clinical outcomes in cranioplasty: risk factors and
257 choice of reconstructive material. *Plast Reconstr Surg* 2014;133:864-873.
- 258 16. Cunha MS, Nakamoto HA, Herson MR, Faes JC, Gemperli R, Ferreira MC. Tissue
259 expander complications in plastic surgery: a 10-year experience. *Rev Hosp Clínicas* 2002;57:93-
260 97.
- 261 17. Wang J, Huang X, Liu K, Gu B, Li Q. Complications in tissue expansion: an updated
262 retrospective analysis of risk factors. *Handchir Mikrochir Plast Chir Organ Deutschsprachigen*
263 *Arbeitsgemeinschaft Für Handchir Organ Deutschsprachigen Arbeitsgemeinschaft Für*
264 *Mikrochir Peripher Nerven Gefäße Organ Ver Dtsch Plast Chir* 2014;46:74-79.
- 265 18. Reinard KA, Zakaria HM, Qatanani A, Lee IY, Rock JP, Houin HP. Preoperative external
266 tissue expansion for complex cranial reconstructions. *J Neurosurg*. January 2016:1-8.

- 267 19. Harris JA. Follicular unit extraction. *Facial Plast Surg FPS* 2008;24:404-413.
268 20. Ahmad M. Does the trichophytic technique have any role in facial wound closure? A
269 hypothesis. *J Plast Reconstr Aesthetic Surg JPRAS* 2009;62:662.

270

271

272

273

274

275

276 **FIGURE LEGENDS**

277

278 **Figure 1.** Preoperative picture of the patient presenting with a sequelar alopecia of vertex after a
279 transposition flap of the scalp.

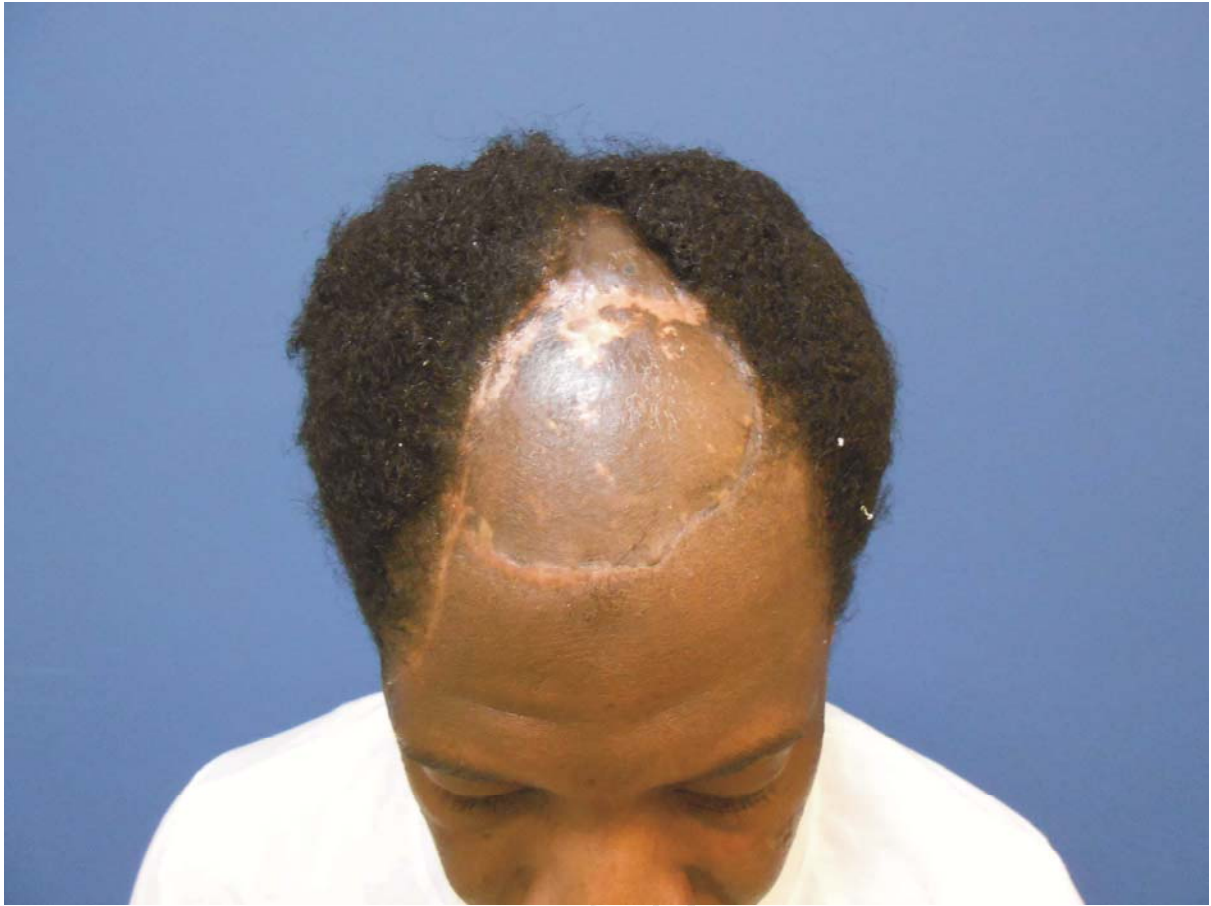280 **Figure 2.** Photo of the two rectangular expanders.

281 **Figure 3.** Picture of the patient after maximal inflation of the expanders.

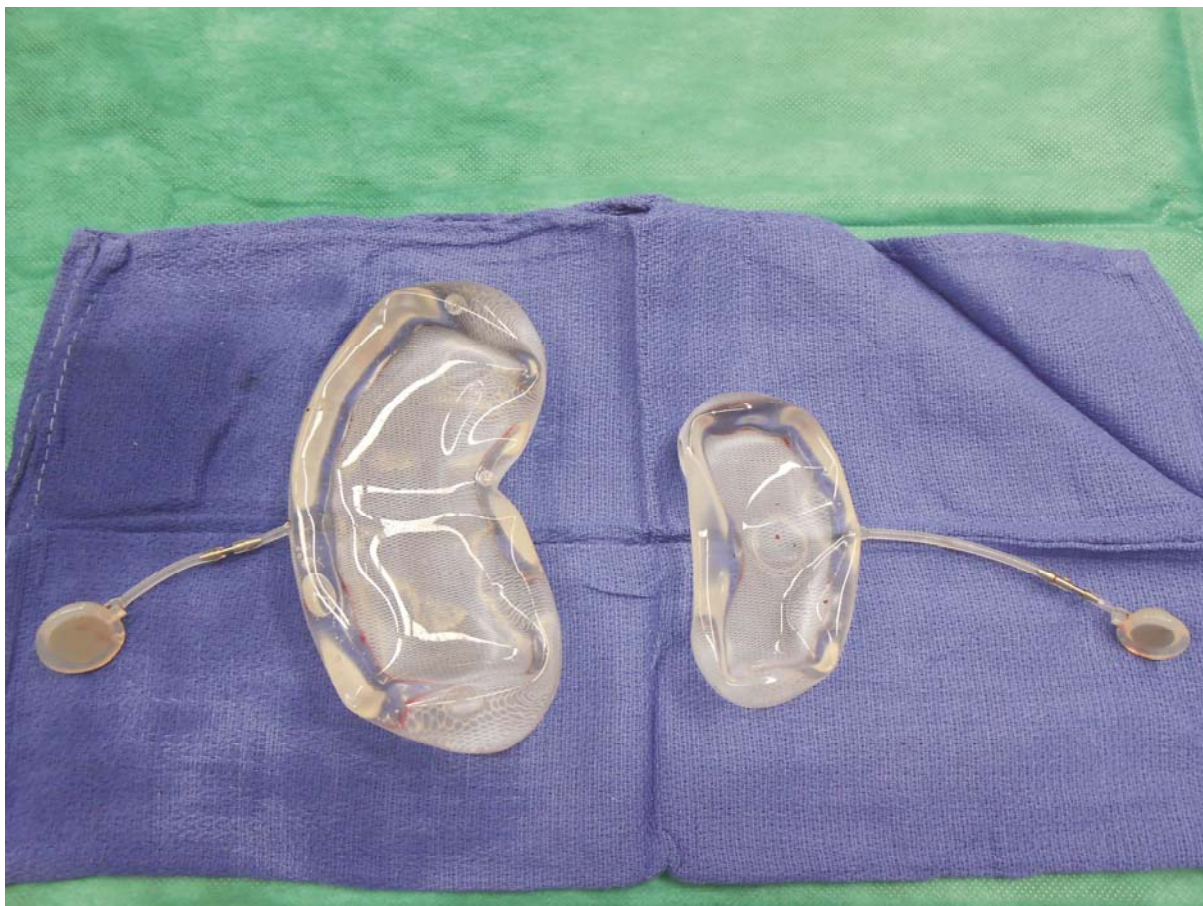282 **Figure 4.** Computed tomographic scan after maximal inflation of the expanders. The scan shows
283 an osteointegration of the hydroxyapatite implant and the absence of fracture or dislocation.

284 **Figure 5.** Intraoperative view after removal of the expanders.

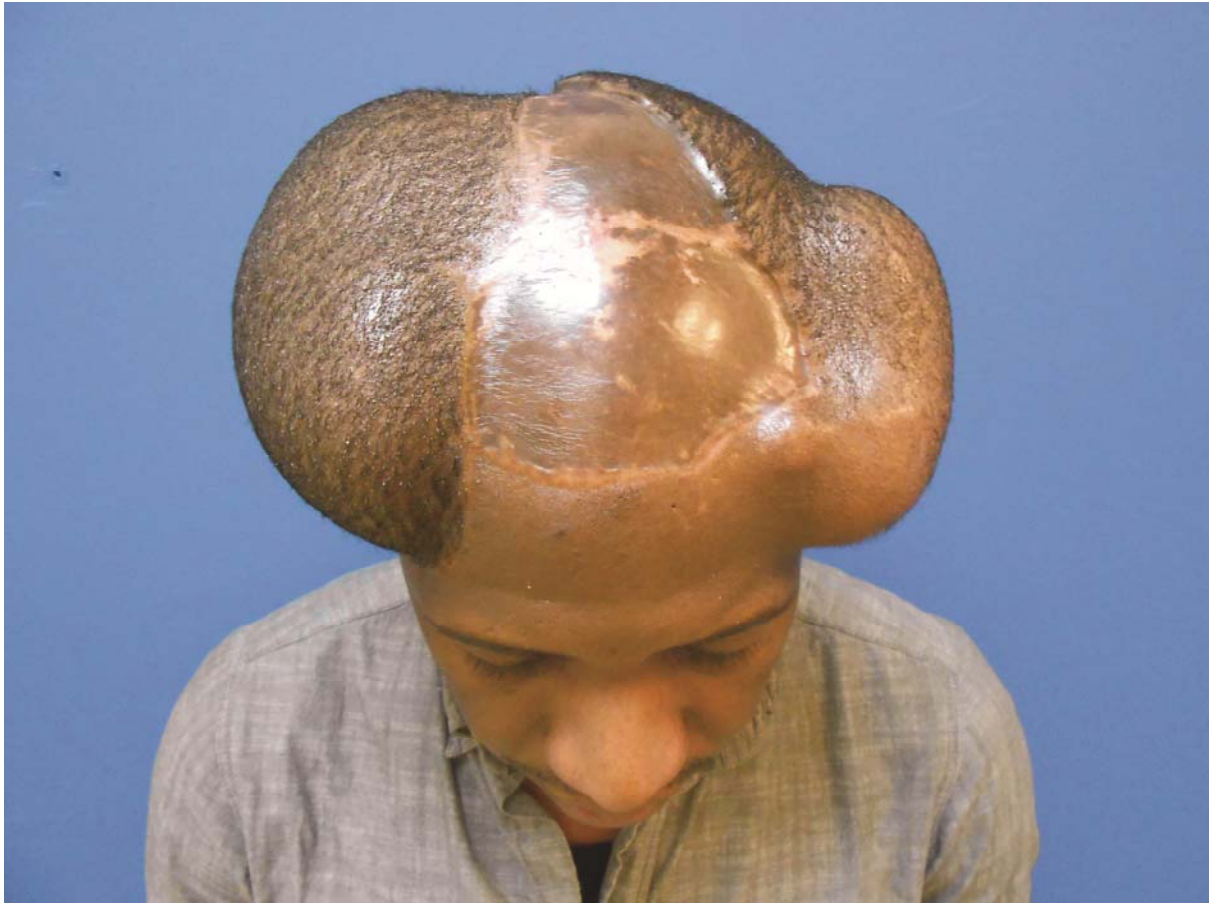285 **Figure 6.** Postoperative picture of the patient after correction of the alopecia.



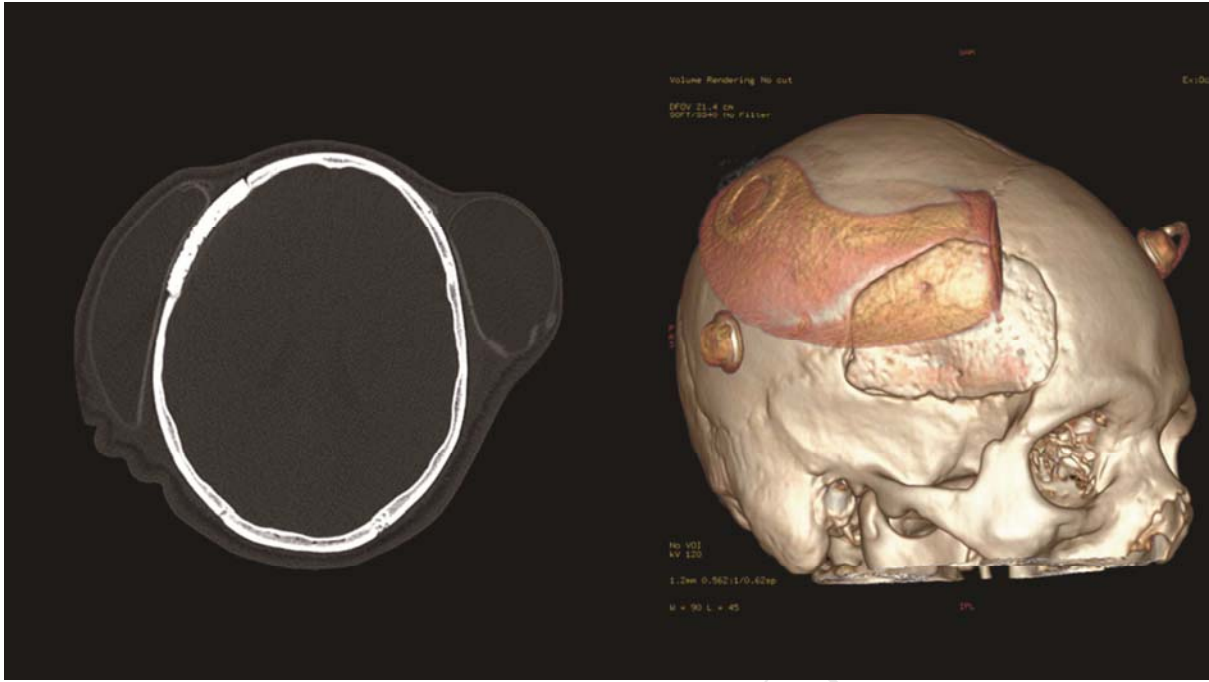
ACCEPTED MANUSCRIPT



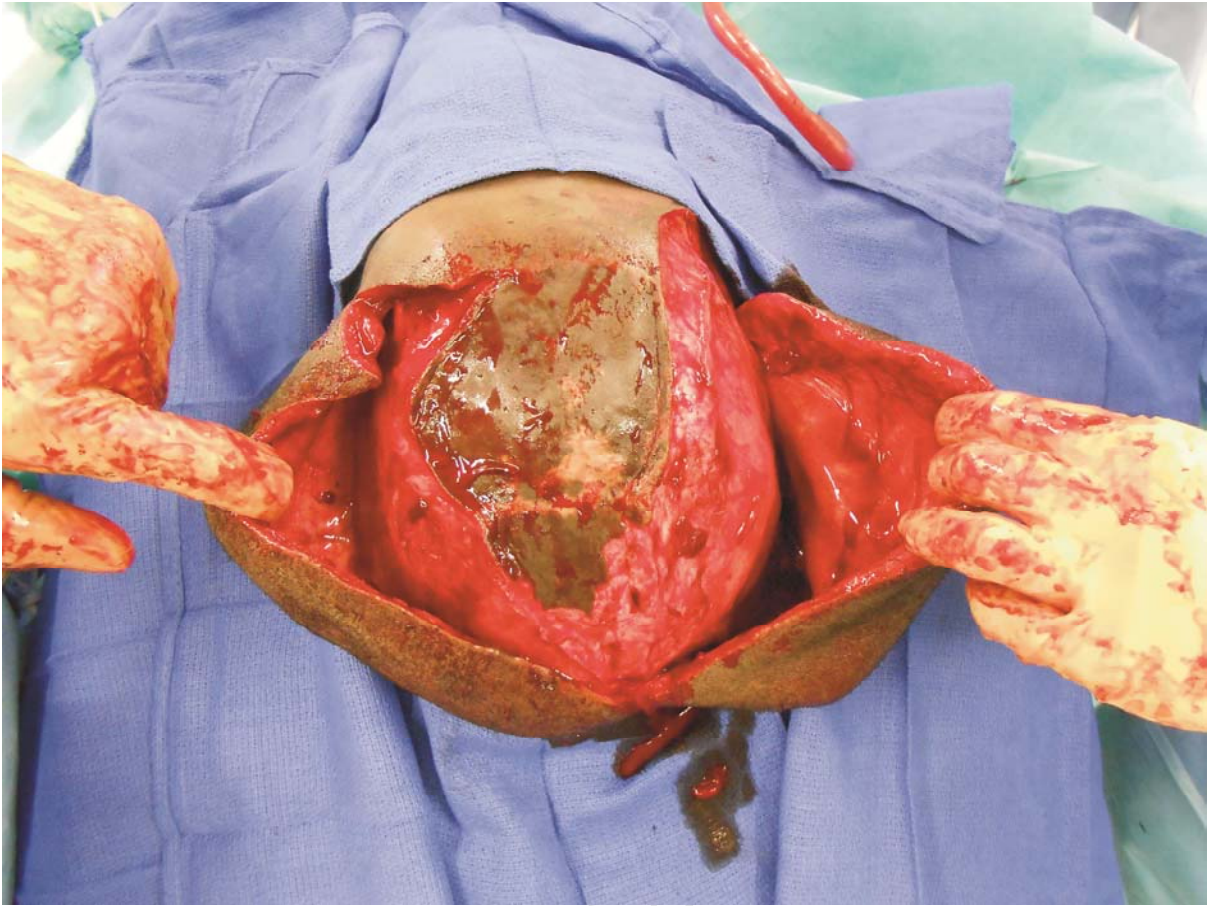
ACCEPTED MANUSCRIPT

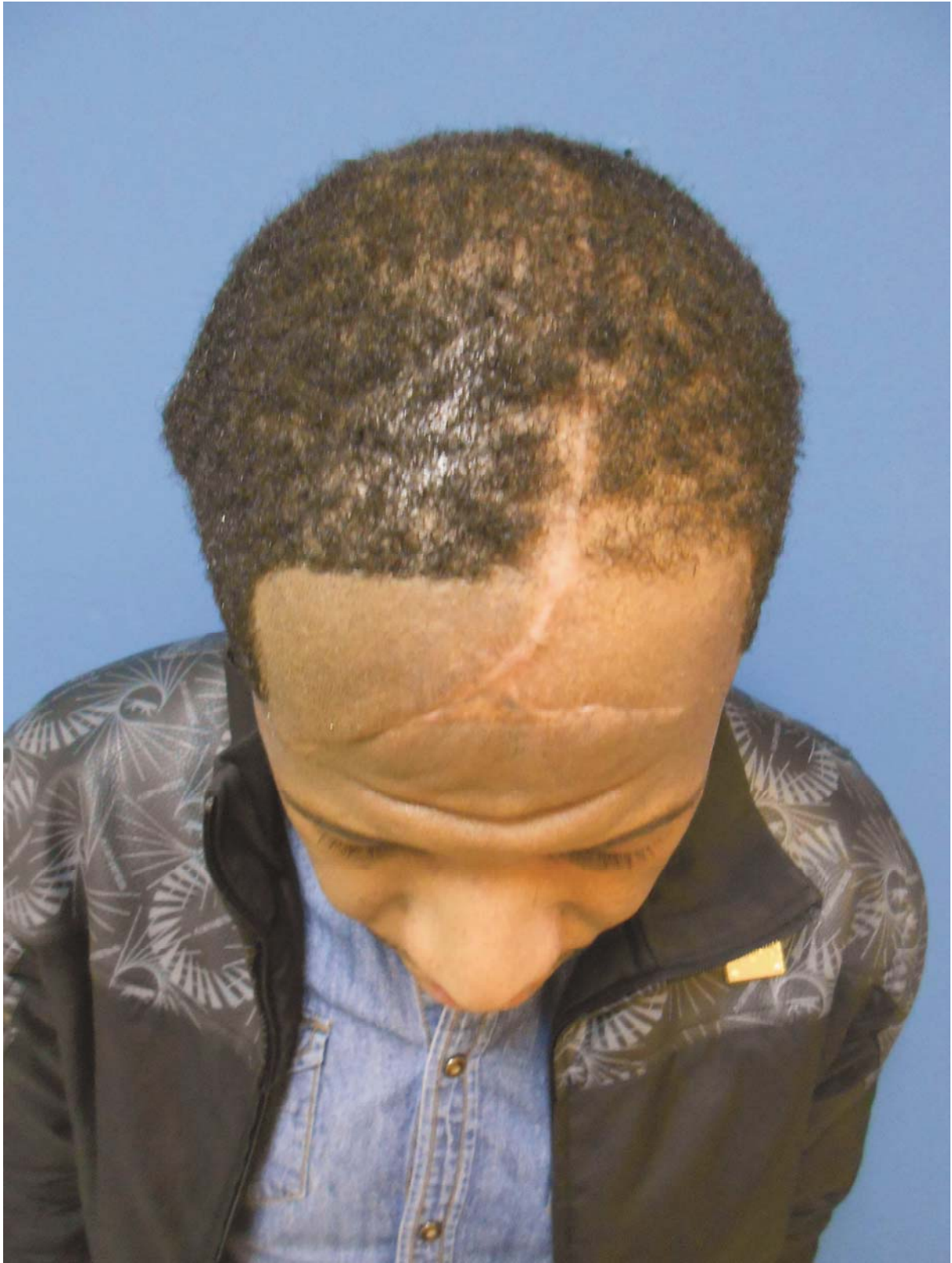


ACCEPTED MANUSCRIPT



ACCEPTED MANUSCRIPT





Highlights

- No data is provided by the literature about the safety of performing expansion above cranial implants.
- We report the first case of a patient who underwent a scalp tissue expansion above a custom-bone hydroxyapatite cranial implant to correct sequela alopecia
- The successful outcome shows that hydroxyapatite implants may be strong enough to support an expansion.

Abbreviations

computed tomography (CT)

ACCEPTED MANUSCRIPT