



# Chyme reinfusion or enteroclysis in nutrition of patients with temporary double enterostomy or enterocutaneous fistula

Ronan Thibault, Denis Picot

## ► To cite this version:

Ronan Thibault, Denis Picot. Chyme reinfusion or enteroclysis in nutrition of patients with temporary double enterostomy or enterocutaneous fistula. *Current Opinion in Clinical Nutrition and Metabolic Care*, 2016, 19 (5), pp.382-387. 10.1097/MCO.0000000000000304 . hal-01390778

**HAL Id: hal-01390778**

**<https://univ-rennes.hal.science/hal-01390778>**

Submitted on 2 Nov 2016

**HAL** is a multi-disciplinary open access archive for the deposit and dissemination of scientific research documents, whether they are published or not. The documents may come from teaching and research institutions in France or abroad, or from public or private research centers.

L'archive ouverte pluridisciplinaire **HAL**, est destinée au dépôt et à la diffusion de documents scientifiques de niveau recherche, publiés ou non, émanant des établissements d'enseignement et de recherche français ou étrangers, des laboratoires publics ou privés.

**Chyme reinfusion or enteroclysis in nutrition of patients with temporary double  
enterostomy or enterocutaneous fistula**

Ronan Thibault,<sup>a</sup> Denis Picot<sup>b</sup>

<sup>a</sup> Nutrition unit, Department of Endocrinology, Diabetology and Nutrition, Home parenteral  
nutrition centre, CHU Rennes, Université de Rennes 1, INSERM U991, Rennes, F-35000,  
France

<sup>b</sup> Department of Nutritional and Digestive Rehabilitation, Clinique Saint Yves, Rennes, F-  
35044, France

Corresponding author:

Prof. Ronan Thibault, MD, PhD

Unité de Nutrition

CHU Rennes - Pontchaillou

2, rue Henri Le Guilloux

35000 Rennes

France

Phone +33 2 99 28 96 46

Fax +33 2 99 28 96 47

E-mail [ronan.thibault@chu-rennes.fr](mailto:ronan.thibault@chu-rennes.fr)

## 22   **Abstract (196 words)**

23

### 24   **Purpose of review**

25   Patients with double temporary enterostomy or enterocutaneous fistula (ECF) may suffer  
26   from intestinal failure (IF). Parenteral nutrition (PN) is the gold standard treatment until  
27   surgical reestablishment of intestinal continuity, but serious complications may arise. Chyme  
28   reinfusion (CR) or enteroclysis are indicated.

### 29   **Recent findings**

30   CR corrects the IF by restoring intestinal absorption, allowing PN weaning in 91% of patients.  
31   CR contributes to improve nutritional status and reduce plasma liver tests abnormalities. CR  
32   is feasible at home without any serious complications in selected patients. Mechanisms  
33   underlying CR effectiveness on intestinal function, such as restoration of ileal brake, are  
34   suggested but most remain to be demonstrated. When the downstream small bowel is  
35   exposed, enteroclysis of enteral nutrition or hydration could be helpful to reduce PN needs, or  
36   in case of insufficient food intake during CR.

### 37   **Summary**

38   CR or enteroclysis are less expensive, safe, and easy-to-use nutrition support techniques, that  
39   may allow reducing PN-related healthcare costs. The latter remains to be demonstrated in the  
40   setting of a prospective randomized controlled trial. This review may contribute to improve  
41   the awareness of intensivists, digestive surgeons and gastroenterologists involved in IF  
42   management to spread the use of CR or enteroclysis.

43

44   **Keywords:** intestinal failure; fistuloclysis; gastrointestinal (GI) surgery; EN; parEN

## Introduction

In the course of an intestinal surgery procedure, several clinical situations lead the surgeon to undertake a double temporary enterostomy (small bowel resection, peritonitis, fistulae, anastomosis protection...) or could be complicated of enterocutaneous fistula (ECF) (peritonitis, anastomosis leakage, digestive adhesences...). These conditions could constitute a type 1 short bowel syndrome and are often complicated with intestinal failure (IF), especially when the stoma output is equal or higher than 1500 ml/24h. These lead to serious complications resulting in hospital readmissions, such as acute or chronic dehydration, renal failure, electrolyte disturbances, micronutrients and mineral deficiencies, and malnutrition, thus increasing healthcare-related costs and affecting patients' quality of life [1]. IF was recently defined by the European Society for Clinical Nutrition and Metabolism (ESPEN) as "the reduction of gut function below the minimum necessary for the absorption of macronutrients and/or water and electrolytes, such that intravenous supplementation is required to maintain health and/or growth » [2]. In case of temporary double enterostomy or ECF, the IF is type 2, and defines as a prolonged acute condition, often in metabolically unstable patients, requiring complex multi-disciplinary care and intravenous supplementation over periods of weeks or months [2]. At this time, the current gold standard therapy indicated until the surgical reestablishment of digestive continuity (SIRC), with a mean duration of 3-6 months, is home parenteral nutrition (HPN) [3]. However, HPN has its own morbidity and, in the absence of expertise, the risks of infectious, hepatic dysfunction, mechanical and metabolic complications are increased [1,3]. Therefore, the availabilities of low cost, safer, and easy-to-use nutrition support techniques could be of high added value in these type 2 IF patients. Chyme reinfusion (CR) [4-9] and enteroclysis [5,6,10] could be these techniques. The scope of this review is to describe the technical principles of CR and enteroclysis, to give practical details for their use, review their clinical benefits in clinical practice, and, due to the lack of data, to hypothesize the mechanisms related to their clinical benefits.

71

72 **Definitions**

73 The interruption of the small bowel by a double enterostomy or an ECF separates the small  
 74 bowel into an upstream afferent segment and a downstream efferent segment (**Figure 1**).

75 Enteroclysis is an enteral nutrition (EN) technique consisting in the administration of EN or  
 76 hydration solutions in the downstream efferent small bowel through efferent enterostomy or  
 77 ECF exposed to the abdomen wall, chyme from the afferent small bowel being thrown out.

78 The term “fistuloclysis” [2,6,10] wrongly used as a synonym of “enteroclysis” should be  
 79 abandoned since: it is medically inappropriate, referring to a technique of fistula irrigation or  
 80 washing and not to an EN technique which could be only delivered in the intestine through  
 81 the fistula, but not in the fistula; it is linguistically inappropriate: one Latina prefix followed  
 82 by one Greek suffix. CR [4] (or re-feeding enteroclysis [2,5] or succus entericus reinfusion  
 83 [8,9]) is an EN technique which artificially re-establishes the small bowel continuity by an  
 84 extra-corporeal circuit of the chyme and mimics the definitive gastro-intestinal function; the  
 85 chyme, composed of digestive secretions and nutrients from oral food and/or tube feeding, is  
 86 collected from the afferent small bowel, and reinfused via the enterostomy or the ECF into the  
 87 efferent diverted small bowel segment. CR could be, at best, in our experience, continuous,  
 88 through a portable or not automated pump, or, as reported by others [5], sequential by manual  
 89 chyme decanting.

90

91 **The principle of CR with auto-regulated pumps**

92 Although first described in 1977 by Etienne Levy, and recently suggested as an alternative  
 93 therapy in IF patients [2], CR is rarely used, under recognized, and not endorsed by most  
 94 health insurances. This is partly due to the fact that the materials used for CR were not  
 95 specifically dedicated to the technique. Indeed, in most centres where it is used, CR is  
 96 performed by diverting from their first use EN pumps and tubulures, or dialysis material...

Usually, and we think that this technique must be abandoned, chyme was collected in a bag thanks to gravity, sometimes refrigerated, often sieved to remove the largest food particles. Chyme is then transferred every 3-4 hours in an EN bag to be reinfused with an auto-regulated EN pump into the downstream efferent small bowel. Others directly reinfused the chyme with a syringe. All these handlings were associated with uncomfortable odours and dirt making the CR technique very unpopular. Spreading the use of auto-regulated pumps dedicated to CR would help to increase CR acceptance and use in IF-specialized centres. At Clinique Saint Yves, Rennes, France, we perform continuous CR using the Entéromate® II system (Labodial, Les Clayes Sous Bois, France), marketed since 1998 (**Figure 2**). Entéromate® II auto-regulates continuous CR without any adjustment or nurse's intervention, and no uncomfortable odour. The dead space volume of the extra-corporeal circuit is lower than 50 ml and does not cause any volemic deprivation. The tubulures are closed and prevent from outside infectious contamination. The automaton has two peristaltic pumps. One pump works permanently and aspirates the jejunal effluent toward a 30 mL disposable plastic container, so that the upper stoma pouch is always empty. The weight of the container is continuously and electronically monitored. When the minimal volume of approximately 10 ml is exceeded, the second pump starts and the contents are infused into the diverted downstream small bowel until the return to minimal volume. The downstream small bowel is intubated through the efferent enterostomy or ECF with a simple lumen polyurethane naso-gastric tube ch 14-16, Levine-typed, without balloon, into the first 15-20 centimetres of the small bowel (**Figure 1**). We advise that polyurethane naso-gastric tubes must be preferred to Foley's because of their higher internal diameter (for a given "ch" calibre) and the absence of balloon, that could injury the small bowel when too much inflated. Ideally a radiologic opacification with water-soluble contrast agents checks the tube position and controls the anatomy and the length of the downstream small bowel until the colon.

## 123 **Indications of CR**

124 In our experience, the patients eligible for CR fulfil the following criteria: IF defined as a  
125 theoretical indication to PN, plus a stoma output nihil per mouth of at least 1200 ml/24h;  
126 existence of a double enterostomy or at least two orifices of ECF visible on the abdominal  
127 wall; theoretical temporary nature of the stoma or ECF in the expectancy of SIRC; presence  
128 of efferent small bowel between the stoma and the colon, or a terminal ileostomy; absence of  
129 obstruction of digestive fistula between the mouth and the afferent stoma, and in the efferent  
130 intestinal tract; ability to catheterize the efferent stoma with a feeding tube on more than 15  
131 cm; absence of progressive peritoneal carcinosis; age >17 years; full agreement of the patient  
132 to carry out CR and accept the food constraints of ingesting smooth puree meals.

133

## 134 **CR and enteroclysis in daily practice**

135 CR and enteroclysis should be integrated in a global approach of intestinal rehabilitation.  
136 Patients require complex management of opened abdominal wounds, high intestinal outputs  
137 and need a multi-disciplinary nutrition team, including specially trained nurses and  
138 nutritionist gastroenterologists or surgeons. During the two days before CR initiation,  
139 enteroclysis is initiating by instilling one liter of oral rehydration solution, together with  
140 laxatives in case of fecal residues or fecaloma in the colon. At the same time, anti-motility  
141 drugs, e.g. loperamide, are stopped to prevent ileus. Antispasmodic agents could be useful in  
142 case of abdominal pain, and cholestyramine is given by enteroclysis in the event of diarrhea  
143 during the first days. In case of persisting diarrhea, loperamide is used. Antisecretory gastric  
144 drugs are used in all patients before and during CR. Octreotide is never used. Once the patient  
145 has been adequately trained and is capable of correctly adjusting the rate of reinfusion,  
146 portable non-autoregulated Enteromate Mobile® pump (Labodial, Les Clayes Sous Bois,  
147 France), marketed since 2010, is used secondly to give autonomy to the patient. This pump is  
148 autonomous thanks to batteries. During CR, to avoid tubes obstruction, patients are

mandatorily orally fed ad libitum with smooth puree meals. In case of insufficient food or hydration intake during CR, EN and additional hydration solutions could be administered classically through a nasogastric feeding tube, gastrostomy or jejunostomy, or, in some cases, by "en Y" enteroclysis in the reinfusion tube into the downstream small bowel [6,8,9].

#### **Clinical benefits of CR and enteroclysis**

Only a few studies have reported the beneficial effects of CR or enteroclysis in IF patients with temporary double enterostomy or ECF. Only one [4] was published within 18 months and none were prospective randomized controlled trials. These studies are monocentric case series, having included only a low number of patients, and did not report post-SIRC clinical outcomes. In adult patients, CR could restore intestinal absorptive capacities [4,7]. This could allow PN discontinuation a few days after its initiation [4,5], and the improvement of frequently observed liver tests abnormalities [4]. Plasma liver tests improvement seems greater in patients treated by enteroclysis coupled with CR than by enteroclysis alone [6]. In neonates and premature infants with double enterostomies, CR reduces PN dependence and corrects plasma liver tests abnormalities [9]. CR improved nutritional status [4,6,7]. The larger monocentric (Clinique Saint Yves, Rennes, France) prospective cohort assessing the efficacy of CR in 212 patients with a temporary double enterostomy (86% of patients) or ECF (14%) waiting for SIRC is under publication and confirms these findings, and suggests the feasibility of home CR [4]. Double enterostomy or ECF were mainly due to peritonitis (44%) and cancer (34%). CR corrects the IF by restoring intestinal absorption: reduction in intestinal losses by 85%, strong improvement in nitrogen and fat digestive absorption coefficients, and strong reduction in the proportion of patients with plasma citrulline  $<20 \mu\text{mol/l}$  [4]. As a result, PN and/or IV hydration could be stopped in 91% of patients, within a median  $\pm$  interquartiles (IQ) of  $2 \pm 9$  days after CR initiation [4], or in 100% of cases within 20 days in the little case series of 20 patients reported by Coetzee et al [5]). In addition,



nutritional status improved. With CR, the number of patients who had one or several plasma liver tests abnormalities decreased from 87 to 51% ( $P<0.001$ ) [4].

### **Complications and side effects of CR**

The management of CR-related complications and side effects requires dedicated healthcare staff education. In our case series of 232 patients [4], eight patients (3%) were excluded because of CR early complications, including one lethal: anal incontinence,  $n=2$ ; ischaemic colitis,  $n=1$ ; newly developed fistulas,  $n=3$ ; cancerous colic stenosis,  $n=1$ ; letal mesenteric infarction:  $n=1$ . Wu et al reported diarrhoea, vomiting, nausea, abdominal pain, and abdominal distension that could affect until 14% of patients, but were all relieved later during CR course [6]. In other case series [4,5], the prevalence of CR-related technical problems (e.g. tube disinsertions or obstructions, chyme leaks, stoma care problems,...) and gastrointestinal side effects was not collected. In our experience, the most frequent side effects of CR are: the difficulty to accept the food constraints of ingesting smooth puree meals that could impact on mood, quality of life, and nutritional status; obstruction or displacement of the CR tube; spasmodic pains during the resumption of normal downstream intestine function; severe constipation, especially if antidiarrheal drugs are used (this is the reason why loperamide has to be stopped before CR initiation).

One considerable advantage of CR is, by using the whole remnant small bowel, to prefigure the post-SRIC intestinal function. Indeed some symptoms occurring during CR, such as pain, fecal incontinence, diarrhoea, would have occurred after SRIC. Thus CR should allow anticipating and even preventing situations that would have occurred after the SRIC with potentially more serious consequences and sometimes would have required a second surgery. For example, in case of fecal incontinence, anal biofeedback could be prescribed before the SRIC.

## **Feasibility of home CR**

In 59 (28%) patients of our French case series [4], CR was feasible at home in selected patients after specific training and education, where they must have acquired total autonomy for CR and basic stoma care. The median duration of home CR was  $36 \pm 40$  days, accumulating 7.4 patients-years. For home CR, we have elaborated a dedicated clinical pathway including a thesaurus of solutions facing well defined technical problems. As a result, no patient had to stop CR, only a few were readmitted for minor problems, and none had to go back to PN. Unfortunately, at this time, home CR is not yet recognized by health insurances as a nutrition support technique. More studies, noteworthy multicentric, are needed to demonstrate safety and clinical benefits of home CR.

## **Medicoeconomics benefits of CR**

At this time, PN remains the gold standard therapy until the patients underwent the SRIC. PN costs are much higher than those of EN and increase with complications [1]. The quick PN weaning with CR could have avoided 26.6 patients-years with PN [4]. As a great part of the costs of type 2 IF patients' therapies resulted from PN-related complications [11], CR could be associated with substantial cost-savings. The prospective randomized controlled trial FRY, supported by the French National Clinical Research Program, will determine the impact of CR compared to PN on the incidence of complications, healthcare costs and quality of life in IF patients with temporary high-output double enterostomy until a follow up of one month post-SIRC. Thanks to an additional ESPEN Technology grant 2015, the FRY trial will allow determining feasibility of home CR in a multicentric setting.

## **Hypotheses upon the mechanisms of the clinical benefits of CR and enteroclysis**

In case of small bowel disruption, the absence of the ileal brake results in a non-inhibition of gastric emptying, gastric hypersecretion and accelerated intestinal motility, contributing to

impaired absorption. Supposed mechanisms of CR-induced improvement of intestinal function are the reabsorption of digestive secretions (gastric, pancreatic, and biliary succus) and the restoration of the ileal brake. The latter was first suggested by Levy et al [12] who showed that proximal stoma output was brake down by hydration solution enteroclysis into the downstream small bowel (-20%) and mainly by CR (-33%). Plasma citrulline normalization is the result of the increase in the functional enterocyte mass and of the better extraction of intraluminal glutamine [7]. In case of terminal ileum resection, the enterohepatic cycle of bile acids is disrupted leading to bile salts malabsorption. This results in an increase in bile acid synthesis by the liver which, in turn, enhances hepatic lipogenesis and intrahepatic cholestasis, resulting in plasma liver tests abnormalities. At physiological state, bile salts activate the intracellular receptor FXR in the small intestine and liver epithelium [13]. FXR activation is in part mediated by endocrine-acting fibroblast growth factor (FGF) 19, a bile salt-induced enterokine. The release of the FGF19 subsequently inhibits bile salt synthesis from cholesterol. In case of IF-induced enterohepatic cycle disruption, bile salts synthesis is not inhibited, resulting in overproduction and liver accumulation that could have a direct toxicity on hepatocytes. CR could act by restoring bile salts enterohepatic cycle and bile salts signalling, decreasing liver inflammation and plasma liver tests. A study is ongoing to demonstrate this hypothesis. Other mechanisms such as changes in intestinal microflora or prevention of bacterial overgrowth deserve further investigation.

## **Conclusion**

CR or enteroclysis are safe and easy-to-use nutrition support techniques. In case of IF secondary to high output temporary enterostomy or ECF, CR is an efficient and reliable technique of EN which corrects IF by restoring intestinal absorption. CR contributes to improve nutritional status and to reduce plasma liver tests abnormalities, and is feasible at home in well selected patients. By allowing the PN weaning within a short period, CR could

253 be associated with substantial cost-savings. The prospective randomized controlled trial FRY,  
254 supported by the French National Clinical Research Program, will determine the impact of  
255 CR compared to PN on the incidence of complications, healthcare costs and quality of life in  
256 IF patients with temporary high-output double enterostomy. This review may contribute to  
257 improve the awareness of intensivists, digestive surgeons and gastroenterologists involved in  
258 IF management to spread the use of CR and enteroclysis.

259

## 260    **Key points**

- 261    • In case of intestinal failure secondary to high output temporary enterostomy or  
262    enterocutaneous fistula, chyme reinfusion is an efficient and reliable technique of enteral  
263    nutrition which corrects intestinal failure by restoring intestinal absorption, allowing  
264    parenteral nutrition weaning in almost all patients.
- 265    • Chyme reinfusion contributes to improve nutritional status and to reduce plasma liver tests  
266    abnormalities, and is feasible at home in well selected patients.
- 267    • Chyme reinfusion allows preparing efferent small bowel and colon to the surgical  
268    reestablishment of intestinal continuity.
- 269    • In patients with exposed efferent small bowel, enteroclysis of hydration and/or enteral  
270    nutrition solutions could allow improving hydration and nutritional status, as well as reducing  
271    parenteral nutrition needs.
- 272    • Multicentre prospective randomized controlled trials are needed to determine the impact of  
273    chyme reinfusion compared to parenteral nutrition on the incidence of complications,  
274    healthcare costs and quality of life, as well as feasibility of home chyme reinfusion, in  
275    intestinal failure patients with temporary high-output double enterostomy or enterocutaneous  
276    fistula.

277

## 278    **Acknowledgement**

279    None

280

## 281    **Financial support and sponsorship**

282    None

283

## 284    **Conflicts of interest**

285 RT declares no conflict of interest regarding this article. DP declares advisory activities  
286 without any financial retribution with Labodial, Les Clayes Sous Bois, France.  
287

## 288   **References**

289

290   [1] Dobb M, Teubner A, Theis V, et al. Review article: the management of long-term

291   parenteral nutrition. *Aliment Pharmacol Ther* 2013;37:587-603

292   [2] Pironi L, Arends J, Baxter J, et al. The Home Artificial Nutrition & Chronic Intestinal

293   Failure and the Acute Intestinal Failure Special Interest Groups of ESPEN. ESPEN endorsed

294   recommendations. Definition and classification of intestinal failure in adults. *Clin Nutr*

295   2015;34:171-180

296   \*\* An important position paper written by experts from the European Society for Clinical

297   Nutrition and Metabolism (ESPEN) defining intestinal failure and proposed the use of chyme

298   reinfusion and enteroclysis in type 2 intestinal failure patients.

299   [3] Pironi L, Arends J, Bozzetti F, et al. ESPEN guidelines on chronic intestinal failure in

300   adults. *Clin Nutr* 2016;35:247-307

301   [4] Picot D, Layec S, Dussaulx L, et al. Chyme reinfusion in patients with intestinal failure

302   due to temporary double enterostomy: a 15-year prospective cohort in a referral centre. *Clin*

303   *Nutr* 2016, in press

304   \*\* This is the largest published case series of chyme reinfusion in intestinal failure patients

305   with temporary double enterostomy or enterocutaneous fistula. This study demonstrates the

306   improvement in intestinal absorption, nutritional status, and plasma liver tests abnormalities.

307   [5] Coetzee E, Rahim Z, Boutall A, Goldberg P. Refeeding enteroclysis as an alternative to

308   parenteral nutrition for enteric fistula. *Colorectal Dis* 2014;16:823-30

309   \* One of the rare paper with [4] showing that chyme reinfusion allows adequate nutrition,

310   water and electrolyte balance, without resorting to parenteral infusions.

311   [6] Wu Y, Ren J, Wang G, et al. Fistuloclysis improves liver function and nutritional status

312   inpatients with high-output upper enteric fistula. *Gastroenterol Res Pract* 2014;2014:941514

313 \* This study shows that enteroclysis improved plasma liver tests and nutritional status in  
314 patients with high-output enterocutaneous fistula, particularly in biliary fistula patients.

315 [7] Picot D, Garin L, Trivin F, et al. Plasma citrulline is a marker of absorptive small bowel  
316 length in patients with transient enterostomy and acute intestinal failure. Clin Nutr  
317 2010;29:235-242

318 [8] Calicis B, Parc Y, Caplin S, et al. Treatment of postoperative peritonitis of small-bowel  
319 origin with continuous enteral nutrition and succus entericus reinfusion. Arch Surg  
320 2002;137:296-300

321 [9] Drenckpohl D, Vegunta R, Knaub L, et al. Reinfusion of succus entericus into the mucous  
322 fistula decreases dependence on parenteral nutrition in neonates. ICAN: Infant, Child, &  
323 Adolescent Nutrition 2012;4:168-174

324 [10] Teubner A, Morrison K, Ravishankar HR, et al. Fistuloclysis can successfully replace  
325 parenteral feeding in the nutritional support of patients with enterocutaneous fistula. Br J Surg  
326 2004;91:625–631

327 [11] Saunders J, Parsons C, King A, et al. The financial cost of managing patients with type 2  
328 intestinal failure; experience from a regional centre. e-SPEN Journal 2013;8:e80-e85

329 [12] Lévy E, Palmer DL, Frileux P, et al. Inhibition of upper reinfusion of succus entericus  
330 into the distal small bowel: a clinical study of 30 patients with peritonitis and temporary  
331 enterostomy. Ann Surg 1983;198:596-600

332 [13] van Erpecum KJ, Schaap FG. Intestinal failure to produce FGF19: A culprit in intestinal  
333 failure-associated liver disease? J Hepatol 2015;62:1231-3

334 \* A short editorial suggesting that intestinal failure-associated liver disease is not related only  
335 to parenteral nutrition, but that bile acids signaling through the FXR-FGF19 axis, should be  
336 involved.



## Figure legends

**Figure 1 – Example of a temporary double enterostomy.** The small bowel continuity is disrupted with two small bowel segments exposed to the abdominal wall: the upstream afferent segment, with impaired digestive and absorptive function, and a downstream efferent segment, totally deprived of digestive secretions, bowel flow and succus entericus. The feeding tube is inserted in the downstream small bowel, and is ready for enteroclysis or chyme reinfusion.

**Figure 2 – Chyme reinfusion technique with the automated pump Enteromate II® (A) and the portable Enteromate® Mobile (B)** (Labodial, Cluses-sous-Bois, France). (A) The left pump works permanently and aspirates the jejunal effluent from the upstream small bowel afferent stoma toward a 30 ml disposable plastic container, which is hung on an electronic steelyard. The upper stoma pouch is always empty. The weight of the container is continuously and electronically monitored. When the minimal volume of approximately 10 ml is exceeded, the second pump starts and the contents are infused into the diverted downstream small bowel until the return to minimal volume. (B) Once the patient has been adequately trained and is capable of correctly adjusting the rate of reinfusion, portable non-autoregulated Enteromate Mobile® pump was used secondly to give autonomy to the patient during the hospitalization and at home. This pump is autonomous thanks to batteries.

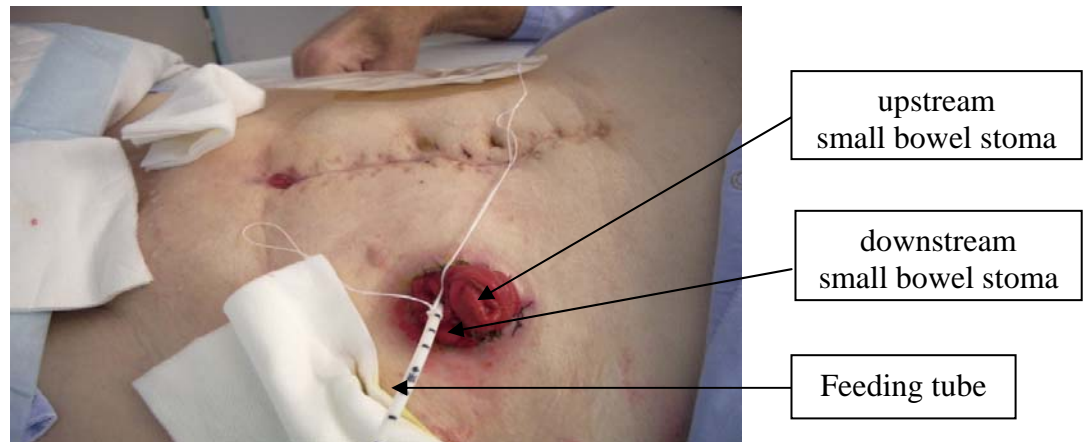
**Figure 1**

Figure 2

