



HAL
open science

Single transversus abdominis muscle flap: another possibility for large congenital diaphragmatic hernia repair.

A. P. Arnaud, A. Martin, E. Habonimana, B Frémond

► To cite this version:

A. P. Arnaud, A. Martin, E. Habonimana, B Frémond. Single transversus abdominis muscle flap: another possibility for large congenital diaphragmatic hernia repair.. Journal of Thoracic and Cardiovascular Surgery, 2016, In press. 10.1016/j.jtcvs.2016.05.005 . hal-01321405

HAL Id: hal-01321405

<https://hal-univ-rennes1.archives-ouvertes.fr/hal-01321405>

Submitted on 21 Jun 2016

HAL is a multi-disciplinary open access archive for the deposit and dissemination of scientific research documents, whether they are published or not. The documents may come from teaching and research institutions in France or abroad, or from public or private research centers.

L'archive ouverte pluridisciplinaire **HAL**, est destinée au dépôt et à la diffusion de documents scientifiques de niveau recherche, publiés ou non, émanant des établissements d'enseignement et de recherche français ou étrangers, des laboratoires publics ou privés.

1 **Single transversus abdominis muscle flap: another possibility for large congenital**
2 **diaphragmatic hernia repair.**

3

4 AP.Arnaud¹, MD, A.Martin¹, MD, E.Habonimana¹, MD, B.Frémond¹, MD-PhD

5

6 ¹ Paediatric surgery department, CHU Rennes, F-35033 Rennes, France

7

8 Correspondence should be addressed to:

9 Alexis P Arnaud, MD

10 Paediatric surgery department

11 Hôpital sud, CHU Rennes

12 16 Boulevard de Bulgarie

13 35000 Rennes

14 France

15 Phone number : 00 33 299284321 extension 63065

16 Email: alexis.arnaud@chu-rennes.fr

17

18 Authors have nothing to disclose with regard to commercial support.

19 No funding was provided to perform this study.

20 Ethics committee registry number: 15.92

21 Article word count: 749/750

22 **Introduction**

23 Large defect congenital diaphragmatic hernias comprise a defect too large to be closed
24 primarily and diaphragm agenesis. This condition remains a surgical and intensive care
25 challenge¹. Many different approaches have been described. Prosthetic patches are often used,
26 but they face the major issue of high recurrence rate ranging from 27 to 50%². Some reports
27 in the literature describe muscle flap repair and though they are scarce and concern small
28 series, they indicate that muscle flaps recur only in 0 to 4.3%^{3,4}. For the last 20 years, our
29 routine clinical practice has been to avoid patches by using a muscle flap to repair the defects
30 that are too large for primary closure. We therefore present a simple novel technique using a
31 single layer muscle flap based on the transversus abdominis muscle.

33 **Patients and methods**

34 Between 1995 and 2015, all newborns presenting with large congenital diaphragmatic defect
35 (i.e. a defect too big to be closed primarily and diaphragmatic agenesis) underwent a single
36 layer transversus abdominis muscle flap repair. We reviewed the data from the medical files
37 of these children. This study was approved by our institutional research ethics board. Data are
38 given in median (range).

40 Surgical technique

41 Under general anaesthesia, the newborn is placed in supine position, with a roll under the
42 thoraco-lumbar junction.

43 The abdominal cavity is opened with a transversal incision 5mm above the umbilicus,
44 extended to the side of the hernia (Figure 1-A). All layers are cut by monopolar diathermy.
45 After reduction of the herniated organs, the anterior and posterior aspects of the diaphragm
46 remnants are dissected. (Figure 1-B). The flap is fashioned. Using the tip of dissecting

47 scissors in the avascular plane, the transversus abdominis muscle is divided from the two
48 other layers of the upper lateral quadrant of the abdominal wall, joining the lower edges of the
49 ribs. Sagittal incision of the aponeurosis between transversus abdominis muscle and the rectus
50 muscle frees the median edge of the flap in order to rotate it backward around the costal edge
51 axis (Figure 1-A). After dissecting the edges of the diaphragmatic remnant (if present) all
52 around the defect, the flap is sutured either to the muscle rim or to the ribs' periosteum using
53 non-absorbable interrupted stitches (Figure 1-C and D). The abdominal muscle wall is then
54 closed in two layers, i.e. superior sheet of external and internal obliques sewn to an inferior
55 sheet of intact abdominal wall. In case of inadequate abdominal capacity, a staged closure of
56 the abdominal wall is performed using a silo.

57

58

59 **Results**

60 16 newborns underwent the single muscle flap repair. All patients but one had a left hernia.
61 Gestational age at birth was 37.6 weeks (34-38.7) and birth weight was 2.875 kg (1.78-3.2).
62 Surgery was performed at 29 hours of life (4-96), all neonates being ventilated on high
63 frequency oscillation. Procedure length was 2.5 hours (1.5-3). Surgery was performed in
64 neonatal intensive care unit (NICU) or in theatre in 14 and 2 cases respectively. Abdominal
65 wall was primarily closed in all but two patients who required a staged closure.
66 Twelve infants were discharged from NICU. Length of stay was 34 days (20; 483) in
67 intensive care unit and 67 days (32; 483) in hospital. Four patients died in NICU: 3 due to
68 refractory pulmonary hypertension (2 at day1, 1 at day228) and 1 as a result of
69 staphylococcus pneumonia at day9.

70

71

72 Discussion

73 Large congenital defect of the diaphragm, i.e. not primarily closable, remains a surgical
74 challenge. Many techniques have been proposed. The abdominal muscle flap repair for
75 diaphragmatic defect was first described in 1962 mobilizing the three layers of the abdominal
76 wall and was then modified by Simpson and Gossage in 1971⁵. They described a two-muscles
77 flap using transversus abdominis and internal oblique, swung posteriorly and stitched to the
78 posterior muscle rim. In our technique, we also use an abdominal muscle flap, but we dissect
79 only the transversus abdominis. The dissection plane allows for a high quality, well-
80 vascularized and innervated flap. The transverse incision at the umbilicus level gives a good
81 exposure to the medial and posterolateral part of the defect compared to medial incision. This
82 incision also facilitates the tailoring of a large muscle flap. Indeed, this technique has always
83 produced a flap large enough to complete the defect closure without requiring prosthetic patch
84 addition.

85 In conclusion, considering the ease of the flap elevation and the large amount of well-
86 vascularized tissue available, we believe that the transversus abdominis muscle flap repair is a
87 safe, simple and suitable technique for large congenital diaphragmatic defect.

88

89

90

91 Acknowledgement: Jean-Jacques Levrel (graphic studio, CHU Rennes) for design graphic,

92 Luke Harper (Paediatric surgery department, CHU St Denis de La Reunion) for English

93 revision.

94

95

96

ACCEPTED MANUSCRIPT

97

98 References

99

100

101

102 1. Congenital Diaphragmatic Hernia Study G, Lally KP, Lally PA, et al. Defect size
103 determines survival in infants with congenital diaphragmatic hernia. *Pediatrics*
104 2007;120:e651-7.

105 2. Jancelewicz T, Chiang M, Oliveira C, Chiu PP. Late surgical outcomes among
106 congenital diaphragmatic hernia (CDH) patients: why long-term follow-up with
107 surgeons is recommended. *Journal of pediatric surgery* 2013;48:935-41.

108 3. Scaife ER, Johnson DG, Meyers RL, Johnson SM, Matlak ME. The split abdominal
109 wall muscle flap--a simple, mesh-free approach to repair large diaphragmatic hernia.
110 *Journal of pediatric surgery* 2003;38:1748-51.

111 4. Barnhart DC, Jacques E, Scaife ER, et al. Split abdominal wall muscle flap repair vs
112 patch repair of large congenital diaphragmatic hernias. *Journal of pediatric surgery*
113 2012;47:81-6.

114 5. Simpson JS, Gossage JD. Use of abdominal wall muscle flap in repair of large
115 congenital diaphragmatic hernia. *Journal of pediatric surgery* 1971;6:42-4.

116

117

118

119 Figure 1 : Surgical technique

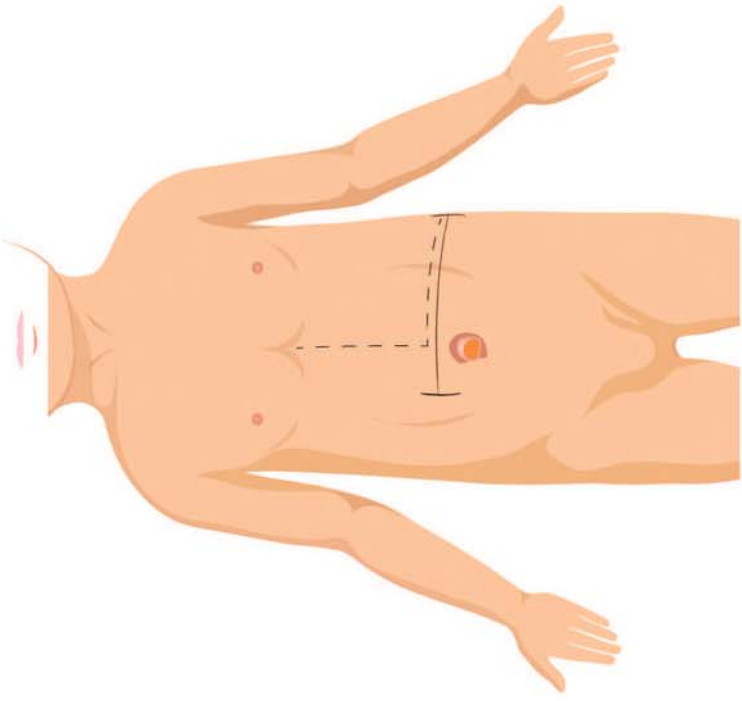
120 A- Newborn is placed in supine position. A transversal cutaneous incision is performed
121 5mm above the umbilicus (continuous line). Muscle flap will be divided along the rectus
122 (dotted line).

123 B- View of a large congenital left diaphragmatic defect. Anterolateral abdominal wall
124 consists of 3 muscle layers : transversus abdominis (TA), internal oblique (IO) and
125 external oblique EO).

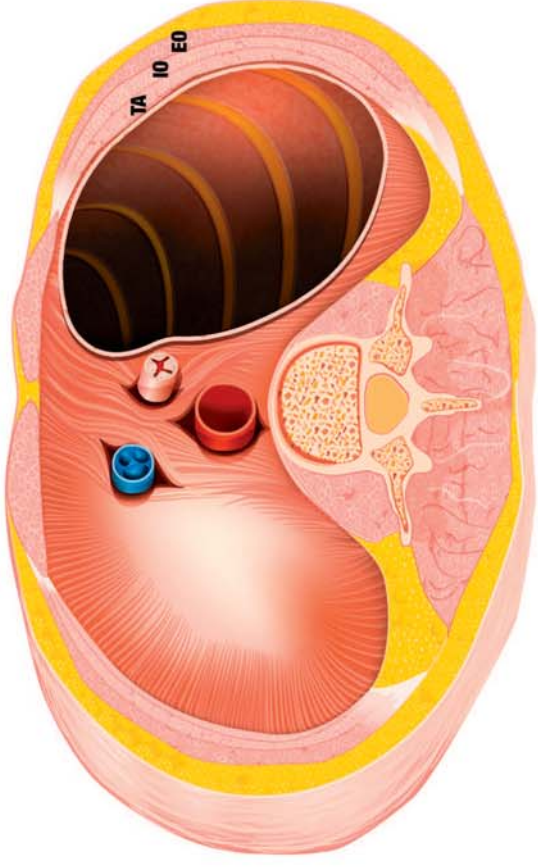
126 C- After division of the avascular plan between the transversus abdominis (TA) and the
127 internal oblique (IO) muscles, the flap (TA) is rotated backward and sutured to the
128 diaphragmatic edges.

129 D-Suture of the transversus abdominis single muscle flap (TA) to the edges of the
130 diaphragmatic remnant is completed. Two muscles, internal oblique (IO) and external
131 oblique (EO), stay in place in the anterolateral abdominal wall.

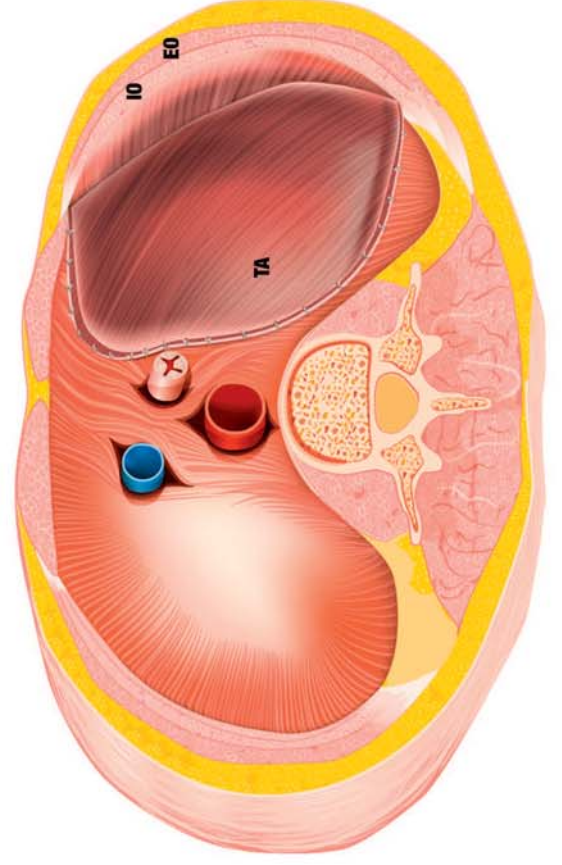
132



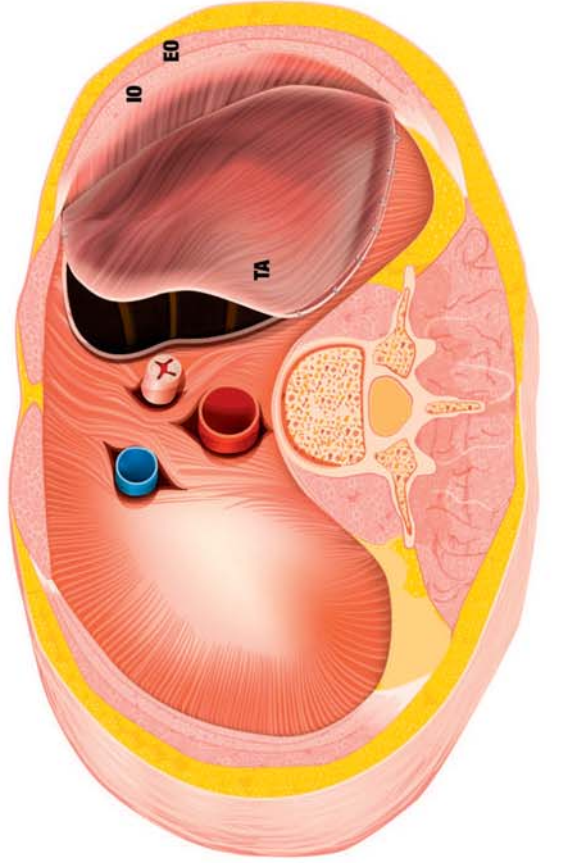
A



B



D



C

