



## **Feasibility of capecitabine and oxaliplatin combination (XELOX) chemotherapy without central venous access device in patients with stage III colorectal cancer**

Alexandra Lapeyre-Prost, Marine Hug De Larauze, Benoist Chibaudel, Marie Line Garcia, Veronique Guering-Meyer, Olivier Bouché, Eveline Boucher, Marc Ychou, Jérôme Dauba, Stéphane Obled, et al.

### **► To cite this version:**

Alexandra Lapeyre-Prost, Marine Hug De Larauze, Benoist Chibaudel, Marie Line Garcia, Veronique Guering-Meyer, et al.. Feasibility of capecitabine and oxaliplatin combination (XELOX) chemotherapy without central venous access device in patients with stage III colorectal cancer. *Clinical Colorectal Cancer*, 2016, 15 (3), pp.250-256. 10.1016/j.clcc.2015.11.004 . hal-01239814

**HAL Id: hal-01239814**

**<https://univ-rennes.hal.science/hal-01239814>**

Submitted on 14 Jan 2016

**HAL** is a multi-disciplinary open access archive for the deposit and dissemination of scientific research documents, whether they are published or not. The documents may come from teaching and research institutions in France or abroad, or from public or private research centers.

L'archive ouverte pluridisciplinaire **HAL**, est destinée au dépôt et à la diffusion de documents scientifiques de niveau recherche, publiés ou non, émanant des établissements d'enseignement et de recherche français ou étrangers, des laboratoires publics ou privés.

Original Study  
Short title: XELOX Without CVAD in Colorectal Cancer

**Feasibility of Capecitabine and Oxaliplatin Combination Chemotherapy Without Central Venous Access Device in Patients With Stage III Colorectal Cancer**

Alexandra Lapeyre-Prost<sup>1, 2</sup>

Marine Hug de Larauze<sup>2</sup>

Benoist Chibaudel<sup>2, 3</sup>

Marie Line Garcia<sup>4</sup>

Veronique Guering-Meyer<sup>5</sup>

Olivier Bouché<sup>6</sup>

Eveline Boucher<sup>7</sup>

Marc Ychou<sup>8</sup>

Jérôme Dauba<sup>9</sup>

Stéphane Obled<sup>10</sup>

Astrid Lièvre<sup>11, 12</sup>

David Malka<sup>13, 14</sup>

Roger Faroux<sup>15</sup>

Isabelle Bonnet<sup>16</sup>

Julien Taieb<sup>1</sup>

Thierry André<sup>2, 4, 17, \*</sup>

thierry.andre@aphp.fr

on behalf of the Groupe Coopérateur Multidisciplinaire en Oncologie, the Fédération Francophone de la Cancérologie Digestive, and the UNICANCER Investigators of the PRODIGE Intergroup

<sup>1</sup>Department of Gastroenterology and Digestive Oncology, Hôpital Européen Georges Pompidou, Paris, France

<sup>2</sup>Multidisciplinary Oncology Research Group (Groupe Coopérateur Multidisciplinaire en Oncologie), Paris, France

<sup>3</sup>Department of Medical Oncology, Institut Hospitalier Franco-Britannique, Levallois-Perret, France

<sup>4</sup>Department of Medical Oncology, Hôpital Saint-Antoine, Paris, France

<sup>5</sup>Department of Medical Oncology, Institut de Cancérologie de l'Ouest Paule Papin, Angers, France

<sup>6</sup>Department of Gastroenterology and Digestive Oncology, Hôpital Robert Debré, Reims, France

<sup>7</sup>Department of Medical Oncology, Centre Eugène Marquis, Rennes, France

<sup>8</sup>Department of Medical Oncology, Centre Régional de Lutte Contre le Cancer Val d'Aurelle, Montpellier, France

<sup>9</sup>Department of Medical Oncology, Hôpital Layne, Mont-de-Marsan, France

<sup>10</sup>Department of Hepatogastroenterology, Centre Hospitalier Universitaire Carémeau, Nîmes, France

<sup>11</sup>Department of Medical Oncology, Institut Curie, Hôpital René Huguenin, Saint-Cloud, France

<sup>12</sup>Université Versailles Saint-Quentin-en-Yvelines, Versailles, France

<sup>13</sup>Department of Surgical **Oncology**, Institut Gustave Roussy, Villejuif, France

<sup>14</sup>Department of Medical Oncology, Institut Gustave Roussy, Villejuif, France

<sup>15</sup>Department of Gastroenterology, Centre Hospitalier Départemental de La Roche-sur-Yon Les Oudairies, Roche-sur-Yon, France

<sup>16</sup>Department of Medical Oncology, Hôpital Jean Bernard, Valenciennes, France

<sup>17</sup>Université Pierre et Marie Curie Paris 6, Paris, France

\*Address for correspondence: Thierry André, MD, Department of Medical Oncology, Hôpital Saint Antoine, 184 rue du Faubourg Saint Antoine, Paris 75012, France

---

**Micro-Abstract**

The use of a central venous access device (CVAD) for adjuvant XELOX (capecitabine, oxaliplatin) does not appear to be justified for all cases of stage III colon cancer. The feasibility of XELOX without a CVAD in the adjuvant setting for stage III patients was evaluated. Our results confirm the feasibility of this approach in 81.2% of patients for whom a CVAD was not placed before the first chemotherapy cycle.

---

**Abstract**

**Background**

5-Fluorouracil and leucovorin plus oxaliplatin (FOLFOX) or capecitabine plus oxaliplatin (XELOX) is a standard adjuvant treatment for patients with stage III colon cancer (CC). Capecitabine is an oral fluoropyrimidine, and administration of oxaliplatin does not necessarily require the insertion of a central venous access device (CVAD). We evaluated the feasibility of XELOX without a CVAD as adjuvant treatment in patients with stage III CC.

**Patients and Methods**

We retrospectively studied prospectively collected data from patients with stage III CC treated with XELOX in the International Duration Evaluation of Adjuvant Chemotherapy French trial. Patients were divided into 2 groups: those with a CVAD and those with peripheral venous access (PVA), including patients who had and had not had a CVAD at the first cycle of chemotherapy. Chemotherapy without a CVAD was considered feasible if the patient received all cycles of adjuvant therapy without it.

**Results**

A total of 203 patients were included: 86 (43%) in the PVA group and 116 (57%) in the CVAD group. Of the 85 patients in the PVA group (1 patient was not treated), 69 (81.2%) did not require the insertion of a CVAD. However, 16 (18.8%) required CVAD insertion owing to systematic delay of the initially planned CVAD before the second cycle of chemotherapy in 7, complications related to PVA usage in 5, a switch to the modified FOLFOX6 regimen in 2, and other reasons in 2. The oxaliplatin dose was similar in both groups regardless of the chemotherapy duration. XELOX without a CVAD was feasible for 81.2% of the patients for whom a CVAD had not been planned before chemotherapy and for 88.4% of patients for whom chemotherapy was planned without the use of a CVAD.

**Conclusion**

XELOX chemotherapy without a CVAD is a feasible approach for treating patients with stage III CC in the adjuvant setting.

---

**Keywords:** Adjuvant chemotherapy; Colon cancer; CVAD; Peripheral venous access; XELOX

## Introduction

Colorectal cancer (CRC) is the third most diagnosed cancer in the world and the fourth most common cause of cancer death.<sup>1</sup> The 3-year disease-free survival (DFS) for patients with stage III CRC without any postoperative chemotherapy has ranged from 44% to 52%.<sup>2,3</sup> The standard adjuvant treatment for patients with stage III colon cancer consists of the combination of folinic acid, 5-FU, and oxaliplatin (FOLFOX), administered for 6 months.<sup>4-7</sup>

With the intent to improve the quality of life of patients with CRC, the oral drug capecitabine was developed as a substitute for infusional 5-FU/LV in the adjuvant setting. In the phase III Xeloda in Adjuvant Colon Cancer Therapy (X-ACT) trial of stage III colon cancer (CC), capecitabine was compared to 6 months of the Mayo Clinic 5-FU/LV combination.<sup>8</sup> Capecitabine yielded at least equivalent DFS to 5-FU/LV. In the multicenter phase III NO16968 trial, which randomized patients with stage III CC to either capecitabine and oxaliplatin (XELOX) for 3 weeks or standard bolus 5-FU/LV, XELOX showed superiority over 5-FU/LV.<sup>9,10</sup> A 3-year DFS of 70.9% with XELOX versus 66.5% with 5-FU/LV and 7-year overall survival of 73% with XELOX versus 67% with 5-FU/LV were observed. These results prompted the adoption of the XELOX regimen as standard adjuvant treatment for stage III CC. The International Duration Evaluation of Adjuvant Chemotherapy (IDEA) phase III multicenter trial was designed to test whether a 3-month course of oxaliplatin-based adjuvant therapy (modified FOLFOX6 or XELOX) is not inferior for DFS to the current 6-month duration of the identical treatment.<sup>11</sup>

With the XELOX regimen, capecitabine is administered orally, with intravenous administration of oxaliplatin. Given that oxaliplatin is classified as an irritating cytostatic regimen,<sup>12</sup> its administration through a peripheral vein does not induce a severe risk of skin toxicity in the case of extravasation. Oxaliplatin infusion without the need for a central venous access device (CVAD) has been reported in patients with metastatic CRC; however, very few data have been published regarding this aspect.<sup>13</sup> The placement of an implantable CVAD might not be always justified in patients for whom peripheral venous access (PVA) is sufficient and for those who undergoing XELOX for a maximum duration of 8 cycles, such as in the case of adjuvant chemotherapy for stage III CRC. The IDEA study provided an ideal learning opportunity to compare CVAD XELOX chemotherapy delivery with PVC XELOX administration in patients with stage III CRC.

The present study used an extraction of the IDEA FRANCE database to evaluate the feasibility of XELOX chemotherapy without a CVAD as adjuvant treatment of stage III CC.

## Patients and Methods

### Patients

Patients eligible for study inclusion were those with stage III CC and those treated with XELOX (at least as the first course of treatment) in the French IDEA study ([ClinicalTrials.gov](#) identifier, NCT00958737; EudraCT number, 2009-010384-16). Patients were excluded from the present analysis if the first cycle of chemotherapy had been the FOLFOX6 modified regimen.

Each patient provided written informed consent before undergoing any study-related procedures. The study was conducted in accordance with the Declaration of Helsinki and Good Clinical Practice guidelines.

### Study Design

The IDEA international collaboration was established to prospectively pool and analyze data from multiple randomized trials to answer the question of whether a 3-month course of oxaliplatin-based adjuvant therapy (FOLFOX4 or modified FOLFOX6 or XELOX) is noninferior to the current standard 6-month treatment in patients with stage III CC. The 3-year DFS was the primary endpoint. We retrospectively studied the data from patients with stage III CC treated with the XELOX regimen identified from the IDEA France trial database (protocol Groupe Coopérateur Multidisciplinaire en Oncologie [GERCOR] C09-1). Baseline demographic and clinicopathologic data were collected by review of the individual patient medical records, including age, sex, body mass index, TN stage, and tumor grade. Details of the chemotherapy received included the first and final chemotherapy cycles; total dose of oxaliplatin, capecitabine, and 5-FU administrated per cycle; reasons for ending treatment, and conversion rate of XELOX to FOLFOX. Additional information regarding the route of chemotherapy administration was collected from the investigators through a specific questionnaire. These data included the date and reasons for CVAD insertion and the occurrence of PVA-related complications, such as extravasation, deterioration of the patient's peripheral veins, lymphangitis, thrombosis, pain, and other complications. The patients were divided into 2 treatment groups: the CVAD group and the PVA group, consisting of patients with and without a CVAD for the first chemotherapy cycle, respectively.

### Treatment

Treatment consisted of 3 or 6 months of chemotherapy with the modified FOLFOX6 (6 or 12 cycles) or XELOX (4 or 8 cycles). The XELOX regimen consisted of oxaliplatin, administered as a 130 mg/m<sup>2</sup> intravenous infusion over 2 hours (on day 1, every 3 weeks), combined with capecitabine, administered orally at a dose of 1000 mg/m<sup>2</sup> twice daily (for a total daily dose of 2000 mg/m<sup>2</sup>; with the first evening dose on day 1 and the last morning dose on day 15). The XELOX regimen was given as intermittent treatment (3-week cycle consisting of 2 weeks of treatment followed by 1 week off). The choice between the 2 treatment regimens was decided by the patient and investigator. The choice between CVAD or PVA administration of oxaliplatin was the investigator's decision.

Dose modification because of adverse events and toxicity was conducted according to the IDEA France protocol.

## Study Endpoints

The primary endpoint was the feasibility of XELOX chemotherapy without a CVAD. Chemotherapy without a CVAD was defined as “feasible” if administered for all cycles of adjuvant chemotherapy and “not feasible” if a CVAD was placed for the second cycle, whatever the reason. The secondary endpoints were the number of patients who required CVAD placement after initial PVA insertion, the interval between PVA removal and CVAD insertion, and the rate and type of PVA-related complications.

The conversion rate from XELOX to FOLFOX and the exposure to oxaliplatin therapy (number of cycles and doses) in each group were also evaluated.

## Statistical Analysis

All eligible patients identified in the IDEA France study were included in the present retrospective study, without any formal statistical power calculations for sample size. Descriptive statistics (number of subjects, median, and average) were used for quantitative variables and percentages for qualitative variables. Pearson's  $\chi^2$  test or the appropriate Fisher exact test was used to evaluate the statistical significance of the differences between the 2 groups. The Student *t* test was used for continuous variables. All tests were performed 2-sided, and *P* < .05 was considered statistically significant.

## Results

### Patient Population

A total of 203 of the 2023 patients (10.0%) from the IDEA France database were considered eligible for the present study. Of these, 86 (42.4%) were classified into the PVA group and 116 (57.1%) into the CVAD group. One patient in the PVA group was not treated. The main characteristics of the eligible patients are listed in [Table 1](#). The distribution of patient characteristics at baseline was similar between the 2 groups, except for tumor grade differentiation.

Table 1 Baseline Patient Characteristics			
Characteristic	CVAD Group (n = 116)	PVA Group (n = 86)	<i>P</i> Value
Age (years)			
Median	66	64	.50
Range	35-86	20-87	—
>70 years	38 (32.8)	26 (30.2)	.69
Sex			.63
Male	69 (59.4)	54 (62.8)	
Female	46 (39.6)	32 (37.2)	
BMI (kg/m <sup>2</sup> )			.50
Median	25	24	
Range	16-42	16-36	
Chemotherapy delay			.73
>4 wk	108 (93.1)	82 (95.3)	
≤4 wk	5 (4.3)	3 (3.5)	
Unknown	3 (2.6)	1 (1.2)	
Treatment arm			.46
3 mo	64 (55.2)	43 (50)	

6 mo	52 (44.8)	43 (50)	
T stage			.052
T1	1 (0.9)	7 (8.1)	
T2	13 (11.2)	7 (8.1)	
T3	85 (73.3)	57 (66.3)	
T4	17 (14.6)	14 (16.3)	
Unknown	0 (0)	1 (1.2)	
N stage			.24
N1	91 (78.4)	73 (84.9)	
N2	25 (21.6)	13 (15.1)	
Differentiation grade			<.05
Well	25 (21.5)	40 (46.6)	
Moderate	75 (64.7)	39 (45.3)	
Poor	10 (8.6)	2 (2.3)	
Unknown	6 (5.2)	5 (5.8)	

Data presented as n (%), unless otherwise noted.

Abbreviations: BMI = body mass index; CVAD = central venous access device; PVA = peripheral venous access.

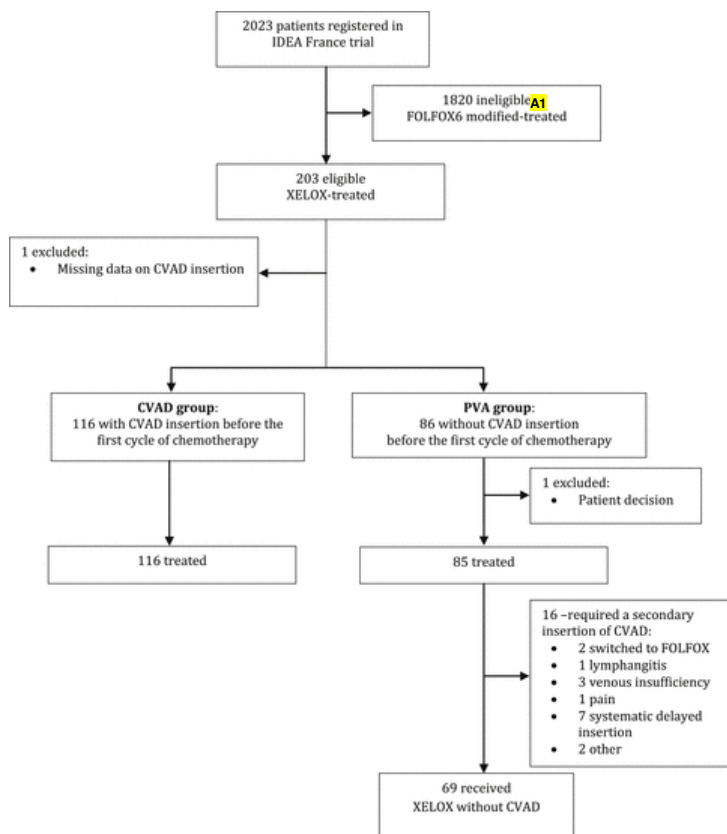
**Table 2** Chemotherapy Exposure

Oxaliplatin	XELOX 3 mo			XELOX 6 mo		
	CVAD Group (n = 64)	PVA Group (n = 43)	<i>P</i> Value	CVAD Group (n = 52)	PVA Group (n = 43)	<i>P</i> Value
Median no. of cycles	4	4	NA	8	7	NA
Median dose (mg/m <sup>2</sup> )	878	882	.23	1430	1306	.55

Abbreviations: CVAD = central venous access device; NA = not applicable; PVA = peripheral venous access; XELOX = capecitabine and oxaliplatin.

## Chemotherapy Administration

In the PVA group, 1 patient was not treated, and 85 patients had chemotherapy administered without a CVAD for the first cycle. Of these 85 patients, 69 (81.2%) did not require the insertion of a CVAD, and 16 (18.8%) did require CVAD insertion. CVAD insertion was required because of complications related to PVA usage in 5, a systematic delay of the initially planned CVAD implantation (with the CVAD placed before the second cycle of chemotherapy) in 7, a switch to the FOLFOX regimen in 2, and other reasons in 2 ([Figure 1](#)). Five (5.8%) of the PVA-related complications were related to deterioration of the venous capital or lymphangitis (n = 4) or pain (n = 1). No cases of chemotherapy extravasation or thrombosis developed. For the 7 patients for whom implantation of a CVAD had initially been planned, the CVAD was implanted after the first cycle of chemotherapy (without previous evaluation of the venous capital) owing to a delay in scheduling catheter insertion. The median interval to CVAD insertion was 20 days (range, 5-88). Of the 7 patients in the systematic delayed insertion group ([Figure 1](#)), 6 received XELOX for 6 months and 1 received XELOX for 3 months.



**Figure 1** Flow Chart

Abbreviations: CVAD = central venous access device; [modified FOLFOX6](#) = 5-fluorouracil and leucovorin plus oxaliplatin; IDEA = International Duration Evaluation of Adjuvant Chemotherapy; PVA = peripheral venous access; XELOX = capecitabine, oxaliplatin.

#### Annotations:

A1. modified FOLFOX6-treated

In the CVAD group, 102 patients (87.9%) underwent systematic CVAD implantation before the first cycle of treatment. Twelve patients (10.3%) underwent CVAD implantation because of venous insufficiency and two (1.7%) for other reasons.

The conversion rate from XELOX to FOLFOX6 modified was 2.3% in the PVA group and 7.7% in the CVAD group.

## Oxaliplatin Exposure

In both groups (CVAD and PVA), patients treated with [XELOX](#) for 3 months received a median of 4 cycles of oxaliplatin ([Table 2](#)). The median cumulative dose of oxaliplatin did not differ significantly between the 2 groups (878 mg/m<sup>2</sup> and 882 mg/m<sup>2</sup>, respectively;  $P = .23$ ). For patients treated with XELOX in the 6-month arm, the median number of oxaliplatin cycles was 8 in the CVAD group and 7 in the PVA group, with no significant difference in the median cumulative dose of oxaliplatin between the 2 groups (1430 mg/m<sup>2</sup> and 1306 mg/m<sup>2</sup>, respectively;  $P = .55$ ).

## Discussion

The results of our study have shown that XELOX chemotherapy without a CVAD is a feasible approach for treating patients with stage III CC in the adjuvant setting. XELOX chemotherapy without a CVAD was successful in 81.2% of patients for whom a CVAD was not planned before the first cycle of chemotherapy and in [88.4%](#) of patients for whom chemotherapy had been planned without the use of CVAD.

The main indication for CVAD includes the need for venous access in patients undergoing prolonged intravenous chemotherapy or patients who are expected to be given vesicant drugs or other drugs associated with vascular intimal damage (administration of solutions with a pH < 5 or > 9, osmolarity > 500 mOsm/L), especially in patients with poor blood flow in the veins.<sup>14,15</sup> However, the insertion and use of the device can be accompanied by multiple early and late complications, mainly pneumothorax, catheter malposition, hemothorax, cardiac arrhythmia, and arterial puncture.<sup>15-18</sup> In the present series, only 5.8% of patients in the PVA group experienced complications related to deterioration of the venous capital or lymphangitis (n = 4), or pain (n = 1). The rate of pain associated with oxaliplatin infusion in the peripheral vein was probably underreported in the present analysis owing to the retrospective data collection using the study questionnaire.

Oxaliplatin, given its pharmacologic features (pH of 6 and osmolarity of 200 mOsm/L) and short-term duration (2-hour infusion for a maximal duration of 6 months), can be infused through a peripheral vein. In most cases, however, if 8 cycles are planned, oxaliplatin infusion will be stopped before the end of treatment owing to oxaliplatin-induced peripheral neuropathy.

Few studies have investigated the feasibility of oxaliplatin administration without using a CVAD. In the study by Yoshida et al.,<sup>13</sup> the safety and efficacy of CVAD-port-free chemotherapy administration of XELOX plus bevacizumab or XELOX alone by way of the median cubital vein in 144 patients with metastatic CRC was assessed. The investigators reported that this approach is appropriate in this setting.<sup>13</sup> Also, although 59% of the patients developed transient vascular pain, none required CVAD implantation or treatment delays with administration by way of a peripheral vein. In our study, XELOX chemotherapy without a CVAD proved to be feasible for 81.2% of patients with stage III CC in whom implantation of a CVAD was not planned before the first cycle of adjuvant treatment and for 88.4% of patients for whom chemotherapy was planned without the use of CVAD, without consequences in treatment exposure. Complications occurring in the absence of a CVAD were relatively rare and benign. The most common reasons that led to a second insertion site for placement of an implantable device were deterioration of the venous capital (8.2%) and a switch to the modified FOLFOX6 regimen (2.4%). The median number of XELOX cycles and the median dose of oxaliplatin were similar in the CVAD and PVA groups for the 3- and 6-month adjuvant chemotherapy durations. However, we found that a CVAD was inserted before oxaliplatin administration in about 57% of cases (CVAD group). In most of the centers, this procedure was performed systematically and in only few cases because of insufficient venous capital. The present analysis was retrospective using data collected from a questionnaire sent to the principal investigators and therefore clearly subject to recall bias and prone to incomplete data.

Most patients prefer oral to intravenous chemotherapy because of its convenience and with the understanding that efficacy will not be sacrificed and their quality of life will be improved.<sup>19-21</sup> Likewise, administration of adjuvant chemotherapy without a CVAD is more convenient for patients. Without a CVAD, the risks of complications related to its placement (eg, pneumothorax, infection, thrombosis) are eliminated and a cicatrix will be absent, an issue particularly important for women. In addition, such an approach eliminates the need for catheter implementation and reduces CVAD system complications and costs. In France, the FOLFOX regimen is the standard of care for stage III CC because of the results of the MOSAIC study.<sup>4,7</sup> The XELOX regimen is not usually used in this setting. In the French IDEA population, the investigators had a choice between these 2 regimens (modified FOLFOX6 or XELOX), and the XELOX regimen was the offered treatment for only 10% of patients. Nurses and physicians will usually request CVAD implantation before a patient begins intravenous chemotherapy. Our analysis has demonstrated that it is possible to administer the XELOX regimen without a CVAD for most patients.

Systematic CVAD implementation before XELOX adjuvant chemotherapy does not appear to be justified. However, a careful assessment of the patient's venous capital by an experimented nurse or physician can better guide the decision of whether a CVAD should be placed, without compromising the patient's anticancer treatment and still respecting the patient's wishes. The implementation of this approach in clinical practice can offer an effective method of generating cost-savings in terms of public health<sup>22</sup> and will become a recommendation, especially if the international IDEA collaboration demonstrates that 3 months of chemotherapy combining fluoropyrimidines with oxaliplatin is noninferior to 6 months of chemotherapy.

## Conclusion

In the present study, we have demonstrated that XELOX chemotherapy without a CVAD is a feasible approach for treating most patients with stage III CC in the adjuvant setting without adverse consequence in treatment exposure. From a clinical standpoint, our findings contribute toward a better orientation of therapeutic decisions. An appropriate assessment of the patient's venous capital by the nurse or physician can better guide decision on whether a CVAD should be placed, with the aim of maximizing the patient's anticancer treatment benefit and minimizing the impairments to the patient's quality of life.

## Clinical Practice Points

- The standard adjuvant treatment regimens for patients with stage III CC consists of the combination of fluoropyrimidine (intravenous 5-FU and LV or oral capecitabine) and oxaliplatin (FOLFOX or XELOX) for 6 months.
- Oxaliplatin administration through a peripheral vein does not induce a severe risk of skin toxicity in the case of extravasation.
- Oxaliplatin infusion without the need for a **central venous access device (CVAD)** has been reported in patients with metastatic CC; however, very few data have been published regarding this aspect, and most oncologists request placement of a CVAD before the first cycle of chemotherapy.
- In the present study, 56% of patients with stage III CC underwent systematic insertion of a CVAD before the first cycle of adjuvant XELOX and 44% began the first cycle of chemotherapy with PVA and without a CVAD.
- For patients without a CVAD at the first cycle of treatment, 18.8% required CVAD insertion for the second cycle for different reasons, principally related to deterioration of the venous capital or lymphangitis.



- A careful assessment of the patient's venous capital by an experienced nurse or physician can better guide the decision of whether a CVDA should be placed, without compromising the patient's anticancer treatment and respecting the patient's wishes.

## Disclosure

B. Chibaudel reports personal fees for consultancy from Roche and Sanofi. O Bouché reports personal fees from Roche, Merck-Sereno, and Amgen. A Lièvre reports honoraria from Merck Serono, Amgen, Sanofi, and Roche. T André reports personal fees from Roche, Amgen, Sanofi, and Merck. No potential conflicts of interest were disclosed by the other authors.

## Acknowledgments

The authors thank the patients, their caregivers, and all the study investigators listed: Albert Aleba (Centre Hospitalier Niort, Niort), Jean-Baptiste Bachet (Groupe Hospitalier Universitaire Pitié Salpêtrière, Paris), Julien Baudon (Centre Hospitalier de Cholet, Cholet), Isabelle Baumgaertner (Centre Hospitalier Universitaire Henri Mondor, Creteil), Yves Becouarn (Institut Bergonié, Bordeaux), Nathalie Bonichon-Lamichhane (Clinique Tivoli, Bordeaux), Christian Borel (Centre Régional de Lutte Contre le Cancer Paul Strauss, Strasbourg), Karine Bouhier Leporrier (Centre Hospitalier Universitaire Côte de Nacre, Caen), Gilles Breysacher (Hôpital Louis Pasteur, Colmar), Jérôme Desrame (Hôpital Jean Mermoz, Lyon), Françoise Desseigne (Centre Léon Berard, Lyon), Louis Maris Dourthe (Clinique Sainte Anne, Strasbourg), Olivier Dupuis (Clinique Victor Hugo, le Mans), Marie Pierre Galais (Centre François Baclesse, Caen), Dany Gargot (Centre Hospitalier Blois, Blois), François Ghiringhelli (Centre G. F. Leclerc, Dijon), Denis Golfain (Centre Hospitalier Général, Dreux), Michel Gozy (Clinique de l'Europe, Amiens), Nathalie Grossat (Centre Hospitalier Universitaire Albert Clarac, Fort de France), Véronique Guerin Meyer (Centre Paul Papin, Angers), Fanny Kayal (Centre Hospitalier Macon, Macon), Cédric Lecaille (Polyclinique Nord Aquitaine, Bordeaux), Christine Lefoll (Centre Hospitalier Lagny, Lagny), Cécile Leyronnas (Institut Daniel Hollard, Grenoble), Jean-Pierre Lotz (Hôpital Tenon, Paris), Laurent Mineur (Institut Sainte Catherine, Avignon), Laurent Mosser (Centre Hospitalier Jacques Puel, Rodez), Christian Platini (Centre Hospitalier Régional Metz-Thionville, Metz), Sandrine Oziel-Taieb (Institut Paoli Calmettes, Marseille), Arnaud Patenotte (Hôpital Robert Morlevat, Semur en Auxois), Mathieu Pawels (Centre Hospitalier d'Abbeville, Abbeville), Patricia Prost (Centre Hospitalier Fleyriat, Bourg en Bresse), Mohamed Ramdani (Centre Hospitalier Béziers, Beziers), Eric Terrebonne (Hôpital du Haut-Lévêque, Pessac), Anne Thiroit-Bidault (Centre Hospitalier Universitaire Bicetre-Kremlin, Bicetre), Thomas Walter (Hôpital Edouard Herriot, Lyon). We thank Dr Magdalena Benetkiewicz (Groupe Coopérateur Multidisciplinaire en Oncologie) for her editorial assistance with the preparation of the manuscript. This study was funded by the National Cancer Clinical Research Programme 2009 and the French National Cancer Institute.

## References

### 1

. J. Ferlay, I. Soerjomataram, M. Ervik, et al., GLOBOCAN 2012 v1.0, Cancer Incidence and Mortality Worldwide: IARC CancerBase No. 11, [Internet]2013, International Agency for Research on Cancer; Lyon, France, Available at: <http://globocan.iarc.fr>, Accessed April 24, 2015.

### 2

. C.G. Moertel, T.R. Fleming, J.S. Macdonald, et al., Levamisole and fluorouracil as adjuvant therapy of resected colon carcinoma, *N Engl J Med* **322**, 1990, 352–358.

### 3

. International Multicentre Pooled Analysis of Colon Cancer Trials (IMPACT) Investigators, Efficacy of adjuvant fluorouracil and folinic acid in colon cancer, *Lancet* **345**, 1995, 939–944.

### 4

. T. André, C. Boni, M. Navarro, et al., Improved overall survival with oxaliplatin, fluorouracil, and leucovorin as adjuvant treatment in stage II or III colon cancer in the MOSAIC trial, *J Clin Oncol* **27**, 2009, 3109–3116.

### 5

. J.P. Kuebler, H.S. Wieand, M.J. O'Connell, et al., Oxaliplatin combined with weekly bolus fluorouracil and leucovorin as surgical adjuvant chemotherapy for stage II and III colon cancer: results from NSABP C-07, *J Clin Oncol* **25**, 2007, 2198–2204.

### 6

. G. Yothers, M.J. O'Connell, C.J. Allegra, et al., Oxaliplatin as adjuvant therapy for colon cancer: updated results of NSABP C-07 trial, including survival and subset analyses, *J Clin Oncol* **29**, 2011, 3768–3774.

## 7

. T. André, C. Boni, L. Mounedji-Boudiaf, et al., Multicenter international study of oxaliplatin/5-fluorouracil/leucovorin in the adjuvant treatment of colon cancer (MOSAIC) investigators: oxaliplatin, fluorouracil, and leucovorin as adjuvant treatment for colon cancer, *N Engl J Med* **350**, 2004, 2343–2351.

## 8

. C. Twelves, A. Wong, M.P. Nowacki, et al., Capecitabine as adjuvant treatment for stage III colon cancer, *N Engl J Med* **352**, 2005, 2696–2704.

## 9

. D.G. Haller, J. Tabernero, J. Maroun, et al., Capecitabine plus oxaliplatin compared with fluorouracil and folinic acid as adjuvant therapy for stage III colon cancer, *J Clin Oncol* **29**, 2011, 1465–1471.

## 10

. H.J. Schmoll, J. Tabernero, J.A. Maroun, et al., Capecitabine plus oxaliplatin compared with fluorouracil/folinic acid as adjuvant therapy for stage III colon cancer: final results of the NO16968 randomized controlled phase III trial, *J Clin Oncol* **33**, 2015, 3733–3740.

## 11

. T. André, T. Iveson, R. Labianca, et al., The IDEA (International Duration Evaluation of Adjuvant Chemotherapy) collaboration: prospective combined analysis of phase III trials investigating duration of adjuvant therapy with the FOLFOX (FOLFOX4 or modified FOLFOX6) or XELOX (3 versus 6 months) regimen for patients with stage III colon cancer: trial design and current status, *Curr Colorectal Cancer Rep* **9**, 2013, 261–269.

## 12

. Bouchoud L, Rochon F, Decosterd S, et al. Extravasation de cytostatiques: procédure de prise en charge approuvée par la COMED, version 6, 2012. Available at: <https://www.yumpu.com/fr/document/view/11734004/extravasation-de-cytostatiques-procedure-de-prise-hug/7>. Accessed April 24, 2015.

## 13

. Y. Yoshida, S. Hoshino, N. Aisu, et al., Administration of chemotherapy via the median cubital vein without implantable central venous access ports: port-free chemotherapy for metastatic colorectal cancer patients, *Int J Clin Oncol* **20**, 2015, 332–337.

## 14

. G. Maurizio, M. Pittiruti and R. Biffi, Vascular access in oncology patients, *CA Cancer J Clin* **58**, 2008, 323–346.

## 15

. Registered Nurses' Association of Ontario. Nursing Best Practice Guidelines. Project: Assessment and Device Selection for Vascular Access. Available at: [www.rnao.org/bestpractices](http://www.rnao.org/bestpractices). Accessed April 24, 2015.

## 16

. N. Barbetakis, C. Asteriou, A. Kleontas, et al., Totally implantable central venous access ports: analysis of 700 cases, *J Surg Oncol* **104**, 2011, 654–656.

## 17

. J.T. Kim, T.Y. Oh, W.H. Chang, et al., Clinical review and analysis of complications of totally implantable venous access devices for chemotherapy, *Med Oncol* **29**, 2012, 1361–1364.

## 18

. H. Sawayama, N. Hayashi, M. Watanabe, et al., The central vein access port and catheter in outpatient chemotherapy for colorectal cancer: a retrospective study of 101 patients, *Surg Today* **42**, 2012, 29–34.

## 19

. C. Twelves, S. Gollins, R. Grieve, et al., A randomised cross-over trial comparing patient preference for oral capecitabine and 5-fluorouracil/leucovorin regimens in patients with advanced colorectal cancer, *Ann Oncol* **17**, 2006, 239–245.

## 20

. G. Liu, E. Franssen, M. Fitch, et al., Patient preferences for oral versus intravenous palliative chemotherapy, *J Clin Oncol* **15**, 1997, 110–115.

## 21

- . M.M. Borner, P. Schoffski, R. de wit, et al., Patient preference and pharmacokinetics of oral modulated uFT versus intravenous fluorouracil and leucovorin: a randomised crossover trial in advanced colorectal cancer, *Eur J Cancer* **38**, 2002, 349–358.

## 22

- . R. Biffi, F. de Braud, F. Orsi, et al., Totally implantable central venous access ports for long-term chemotherapy a prospective study analyzing complications and costs of 333 devices with a minimum follow-up of 180 days, *Ann Oncol* **9**, 1998, 767–773.