



**The combination of intra-arterial yttrium-90
radioembolization with systemic chemotherapy is a
promising method for the downstaging to surgery of
initially unresectable huge intrahepatic
cholangiocarcinoma**

M Rayar, Laurent Sulpice, J Edeline, Etienne Garin, G B Levi Sandri, B.
Meunier, Eveline Boucher, Karim Boudjema

► **To cite this version:**

M Rayar, Laurent Sulpice, J Edeline, Etienne Garin, G B Levi Sandri, et al.. The combination of intra-arterial yttrium-90 radioembolization with systemic chemotherapy is a promising method for the downstaging to surgery of initially unresectable huge intrahepatic cholangiocarcinoma. *Annals of Surgical Oncology*, 2015, 22 (9), pp.3102-8. 10.1245/s10434-014-4365-3 . hal-01146927

HAL Id: hal-01146927

<https://univ-rennes.hal.science/hal-01146927>

Submitted on 17 Nov 2015

HAL is a multi-disciplinary open access archive for the deposit and dissemination of scientific research documents, whether they are published or not. The documents may come from teaching and research institutions in France or abroad, or from public or private research centers.

L'archive ouverte pluridisciplinaire **HAL**, est destinée au dépôt et à la diffusion de documents scientifiques de niveau recherche, publiés ou non, émanant des établissements d'enseignement et de recherche français ou étrangers, des laboratoires publics ou privés.

The combination of intra-arterial yttrium-90 radioembolization with systemic chemotherapy is a promising method for the downstaging to surgery of initially unresectable huge intrahepatic cholangiocarcinoma

Running title: Cholangiocarcinoma downstaging with Ytt90

M. Rayar MD¹, L. Sulpice¹ MD PhD, J. Edeline² MD, E. Garin³ MD PhD, GB Levi Sandri¹ MD, B. Meunier¹ MD, E. Boucher² MD, and K. Boudjema¹ MD PhD.

¹ Service de Chirurgie Hépatobiliaire et Digestive. Hôpital Pontchaillou, Centre Hospitalier Universitaire de Rennes, Université de Rennes 1, France

² Service d'Oncologie Digestive, Centre Régional de Lutte contre le Cancer, Rennes, France

³ Service de Médecine Nucléaire, Centre Régional de Lutte contre le Cancer, Rennes, France

Correspondence:

Pr Karim Boudjema. Service de Chirurgie Hépatobiliaire et Digestive. Hôpital Pontchaillou, Centre Hospitalier Universitaire de Rennes, France

karim.boudjema@chu-rennes.fr

Conflicts of Interest and Source of Funding:

E.Garin is consultant for BTG. For the remaining authors none were declared.

No external source of funding.

Synopsis:

Surgical resection is the only potential curative treatment of intra-hepatic cholangiocarcinoma (ICC). However, few patients are resectable and currently no treatments have proved efficacy for the downstaging. We report our experience of 8 initially unresectable ICC, downstaged by Yttrium-90 radioembolization plus systemic chemotherapy, and secondarily operated.

Abstract

Purpose: To evaluate the downstaging efficacy of yttrium-90 radioembolization (Ytt-90)-associated with chemotherapy and the results of surgery for initially unresectable huge ICC.

Methods: Between January 2008 and October 2013, unresectable ICC were treated with chemotherapy and Ytt-90. Patients with unique tumors localized to non-cirrhotic livers and without extra-hepatic metastasis were considered as potentially resectable and were evaluated every 2 months for possible secondary resection.

Results: Forty-five patients were treated for unresectable ICCs; 10 had potentially resectable tumors, and 8 underwent surgery. Initial unresectability was due to the involvement of the hepatic veins or portal vein of the future liver remnant in 7 and 1 cases, respectively. Pre-operative treatment induced significant decreases in tumor volume (295 versus 168 ml, $p=0.02$) and allowed for R0 resection in all cases. Three (37.5%) patients had Clavien-Dindo grade ≥ 3 complications, including two postoperative deaths. The median follow-ups were 15.6 [4 – 40.7] months after medical treatment initiation and 7.2 [0.13 - 36.4] months post-surgery. At the end of the study period, five patients were still alive with one patient still alive 40 months after medical treatment initiation (36.4 months post-surgery), two patients experienced recurrences.

Conclusions: For initially unresectable huge ICCs, chemotherapy with Ytt-90 radioembolization is an effective downstaging method that allows for secondary resectability.

INTRODUCTION:

Although rare, intrahepatic cholangiocarcinomas (ICC) are the second most frequent primary liver cancer after hepatocellular carcinomas (HCC).^{1, 2} ICC account for 5 to 10% of primary liver malignancies,¹ and their incidence has significantly increased over the last two decades³⁻⁵.

Complete surgical resection remains the only potentially curative treatment^{6, 7}. However, because these tumors remain clinically silent, patients are generally diagnosed when the tumors are huge. Resection is therefore frequently impossible or incomplete,⁷ and recurrence rates remain high.⁸⁻¹⁰

For patients with huge ICC, non-resectability results from the vascular involvement (i.e., glissonian vessels and hepatic veins) of the potential future liver remnant (FLR). In these patients, tumor downsizing can improve the resectability and eventually lead to curative treatment, regardless of the method used to achieve downsizing. Currently, no preoperative treatment has proven to be efficient in this setting.

Radioembolization using yttrium-90 (Ytt-90) has demonstrated its efficacy in the palliative treatment of HCC^{11, 12} and ICC.¹³⁻¹⁶ Our team has previously reported that, in HCC patients, Ytt-90 radioembolization is effective in reducing tumor volumes and simultaneously inducing hypertrophy of the liver contralateral to the tumor.¹⁷ This combined effect might allow for secondary resection in patients who are initially unresectable.

The aim of this study was to report our experience with initially unresectable patients with huge ICC who were first treated with a combination of intra-arterial Ytt-90 radioembolization and systemic chemotherapy and subsequently became secondarily resectable.

PATIENTS AND METHODS

Patients

Between January 2008 and October 2013, all patients with mass-forming type ICC that were judged to be unresectable by a multidisciplinary committee including oncologists, radiologists and senior surgeons were offered a combination of intra-arterial Ytt-90 radioembolization and systemic chemotherapy as a palliative treatment. The inclusion criteria were a biopsy-proven ICC, an Eastern Cooperation Oncology Group (ECOG) performance status ≤ 2 ,¹⁸ and adequate liver function (i.e., a normal bilirubin blood level). The treated patients were closely monitored with physical examinations, biology tests, evaluations of the side effects after each chemotherapy cycle, and CT-scans every 2 months.

This retrospective study received approval from the local ethical committee (authorization number 14.28).

Chemotherapy and Ytt-90 radioembolization

Systemic chemotherapy was first initiated using gemcitabine and/or platinum salts.

Gemcitabine was not administered in the cycles before and after each radioembolization to avoid possible increases in toxicity.

The Ytt-90 radioembolizations were administered few weeks after the initiation of the chemotherapy as previously described.¹⁷ Briefly, a supra-selective diagnostic angiography with Tc-99m macro-aggregated albumin was first performed to evaluate pulmonary shunting and the absence of digestive uptake and to calculate the Ytt-90 activity according to target volume. Therapeutic arteriography was performed 8 days later using glass microspheres (Therasphere®). When necessary, a second injection was administered 1 month later to treat the entire tumor. Chemotherapy was pursued after radioembolization.

Tumor response and resectability criteria:

All patients underwent CT-scan prior to the initiation of chemotherapy and every 2 months thereafter with evaluation of the tumor responses by the multidisciplinary committee. Patients with solitary tumors on non-cirrhotic livers and an absence of extra-hepatic metastases were considered for potential resection. Resectability was defined as the possible complete removal of the tumor regardless of the margin width and regardless of the technique (i.e., in situ or ex vivo resections) and with the use of complex vascular reconstruction when necessary. When tumor resectability was possible in terms of the anatomical criteria, but the future liver remnant volume (FLRV) represented less than 30% of the total liver volume (TLV), additional portal vein embolization was performed. The liver resections included hilar lymphadenectomy in all cases. The extrahepatic bile duct was resected when necessary, and bilioenteric anastomosis using a Roux-en-Y was performed. The time between the last chemotherapy cycle and the surgery was at least one month.

Survival analyses

The overall survivals (OS) were calculated from the time of the initiation of chemotherapy and from the time of surgery.

Disease-free survivals (DFS) were calculated from time of surgery.

Statistical analyses

The quantitative variables are expressed as the medians with ranges. Categorical variables are expressed as numbers and percentages. Volumetric values were compared with paired Wilcoxon tests.

Survival analyses were performed using the Kaplan-Meier method. Statistical analyses were performed with the R statistical software version 3.0.0. Volumetric analyses were performed using the Myrian® Xp liver software. Differences were considered significant when $p < 0.05$.

RESULTS

During the study period, 45 patients were treated with a combination of systemic chemotherapy and intra-arterial Ytt-90 radioembolization for unresectable ICCs. Twenty-seven (60%) patients had multiples lesions and/or extra-hepatic disease and were treated in a palliative intent. Four (9%) patients were treated for tumor recurrence. Among the 14 (31%) patients remaining, 4 had liver cirrhosis with portal hypertension. Eventually, 10 patients had single huge ICCs that developed non-cirrhotic liver without extrahepatic disease and were considered for potential resection. Ultimately, 8 patients (5 women and 3 men) underwent surgical resection with curative intent and represent our study population. The 2 remaining patients were not resected due to tumoral progression. (Figure 1)

Among these eight resected patients, the initial unresectabilities were due to tumoral involvement of the hepatic veins (HV) of the FLR in seven cases and tumoral involvement of the portal pedicle of the FLR in the remaining case. The demographic data and tumor characteristics of the resected patients are reported in table 1.

Pre-operative treatment:

All eight patients received a median of seven cycles [range: 3 - 18] of systemic chemotherapy. Chemotherapy associated gemcitabine (six cases) or 5-fluorouracil (two cases) with a platinum salts (oxaliplatin in five cases, and cisplatin in three cases).

Intra-arterial Ytt-90 was administered with a median injected activity of 2 GBq [1.5-3.2]. Two patients underwent two successive radioembolization procedures, in order to treat the entire tumoral volume. The median duration of chemo-radioembolization therapy (i.e., the time from the initiation of chemotherapy until surgery) was 7.6 months [3.4 – 16.7]. Tolerance was excellent, and no patient presented grade III or higher toxicity.

Tumor downstaging and FLRV hypertrophy:

There was no difference between the pre- and post-treatment median TLVs (1530 ml [1200-3580] versus 1372 ml [1255 – 2000]; $p=0.16$), and the tumor volume downsizing was significant (295 ml [90-1250] versus 168 ml [46 – 535]; $p=0.02$). Figures 2 show three representative cases of tumor shrinkage after treatment.

There was no significant difference between the pre- and post-treatment median FLRVs (467 ml [185 - 917] versus 507.5 ml [310 -795], respectively; $p=0.46$), while the median FLRV/TLV ratio significantly increased (27.2% vs. 35.9%, $p=0.04$) and was greater than 30% in 7 cases [30.0% – 49.7%]. The remaining patient had a pre-treatment FLRV/TLV ratio of 23.8%, which reached 38.5 % after PVE.

Surgical procedure:

The resections were performed *in situ* with the exception of one patient who underwent an *ex vivo* surgery because complex vascular reconstruction was required. Extended hepatectomies (i.e., resection of at least five segments) were performed in all cases including right hepatectomies extended to segment 1 in two cases (25%), right trisectionectomy extended to segment 1 in five cases (62.5%) and a left trisectionectomy in one case (12.5%).¹⁹

The biliary confluence and the extrahepatic biliary tree were resected in two cases with bilio-enteric reconstruction. The retro-hepatic inferior vena cava (IVC) was resected in four cases (laterally in two cases and totally in two cases with vascular prosthetic replacement). The median duration of surgery was 210 min [150-600]. All *in situ* resections were performed under continuous simultaneous clamping of the portal pedicle and the infrahepatic IVC. Three (37.5%) patients required blood transfusion.

R0 resection was achieved in all patients.

Postoperative course (table 2):

Three (37.5%) patients experienced Clavien-Dindo complication of grade 3 or more during their hospital stays. Among these three patients, two died. One patient had a sudden massive stroke on postoperative day 9 (1 day before planned discharge). The second patient had undergone an ex vivo resection of the tumor with arterial, portal and suprahepatic vein reconstructions and developed severe liver failure due to thrombosis of both the hepatic artery and portal vein. Urgent liver revascularization did not prevent the fatal evolution at postoperative day 4.

None of the remaining patients exhibited bile leakage or post-operative hemorrhage.

The median hospital stay duration was 9.5 days [4 – 21].

Midterm evolution and survival analysis

The median follow up time of the entire serie was 15.6 months [4 – 40.7] from the initiation of medical treatment and 7.2 months [0.13 - 36.4] from the date of surgery.

Among the six patients who survived the postoperative period, one patient (aged 80 years old) died 6.5 months after surgery (14 months after the initiation of treatment) without evidence of initial disease recurrence, and five patients were still alive (figure 3). The median follow-up for these six patients was 16.9 [15.2 – 40.7] months after the initiation of medical treatment (8.2 [2 – 36.4] months after surgery).

Two patients experienced recurrences. One patient exhibited lung metastasis 19 months after surgery and received chemotherapy and stereotaxic radiotherapy and is still alive 36.4 month after the surgery (40.7 months after medical treatment initiation). The other patient exhibited multiple-site metastases (lung, liver, and liver hilum lymph nodes) 7 months after surgery

(15.1 month after the initiation of medical treatment). The median disease-free survival was 19.1 months when considering recurrence only.

Discussion

ICC is a primary liver tumor whose incidence and mortality are increasing in western countries.⁵ Complete surgical resection is the only available treatment that allows for prolonged survival. For unresectable patients, survival without treatment is under one year.²⁰ As the lesion remains clinically silent, ICCs are generally diagnosed at an advanced stage, and only a minority of patients can be resected. Indeed, Tan et al.⁷ reported a global resection rate of 12 %, with only 37% of the potentially resectable patients (defined by single unilobar tumors without evidence of vascular invasion) who were eventually resected.

In the present study, of the 10 patients who were eligible for surgery, eight (80%) patients with single localized ICCs who were initially considered unresectable were offered a complete resection after the induction treatment of combined chemotherapy and Ytt-90 radioembolization.

For unresectable ICCs, systemic chemotherapy (associating Gemcitabine and platinum salt) produces a response rate of 20-35% and a median overall survival of 10 - 15 month.²¹⁻²⁵ Such low efficiency is also associated with a high rate of grade 3 - 4 toxicity.²¹ Ytt-90 radioembolization is a novel and promising therapy for the palliative treatment of ICC, and, to our knowledge, five studies (two from the same team) have reported median overall survivals of 9.3 to 22 months after treatment.^{13-16, 26} In a study by Ibrahim et al.,¹³ one patient was downstaged to resection, and another patient was downstaged to liver transplantation. This study was expanded to 46 patients,¹⁶ and three additional patients were eventually resected or transplanted. Saxena et al.¹⁴ also reported one patient who was downstaged to surgery.

Reported tolerances of Ytt-90 radioembolization were excellent and usually better than other intra-arterial treatment.^{27, 28} In our study, no patients presented severe toxicity (grade III or higher) and particularly no liver adverse effect. Moreover, as no postoperative bile leakage

was observed, we could consider that Yt-90 radioembolization is a suitable treatment before liver resection, as liver parenchyma seemed not to be altered even after multiple procedures. Recently, Servajean et al.²⁹ reported a case of a huge ICC with involvement of the three hepatic veins that was initially non-resectable. After Yt-90 radioembolization with resin microspheres (SIRS-spheres®) combined with chemotherapy (eight cycles before and four cycles after radioembolization), the patient underwent a left hepatectomy that was enlarged to segment 8 with a free margin between the tumor and the right hepatic vein.

In our study, 8/10 patients were eventually resected. This high percentage compared to the published results might have been because only solitary tumors and non-cirrhotic livers were considered for surgery. Indeed, we did not offer extended liver resection to patients with cirrhotic liver even when the FLRV was greater than 30%. For such patients, liver transplantation might be a potential therapeutic option. Indeed, we believe that liver transplantation was not an appropriate option for these patients because, in our series, recurrence after surgery was primarily extra hepatic (i.e., lung localizations in the two patients), which suggests that extra hepatic microscopic disease might have been present at the time of surgery.

Although pre-operative treatment induced significant tumor volume reductions, R0 resection could only be achieved through extended hepatectomy with the removal of at least five segments, and half of the patients also had complex vascular reconstructions (including IVC resection in 4 cases and ex-vivo surgery in 1 case). These factors might explain our postoperative mortality rate. However, the mortality rate should be interpreted in light of Wang et al.'s nomogram,³⁰ which predicts 3-year survival rates below < 15% among patients with similar huge ICCs with vascular involvements. Moreover, it should be noted that one of the two postoperative deaths was not related to the surgery.

After complete resection, ICC's recurrence rate remained high, and recurrence typically occurred within the first year after surgery.^{8, 31} In our series, two of the six patients who were alive after the postoperative course exhibited recurrence, but no deaths related to tumor recurrence were observed. These findings might suggest that recurrences were managed more efficiently after removal of the primary lesion, and a parallel could be drawn with management of unresectable liver metastases from colorectal cancer.³²

Recently, Ytt-90 radioembolization was also proposed as an alternative to PVE in HCC cirrhotic patients.¹⁷ Our results support these findings because only one patient required PVE prior to surgery to increase the FLRV/TLV ratio above 30%. However, in our series, the increase in the FLR/TLV ratio was primarily due to liver tumor shrinkage rather than hypertrophy of the FLRV.

Our series is currently the largest to report on secondarily resected patients with ICC after downstaging with Ytt-90 radioembolization plus systemic chemotherapy but has some limitations. First, our downstaging rate of 80% was biased by our patient's selection criteria as we only considered patients with unique tumor on non-cirrhotic liver and without extrahepatic disease, which represents only 10/45 (22%) patients. Second, our population included only eight patients, and the median follow-up time remains limited. Therefore, we cannot yet outline the oncological interest of the method. However, considering the time from the initiation of chemotherapy, nearly all patients were followed up for more than 1 year, and one patient remained alive 3 years after surgery. We intentionally did not compare the survival of the 8 resected patients with the 37 remaining patients since these 2 groups were different (unresected patients had generally multiple hepatic tumours and/or extrahepatic metastases).

In conclusion, our experiences is the largest serie that support the notion that Ytt-90 radioembolization plus systemic chemotherapy might be an effective therapeutic option to

downstage huge, unique and initially non-resectable ICCs for secondary resections. Larger numbers of patients and longer follow-up times are obviously required to further validate this perspective.

Acknowledgments :

M. Rayar contributed to study design, manuscript writing, data collection, statistical analysis and manuscript reviewing.

L.Sulpice contributed to study design, manuscript writing and manuscript reviewing.

J.Edeline contributed to data collection and manuscript reviewing.

E.Boucher contributed to data collection and manuscript reviewing.

E.Garin contributed to data collection and manuscript reviewing.

G.B. Levi Sandri contributed to data collection and statistical analysis.

B. Meunier contribute to data collection and manuscript reviewing

K. Boudjema contribute to study design, manuscript writing, data collection and manuscript reviewing.

REFERENCES

1. Endo I, Gonen M, Yopp AC, et al. Intrahepatic cholangiocarcinoma: rising frequency, improved survival, and determinants of outcome after resection. *Ann Surg* 2008; 248:84-96.
2. Rizvi S, Gores GJ. Pathogenesis, diagnosis, and management of cholangiocarcinoma. *Gastroenterology* 2013; 145:1215-29.
3. Siegel R, Ma J, Zou Z, Jemal A. Cancer statistics, 2014. *CA Cancer J Clin* 2014; 64:9-29.
4. Dodson RM, Weiss MJ, Cosgrove D, et al. Intrahepatic cholangiocarcinoma: management options and emerging therapies. *J Am Coll Surg* 2013; 217:736-750 e4.
5. Patel T. Increasing incidence and mortality of primary intrahepatic cholangiocarcinoma in the United States. *Hepatology* 2001; 33:1353-7.
6. Farges O, Fuks D. Clinical presentation and management of intrahepatic cholangiocarcinoma. *Gastroenterol Clin Biol* 2010; 34:191-9.
7. Tan JC, Coburn NG, Baxter NN, et al. Surgical management of intrahepatic cholangiocarcinoma--a population-based study. *Ann Surg Oncol* 2008; 15:600-8.
8. Sulpice L, Rayar M, Boucher E, et al. Treatment of recurrent intrahepatic cholangiocarcinoma. *Br J Surg* 2012; 99:1711-7.
9. Nathan H, Pawlik TM, Wolfgang CL, et al. Trends in survival after surgery for cholangiocarcinoma: a 30-year population-based SEER database analysis. *J Gastrointest Surg* 2007; 11:1488-96; discussion 1496-7.
10. Ohtsuka M, Ito H, Kimura F, et al. Results of surgical treatment for intrahepatic cholangiocarcinoma and clinicopathological factors influencing survival. *Br J Surg* 2002; 89:1525-31.

11. Geschwind JF, Salem R, Carr BI, et al. Yttrium-90 microspheres for the treatment of hepatocellular carcinoma. *Gastroenterology* 2004; 127(5 Suppl 1):S194-205.
12. Vente MA, Wondergem M, van der Tweel I, et al. Yttrium-90 microsphere radioembolization for the treatment of liver malignancies: a structured meta-analysis. *Eur Radiol* 2009; 19:951-9.
13. Ibrahim SM, Mulcahy MF, Lewandowski RJ, et al. Treatment of unresectable cholangiocarcinoma using yttrium-90 microspheres: results from a pilot study. *Cancer* 2008; 113:2119-28.
14. Saxena A, Bester L, Chua TC, et al. Yttrium-90 radiotherapy for unresectable intrahepatic cholangiocarcinoma: a preliminary assessment of this novel treatment option. *Ann Surg Oncol* 2010; 17:484-91.
15. Rafi S, Piduru SM, El-Rayes B, et al. Yttrium-90 radioembolization for unresectable standard-chemorefractory intrahepatic cholangiocarcinoma: survival, efficacy, and safety study. *Cardiovasc Intervent Radiol* 2013; 36:440-8.
16. Mouli S, Memon K, Baker T, et al. Yttrium-90 radioembolization for intrahepatic cholangiocarcinoma: safety, response, and survival analysis. *J Vasc Interv Radiol* 2013; 24:1227-34.
17. Edeline J, Lenoir L, Boudjema K, et al. Volumetric changes after (90)y radioembolization for hepatocellular carcinoma in cirrhosis: an option to portal vein embolization in a preoperative setting? *Ann Surg Oncol* 2013; 20:2518-25.
18. Oken MM, Creech RH, Tormey DC, et al. Toxicity and response criteria of the Eastern Cooperative Oncology Group. *Am J Clin Oncol* 1982; 5:649-55.
19. Strasberg SM, Phillips C. Use and dissemination of the brisbane 2000 nomenclature of liver anatomy and resections. *Ann Surg* 2013; 257:377-82.
20. Chou FF, Sheen-Chen SM, Chen YS, et al. Surgical treatment of cholangiocarcinoma. *Hepatogastroenterology* 1997; 44:760-5.

21. Valle J, Wasan H, Palmer DH, et al. Cisplatin plus gemcitabine versus gemcitabine for biliary tract cancer. *N Engl J Med* 2010; 362:1273-81.
22. Kiba T, Nishimura T, Matsumoto S, et al. Single-agent gemcitabine for biliary tract cancers. Study outcomes and systematic review of the literature. *Oncology* 2006; 70:358-65.
23. Lee GW, Kang JH, Kim HG, et al. Combination chemotherapy with gemcitabine and cisplatin as first-line treatment for immunohistochemically proven cholangiocarcinoma. *Am J Clin Oncol* 2006; 29:127-31.
24. Knox JJ, Hedley D, Oza A, et al. Combining gemcitabine and capecitabine in patients with advanced biliary cancer: a phase II trial. *J Clin Oncol* 2005; 23:2332-8.
25. Andre T, Tournigand C, Rosmorduc O, et al. Gemcitabine combined with oxaliplatin (GEMOX) in advanced biliary tract adenocarcinoma: a GERCOR study. *Ann Oncol* 2004; 15:1339-43.
26. Hoffmann RT, Paprottka PM, Schon A, et al. Transarterial hepatic yttrium-90 radioembolization in patients with unresectable intrahepatic cholangiocarcinoma: factors associated with prolonged survival. *Cardiovasc Intervent Radiol*; 35:105-16.
27. Hyder O, Marsh JW, Salem R, et al. Intra-arterial therapy for advanced intrahepatic cholangiocarcinoma: a multi-institutional analysis. *Ann Surg Oncol* 2013; 20:3779-86.
28. Benson AB, 3rd, Geschwind JF, Mulcahy MF, et al. Radioembolisation for liver metastases: results from a prospective 151 patient multi-institutional phase II study. *Eur J Cancer*; 49:3122-30.
29. Servajean C, Gilabert M, Piana G, et al. One case of intrahepatic cholangiocarcinoma amenable to resection after radioembolization. *World J Gastroenterol*; 20:5131-4.
30. Wang Y, Li J, Xia Y, et al. Prognostic nomogram for intrahepatic cholangiocarcinoma after partial hepatectomy. *J Clin Oncol*; 31:1188-95.

31. Mavros MN, Economopoulos KP, Alexiou VG, Pawlik TM. Treatment and Prognosis for Patients With Intrahepatic Cholangiocarcinoma: Systematic Review and Meta-analysis. *JAMA Surg* 2014.
32. de Mestier L, Manceau G, Neuzillet C, et al. Primary tumor resection in colorectal cancer with unresectable synchronous metastases: A review. *World J Gastrointest Oncol* 2014; 6:156-69.

Figure titles and legends:

Figure 1

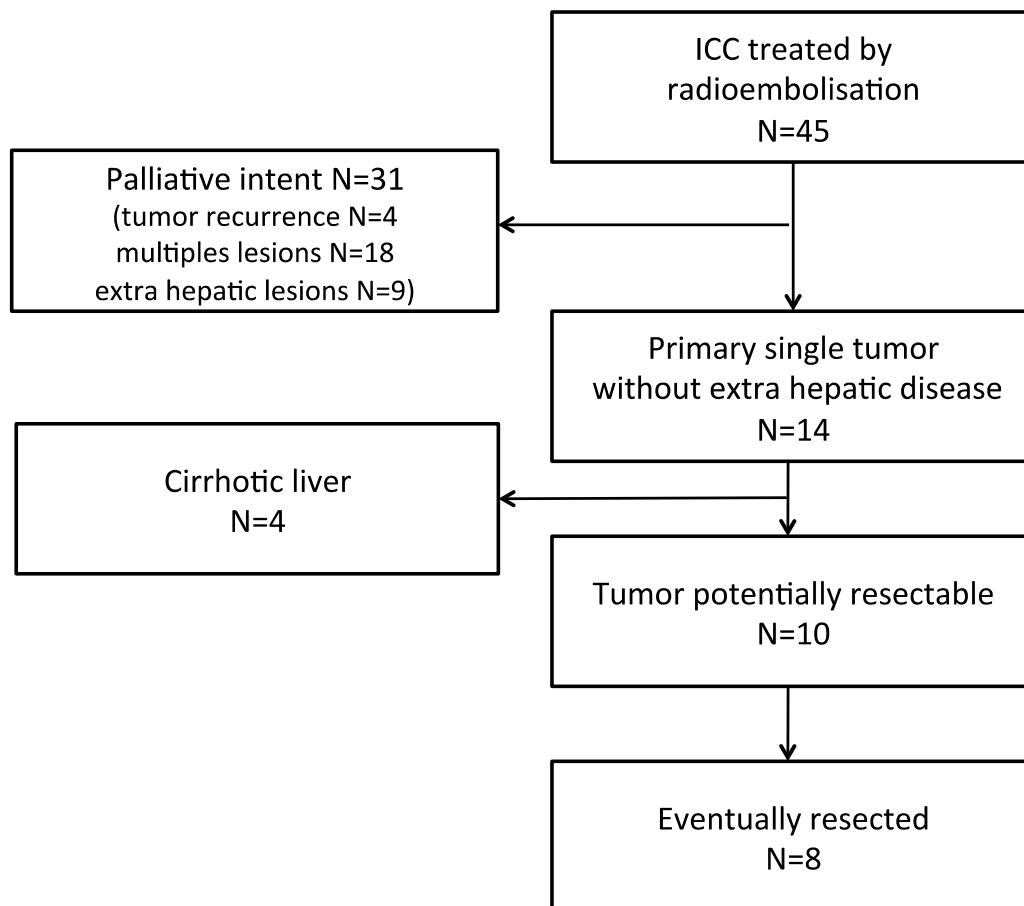


Figure 1: Flow chart of the patients with unresectable ICCs who were treated with Yt-90 radioembolization and resected in our institution.

Figure 2

Les paramètres nécessaires sont manquants ou erronés.





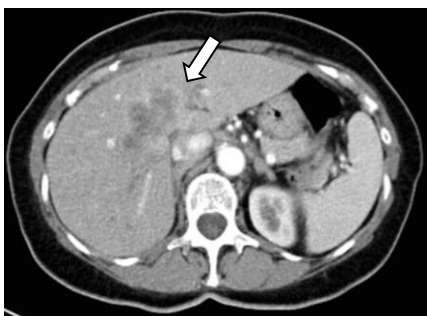
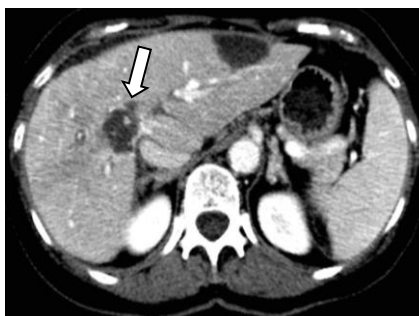
	Initial	Preop.
A		<p>5Fluorouracyl + Cisplatin (6 cycles) Yttrium-90 (2.24 Bq) Time interval: 3 m</p> 
B		<p>Gemcitabine + Cisplatin (4 cycles) Yttrium-90 (2.0 Bq) Time interval : 5 m</p> 
C		<p>Capecitabine + Cisplatin (4 cycles) Yttrium-90 (1.95 Bq) Time interval:2 m</p> 

Figure 2: Three representative cases of tumor downstaging from our series.

A: A 66-year-old woman with a 9-cm lesion. Initially, the tumor deeply infiltrated the right anterior section up to the median hepatic vein. After treatment, tumor downstaging and left liver hypertrophy allowed for the safe performance of a right hepatectomy that extended to segment 1 with partial resection of inferior retro-hepatic vena cava.

B: A 39-year-old man with a 20-cm lesion. Initially, the tumor was in contact with the origin of the left portal pedicle and involved the three hepatic veins. After treatment, significant downstaging of the tumor and hypertrophy of the left liver allowed for the performance of a R0 right trisectionectomy with resection of the inferior retro-hepatic vena cava.

C: A 70-year-old woman with a 6.5-cm-diameter central lesion. Initially, the tumor seemed to infiltrate the left portal pedicle. After treatment, the tumor shrinkage and liver remnant hypertrophy allowed for the performance of a right trisectionectomy that extended to segment 1 with biliary confluence resection.

Figure 3:

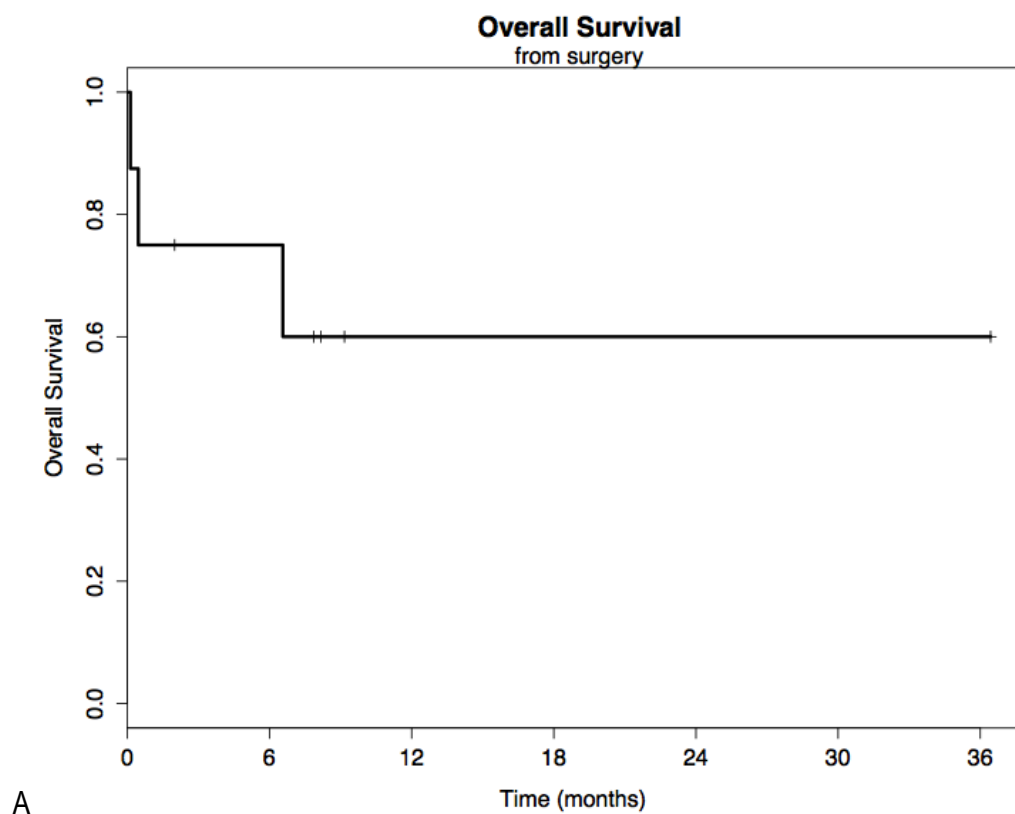


Figure 3: Overall survival of the resected patients.

A: Overall survival from the day of surgery.

B: Overall survival from the initiation of chemotherapy.

Table 1: Clinical features of the resected patients.

Variables	
Age (years) *	68 [39 - 79]
Sex ratio (M/F)	0.6 (3/5)
BMI*	23 [19 - 27]
ASA score	
0	2 (25%)
1	4 (50%)
2	2 (25%)
ECOG status	
0	4 (50%)
1	4 (50%)
2	0
CA 19-9 level (KU/l) at time of diagnosis*	18.5 [10 – 1125]
Tumor size* before treatment (cm)	9.2 [6.5 – 20]
Vascular involvement of the FLR	
Artery	0
Portal vein	1 (12.5%)
Hepatic veins	7 (87.5%)
Retro hepatic inferior vena cava	4 (50%)
Biliary confluence	2 (25%)
Lymph node invasion	3 (37.5%)
hilar	3 (37.5%)
distant	2 (25%)
Tumor distribution	
Unilobar	3 (37.5%)
Bilobar	5 (62.5%)

* median value [range].

Table 2: Operative and post-operative parameters.

Variables	
Major resection	8 (100%)
right-side hepatectomy	7 (87.5%)
left-side hepatectomy	1 (12.5%)
Number of segments resected*	6 [5 – 6]
Duration (min)*	210 (150 -600)
Transfusion	3 (37.5%)
Bile leakage	0
Liver failure	2 (25%)
Postoperative hemorrhage	0
Ascitis	3 (37.5%)
Reoperation	2 (25%)
Clavien classification:	
<3	5 (62.5%)
3	1 (12.5%)
4	0
5	2 (25%)
Hospital stay duration (days)*	9.5 [4-21]

* Median values [ranges].