



HAL
open science

Anti-glomerular basement membrane disease, ulcerative colitis, and primary sclerosing cholangitis: link or co-incidence?

Emilie Pinçon, Guillaume Bouguen, Guillaume Coiffier, Joseph Rivalan,
Patrick Le Pogamp, Nathalie Rioux-Leclercq, Cecile Vigneau

► To cite this version:

Emilie Pinçon, Guillaume Bouguen, Guillaume Coiffier, Joseph Rivalan, Patrick Le Pogamp, et al.. Anti-glomerular basement membrane disease, ulcerative colitis, and primary sclerosing cholangitis: link or co-incidence?. *Nephrology Reviews*, 2010, 2 (1), pp.47-48. 10.4081/nr.2010.e10. hal-01117592

HAL Id: hal-01117592

<https://univ-rennes.hal.science/hal-01117592>

Submitted on 17 Feb 2015

HAL is a multi-disciplinary open access archive for the deposit and dissemination of scientific research documents, whether they are published or not. The documents may come from teaching and research institutions in France or abroad, or from public or private research centers.

L'archive ouverte pluridisciplinaire **HAL**, est destinée au dépôt et à la diffusion de documents scientifiques de niveau recherche, publiés ou non, émanant des établissements d'enseignement et de recherche français ou étrangers, des laboratoires publics ou privés.



Distributed under a Creative Commons Attribution - NonCommercial - NoDerivatives 4.0 International License

Anti-glomerular basement membrane disease, ulcerative colitis, and primary sclerosing cholangitis: link or co-incidence?

Emilie Pinçon,¹ Guillaume Bouguen,² Guillaume Coiffier,¹ Joseph Rivalan,¹ Patrick Le Pogamp,¹ Nathalie Rioux-Leclercq,^{3,4} Cecile Vigneau^{1,4}

¹Service de néphrologie, CHU Pontchaillou, Rennes;

²Service de gastroentérologie, CHU Pontchaillou, Rennes;

³Service d'anatomie et cytologie pathologiques, CHU Pontchaillou, Rennes;

⁴UMR 6061/IFR 140, Université Rennes 1, Rennes, France

Abstract

Ulcerative colitis, primary sclerosing cholangitis, and anti-glomerular basement membrane disease (anti-GBM) are three rare immune diseases with incompletely understood pathogenic mechanisms. We describe here the case of a 29-year-old man with ulcerative colitis and primary sclerosing cholangitis who, eight years later, developed anti-GBM disease with destruction of all glomeruli leading to end-stage kidney disease. Association of these three immune diseases in the same patient has never been described. Because HLA-mediated susceptibility cannot be incriminated completely in our case, we hypothesize that environmental factors or previous immunosuppressive treatment used might be the link.

Introduction

Anti-glomerular basement membrane (anti-GBM) disease is mediated by auto-antibodies, leading to crescentic glomerulonephritis.¹ Ulcerative colitis (UC) is a chronic inflammatory bowel disease (IBD), the cause of which is incompletely understood but may be immunologic.² Primary sclerosing cholangitis (PSC) is a cholestatic liver disease often associated with UC.

Here, we describe a patient who developed first UC and PSC and, a few years later, anti-GBM glomerulonephritis. This case raises the question of whether this is a coincidence or whether there is a link between these three diseases.

Case Report

Mr B., a 29-year-old white man, was admitted because he complained of a high fever lasting for two weeks, without any other clinical sign except herpetic keratitis (treated with valacyclovir for seven days). His past medical history included UC eight years earlier (with a histological diagnosis and p-ANCA detected by indirect immunofluorescence but without specificity detected by the ELISA test). He had been treated successively with 5-aminosalicylic acid, steroids for approximately three years (with high corticoid dependence), azathioprine for one month (gastrointestinal intolerance), infliximab (nine infusions ineffective), and finally a complete colectomy six years previously. UC was associated with a liver biopsy-proved PSC (biopsy performed six years before for anicteric cholestasis). He also presented with cutaneous biopsy-proved lichen planus. Since the colectomy and during the six years, he did not require any therapy.

An initial blood test showed a serum creatinine of 113 $\mu\text{mol/L}$ and an increased C-reactive protein (CRP) of 103 mg/L. Because of a

persistent high fever, after four days our patient was referred to the emergency unit. Blood tests showed acute renal failure (creatinine: 507 $\mu\text{mol/L}$; urea: 17.9 mmol/L) with inflammatory syndrome (CRP: 294 mg/L; white blood cell count: 14,900 G/L). At the time of admission, Mr B. was febrile at 40°C and his blood pressure was 150/90 mmHg. Apart from cutaneous lichen planus, the clinical examination was unremarkable. He was oliguric; his stools were abundant as usual. Urinalysis showed 3+ blood and 3+ protein, with proteinuria quantified at 1.17g/L on oliguric diuresis. Serum creatinine increased up to 800 $\mu\text{mol/L}$; the blood picture showed hemoglobin 12.8 g/dL, white blood cell count 18,800 G/L, platelets 503,000 G/L, and CRP increased up to 320 mg/L. Oxygen saturation and the thoracic CT-scan were normal.

A complete search for infectious disease, with urine and blood cultures for bacterial and fungal infections (including BK), and serology and PCR for viral infection, as well as stool cultures and a chest X-ray, was negative. Anti-GBM antibodies were positive (32 U/mL). ANCA were positive on immunofluorescence but without any specificity with ELISA testing. Antinuclear factor was 1/160 flecked with anti-SSA; the complement proteins assay was normal; plasma protein electrophoresis revealed hypoalbuminemia (24 g/L) and elevated α -globulins. A renal biopsy showed extensive exuberant crescent with necrotizing changes in 90% of glomeruli (Figure 1). Glomerular tufts were considerably compressed with thrombotic changes. The interstitium and tubules had inflammatory edema. Immunofluorescence revealed linear deposition of IgG along capillary loops. His *MHC* gene was typed: A1A3 B8B40 DRB1*01, DRB1*03, DQB1*02, DQB1*05.

Owing to the clinical severity and our patient's young age, despite the poor histological prognosis, Mr B. received three courses of methylprednisolone followed by oral prednisolone and cyclophosphamide (2 mg/kg daily). Plasma exchange was performed daily

Correspondence: Emilie Pinçon, CHU Pontchaillou, Rennes, France.

E-mail: emilie.pincon@chu-rennes.fr

Key words: anti-GBM glomerulonephritis, primary sclerosing cholangitis, ulcerative colitis.

Acknowledgment: Stuart Fraser, for English assistance.

Conflict of interest: the authors report no conflicts of interest.

Received for publication: 22 April 2010.

Revision received: 12 July 2010.

Accepted for publication: 13 July 2010.

This work is licensed under a Creative Commons Attribution 3.0 License (by-nc 3.0).

©Copyright E. Pinçon et al., 2010
Licensee PAGEPress, Italy
Nephrology Reviews 2010; 2:e10
doi:10.4081/nr.2010.e10

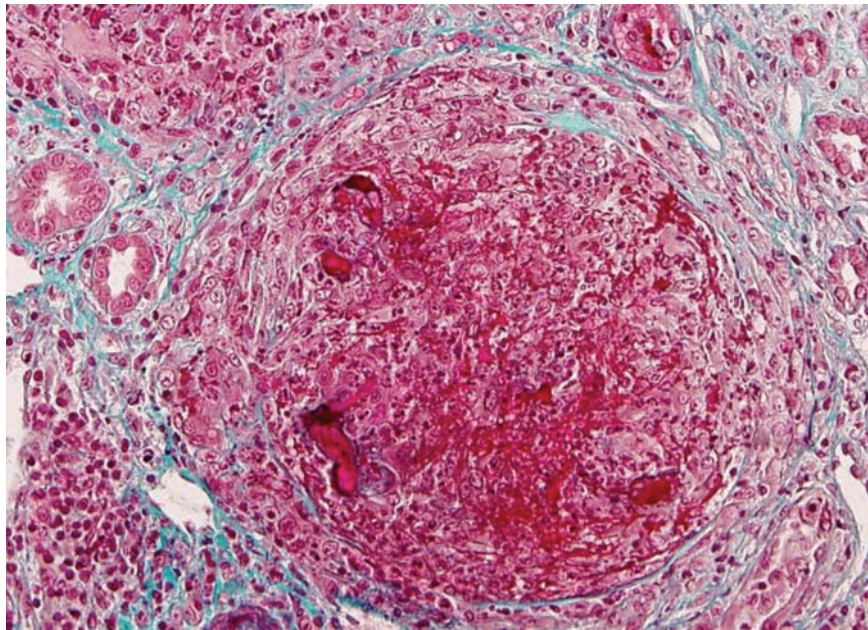


Figure 1. Abundant necrotizing changes with the glomerular tuft entirely compressed by a voluminous crescent. (High-power; trichrome stain.)

for 15 days (5L plasma per treatment, albumin plus hydroxyethylamidon as replacement fluid). At the same time, renal replacement therapy was started. Despite immunosuppressive therapy and plasma exchanges, Mr B. remained on hemodialysis.

Discussion

This association of three severe immune diseases in the same young patient is intriguing. The first association of UC and anti-GBM glomerulonephritis was described in one child who developed an UC four years after his renal transplantation for end-stage renal disease owing to anti-GBM disease.³ The authors hypothesized that HLA DR2 homozygosity may have predisposed to both immune diseases. Nakamura *et al.* described the case of a woman who developed UC 19 months after the onset of anti-GBM disease.⁴ She was also homozygous for the DR2 allele. Plaisier *et al.* reported a patient who developed anti-GBM nephritis and bullous pemphigoid in the context of Crohn's disease relapse.⁵ The authors hypothesized that an infectious aggression can result in a simultaneous relapse of Crohn's disease and exposure of the Goodpasture antigenic site recognized as foreign. Finally, our case is the fourth reported case and the first one associated with PSC. Our case raises the question: is there a relationship between UC, PSC, and anti-GBM nephropathy?

The first link might be the HLA susceptibility. There is indeed a strong association between anti-GBM disease and the *HLA-DR2* gene, which is present in approximately 80%

of cases.⁶ However, contrary to the first two described cases, the HLA genotype of our patient was not DR2. A study revealed a neutral association of DRB1*03 (carried by our patient) but a decreased frequency of DRB1*01 (also carried by our patient) in anti-GBM nephritis.⁷ The DRB1*03 is known to confer a high risk to develop PSC but less risk of UC.⁸ Therefore, our patient's HLA genotype cannot easily explain the association of these immune diseases. The second link might be trigger factors such as drugs or upper respiratory infection. However, in our case like in the first two other cases, diseases were not simultaneous but separate by years. Mr B. did have an HSV infection that might have triggered the glomerulopathy but he did not have it when he developed UC. In IBD, lymphocytes activated by bacterially-derived antigens can transfer to the kidneys and cause inflammation that leads to exposure of the Goodpasture antigenic site.⁹ However, because our patient was colectomized, he no longer presented with colitis, which makes this triggering mechanism unlikely. Thirdly, another hypothesis could be that previous immunosuppressive therapy received by Mr B. changed his profile of autoantibody response. In the case described by Hibbs *et al.*,³ the patient also developed an autoimmune disease while on post-transplant immunosuppressive therapy. However, despite the large number of patients under immunosuppressive therapy for organ transplantations, very few developed IBD, likewise pleading against this hypothesis. There are some reports of autoimmune processes developing after infliximab therapy; principally cutaneous vasculitis, lupus, and interstitial lung disease, but no glomerulonephritis to date.¹⁰ Is inflix-

imab the link for our patient?

In conclusion, we present the fourth case of the association of anti-GBM disease and UC, and the first one associated with PSC. The HLA genotype, or an environmental or infectious trigger, or long-term previous immunosuppressive treatment (except for treatment with infliximab) does not seem to be the link. Thus, is there a link or is it coincidence?

References

1. Kalluri R, Wilson CB, Weber M, et al. Identification of the alpha 3 chain of type IV collagen as the common autoantigen in antibasement membrane disease and Goodpasture syndrome. *J Am Soc Nephrol* 1995;6:1178-85.
2. Sartor RB. Current concepts of the etiology and pathogenesis of ulcerative colitis and Crohn's disease. *Gastroenterol Clin North Am* 1995;24:475-507.
3. Hibbs AM, Bznik-Cizman B, Guttenberg M, et al. Ulcerative colitis in a renal transplant patient with previous Goodpasture disease. *Pediatr Nephrol* 2001;16:543-6.
4. Nakamura T, Suzuki Y, Koide H. Granulocyte and monocyte adsorption apheresis in a patient with antglomerular basement membrane glomerulonephritis and active ulcerative colitis. *Am J Med Sci* 2003;325:296-8.
5. Plaisier E, Borradori L, Hellmark T, et al. Anti-glomerular basement membrane nephritis and bullous pemphigoid caused by distinct anti-alpha 3(IV)NC1 and anti-BP180 antibodies in a patient with Crohn's disease. *Am J Kidney Dis* 2002;40:649-54.
6. Phelps RG, Rees AJ. The HLA complex in Goodpasture's disease: a model for analyzing susceptibility to autoimmunity. *Kidney Int* 1999;56:1638-53.
7. Fisher M, Pusey CD, Vaughan RW, Rees AJ. Susceptibility to anti-glomerular basement membrane disease is strongly associated with HLA-DRB1 genes. *Kidney Int* 1997;51:222-9.
8. Reinshagen M, Loeliger C, Kuehn P, et al. HLA class II gene frequencies in Crohn's disease: a population-based analysis in Germany. *Gut* 1996;38:538-42.
9. Fantini MC, Pallone F, Monteleone G. Common immunologic mechanisms in inflammatory bowel disease and spondylarthropathies. *World J Gastroenterol* 2009;15:2472-8.
10. Ramos-Casals M, Brito-Zerón P, Muñoz S, et al. Autoimmune diseases induced by TNF-targeted therapies: analysis of 233 cases. *Medicine (Baltimore)* 2007;86:242-51.