



HAL
open science

Long-term effectiveness and safety of interleukin-1 receptor antagonist (anakinra) in Schnitzler's syndrome: A French multicenter study.

Antoine Néel, Benoît Henry, Sebastien Barbarot, Agathe Masseur, François Perrin, Claire Bernier, Xavier Kyndt, Xavier Puechal, Pierre-Jean Weiller, Olivier Decaux, et al.

► To cite this version:

Antoine Néel, Benoît Henry, Sebastien Barbarot, Agathe Masseur, François Perrin, et al.. Long-term effectiveness and safety of interleukin-1 receptor antagonist (anakinra) in Schnitzler's syndrome: A French multicenter study.. *Autoimmunity Reviews*, 2014, 13 (10), pp.1035-1041. 10.1016/j.autrev.2014.08.031 . hal-01072523

HAL Id: hal-01072523

<https://univ-rennes.hal.science/hal-01072523>

Submitted on 8 Oct 2014

HAL is a multi-disciplinary open access archive for the deposit and dissemination of scientific research documents, whether they are published or not. The documents may come from teaching and research institutions in France or abroad, or from public or private research centers.

L'archive ouverte pluridisciplinaire **HAL**, est destinée au dépôt et à la diffusion de documents scientifiques de niveau recherche, publiés ou non, émanant des établissements d'enseignement et de recherche français ou étrangers, des laboratoires publics ou privés.

Long-term Effectiveness and Safety of Interleukin-1 Receptor Antagonist (Anakinra) in Schnitzler's Syndrome: a French Multicenter Study

Antoine Néel¹ MD, Benoit Henry¹ MD, Sebastien Barbarot² MD, PhD, Agathe Masseau¹ MD, François Perrin¹ MD, Claire Bernier² MD, Xavier Kyndt³ MD, Xavier Puechal⁴ MD, PhD, Pierre-Jean Weiller⁵ MD, Olivier Decaux^{6,7} MD, PhD, Jacques Ninet⁸ MD, Arnaud Hot⁸ MD, Achille Aouba⁹ MD, Leonardo Astudillo¹⁰ MD, Jean-Marie Berthelot¹¹ MD, Fabrice Bonnet¹² MD, PhD, Jean-Marie Brisseau¹ MD, Bérangère Cador⁶ MD, Fabienne Closs-Prophette¹³ MD, Thomas Dejoie¹⁴ PharmD, Jean-Dominique de Korwin¹⁵ MD, Robin Dhote¹⁶ MD, Renato Fior⁹ MD, Bernard Grosbois^{6,7} MD, Eric Hachulla^{17,18,19} MD, PhD, Pierre-Yves Hatron^{17,18} MD, Henry Jardel²⁰ MD, David Launay^{17,18,19} MD, PhD, Adrien Lorleac'h²¹ MD, Pierre Pottier^{1,22} MD, Guillaume Moulis²³ MD, Jacques Serratrice⁵ MD, Amar Smail²³ MD, and Mohamed Hamidou^{1,22} MD.

Running head: Anakinra in Schnitzler's Syndrome

Corresponding author and reprint requests:

Dr Antoine Néel

Service de Médecine Interne

Centre Hospitalier Universitaire de Nantes – Hôtel Dieu

1 Place Alexis Ricordeau

44093 NANTES

Tel: +33.2.40.08.33.55; Fax: +33.2.40.08.33.79

Email: antoine.neel@univ-nantes.fr

Affiliations:

- | | |
|----------------------------------------------------------------------------------------------------------------|------------------------------|
| 1. CHU de Nantes, Service de Médecine Interne, F 44093 Nantes, France. | AN, BH, AM, FP, JMBr, PP, MH |
| 2. CHU de Nantes, Service de Dermatologie, F 44093 Nantes, France. | SB, CB |
| 3. CH de Valenciennes, Service de Médecine Interne-Néphrologie, F 59322 Valenciennes, France. | XK |
| 4. CHU Cochin (AP-HP), Département de Médecine Interne, F 75014 Paris, France. | XP |
| 5. CHU la Timone (AP-HM; Aix-Marseille Université), Service de Médecine Interne, F 13385 Marseille, France. | PJW, JS |
| 6. CHU de Rennes, Service de Médecine Interne, F 35033 Rennes, France. | OD, BC, BG |
| 7. Université Rennes 1, UMR CNRS 6290 IGRD, 35042 Rennes, France. | OD |
| 8. CHU Edouard Herriot (HCL), Service de Médecine Interne, F 69437 Lyon, France. | AH, JN |
| 9. CHU Antoine Bécclère (AP-HP), Service de Médecine Interne et Immunologie Clinique, F 92140 Clamart, France. | AA, RF |
| 10. CHU de Toulouse, Service de Médecine Interne, F 31059 Toulouse, France. | LA, GM |
| 11. CHU de Nantes, Service de Rhumatologie, F 44093 Nantes, France. | JMBe |
| 12. CHU de Bordeaux, Service de Médecine Interne et Maladies Infectieuses, F 33075 Bordeaux, France. | FB |
| 13. CH du Mans, Service de Médecine Polyvalente, F 72037 Le Mans, France. | FCP |
| 14. CHU de Nantes, Laboratoire de Biochimie, F 44093 Nantes, France. | TD |
| 15. CHU de Nancy, Service de Médecine Interne – Médecine Générale, F 54035 Nancy, France. | JDdK |
| 16. CHU Avicenne (AP-HP), Service de Médecine Interne, F 93009 Bobigny, France. | RD |
| 17. CHRU de Lille, Service de Médecine Interne et Immunologie Clinique, F 59037 Lille, France. | DL, EH, PYH |
| 18. Faculté de Médecine, Université Lille Nord de France, F59037 Lille, France | DL, EH, PYH |
| 19. EA2686, IMPRT IFR 114, F 59037 Lille, France. | DL, EH |
| 20. CH Bretagne Atlantique, Service de Médecine Interne, F 56017 Vannes, France. | HJ |
| 21. CH Bretagne Sud, Service de Médecine Interne et Maladies Infectieuses, F 56100 Lorient, France. | AL |
| 22. Faculté de Médecine, Université de Nantes, F44093 Nantes, France | PP, MH |
| 23. CHU d'Amiens, Service de Médecine Interne, F 80054 Amiens, France. | AS |

Key indexing terms:

Schnitzler's syndrome, IL-1 receptor antagonist, autoinflammatory disease, gammopathy, urticaria

Word count: Abstract: 250; Text: 2995

3 Tables; 3 Figures

ABSTRACT

Objective: To assess the long-term effectiveness and safety of IL1Ra in Schnitzler syndrome (SchS).

Methods: Between 2010 and 2012, we performed a nationwide survey among French internal medicine departments to identify SchS patients. We retrospectively analyzed the long-term efficacy and safety of IL1Ra and the outcome of patients that did not receive this treatment.

Results: Forty-two patients were included in the study, 29 of whom received IL1Ra. The mean age at disease onset was 59.9 years. Disease manifestations included urticaria (100%), fever (76%), bone/joint pain (86%), bone lesions (76%), anemia (67%), and weight loss (60%). The monoclonal gammopathy was overwhelmingly IgM kappa (83%). The mean follow-up was 9.5 years (range: 1.6–35). Two patients developed Waldenström's macroglobulinemia and one developed AA amyloidosis. All of the 29 patients who received IL1Ra responded dramatically. After a median follow-up of 36 months (range: 2–79), the effectiveness remained unchanged. All patients remained on anti-IL-1 therapy. Twenty-four patients (83%) went into complete remission and five (17%) into partial remission. Three patients experienced grade 3–4 neutropenia. Six patients developed severe infections. No lymphoproliferative diseases occurred while on IL1Ra. When last seen, all patients without anakinra had an active disease with variable impact on their quality of life. Their median corticosteroids dosage was 6 mg/d (range: 5–25).

Conclusions: IL1Ra is effective in SchS, with a sharp corticosteroid-sparing effect. Treatment failures should lead to reconsider the diagnosis. Long-term follow-up revealed no loss of effectiveness and a favorable tolerance profile. The long-term effects on the risk of hemopathy remain unknown.

1. Introduction

Schnitzler's syndrome (SchS) is a rare disease that manifests with a urticarial skin rash, monoclonal gammopathy (mostly IgM kappa), and a variable combination of recurrent fever, osteoarticular pain, sclerotic bone lesions, lymphadenopathy, and hepatosplenomegaly [1,2] This disease was first described by the French dermatologist Liliane Schnitzler almost 40 years ago (3,4), but even today it is still underdiagnosed [5].

Patients with SchS frequently exhibit an altered quality of life (QoL) because of recurrent fever, rash, pain, fatigue, and sometimes weight loss or anemia [1,2]. As with other patients with monoclonal gammopathy of undetermined significance, SchS patients may develop a hematological malignancy (usually Waldenström's macroglobulinemia). More infrequently, they can develop AA amyloidosis [6,7]. Conventional therapies, such as antihistamines, non-steroidal anti-inflammatory drugs (NSAID), corticosteroids, immunomodulating agents (colchicine and hydroxychloroquine), and pefloxacin, usually provide only partial or transient improvement of the symptoms [7]. Disease-modifying anti-rheumatic drugs are rarely useful [2,7]. In recent years, several case reports have revealed the remarkable efficacy of the interleukin-1 (IL-1) receptor antagonist (IL1Ra) anakinra on this disease [8,9]. Two small, open-label, non-comparative studies also demonstrated the short-term efficacy of the long-acting IL-1 blockers canakinumab [10] and riloncept [11]. Given the efficacy of blocking IL-1 activity towards treatment of this disease, phenotypical similarities between SchS and cryopyrin-associated periodic syndrome, and biological data suggesting a dysfunction of the inflammasome [11-15], most physicians and scientists consider SchS an acquired, late-onset auto-inflammatory disease [1,2,7,16]. However, the relationship between the systemic inflammation and the monoclonal component remains unknown.

Unfortunately, most data regarding the use of IL1Ra in SchS arise from case reports or very small study series. Therefore, long-term data regarding its efficacy, tolerance, and safety are scarce. Furthermore, the concern that some patients may not respond to IL-1 blockers has recently emerged [17,18] and the possibility of secondary treatment failure remains unknown (2).

Herein we report on the long-term effectiveness and safety of the off-label use of IL1Ra in SchS through a retrospective analysis of a multicenter cohort of 42 patients with SchS, of whom 29 were treated with IL1Ra.

2. Patients and Methods

2.1. Patients

In this study, we included all of the SchS patients evaluated at Nantes University Hospital since 1998 (n = 17). Further, we conducted a nationwide survey among all of the departments of internal medicine in France through the French Internal Medicine Society (Société Nationale Française de Médecine Interne) from 2010 to 2012. To be included, patients had to fulfill the diagnostic criteria proposed by Lipsker et al. in 2001 [19], irrespective of the recourse or the effect of IL-1 blockers. This observational study was performed in accordance with the Helsinki declaration, European and French ethical laws.

2.2. Data collection

Data were collected from charts using a standardized form that included the following information: gender, month/year of birth, date of first symptoms and diagnosis, disease manifestations, bone and thoracoabdominal imaging findings, previous therapies, significant comorbidities, clinico-biological features, concomitant treatments at the onset of IL1Ra use and at the last follow-up, secondary IL1Ra treatment failures, flare-ups following drug

interruption or tapering, IL1Ra withdrawal and its reason(s), severe infections (requiring hospitalization), injection site reactions, neutropenia and any other IL1Ra adverse effects, solid or hematologic malignancy, death and cause of death.

2.3. Disease activity measurement and response to IL1Ra

Physician assessment of SchS clinical activity was recorded using a semi-quantitative scale for skin rashes, pain, and fever (absent/rare-moderate/frequent-severe). Moderate and severe anemia was defined as 10–12 and <10 g/dL hemoglobin levels, respectively. Complete remission was defined as the disappearance of all clinical signs of disease activity (rash, fever, and pain) under IL1Ra monotherapy. Partial remission was defined based on the improvement of at least 50% of the SchS symptoms and systemic inflammation under IL1Ra treatment with persistence of over one sign of disease activity among the following: rash, pain, fever, and elevated C-reactive protein (CRP; >10 mg/L). For the longitudinal analysis of the monoclonal component level, all of the serum electrophoreses of patients followed at Nantes University Hospital were re-analyzed using a standard computer-assisted method.

2.4. Data Analysis

Categorical variables were expressed as percentages and compared using chi-squared tests or Fisher's exact tests, as appropriate. For quantitative variables, comparisons of independent groups and paired measurements were performed using the non-parametric Mann-Whitney tests and Wilcoxon signed-rank tests, respectively. Data analysis was performed using GraphPad Prism 4.02 software (GraphPad; San Diego, CA, USA). All tests were two-sided and a $p < 0.05$ was considered statistically significant.

3. Results

3.1. Cohort characteristics

The cohort included 42 SchS patients from 16 centers. There were 30 men and 12 women. The mean age at disease onset was 59.9 ± 11.9 years (range: 34–79). The mean diagnostic delay was 43 ± 36 months (range: 1–141).

Aside from the urticarial rash, fever and bone and joint pain were the most frequent complaints (Table 1). In addition, 25 patients experienced weight loss and 28 developed inflammatory anemia, with a hemoglobin level at <10 g/dL in 16 cases (38%).

Overall, 29 patients were treated with corticosteroids (69%), 26 received an immunomodulating agent (62%), 13 received an immunosuppressant or an alkylating agent (31%), and 3 received a non anti-IL1 biologic (7%). Twenty-nine patients were treated with IL1Ra (69%). The details on each treatment are reported in Table 2.

The mean follow-up was 9.5 years (range: 1.6–35). Two patients progressed toward a hematologic malignancy (Waldenström's macroglobulinemia), three and nine years after the first SchS symptoms (age: 63 and 75 years). One untreated patient developed renal AA amyloidosis. Four patients died (Table 3).

3.2. Patients treated with IL1Ra

Twenty-nine patients were treated with IL1Ra: 20 men and 9 women. At IL1Ra introduction, the mean age was 65.9 ± 10.7 years (range: 44–85) and mean disease duration was 7.5 ± 6.9 years (range: 10 months to 32 years). One patient received IL1Ra as a first-line therapy. Four patients received only symptomatic drugs (NSAID or antihistamines) prior to IL1Ra treatment. Twenty-four patients had failed at least one immunomodulating ($n = 20$), immunosuppressive ($n = 11$), or non anti-IL1 biologic ($n = 3$) treatment. Twenty-one patients received corticosteroids (72%).

From a clinical standpoint, all of the patients had an active disease at the point of IL1Ra introduction (Figure 1). All of them suffered recurrent or chronic skin rash, and 22 had severe extracutaneous symptoms (fever and/or bone pain; 76%). The remaining seven patients had no or moderate extracutaneous symptoms but severe anemia ($n = 1$), significant weight loss ($n = 4$), and/or fatigue ($n = 3$). Fifteen patients were corticosteroid dependent and their mean corticosteroid dose was 13.6 ± 8.4 mg/d of the equivalent prednisone (median: 10 mg/d) and the mean duration of corticosteroid therapy was 3.1 ± 3 years (range: 0.5–12.8). In addition, one patient with a long-standing (12 years) untreated IgM kappa SchS developed AA amyloidosis, which was revealed by nephrotic-range proteinuria (3–3.5 g/day). Amyloid deposits were discovered and typed using immunofluorescence, both with colon and accessory salivary gland biopsies.

3.3. Initial and long-term effectiveness of IL1Ra

All 29 treated patients experienced a dramatic improvement in all of the clinical signs of disease activity within 48 h after IL1Ra introduction, which enabled discontinuation of the concomitant therapies. Only three patients were maintained on low-dose corticosteroid therapy in order to alleviate residual symptoms.

After a median follow-up of 36 months (range: 3–79), the effectiveness of IL1Ra was unchanged. At the last follow-up under IL1Ra (Figure 1), 24 patients (83%) were in complete remission under IL1Ra monotherapy. Three had mild residual bone pain. Five patients (17%) were in partial remission. Among these, three were asymptomatic with normal CRP under IL1Ra treatment plus low-dose corticosteroids and two patients had intermittent skin rash and pain with normal CRP under IL1Ra monotherapy. The CRP level returned to normal in all of the patients in complete clinical remission, except one (Figure 2). The mean hemoglobin level rose from 11.2 to 13.4 g/dL ($p < 0.001$). Only one patient was switched to canakinumab

because he was in partial remission and experienced injection site reaction under IL1Ra. Canakinumab was well tolerated and maintained a comparable state of partial remission. For nineteen of the patients, IL1Ra injections were spaced out. Injections were done on alternate days; however, complete clinical remission was maintained in only four cases. Other patients had to resume back to daily injection.

Anakinra had no effect on the level of the IgM kappa monoclonal component (Figure 3). Of note, the latter was frequently present at a very low level.

3.4. Long-term tolerance and safety of IL1Ra

Injection site reactions were reported in five patients (17%). All of them could continue with the treatment. Six patients experienced severe infections, including one case of a severe sore throat and five cases of pneumonia. Importantly, among the patients that developed pneumonia, four out of the five had predisposing factors (three had severe chronic obstructive pulmonary disease (COPD) and one had dementia and parenteral feeding), aside from IL1Ra. The pneumonia was fatal in two of these cases. Three cases of uncomplicated neutropenia were recorded. In one patient, it did not recur after adjusting the IL1Ra dosage to weight (30 kg). In another patient, the neutrophil count normalized and complete remission persisted under alternate day injections. In the third case, neutropenia occurred on two occasions within 48 hours after IL1Ra introduction, but it did not recur on the third attempt.

One patient under IL1Ra treatment developed colon cancer during the follow-up. However, six other malignancy or pre-malignant states were observed in four patients that had not received IL1Ra at that time (colon, prostate, bladder, kidney, colon adenoma, and basal cell carcinoma).

3.5. Outcome of IL1Ra-naive patients

Thirteen patients did not receive IL1Ra treatment. Overall, disease manifestations were similar to that of patients that received IL1Ra, except for pain, which tended to be less frequent (Table 1). Clinical information at the last follow-up was available for 12 patients. All of them still harbored an active disease or had their disease controlled with corticosteroids. Eight patients were treated with corticosteroids (median dose: 6 mg/day; range: 5–25). Except for two patients, all of the cases had elevated CRP levels (median: 29.6 mg/L). Two patients received colchicine and one received chloraminophene. Compared to the patients that were treated with IL1Ra, the disease duration was comparable (median = 97 vs. 110 months, $p = 0.11$), but the IL1Ra-treated patients had less severe symptoms and biological abnormalities (Figures 1 and 2).

4. Discussion

In this study we assessed the long-term effectiveness, tolerance, and safety of IL1Ra treatment in patients with SchS. To the best of our knowledge, this is the largest series focusing on the management of these patients since the advent of IL-1-targeted therapies.

A wide range of drugs has been used in patients with SchS [2,7,20]. However, none of these treatments were reported to induce a complete, durable remission of the disease until the first report of the successful use of IL1Ra [8]. Since then, numerous case reports have confirmed this observation [2,9]. The present series confirmed the dramatic efficacy of IL1Ra in SchS, which appeared to be constant in our patients. Several authors have suggested that the response to IL1Ra treatment could be used as a diagnostic criterion [1]. However, we did not use this criterion in our study because we wanted to assay any cases of primary IL1Ra failure, which we did not observe in our patients. Therefore, we strongly believe that failures

in IL1Ra treatment should lead to a reconsideration of the diagnosis of SchS. Nevertheless, some authors have reported cases of primary failure of IL1Ra treatment. Krause et al. reported on three patients that were refractory to IL-1 blockers but responded to tocilizumab [17]. In a recent series, 5 out of 20 cases from the Mayo Clinic that received IL1Ra had mixed results: three were lost in the follow-up, one experienced a dramatic response, and one saw only minimal effects [18]. Therefore, it remained unclear whether the efficacy of IL1Ra was overestimated from publication bias or whether some cases were resistant to IL1Ra, which may represent a variant of the disease.

In this regard, one should note that in the three cases of IL1Ra-resistant cases reported by Krause et al., several atypical features were present [17]. First, in two of the cases, the gammopathy was not IgM kappa, even though this gammopathy isotype is a major indication of SchS [5]. Second, no data were provided on the bone imaging of these three patients. In our experience, and that of others [21], bone lesions are highly prevalent in SchS, provided that appropriate imaging techniques are used aside from conventional radiographs (i.e. technetium-99 (Tc99) bone scan). Third, two patients were reported to suffer from recurrent ocular inflammation, which is not a typical feature of bona fide SchS. Indeed, we encountered only one patient that developed a single ocular inflammation in our study. Altogether, these elements, along with our findings, suggest that IL1Ra refractory patients are exceedingly rare and that they may represent a variant of SchS. Indeed, one may speculate that some gammopathy-associated systemic diseases have yet to be characterized. Longhurst et al. recently described a patient with a long-standing history of urticaria, monoclonal gammopathy, recurrent fever, cytopenia, and complement activation that was resistant to IL1Ra, which may represent a new gammopathy-associated autoinflammatory syndrome [22].

Until now, the accumulated evidence was scarce regarding the long-term outcome of patients with SchS that were treated with IL1Ra. Approximately 40 individual cases of

IL1Ra-responsive SchS have been reported worldwide, with a median follow-up of only 12 months [2,8,9,15,16,23-27]. In the present study, the median follow-up under IL1Ra treatment was three years and 11 patients were treated for more than four years. Our study revealed no loss in the effectiveness of the treatment and an adequate tolerance profile. Importantly, our data show that anakinra has a major corticosteroid sparing effect. Overall, the long term effectiveness and therapeutic maintenance of IL1Ra in SchS seems to be superior to what has been reported in other rheumatic diseases that could benefit from this drug, namely rheumatoid arthritis [28], adult-onset Still's disease (AOSD) [29-31]. This is reminiscent of its efficacy in inherited auto-inflammatory syndromes [32]. Our series also enlightens the safety profile of long term off-label use of IL1Ra, which efficacy has been reported in various non-rheumatic adult-onset inflammatory diseases [33,34].

The patients' tolerance to IL1Ra injections was rather unexpected. Indeed, only one was switched to a long-acting anti-IL-1. This finding suggests that the impressive clinical benefits experienced by most of our patients clearly outweigh the restrictive nature of daily injections. However, a few patients considered treatments that required daily injections were not worth the impact to their QoL and therefore decline to recourse to IL1Ra.

Severe infections were observed in six of the patients treated with IL1Ra (20%). This figure is consistent with the findings of Laskaris et al. in patients with AOSD: among 25 patients treated with IL1Ra for a median duration of 15 months, 28% developed an infection [31]. However, another series with 28 AOSD patients receiving a prolonged IL1Ra treatment recorded no serious infections [29]. These discrepancies could be explained by the longer follow-up of our series and the older age of the patients with SchS compared to AOSD. Moreover, most of our cases had additional predisposing factors to severe infections. Indeed, four out of six patients that experienced a severe infection were steroid-dependent before the recourse to IL1Ra treatment and had previously received high corticosteroid doses (>7.5 mg/d

of prednisone). However, the outcome was fatal in two cases and it cannot be stated whether the same would have occurred in the absence of blocking IL-1Ra. On the other hand, pursuing high dose corticosteroids in these patients would have probably also carried a significant risk of infection. Therefore, clinicians should heed caution and remember that IL1Ra could increase the risk of severe infections [35,36]. Another matter of concern was the risk of IL1Ra-induced neutropenia. Only three cases were recorded and none developed an infection. Interestingly, the adjustment of the therapeutic scheme circumvented this side effect and allowed continuation of the treatment in all cases.

Aside from the impaired QoL and the side effects of long-term corticosteroid use, the main long-term threat to SchS patients is development of a hematologic malignancy (mainly Waldenström's macroglobulinemia) [1,2,7,18,37]. In our patients, only two cases of hematologic malignancies were observed, both in IL1Ra-untreated patients. Further studies are needed to determine whether IL-1 blockers modify this risk, which has been estimated to be 15% at 10 years [7]. In this regard, our finding that blocking IL-1 had no significant effect on the monoclonal component is reassuring.

In our study we encountered one patient that developed AA amyloidosis. This patient suffered from SchS for more than ten years before he developed proteinuria. However, his symptoms had no major impact on his daily living. Therefore, he was reluctant to receive any medication. IL1Ra treatment induced a complete remission of SchS, but after 12 months of follow-up, the proteinuria had not improved. AA amyloidosis is a key complication of *bona-fide* inherited autoinflammatory diseases [38], but little is known regarding patients with SchS. To our knowledge, only three cases of SchS-related AA amyloidosis have been reported in the literature [6,7]. Some clinicians reckon that this threat warrants complete control of inflammation in every single patient with SchS.

Our work has the intrinsic limitation associated with retrospective studies and is not free from certain biases. For example, since the patients were recruited from internal medicine departments, there may be an overestimation of the burden of systemic and osteoarticular symptoms. Patients referred to dermatologists may have less severe disease manifestations. However, retrospective studies are essential tools for the study of such rare diseases. They can also provide meaningful information regarding the efficacy and safety of therapeutic strategies in real life situations [39].

As a whole, our data demonstrated the remarkable sustained efficacy of IL1Ra in SchS, as well as its favorable tolerance profile. We believe that every patient with SchS should have access to this drug [2]. However, whether every single patient with SchS should be convinced to be treated by an anti-IL-1 agent may be a matter of debate. In our view, the decision for recourse to this drug must be taken on an individual basis. Further studies are needed regarding the risk of AA amyloidosis in SchS, as well as on the influence of IL1Ra on the incidence of hematologic malignancies.

Acknowledgements: The authors would like to thank the members of the Société Nationale Française de Médecine Interne that participated in the survey and Dr Jonathan Batchelor, Nottingham, for his advises.

Contributors: AN, BH, SB and MH conceived and designed the study. AN, BH and FP collected and interpreted the data. AN performed statistical analysis. TD performed serum electrophoresis re-analysis. AM, CB, XK, XP, PJW, OD, JN, AH, AA, LA, JMBe, FB, JMBr, BC, FCP, JDdK, RD, RF, BG, EH, PYH, HJ, DL, AL, PP, GM, JS, AS contributed to the

survey and data collection and critically reviewed, edited the manuscript and approved the final version.

Funding: AN received a grant from Groupama Loire Bretagne – Fondation Groupama pour la Santé.

Conflicts of Interest: DL received a grant from Sobi (<10,000 USD). EH received lecture fees from Sobi (<10,000 USD). The other authors have no conflict of interest to disclose.

Ethics Approval : According to french legislation regarding retrospective observationnal studies using anonymous data, Ethics Committee approval was not required, which was confirmed by the chair of our Institutionnal Ethics Committee. The study was performed in accordance with the Declaration of Helsinki's guidelines for research in humans.

REFERENCES

- [1] Lipsker D. The Schnitzler syndrome. *Orphanet J Rare Dis* 2010;5:38.
- [2] Simon A, Asli B, Braun-Falco M, De Koning H, Fermanand JP, Grattan C, et al. Schnitzler's syndrome: diagnosis, treatment, and follow-up. *Allergy* 2013;68:562-8.
- [3] Schnitzler L. Lesions urticariennes chroniques permanentes (erytheme petaloide?) Cas cliniques, no. 46 B. *Journee Dermatologique d'Angers*, 28 octobre 1972.
- [4] Schnitzler L, Hurez D, Verret JL. Urticaire chronique-osteocodensation-macroglobulinemie. *Cas princeps. Etude sur 20 ans. Ann Dermatol Venereol* 1989;116:547-50.
- [5] Jain T, Offord CP, Kyle R, Dingli D. Schnitzler syndrome - an under diagnosed clinical entity. *Haematologica* 2013;98:1581-5.
- [6] Claes K, Bammens B, Delforge M, Evenepoel P, Kuypers D, Vanrenterghem Y. Another devastating complication of the Schnitzler syndrome: AA amyloidosis. *Br J Dermatol* 2008;158:182-4.
- [7] de Koning HD, Bodar EJ, van der Meer JW, Simon A; Schnitzler Syndrome Study Group. Schnitzler syndrome: beyond the case reports: review and follow-up of 94 patients with an emphasis on prognosis and treatment. *Semin Arthritis Rheum* 2007;37:137-48.
- [8] Martinez-Taboada VM, Fontalba A, Blanco R, Fernández-Luna JL. Successful treatment of refractory Schnitzler syndrome with anakinra: comment on the article by Hawkins et al. *Arthritis Rheum* 2005;52:2226-7.
- [9] Gran JT, Midtvedt Ø, Haug S, Aukrust P. Treatment of Schnitzler's syndrome with anakinra: report of three cases and review of the literature. *Scand J Rheumatol* 2011;40:74-9.
- [10] de Koning HD, Schalkwijk J, van der Ven-Jongekrijg J, Stoffels M, van der Meer JW, Simon A. Sustained efficacy of the monoclonal anti-interleukin-1 beta antibody canakinumab in a 9-month trial in Schnitzler's syndrome. *Ann Rheum Dis* 2013;72:1634-8.
- [11] Krause K, Weller K, Stefaniak R, Wittkowski H, Altrichter S, Siebenhaar F, et al. Efficacy and safety of the interleukin-1 antagonist rilonacept in Schnitzler syndrome: an open-label study. *Allergy* 2012;67:943-50.
- [12] Ryan JG, de Koning HD, Beck LA, Booty MG, Kastner DL, Simon A. IL-1 blockade in Schnitzler syndrome: ex vivo findings correlate with clinical remission. *J Allergy Clin Immunol* 2008;121:260-2.
- [13] Pizzirani C, Falzoni S, Govoni M, La Corte R, Donadei S, Di Virgilio F, et al. Dysfunctional inflammasome in Schnitzler's syndrome. *Rheumatology (Oxford)* 2009;48:1304-8.
- [14] Migliorini P, Del Corso I, Tommasi C, Boraschi D. Free circulating interleukin-18 is increased in Schnitzler syndrome: a new autoinflammatory disease? *Eur Cytokine Netw* 2009;20:108-11.
- [15] Launay D, Dutoit-Lefevre V, Faure E, Robineau O, Hauspie C, Sobanski V, et al. Effect of in vitro and in vivo anakinra on cytokines production in Schnitzler syndrome. *PLoS One* 2013;8:e59327.
- [16] Tinazzi E, Puccetti A, Patuzzo G, Sorletto M, Barbieri A, Lunardi C. Schnitzler syndrome, an autoimmune-autoinflammatory syndrome: report of two new cases and review of the literature. *Autoimmun Rev* 2011;10:404-9.

- [17] Krause K, Feist E, Fiene M, Kallinich T, Maurer M. Complete remission in 3 of 3 anti-IL-6-treated patients with Schnitzler syndrome. *J Allergy Clin Immunol* 2012;129:848-50.
- [18] Sokumbi O, Drage LA, Peters MS. Clinical and histopathologic review of Schnitzler syndrome: the Mayo Clinic experience (1972-2011). *J Am Acad Dermatol* 2012;67:1289-95.
- [19] Lipsker D, Veran Y, Grunenberger F, Cribier B, Heid E, Grosshans E. The Schnitzler syndrome. Four new cases and review of the literature. *Medicine (Baltimore)* 2001;80:37-44.
- [20] Asli B, Bienvenu B, Cordoliani F, Brouet JC, Uzunhan Y, Arnulf B, et al. Chronic urticaria and monoclonal IgM gammopathy (Schnitzler syndrome): report of 11 cases treated with pefloxacin. *Arch Dermatol* 2007;143:1046-50.
- [21] Terpos E, Asli B, Christoulas D, Brouet JC, Kastiris E, Rybojad M, et al. Increased angiogenesis and enhanced bone formation in patients with IgM monoclonal gammopathy and urticarial skin rash: new insight into the biology of Schnitzler syndrome. *Haematologica* 2012;97:1699-703.
- [22] Longhurst HJ, Yong PF, Manson AL, Cavenagh JD, Grigoriadou S, Buckland MS. Mullins' syndrome: a new gammopathy-related autoinflammatory syndrome resistant to anakinra. *QJM* 2012; Epub Oct 29. doi: 10.1093/qjmed/hcs208.
- [23] Lee KY, Grattan CE. Intracostal neuralgia as a previously undescribed symptom of Schnitzler's syndrome. *Br J Dermatol* 2012;167:1392-3.
- [24] Volz T, Wölbing F, Fischer J, Braun M, Maggosschitz I, Schaller M, et al. Dermal interleukin-1 expression and effective and long-lasting therapy with interleukin-1 receptor antagonist anakinra in Schnitzler syndrome. *Acta Derm Venereol* 2012;92:393-4.
- [25] Larocca CA, McEvoy JW, Ellis CL, Junkins-Hopkins J, Kolb T, Baer AN, et al. Schnitzler's syndrome associated with pancreatitis: a disease of IL-1 dysregulation. *Clin Rheumatol* 2012;31:169-74.
- [26] Sedivá A, Poloučková A, Podrazil M, Froňková E, Kalina T. Characterization of the B-cell compartment in a patient with Schnitzler syndrome. *Scand J Rheumatol* 2011;40:158-60.
- [27] Szturz P, Adam Z, Hájek R, Mayer J. Successful anakinra therapy in 2 patients with Schnitzler syndrome. *Onkologie* 2011;34:265-8.
- [28] Nuki G, Bresnihan B, Bear MB, McCabe D; European Group Of Clinical Investigators. Long-term safety and maintenance of clinical improvement following treatment with anakinra (recombinant human interleukin-1 receptor antagonist) in patients with rheumatoid arthritis: extension phase of a randomized, double-blind, placebo-controlled trial. *Arthritis Rheum* 2002;46:2838-46.
- [29] Giampietro C, Ridene M, Lequerre T, Costedoat Chalumeau N, Amoura Z, Sellam J, et al. Anakinra in adult-onset Still's disease: long-term treatment in patients resistant to conventional therapy. *Arthritis Care Res (Hoboken)* 2013;65:822-6.
- [30] Gerfaud-Valentin M, Jamilloux Y, Iwaz J, Sève P. Adult-onset Still's disease. *Autoimmun Rev* 2014;13:708-22.
- [31] Laskari K, Tzioufas AG, Moutsopoulos HM. Efficacy and long-term follow-up of IL-1R inhibitor anakinra in adults with Still's disease: a case-series study. *Arthritis Res Ther* 2011;13:R91.
- [32] Caorsi R, Federici S, Gattorno M. Biologic drugs in autoinflammatory syndromes. *Autoimmun Rev.* 2012;12:81-6.

- [33] Saadoun D, Bodaghi B, Bienvenu B, Wechsler B, Sene D, Trad S, Abad S, Cacoub P, Kodjikian L, Sève P. Biotherapies in inflammatory ocular disorders: Interferons, immunoglobulins, monoclonal antibodies. *Autoimmun Rev* 2013;12:774-83.
- [34] Maestroni S, Di Corato PR, Cumetti D, Chiara DB, Ghidoni S, Prisacaru L, Cantarini L, Imazio M, Penco S, Pedrotti P, Caforio AL, Doria A, Brucato A. Recurrent pericarditis: autoimmune or autoinflammatory? *Autoimmun Rev* 2012;12:60-5.
- [35] Ghogomu E, Tugwell P. Biologics for rheumatoid arthritis: an overview of Cochrane reviews. *Cochrane Database Syst Rev* 2009;(4):CD007848.
- [36] Singh JA, Wells GA, Christensen R, Tanjong Ghogomu E, Maxwell L, Macdonald JK, et al. Adverse effects of biologics: a network meta-analysis and Cochrane overview. *Cochrane Database Syst Rev*. 2011;(2):CD008794.
- [37] Verret JL, Leclech C, Rousselet MC, Hurez D, Schnitzler L. Schnitzler syndrome and Waldenström's disease. Fatal outcome of the original case. *Ann Dermatol Venereol* 1993;120:459-60.
- [38] Obici L, Merlini G. Amyloidosis in autoinflammatory syndromes. *Autoimmun Rev* 2012;12:14-7.
- [39] Koné-Paut I, Piram M. Targeting interleukin-1 β in CAPS (cryopyrin-associated periodic) syndromes: what did we learn? *Autoimmun Rev* 2012;12:77-80.

Table 1: Main characteristics of the 42 patients with Schnitzler's syndrome throughout the course of the disease.

	IL1Ra n = 29	No IL1Ra n = 13	Total n = 42	p
Age at disease onset, years	58.4 ± 12.4	63.2 ± 10.5	59.9 ± 11.9	0.2
Sex, M/F	20/9	10/3	30/12	0.7
Disease duration prior to diagnosis (months)	46 ± 39	36 ± 27	43 ± 36	0.4
Disease manifestations (ever)				
Rash	29 (100)	13 (100)	42 (100)	1
Fever	24 (83)	8 (61)	32 (76)	0.2
Pain (arthralgia or bone pain)	27 (93)	9 (69)	36 (86)	0.06
Weight loss (-10%)	19 (65)	6 (46)	25 (60)	0.3
Lymphadenopathy	8 (28)	5 (38)	14 (33)	0.5
Hepato- or splenomegaly	2 (7)	0 (0)	2 (5)	1
Bone lesion(s) [*]	24 (83)	8 (61)	32 (76)	0.2
Hemoglobin level, g/dL ^{**}	10.9 ± 1.7	11.2 ± 1.8	11.2 ± 1.7	0.6
CRP, mg/L ^{**}	132 ± 65	106 ± 60	124 ± 64	0.4
Monoclonal component				
IgM (overall)	26 (90)	11 (85)	37 (88)	0.6
IgM kappa	24 (83)	9 (69)	33 (78)	0.4
IgM kappa + other	1 (3)	1 (8)	2 (5)	
IgM lambda	1 (3)	1 (8)	2 (5)	
IgG	3 (10)	2 (15)	5 (12)	

The table represents the number (percentage) or mean ± standard deviation

* Suggested by findings from a Tc99 Bone scan in 27/36 (75%) or conventional radiographs in 17/34 (50%)

** worst value recorded during the follow-up

Table 2: Treatments during the entire follow-up of the 42 patients with Schnitzler's syndrome.

Treatment	n (%)
NSAID	18 (43)
Corticosteroids	29 (69)
Immunomodulating agents	26 (62)
Colchicine	18 (43)
Hydroxychloroquine	8 (19)
Pefloxacin	8 (19)
Disulone	2 (5)
Thalidomide	1 (2)
Immunosuppressants or Alkylating agents	13 (31)
Methotrexate	6 (14)
Azathioprine	3 (7)
Chlorambucil or Melphalan	5 (12)
Non anti-IL-1 biologic	5(7)
Infliximab	3 (7)
Rituximab	1 (2)
Anti-IL-1	29 (69)
Anakinra	29 (69)
Canakinumab	1 (2)

NSAID: non steroidal anti-inflammatory drug

Table 3: Death in patients with Schnitzler's syndrome: age, cause, and last treatments.

Sex	Age	Cause of death	SchS treatment
M	77y	Pneumonia, Severe pre-existing COPD	IL1Ra (CR)
M	86y	Pneumonia, Severe pre-existing COPD	IL1Ra (CR)
F	80y	Unknown	IL1Ra (CR)
F	77y	Dementia	Cs, 5mg/d (PR)

COPD: chronic obstructive pulmonary disease ; Cs: Corticosteroids ; CR: complete remission ; PR: partial remission

ACCEPTED MANUSCRIPT

Figures

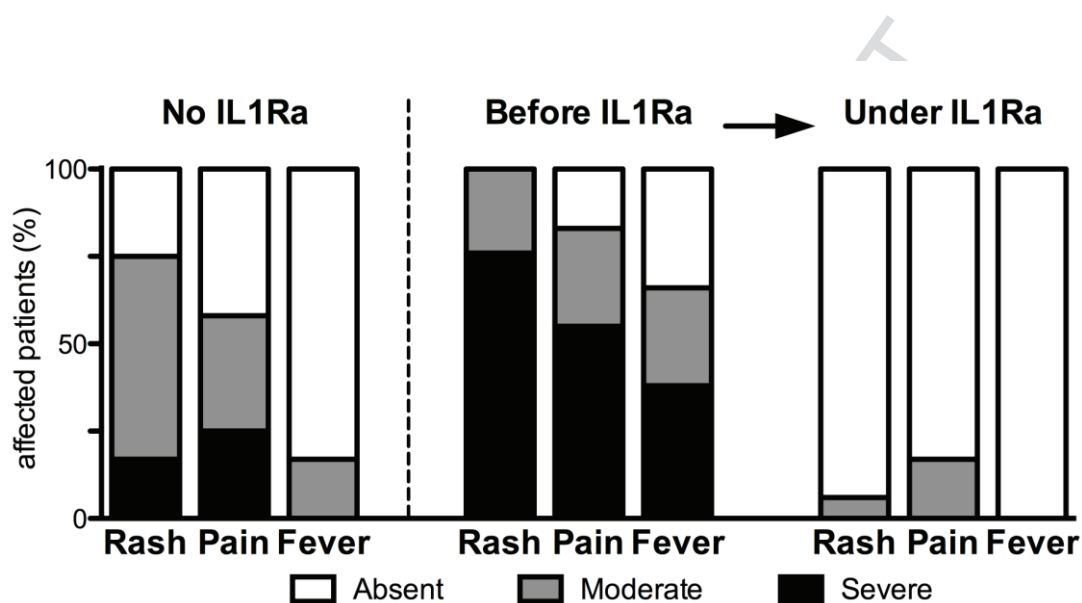


Figure 1: Clinical manifestations according to the therapeutic regimen and response to IL1Ra. No IL1Ra: graph refers to information from the last follow-up. Before/under IL1Ra: graphs refer to the time of IL1Ra introduction (“before IL1Ra”) and last available information under IL1Ra treatment (“After IL1Ra”).

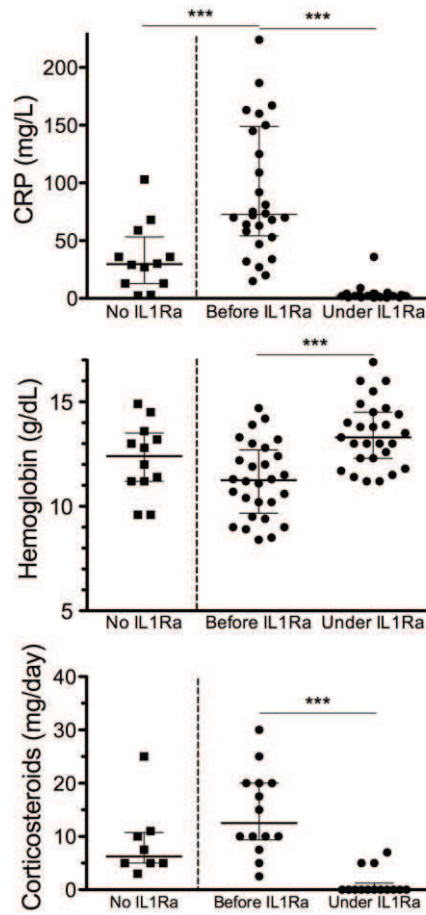


Figure 2: Biological findings and corticosteroid use according to the therapeutic regimen and response to IL1Ra treatment. No IL1Ra: graphs refer to information from the last follow-up. Before / under IL1Ra: graphs refer to the time of IL1Ra introduction (“before IL1Ra”) and last available information under IL1Ra treatment (“under IL1Ra”). The horizontal bars represent the median and interquartile range. *** $p < 0.0001$.

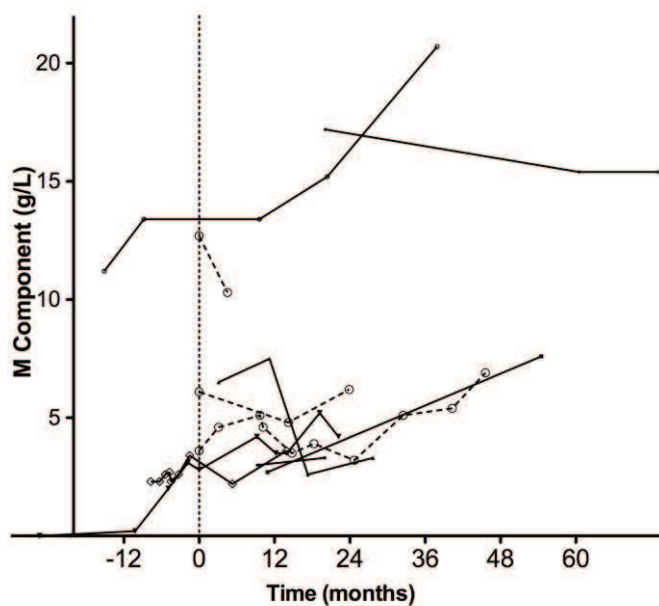


Figure 3: Evolution of the monoclonal component level over time, with or without IL1Ra treatment. Longitudinal analysis of 10 SchS patients from Nantes University Hospital, treated with IL1Ra (n = 7, continuous line; month 0 refers to the date of the first IL1Ra injection) or untreated (n = 3, dashed line with open circles; month 0 refers to the first available serum electrophoresis).