



Intérêt diagnostic des TEP-TDM en infectiologie [Contribution of 18fluoro-deoxyglucose PET/CT for the diagnosis of infectious diseases.]

Matthieu Revest, Solène Patrat-Delon, Anne Devillers, Pierre Tattevin,
Christian Michelet

► To cite this version:

Matthieu Revest, Solène Patrat-Delon, Anne Devillers, Pierre Tattevin, Christian Michelet. Intérêt diagnostic des TEP-TDM en infectiologie [Contribution of 18fluoro-deoxyglucose PET/CT for the diagnosis of infectious diseases.]. *Médecine et Maladies Infectieuses*, 2014, 44 (6), pp.251-60. 10.1016/j.medmal.2014.04.007 . hal-01064982

HAL Id: hal-01064982

<https://univ-rennes.hal.science/hal-01064982>

Submitted on 26 Sep 2014

HAL is a multi-disciplinary open access archive for the deposit and dissemination of scientific research documents, whether they are published or not. The documents may come from teaching and research institutions in France or abroad, or from public or private research centers.

L'archive ouverte pluridisciplinaire **HAL**, est destinée au dépôt et à la diffusion de documents scientifiques de niveau recherche, publiés ou non, émanant des établissements d'enseignement et de recherche français ou étrangers, des laboratoires publics ou privés.

Intérêt diagnostique des TEP-TDM en infectiologie

Contribution of 18 Fluoro-deoxyglucose PET/CT for the diagnosis of infectious diseases

M. Revest^{1,2}, S. Patrat-Delon¹, A. Devillers³, P. Tattevin^{1,2,4}, C. Michelet^{1,2}

¹Service des Maladies Infectieuses et Réanimation Médicale, CHU Rennes

²CIC Inserm 0203, CHU Rennes et Université Rennes 1

³Service de médecine nucléaire, centre régional de lutte contre le cancer Eugène Marquis, Rennes

⁴Inserm U835, Université Rennes 1

Corresponding author: Matthieu Revest

Telephone: +33 2 99 28 95 64

Fax: +33 2 99 28 99 80

e-mail: matthieu.revest@chu-rennes.fr

This study was initially presented at the 13th National Infectious Diseases Meeting on June 14, 2012, in Tours (France)

This study did not benefit from any financial grant.

Résumé

Le diagnostic de certaines maladies infectieuses peut être parfois difficile et de nouvelles procédures diagnostiques sont évaluées régulièrement pour répondre à cette problématique. La tomographie par émission de positron au ^{18}F Fluorodeoxyglucose couplée au scanner (^{18}F FDG-PET/CT) a été évaluée dans de nombreuses maladies infectieuses et ses résultats sont contrastés. L'analyse de la littérature permet tout de même de tirer quelques conclusions. Premièrement, le ^{18}F FDG-PET/CT n'est en l'état actuel des choses, pas un examen de première intention dans le contexte des maladies infectieuses. Deuxièmement, son utilité semble acquise dans l'évaluation des patients présentant une fièvre d'origine indéterminée. Sa valeur prédictive négative est notamment de 100% : les patients présentant ce symptôme avec un premier bilan et un ^{18}F FDG-PET/CT négatifs voient quasi systématiquement leur fièvre spontanément disparaître sans qu'aucune pathologie n'apparaisse dans le suivi. Troisièmement, le ^{18}F FDG-PET/CT semble également avoir un intérêt dans le diagnostic des infections de prothèses vasculaires ou d'ostéomyélite. Quatrièmement, ses performances chez les patients présentant une endocardite infectieuse notamment pour le diagnostic de localisations infectieuses secondaires ou chez les patients avec suspicion d'infection de pace maker ou de défibrillateur implantable sont prometteuses mais encore préliminaires. Enfin, les résultats des études s'étant intéressés au ^{18}F FDG-PET/CT dans d'autres maladies infectieuses ne permettent actuellement pas de le recommander pour ces autres situations.

Mots clés : ^{18}F FDG-PET/CT, fièvre d'origine indéterminée, endocardite infectieuse, infection de prothèse vasculaire, ostéomyélite

Abstract

The diagnosis of some infectious diseases is sometimes difficult to make and new diagnostic tools have been regularly assessed to that end. ^{18}F Fluoro-deoxyglucose (^{18}F FDG) positron-emission tomography (PET) coupled with computed tomography (CT) is one of these new procedures. It has been evaluated for numerous infectious diseases with uneven results. A literature review allowed drawing some conclusions. First, ^{18}F FDG-PET/CT is not currently a first-line procedure for infectious diseases. Second, it has proved useful for the evaluation of patients presenting with fever of unknown origin (FUO). Its negative predictive value is 100%: the symptoms of patients experiencing FUO with negative first-line investigations and a negative ^{18}F FDG-PET/CT will almost always spontaneously disappear. Third, ^{18}F FDG-PET/CT also seems to be contributive for the diagnosis of vascular prosthesis infections or osteomyelitis. Fourth, it has promising results for patients presenting with infective endocarditis, especially for secondary infectious foci, or for patients presenting with suspected infection of pacemakers or implanted defibrillator; but results are still preliminary and must be confirmed. Finally ^{18}F FDG-PET/CT cannot be recommended yet for other infectious diseases due to lack of published data.

Keywords: ^{18}F FDG-PET/CT, fever of unknown origin, infective endocarditis, vascular prosthesis infection, osteomyelitis

1. Introduction:

Early diagnosis is crucial for the optimal management of patients presenting with infectious diseases. Most of the time, this diagnosis is quite easily to make with usual microbiological or imaging investigations. Sometimes, it can be challenging, and new investigational techniques are needed. Metabolic and functional imaging techniques may be useful in these difficult clinical presentations, and scintigraphic or nuclear medicine procedures have been developed recently to deal with these. ^{18}F -fluoro-deoxyglucose (^{18}F FDG) positron-emission tomography (PET) is one of the new tools [1]. PET delivers high-resolution images using biologically active compounds labeled with positron emitters. ^{18}F FDG, a radiolabeled glycogen analogue, is accumulated in hypermetabolic cells, such as malignant cells that present with increased intracellular glucose metabolism [2], and is frequently used in oncology [3,4]. ^{18}F FDG is injected intravenously, and then the PET camera can identify hypermetabolic foci by detecting the positron emission of this radiolabeled tracer. A semi-quantitative analysis is performed by determining the Standardized Uptake Value (SUV), which is related to the concentration of ^{18}F FDG in the hypermetabolic foci detected.

^{18}F FDG-PET/CT combines many advantages when associated with computed tomography (CT): optimal spatial resolution, accurate anatomical localization of abnormalities, rapid diagnostic results, whole-body analysis, and lack of metallic hardware artifacts [1,5,6]. However, kidneys, bladder, brain, and meninges have a high metabolism in normal condition and ^{18}F FDG-PET/CT results can therefore be difficult to interpret for those tissues or organs [1].

Inflammatory cells involved in host response to infectious diseases also present with enhanced metabolism [1]. The contribution of ^{18}F FDG-PET/CT roles for the diagnosis of infectious diseases has therefore been considered for many years [7]. An increasing number of articles focusing on the relevance of ^{18}F FDG-PET/CT in various infectious conditions have been published [1,6]. However, the exact contribution of ^{18}F FDG-PET/CT for the diagnosis of infectious diseases has not been determined yet. We had for aim to focus on the use of this modern technique in the management of patients with suspected or confirmed infectious diseases: ^{18}F FDG-PET/CT seems to be clearly indicated in a few indications but data on the relevance of this imaging technique is still lacking for most infectious diseases.

2. Investigating fever of unknown origin

Fever of unknown origin (FUO) is defined as a fever $\geq 38.3^\circ\text{C}$, lasting for at least 3 weeks, without any diagnosis after 3 days of investigations for inpatient or 3 outpatient consultations [8,9]. No diagnosis can be made in up to 50% of cases despite a modern management [10]. FUO is probably the case in which ^{18}F FDG-PET/CT has been the most frequently evaluated [1]. Blockmans *et al.* investigated the clinical contribution of ^{18}F FDG-PET/CT for patients with FUO and compared its results to those of Gallium scintigraphy in the late nineties [11]. Fifty-eight patients were included and underwent ^{18}F FDG-PET/CT. A final diagnosis was made for 38 (42%). Forty-six ^{18}F FDG-PET/CT results were abnormal and 42% of these abnormal scans were considered helpful for the diagnosis, compared to only 25% for Gallium scintigraphy. The authors concluded that ^{18}F FDG-PET/CT should replace Gallium scintigraphy as nuclear medicine investigation for patients presenting with FUO. Many other studies have been made since [12-20]. All of them had for objective to assess ^{18}F FDG-PET/CT as a complementary procedure to routine investigations performed for patients presenting with FUO, including CT-scan or magnetic resonance imaging (MRI). Most of these studies yielded good results. Sensitivities and specificities were often lacking because a final diagnosis was not always made, but positive predictive values (PPV) and negative predictive values (NPV) ranged respectively from 30% to 97% and from 50% to 100% (table 1). Another value has been often

calculated in these studies: the probability for ^{18}F FDG-PET/CT to contribute to the diagnosis. In some situations, diagnosis is possible only if ^{18}F FDG-PET/CT is performed. On the other hand, it may be difficult to conclude to the absence of any disease in a patient with FUO and a normal ^{18}F FDG-PET/CT, since no other investigational procedure is available, and in this specific situation, ^{18}F FDG-PET/CT did not contribute to diagnosis (table 1). This probability for ^{18}F FDG-PET/CT to contribute to the diagnosis ranged from 16% to 69%, except in 1 study described later [18]. These results could seem unsatisfactory but they were actually very good: they concerned patients with no diagnosis after an exhaustive routine investigation, including modern imaging techniques (CT-scan, MRI), for FUO. Obtaining a diagnosis thanks to a new investigational tool was therefore very difficult and those results were excellent. Keidar *et al.* [18] illustrated this point with 48 consecutive patients presenting with FUO who were prospectively enrolled. ^{18}F FDG-PET/CT was negative for 21 patients and positive for 27 others (56%). A diagnosis was obtained for 22 patients with positive ^{18}F FDG-PET/CT. The main interest of this study was the very long patient follow-up period: 12 to 36 months. Thus, the authors were able to confirm the PPV and the NPV of ^{18}F FDG-PET/CT in their study. Seven patients with negative PET-scan were diagnosed as having drug-induced fever (1 patient), non-focal infection (1 patient with Q-fever, 1 with typhoid fever, and 1 with cytomegalovirus viremia), or urinary tract infection (3 patients) for which ^{18}F FDG-PET/CT is known to be weakly efficient. All the remaining patients with negative PET-scan had a spontaneous resolution of fever with no other evidence of a localized inflammatory, infectious, or malignant disease during follow-up. Four of the 5 undiagnosed patients with positive ^{18}F FDG-PET/CT also had spontaneous resolution of fever. A Still disease was diagnosed for the other one. The authors concluded that the PPV and NPV of ^{18}F FDG-PET/CT in their study were respectively 81 and 100%, highlighting the contribution of a negative ^{18}F FDG-PET/CT for patients presenting with FUO.

^{18}F FDG-PET/CT thus seems clearly contributive for the management of patients presenting with FUO (figure 1). A structured diagnostic protocol relying on this imaging procedure is proposed in figure 2. A national prospective study coordinated by the Limoges nuclear medicine department, focusing on the contribution of this procedure for FUO, has just ended and results of this study should help clinicians in this clinical presentation.

3. Musculoskeletal infections

a. Osteomyelitis and spondylodiscitis

The diagnosis of subacute or chronic osteomyelitis can be difficult, especially in case of preexisting alterations of osseous structures due to previous surgery or trauma. The results of conventional imaging are often non-specific [1]. The results of conventional nuclear medicine procedures can also be weakly sensitive, specific, or both, and have poor spatial resolution [1]. ^{18}F FDG-PET/CT was very effective in this clinical presentation. de Winter *et al.* conducted a prospective study on the contribution of ^{18}F FDG-PET/CT for the diagnosis of chronic skeletal infections in 60 patients having undergone recent surgery. They reported a sensitivity, specificity, and overall accuracy of 100%, 86%, and 93% respectively [21]. Hartmann *et al.* retrospectively assessed the diagnostic contribution of ^{18}F FDG-PET/CT for 33 patients presenting with suspected post-traumatic chronic osteomyelitis [22]. The sensitivity, specificity, and accuracy were 94%, 87%, and 91% respectively. The NPV was 97% in this study.

The authors of a meta-analysis comparing ^{18}F FDG-PET/CT's performance to that of other imaging tools published in 2005, demonstrated a pooled-sensitivity of 96%, a pooled-specificity of 91%, and the superiority of ^{18}F FDG-PET/CT to other techniques for the diagnosis of chronic osteomyelitis (table 2) [23].

PET/CT was also evaluated for spondylodiscitis. The clinical contribution of this technique

was less clearly determined, especially since MRI is highly sensitive and accurate in detecting vertebral osteomyelitis[1]. However, ^{18}F FDG-PET/CT could be helpful to differentiate between active degenerative lesions and infectious end-plate abnormalities, and in cases where MRI is less efficient, such as suspicion of vertebral osteosynthesis infection [24,25]. It could also be useful for the evaluation of response to therapy in patients presenting with spondylodiscitis[26]. Again, the clinical relevance of these results was not clearly defined since clinical evaluation was most of the time sufficient to evaluate the effectiveness of spondylodiscitis treatment.

b. Diabetic foot

Peripheral neuropathy is common in patients presenting with diabetes mellitus and 5 to 10% of diabetic patients have foot ulcers that evolve to osteomyelitis[27]. It is sometimes difficult to discriminate between infectious process and Charcot's osteoarthropathy, the end-stage diabetic peripheral neuropathy. Hyperglycemia can affect ^{18}F FDG-PET/CT results and this procedure may be difficult to apply for diabetic patients. Nevertheless, the quality of PET/CT images to assess infection in diabetic patients is optimal when glycaemia levels are inferior to 250 mg/dL[28]; and this technique has been assessed for the diagnosis of infection in patients presenting with diabetic foot. Keidar *et al.*[29] evaluated the contribution of ^{18}F FDG-PET/CT for the diagnosis of suspected osteomyelitis in 14 patients presenting with diabetic foot. This technique allowed identifying osteomyelitis in 8 out of 8 sites, and soft tissue infection in 5 out of 5 sites, while CT alone allowed identifying osteomyelitis in 7 out of 8 sites and soft tissue infection in 4 out of 5 sites. The authors concluded that ^{18}F FDG-PET/CT was an effective technique for the diagnosis of osteomyelitis in patients presenting with diabetic foot, and to discriminate between soft tissue and bone infection. ^{18}F FDG-PET/CT can also yield hypermetabolism in Charcot's osteoarthropathy without any osteomyelitis[30] and the specificity of ^{18}F FDG-PET/CT may be therefore questioned. Basu *et al.* investigated this point in a prospective study on 63 patients in 4 groups: 20 non-diabetic patients with normal lower extremities, 21 patients presenting with uncomplicated diabetic foot, 17 patients presenting with Charcot's arthropathy, and 5 patients presenting with proven osteomyelitis secondary to a complicated diabetic foot[31]. The mean standardized uptake values (SUV) in healthy individuals and patients presenting with uncomplicated diabetic foot were 0.42 ± 0.12 and 0.5 ± 0.16 respectively ($P > 0.05$). The mean SUV for Charcot's arthropathy and in osteomyelitis were 1.3 ± 0.4 and 4.38 ± 1.39 . Differences were statistically significant ($P < 0.01$) between these 2 groups and between Charcot's arthropathy group and healthy controls or patients presenting with uncomplicated diabetic foot. These authors concluded that ^{18}F FDG-PET/CT was a relevant imaging technique for the diagnosis of diabetic foot. However, the number of patients included in all those studies was rather small and further investigations are needed. For instance, even if ^{18}F FDG-PET/CT appears to be more effective than Gallium scintigraphy for this indication, no comparison between ^{18}F FDG-PET/CT and radiolabeled leukocytes scintigraphy has been made so far and such a comparative study would be greatly contributive to determine the role of ^{18}F FDG-PET/CT for the diagnosis of patients with a suspected diabetic foot infection.

c. Infected prosthesis

^{18}F FDG-PET/CT seems to have a great potential for the investigation of patients with suspected orthopedic prosthetic infection, since the procedure is weakly affected by artifacts from metallic implants. It may be contributive to discriminate between aseptic loosening and periprosthetic infection. The authors of a preliminary prospective study including 62 patients evaluated the accuracy of ^{18}F FDG-PET for the investigation of painful lower limb prostheses[32]. A final diagnosis was made by surgical exploration or clinical follow-up for 1

year. The sensitivity, specificity, and accuracy of PET were 90.9%, 72%, and 77.8% respectively to detect infection in knee prosthesis. The results for the detection of infection in hip prosthesis were better with a sensitivity, specificity, and accuracy of 90%, 89.3%, and 89.5% respectively. The reason why ^{18}F FDG-PET was more accurate for the diagnosis of infection in hip than in knee prostheses was unclear. Those results were later confirmed. Pill *et al.* compared ^{18}F FDG-PET to ^{111}In Indium-white blood cell imaging for the diagnosis of hip prosthetic infections [33]. Eighty-nine patients presenting with painful hip prostheses were prospectively included and underwent ^{18}F FDG-PET and ^{111}In Indium-white blood scintigraphy, or ^{18}F FDG-PET alone. The diagnosis of total hip arthroplasty infection was secondarily confirmed or invalidated by surgery and microbiological samples harvested during surgery. ^{18}F FDG-PET allowed diagnosing 20 out of the 21 infected prostheses (sensitivity, 95.2%) and ruled out infection in 66 out of the 71 aseptic hip prostheses (specificity, 93%). The PPV and NPV were 80% and 98.5% respectively in this study. ^{111}In Indium-white blood scintigraphy was less efficient with a sensitivity, specificity, PPV, and NPV of 50%, 95.1%, 41.7%, and 88.6% respectively. However, the same group of investigators also demonstrated a lack of specificity for the detection of hip prosthetic infections [34]. They prospectively enrolled 9 patients having undergone total hip arthroplasty, followed-up by ^{18}F FDG-PET at 3, 6, and 12 months after surgery. Their aim was to assess the patterns and time course of FDG accumulation after total hip replacement. They also retrospectively analyzed the clinical data of 18 other patients who had undergone arthroplasty and ^{18}F FDG-PET/CT for oncologic indications. All the included patients were totally asymptomatic. The results were demonstrative: in 81% of the cases, increased FDG uptake was noted around the femoral head or neck part of the prosthesis. The **averaged** delay between surgery and ^{18}F FDG-PET procedure was 71.3 months for these patients with a maximum of 288 months. There was no increased FDG uptake in only 4 patients, but the **averaged** delay between surgery and ^{18}F FDG-PET procedure was much longer in these patients: 114.8 months. Therefore, surgery can induce an inflammatory reaction and thus a prolonged FDG increased uptake, which may complicate the results of ^{18}F FDG-PET procedure in case of infection suspected to be related to the orthopedic prosthesis. Moreover, Chacko *et al.* [35] demonstrated that the level of FDG uptake could not be used to discriminate between aseptic loosening and prosthesis infection. Thirty-two patients presenting with painful hip prosthesis underwent ^{18}F FDG-PET before prosthesis replacement. Twelve of them presented with prosthesis infection proven by microbiological samples harvested during surgery. Eleven of these patients displayed moderately increased FDG uptake along the interface between the bone and prosthesis, with SUVs inferior to 2 in some cases. All the ^{18}F FDG-PET performed in the 20 patients presenting with aseptic loosening proved the increased FDG uptake with much higher SUVs than the one found in septic patients, ranging from 1.5 to 7. The authors concluded that the amount of FDG uptake was not a marker of prosthetic infection. Nevertheless, the same authors [35] and others [1] suggested that there was a specific FDG uptake pattern for hip prosthetic infection: FDG uptake between the bone and prosthesis, at the mid-shaft level of the prosthesis, but not at other levels, could be specific of infection. Thus, ^{18}F FDG-PET/CT may be contributive for the evaluation of suspected prosthesis related infection but major concerns remain related to its specificity (prolonged increased FDG uptake after surgery) and other studies are needed to determine its clinical usefulness in this clinical presentation.

4. Bacteremia and cardiovascular diseases

a. Bacteremia

Bacteremia, and especially Gram-positive bacteremia, can lead to metastatic infectious foci and early diagnosis of these secondary infectious sites is crucial since they require prolonged

antibiotic treatment and, sometimes, drainage. Some authors assessed ^{18}F FDG-PET/CT for the detection of metastatic infectious foci, in Gram-positive bacteremia, to determine whether this could positively influence the clinical outcome [36]. One hundred-fifteen patients presenting with Gram-positive bacteremia (73 due to *Staphylococcus aureus*, 30 to *Streptococcus* sp., and 12 to *Enterococcus* sp.) were prospectively recruited. ^{18}F FDG-PET/CT was performed within 2 weeks after the first positive blood culture, in addition to other usual investigations. These patients were compared to a matched historical control group of 230 patients for whom no ^{18}F FDG-PET/CT was performed. More metastatic infectious foci were diagnosed in the study group than in the control group (67.8% vs. 35.7%, $P < 0.01$). Metastatic foci were asymptomatic in 35 patients (30%) and would have not been diagnosed without ^{18}F FDG-PET/CT. More interestingly, the mortality rate at 6 months was lower in the study group than in the control group: 19.1% vs. 32.2% ($P = 0.014$). These results were later confirmed by the same group of investigators in a study including only staphylococcal and streptococcal bacteremia [37], and in a cost-effectiveness analysis [38]. However, there were some limitations in those studies. First, they were not randomized comparative studies and historical comparisons provide less robust conclusions than randomized trials. Second, there were important discrepancies between the 2 groups: i) echocardiography was performed more often in the study than in the control group (83% vs. 29%, $P < 0.001$), and therefore the rate of infective endocarditis among patients of the control group was probably underestimated (8% vs. 18% in the study group, $P < 0.01$), with an impact on the treatment and the outcome; ii) treatment was more frequently delayed in the control group (45% vs. 27%, $P = 0.01$); iii) the median treatment duration was shorter in the control group than in the study group. Patients without documented secondary infectious foci were treated 14 days even in case of *S. aureus* bacteremia. More patients received only 14 days of antibiotics in the control group than in the study group since more metastatic infectious sites were identified in the study group. This duration of treatment seemed rather short for *S. aureus* bacteremia since the absence of metastatic sites of infection was a necessary but not a sufficient condition to treat such infections only 14 days [39,40]. To conclude, ^{18}F FDG-PET/CT may be contributive for the investigation of patients presenting with Gram-positive bacteremia, but data is still lacking and this expensive procedure cannot be recommended currently for this clinical presentation.

b. Infective endocarditis

The modified Duke criteria are considered to be the gold standard for the diagnosis of infective endocarditis (IE) [41]. However, this diagnosis can be challenging, especially in case of prosthetic valve endocarditis (PVE), for which echocardiography can be inconclusive in almost 30% of cases [42]. Thus, ^{18}F FDG-PET/CT could be a promising diagnostic procedure in these cases. The authors of 2 important studies assessed the contribution of ^{18}F FDG-PET/CT for IE. The authors of the first study prospectively included 72 patients presenting with Gram-positive bacteremia who underwent echocardiography and ^{18}F FDG-PET/CT [43]. IE was defined according to the modified Duke criteria. Patients were followed-up for 6 months after the first positive blood culture. Eighteen patients (25%) were diagnosed with proven IE, 10 with *S. aureus* endocarditis and 8 with streptococcal endocarditis. Two of these were diagnosed with PVE. Enhanced valve FDG uptake on ^{18}F FDG-PET/CT was demonstrated in only 7 patients presenting with IE. High FDG uptake in heart valves was demonstrated in 4 patients without IE. Two of these 4 patients had undergone heart valve replacement 27 days and 7 years earlier. Overall, sensitivity and specificity of ^{18}F FDG-PET/CT for the diagnosis of IE in this study were 39% and 93% respectively. The PPV was 64%, the NPV was 82%, and the authors concluded that ^{18}F FDG-PET/CT was not contributive enough for the diagnosis of IE.

The authors of the second study evaluated the diagnostic value of ^{18}F FDG-PET/CT for PVE[44]. They prospectively studied 72 consecutive patients presenting with suspected PVE. All of the patients underwent routine investigations for suspected PVE including exhaustive microbiological workup, transthoracic and transoesophageal echocardiography. ^{18}F FDG-PET/CT was also performed at admission. An expert team made the final diagnosis determined during a 3-month follow-up after admission, according to the modified Duke criteria. The results were: sensitivity 73%, specificity 80%, PPV 85%, NPV 67%, and global accuracy 76%. It should be noted that when abnormal FDG uptake around the prosthetic valve was added as a new major criterion, the sensitivity of the new modified Duke criteria at admission increased from 70% to 97% ($P=0.008$), without any decrease of specificity. This result was related to a significant reduction in the rate of "possible IE" from 56% to 32% ($P<0.0001$). However, despite those very promising results, it seemed difficult to systematically encourage the performing ^{18}F FDG-PET/CT for the diagnosis of IE. The current modified Duke criteria are sufficient for the diagnosis of IE most of the time. We believe that ^{18}F FDG-PET/CT should be used only in the very difficult cases of patients with suspected PVE for whom the modified Duke criteria cannot allow making a final diagnosis. It could also be performed for patients presenting with IE, remaining febrile despite an appropriate treatment. It could allow detecting secondary infectious foci requiring specific treatment. This presentation is very similar to FUO for which ^{18}F FDG-PET/CT prove highly valuable. A national French multicenter study will begin in 2014 to evaluate the accuracy of this procedure for the diagnosis of secondary infectious foci during IE.

c. Infection of cardiovascular implantable electronic devices

Infection of cardiovascular implantable electronic devices (CIED) is a serious complication and can lead to complete removal. The diagnosis of pocket infection is most often easy to make, while the diagnosis of lead infection is often more challenging. The authors of a pilot study evaluated the contribution of ^{18}F FDG-PET/CT for patients suspected of having sepsis after CIED implantation[45]. Twenty-one patients presenting with suspected device infection were prospectively included and compared with 14 controls. The final diagnosis was made according to either bacteriological data after device culture or, when no device was extracted, on a 6-month follow-up according to the modified Duke criteria and not according to ^{18}F FDG-PET/CT results. These results were compared to the final diagnosis obtained for each patient to determine the accuracy of this technique. The sensitivity, specificity, PPV, and NPV were respectively 100%, 100%, 100%, and 100% for pocket infections, but only 60%, 100%, 100%, and 73% for lead infections which are the most difficult to diagnose. It should be noted that 4 patients with false negative lead infection received antibiotics before ^{18}F FDG-PET/CT's was performed for longer than the 6 true positives (20 days vs. 3.2 days, $P<0.01$). The authors concluded that negative ^{18}F FDG-PET/CT should be interpreted with caution for the diagnosis of CIED infection, especially in patients having previously received antibiotics.

The authors of a second study investigated the impact of ^{18}F FDG-PET/CT on the management of patients suspected of having a CIED infection[46]. Forty-two patients suspected of having an infection were compared to 12 patients without infection in whom a CIED had been implanted 4 to 8 weeks earlier, and to 12 other patients in whom a CIED had been implanted for more than 6 months, without infection. All these patients underwent ^{18}F FDG-PET/CT. A final diagnosis of CIED infection was made for 35 of the 42 patients suspected of having an infection. The sensitivity and specificity of ^{18}F FDG-PET/CT were respectively 89% and 86%. The SUVs were much higher in infected patients than in patients who had been implanted recently. There was no enhanced FDG uptake in any of the patients implanted for more than 6 months. Six of the patients presenting with CIED infection, had superficial FDG uptake limited to subcutaneous tissues, without any contact with generator or leads, and were

considered to have only superficial infections. They were treated with antibiotics alone, without any material removal. The 6 patients were free of infection after a 9-month follow-up. The authors concluded that ^{18}F FDG-PET/CT could be useful in the management of patients suspected of having a CIED infection, to assess the extension of the infectious process and to help restrict lead removal to the appropriate patients.

^{18}F FDG-PET/CT may be helpful to diagnose CIED infection and some authors have reported promising results. Nevertheless, the sample sizes of these studies were small and more data are needed to determine the true indications of ^{18}F FDG-PET/CT in this type of infection.

d. Vascular prosthesis infection

^{18}F FDG-PET/CT seems to be a very promising diagnostic tool for vascular prosthesis infection. CT-scan remains the first-line diagnostic procedure but results provided are not always conclusive and ^{18}F FDG-PET/CT might be very helpful in this case. Keidar *et al.* studied the contribution of ^{18}F FDG-PET/CT for the diagnosis of suspected vascular grafts infections[47]. Thirty-nine patients were included in this non-comparative prospective study and underwent ^{18}F FDG-PET/CT. The final diagnosis was based on histopathological and/or microbiological findings obtained during surgery or on clinical and imaging follow-up. Vascular graft infection was confirmed in 14 patients. The sensitivity of ^{18}F FDG-PET/CT was 93% and its specificity 91%. The PPV and NPV were respectively 88% and 96%. Another study assessed the effectiveness of ^{18}F FDG-PET/CT compared to that of CT in 33 consecutive patients presenting with suspected aortic prosthetic graft infection[48]. Although both imaging procedures were effective, ^{18}F FDG-PET/CT seemed to be superior to CT in some circumstances. Two patterns of FDG uptake were documented: i) linear, along the graft wall, due to a physiological inflammatory response to a foreign body, which may persist for years, and ii) focal, highly suggestive of prosthesis infection (figure 3). The specificity and PPV of ^{18}F FDG-PET/CT for the diagnosis of aortic prosthesis graft infection was superior to 95% when focal uptake was the only positive criterion. Those results were later confirmed, in a study including the highest number of patients performed to date: Spacek *et al.* prospectively investigated the contribution of ^{18}F FDG-PET/CT in 76 consecutive patients for 96 vascular prosthesis grafts in which infection was suspected[49]. They found that the sensitivity, specificity, PPV, NPV, and overall accuracy of ^{18}F FDG-PET/CT were respectively 98.2%, 75.5%, 84.4%, 96.9%, and 88.5% when all the PET/CT with enhanced FDG uptake were considered as the positive criteria. The results were much better when only PET/CT with focal homogenous FDG uptake enhancement were considered as demonstrative of infection, with a sensitivity of 97.7%, a specificity of 91.2%, a PPV 93.5%, a NPV 96.9%, and a global accuracy of 94.9%.

CT-scan is most of the time conclusive for the diagnosis of vascular prosthesis infection, thus ^{18}F FDG-PET/CT cannot be recommended as a first line investigation tool in this case. However, we think that ^{18}F FDG-PET/CT is the procedure of choice for the diagnosis of this very severe infection when CT-scan is inconclusive, although data comparing ^{18}F FDG-PET/CT and radiolabeled leukocyte scintigraphy is still lacking for this type of infection.

5. Miscellaneous infections

^{18}F FDG-PET/CT was evaluated in many other infectious diseases: in tuberculosis to monitor early therapeutic response[50,51], in intensive care units to rule out important infections in mechanically ventilated patients[52], in HIV infection to determine lymphoid tissue activation[53] or to discriminate between cerebral toxoplasmosis and cerebral lymphoma[54], etc. However, the authors of these studies provided very limited and preliminary data and ^{18}F FDG-PET/CT should be used in those indications only in clinical trial settings and not routinely.

6. Conclusion

¹⁸FDG-PET/CT is a very promising imaging procedure for the diagnosis of infectious diseases. It is not used for first line investigation but can be very helpful in infectious diseases when the diagnosis is difficult to make such as for FUO and vascular prosthesis infection. It can also be contributive when vertebral osteosynthesis device infection is suspected, since MRI results can be difficult to interpret, and in diabetic foot with suspicion of osteomyelitis. The results are promising in case of IE to detect secondary infectious foci, or for prosthetic valve endocarditis difficult to diagnose and future studies will promptly start and supply more definitive answers. Other indications will probably be considered in the near future but studies evaluating its relevance are still needed to further determine the real contribution of ¹⁸FDG-PET/CT for the diagnosis of infectious diseases.

Tableau 1: résultats des études dédiées à l'évaluation du ^{18}F FDG-PET/CT chez les patients avec une fièvre d'origine indéterminée

Table 1: results of studies dealing with the evaluation of ^{18}F FDG-PET/CT for patients presenting with fever of unknown origin

First author	Year	Method	Number of patients	Useful for the diagnosis	Negative predictive value	Positive predictive value
Meller[12]	2000	Prospective	20	55%	75%	92%
Stumpe[13]	2000	Retrospective	39	ND	100%	97%
Lorenzen[14]	2001	Retrospective	16	69%	100%	92%
Bleeker-Rovers[15]	2004	Retrospective	35	37%	95%	87%
Kjaer[16]	2004	Prospective	19	16%	69%	30%
Bleeker-Rovers[17]	2007	Prospective	70	33%	92%	70%
Keidar[18]	2008	Prospective	48	89%	100%	81%
Sheng[19]	2011	Prospective	48	66%	50%	80%
Seshadri[20]	2012	Prospective	23	61%	78%	86%

ND: No Data

Tableau 2: résultats comparés de ^{18}F FDG-PET/CT, scintigraphie osseuse, scintigraphie aux leucocytes, scintigraphie au Gallium, et IRM pour le diagnostic d'ostéomyélite chronique (selon Termaat *et al.*[23])

Table 2: comparative results of ^{18}F FDG-PET/CT, bone scintigraphy, leukocyte scintigraphy, Gallium scintigraphy, and magnetic resonance imaging for the diagnosis of chronic osteomyelitis (according to Termaat *et al.*[23])

	Sensitivity (Confidence Interval 95%)	Specificity (Confidence Interval 95%)
^{18}F FDG-PET/CT	96% (88%-99%)	91% (81%-95%)
Bone scintigraphy	82% (70%-89%)	25% (16%-36%)
Leukocyte scintigraphy	61% (43%-76%)	77% (63%-87%)
Combined bone and leukocyte scintigraphy	78% (72%-83%)	84% (75%-90%)
Gallium scintigraphy	56% (26%-82%)	76% (49%-91%)
Magnetic resonance imaging	84% (69%-92%)	60% (38%-78%)

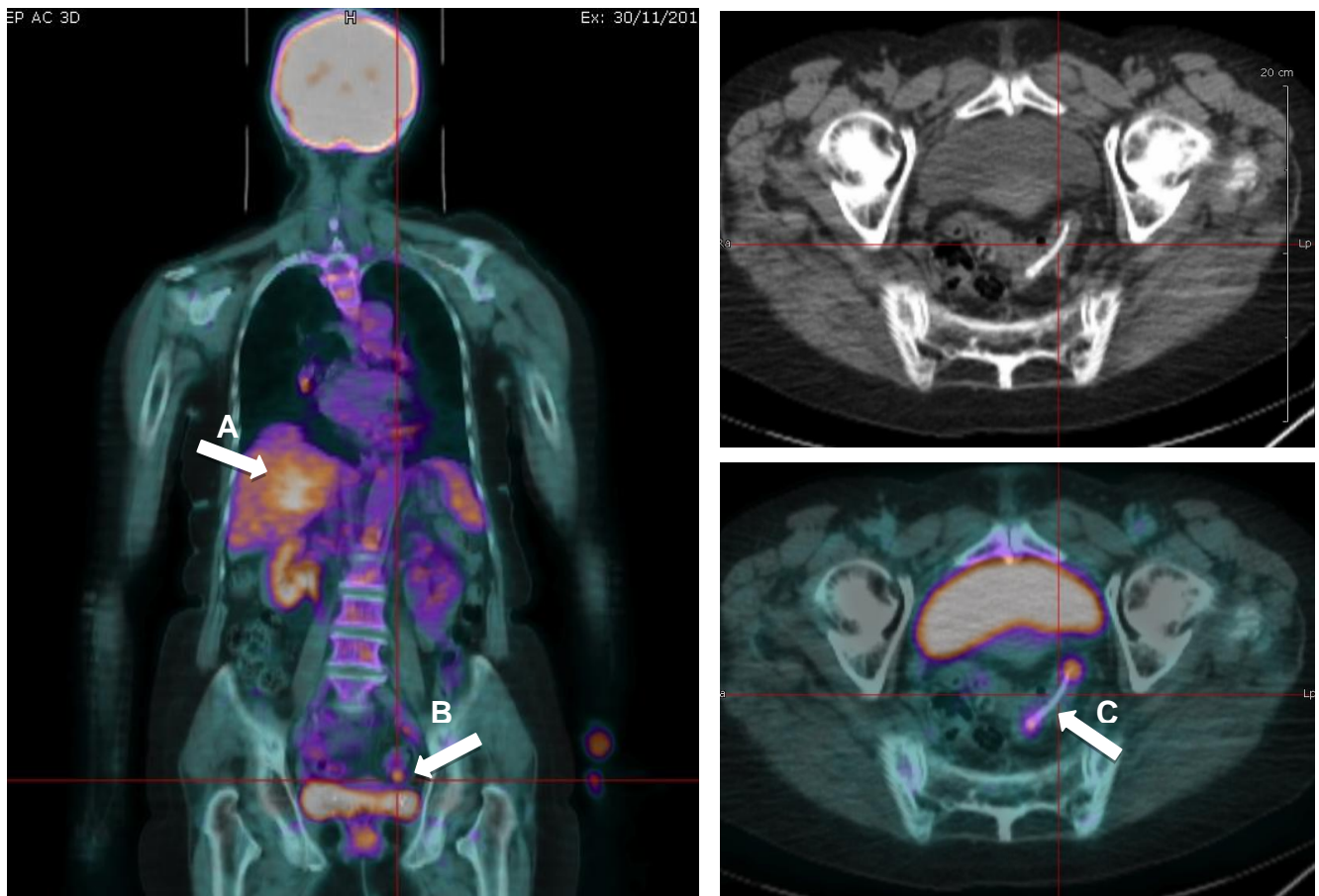
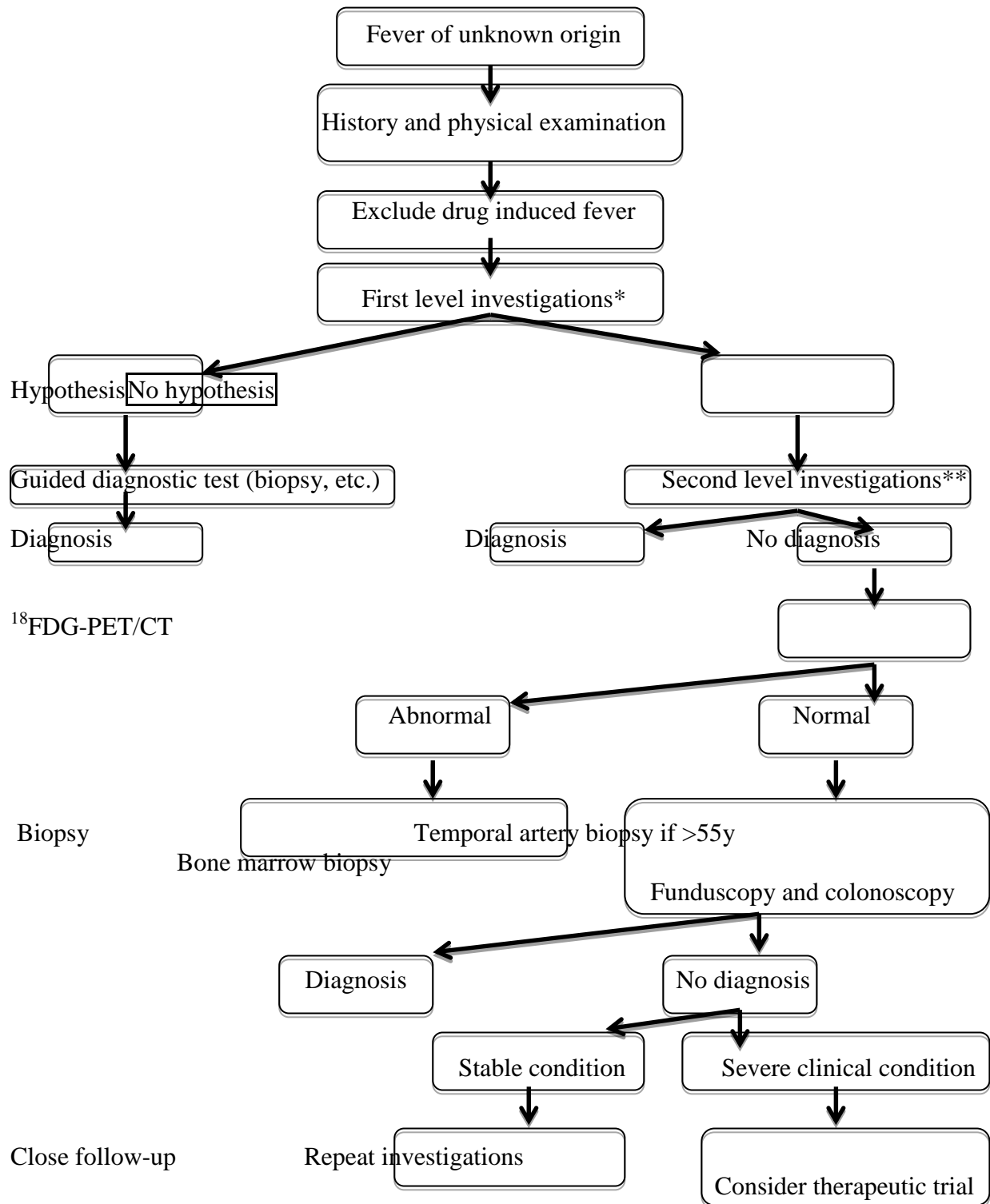


Figure 1: ^{18}F -FDG-PET/CT une fièvre d'origine indéterminée
 Figure 1: ^{18}F -FDG-PET/CT for fever of unknown origin

A 72-year old woman was hospitalized for recurrent liver abscesses. A first CT-scan was considered as non-conclusive (data not shown). ^{18}F -FDG-PET/CT demonstrated hyper metabolism in the liver (abscess already known, arrow A), but also in the pelvis (arrow B). A centered image demonstrated the presence of a rabbit bone inside the sigmoid (arrow C) with surrounding digestive ulcerations contributing to these recurrent liver abscesses. After surgery and rabbit bone removal, the patient no longer presented with any liver abscess.

Figure 2: proposition de protocole diagnostic structuré pour l'utilisation de ^{18}F FDG-PET/CT chez les patients avec une fièvre d'origine indéterminée

Figure 2: proposed structured diagnostic protocol for ^{18}F FDG-PET/CT inpatients presenting with fever of unknown origin



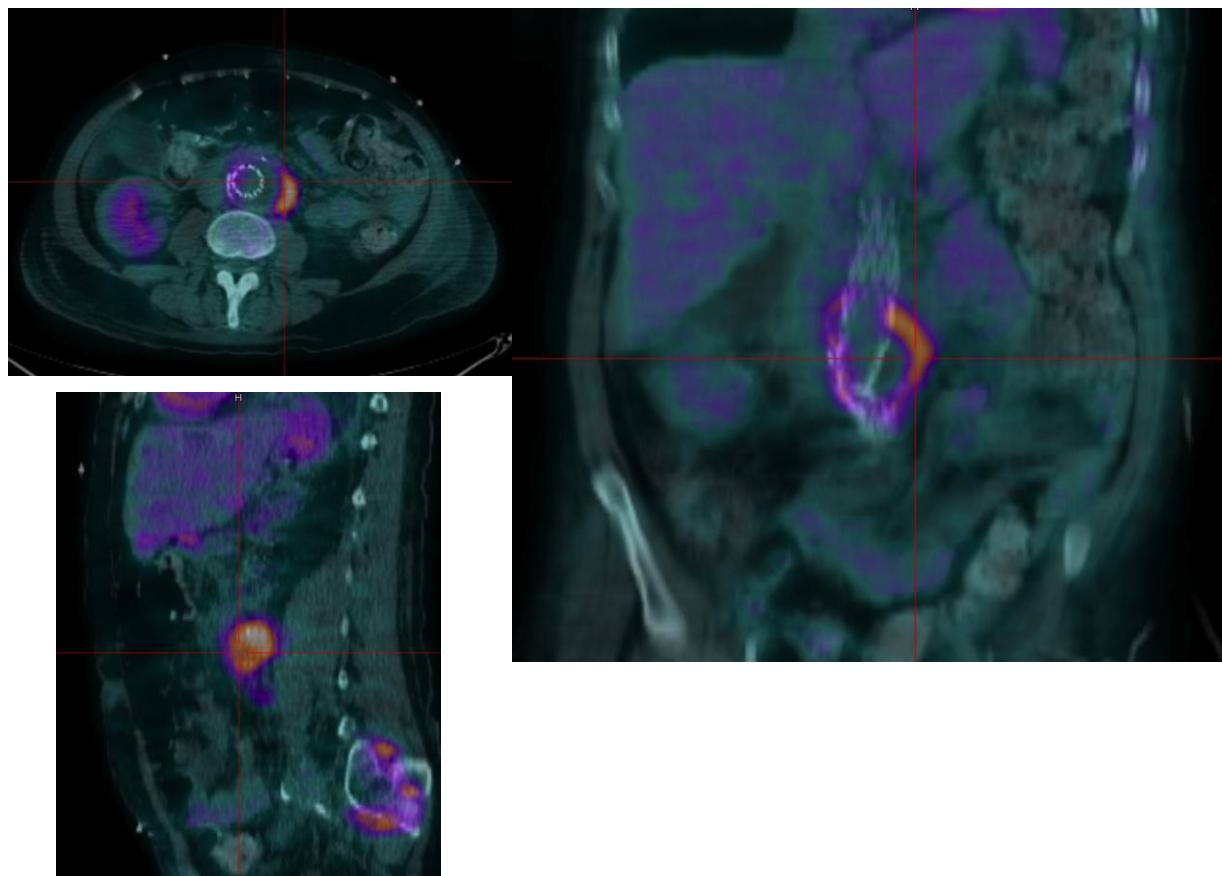
*First level investigations: haemoglobin, platelet count, leukocyte count and differentiation, electrolytes, creatinine, protein electrophoresis, alkaline phosphatase, ALAT, LDH, creatine

kinase, C reactive protein, blood culture (n=3), urinalysis, urine culture, tuberculin skin test, blood serum tests (CMV, EBV, Toxoplasmosis, HIV), chest and abdominal CT.

**Second level investigations: Q fever, bartonella, brucella blood serum tests and other blood serum tests according to the epidemiological characteristics of the patient, antinuclear antibodies and rheumatoid factor, microscopescreening for acid-fast bacilli on a smear, lower limb venous Doppler

Figure 3 : TEP au FDG dans une infection de prothèse vasculaire

Figure 3: focal enhanced FDG uptake in a vascular endoprosthesis infection



References:

1. Kumar R, Basu S, Torigian D, Anand V, Zhuang H, Alavi A. Role of modern imaging techniques for diagnosis of infection in the era of 18F-fluorodeoxyglucose positron emission tomography. *Clin Microbiol Rev* 2008;21:209-224.
2. Avril N, Menzel M, Dose J, Schelling M, Weber W, Janicke F, et al. Glucose metabolism of breast cancer assessed by 18F-FDG PET: histologic and immunohistochemical tissue analysis. *J Nucl Med* 2001;42:9-16.
3. Isasi CR, Lu P, Blaufox MD. A metaanalysis of 18F-2-deoxy-2-fluoro-D-glucose positron emission tomography in the staging and restaging of patients with lymphoma. *Cancer* 2005;104:1066-1074.
4. Ak I, Stokkel MP, Pauwels EK. Positron emission tomography with 2-[18F]fluoro-2-deoxy-D-glucose in oncology. Part II. The clinical value in detecting and staging primary tumours. *J Cancer Res Clin Oncol* 2000;126:560-574.
5. De Winter F, Vogelaers D, Gemmel F, Dierckx RA. Promising role of 18-F-fluoro-D-deoxyglucose positron emission tomography in clinical infectious diseases. *Eur J Clin Microbiol Infect Dis* 2002;21:247-257.
6. Haroon A, Zumla A, Bomanji J. Role of fluorine 18 fluorodeoxyglucose positron emission tomography-computed tomography in focal and generalized infectious and inflammatory disorders. *Clin Infect Dis* 2012;54:1333-1341.
7. Becker W, Meller J. The role of nuclear medicine in infection and inflammation. *Lancet Infect Dis* 2001;1:326-333.
8. Petersdorf RG, Beeson PB. Fever of unexplained origin: report on 100 cases. *Medicine (Baltimore)* 1961;40:1-30.
9. Petersdorf RG. Fever of unknown origin. An old friend revisited. *Arch Intern Med* 1992;152:21-22.
10. Bleeker-Rovers CP, Vos FJ, de Kleijn EM, Mudde AH, Dofferhoff TS, Richter C, et al. A prospective multicenter study on fever of unknown origin: the yield of a structured diagnostic protocol. *Medicine (Baltimore)* 2007;86:26-38.
11. Blockmans D, Knockaert D, Maes A, De Caestecker J, Stroobants S, Bobbaers H, et al. Clinical value of [(18)F]fluoro-deoxyglucose positron emission tomography for patients with fever of unknown origin. *Clin Infect Dis* 2001;32:191-196.
12. Meller J, Altenvoerde G, Munzel U, Jauho A, Behe M, Gratz S, et al. Fever of unknown origin: prospective comparison of [18F]FDG imaging with a double-head coincidence camera and gallium-67 citrate SPET. *Eur J Nucl Med* 2000;27:1617-1625.
13. Stumpe KD, Dazzi H, Schaffner A, von Schulthess GK. Infection imaging using whole-body FDG-PET. *Eur J Nucl Med* 2000;27:822-832.
14. Lorenzen J, Buchert R, Bohuslavizki KH. Value of FDG PET in patients with fever of unknown origin. *Nucl Med Commun* 2001;22:779-783.
15. Bleeker-Rovers CP, de Kleijn EM, Corstens FH, van der Meer JW, Oyen WJ. Clinical value of FDG PET in patients with fever of unknown origin and patients suspected of focal infection or inflammation. *Eur J Nucl Med Mol Imaging* 2004;31:29-37.
16. Kjaer A, Lebech AM, Eigtved A, Hojgaard L. Fever of unknown origin: prospective comparison of diagnostic value of 18F-FDG PET and 111In-granulocyte scintigraphy. *Eur J Nucl Med Mol Imaging* 2004;31:622-626.
17. Bleeker-Rovers CP, Vos FJ, Mudde AH, Dofferhoff AS, de Geus-Oei LF, Rijnders A, et al. A prospective multi-centre study of the value of FDG-PET as part of a structured

- diagnostic protocol in patients with fever of unknown origin. *Eur J Nucl Med Mol Imaging* 2007;34:694-703.
18. Keidar Z, Gurman-Balbir A, Gaitini D, Israel O. Fever of unknown origin: the role of 18F-FDG PET/CT. *J Nucl Med* 2008;49:1980-1985.
 19. Sheng JF, Sheng ZK, Shen XM, Bi S, Li JJ, Sheng G, et al. Diagnostic value of fluorine-18 fluorodeoxyglucose positron emission tomography/computed tomography in patients with fever of unknown origin. *Eur J Intern Med* 2011;22:112-116.
 20. Seshadri N, Sonoda LI, Lever AM, Balan K. Superiority of 18F-FDG PET compared to 111In-labelled leukocyte scintigraphy in the evaluation of fever of unknown origin. *J Infect* 2012;65:71-79.
 21. de Winter F, van de Wiele C, Vogelaers D, de Smet K, Verdonk R, Dierckx RA. Fluorine-18 fluorodeoxyglucose-positron emission tomography: a highly accurate imaging modality for the diagnosis of chronic musculoskeletal infections. *J Bone Joint Surg Am* 2001;83-A:651-660.
 22. Hartmann A, Eid K, Dora C, Trentz O, von Schulthess GK, Stumpe KD. Diagnostic value of 18F-FDG PET/CT in trauma patients with suspected chronic osteomyelitis. *Eur J Nucl Med Mol Imaging* 2007;34:704-714.
 23. Termaat MF, Raijmakers PG, Scholten HJ, Bakker FC, Patka P, Haarman HJ. The accuracy of diagnostic imaging for the assessment of chronic osteomyelitis: a systematic review and meta-analysis. *J Bone Joint Surg Am* 2005;87:2464-2471.
 24. Guhlmann A, Brecht-Krauss D, Suger G, Glatting G, Kotzerke J, Kinzl L, et al. Fluorine-18-FDG PET and technetium-99m antigranulocyte antibody scintigraphy in chronic osteomyelitis. *J Nucl Med* 1998;39:2145-2152.
 25. Stumpe KD, Zanetti M, Weishaupt D, Hodler J, Boos N, Von Schulthess GK. FDG positron emission tomography for differentiation of degenerative and infectious endplate abnormalities in the lumbar spine detected on MR imaging. *AJR Am J Roentgenol* 2002;179:1151-1157.
 26. Nanni C, Boriani L, Salvadori C, Zamparini E, Rorato G, Ambrosini V, et al. FDG PET/CT is useful for the interim evaluation of response to therapy in patients affected by haematogenous spondylodiscitis. *Eur J Nucl Med Mol Imaging* 2012;39:1538-1544.
 27. Boulton AJ. The diabetic foot: a global view. *Diabetes Metab Res Rev* 2000;16 Suppl 1:S2-5.
 28. Zhuang HM, Cortes-Blanco A, Pourdehnad M, Adam LE, Yamamoto AJ, Martinez-Lazaro R, et al. Do high glucose levels have differential effect on FDG uptake in inflammatory and malignant disorders? *Nucl Med Commun* 2001;22:1123-1128.
 29. Keidar Z, Militianu D, Melamed E, Bar-Shalom R, Israel O. The diabetic foot: initial experience with 18F-FDG PET/CT. *J Nucl Med* 2005;46:444-449.
 30. Hopfner S, Krolak C, Kessler S, Tiling R, Brinkbaumer K, Hahn K, et al. Preoperative imaging of Charcot neuroarthropathy in diabetic patients: comparison of ring PET, hybrid PET, and magnetic resonance imaging. *Foot Ankle Int* 2004;25:890-895.
 31. Basu S, Chryssikos T, Houseni M, Scot Malay D, Shah J, Zhuang H, et al. Potential role of FDG PET in the setting of diabetic neuro-osteoarthropathy: can it differentiate uncomplicated Charcot's neuroarthropathy from osteomyelitis and soft-tissue infection? *Nucl Med Commun* 2007;28:465-472.
 32. Zhuang H, Duarte PS, Pourdehnad M, Maes A, Van Acker F, Shnier D, et al. The promising role of 18F-FDG PET in detecting infected lower limb prosthesis implants. *J Nucl Med* 2001;42:44-48.

33. Pill SG, Parvizi J, Tang PH, Garino JP, Nelson C, Zhuang H, et al. Comparison of fluorodeoxyglucose positron emission tomography and (111)indium-white blood cell imaging in the diagnosis of periprosthetic infection of the hip. *J Arthroplasty* 2006;21:91-97.
34. Zhuang H, Chacko TK, Hickeson M, Stevenson K, Feng Q, Ponzo F, et al. Persistent non-specific FDG uptake on PET imaging following hip arthroplasty. *Eur J Nucl Med Mol Imaging* 2002;29:1328-1333.
35. Chacko TK, Zhuang H, Stevenson K, Moussavian B, Alavi A. The importance of the location of fluorodeoxyglucose uptake in periprosthetic infection in painful hip prostheses. *Nucl Med Commun* 2002;23:851-855.
36. Vos FJ, Bleeker-Rovers CP, Sturm PD, Krabbe PF, van Dijk AP, Culjpers ML, et al. 18F-FDG PET/CT for detection of metastatic infection in gram-positive bacteremia. *J Nucl Med* 2010;51:1234-1240.
37. Vos FJ, Kullberg BJ, Sturm PD, Krabbe PF, van Dijk AP, Wanten GJ, et al. Metastatic infectious disease and clinical outcome in *Staphylococcus aureus* and *Streptococcus* species bacteremia. *Medicine (Baltimore)* 2012;91:86-94.
38. Vos FJ, Bleeker-Rovers CP, Kullberg BJ, Adang EM, Oyen WJ. Cost-effectiveness of routine (18)F-FDG PET/CT in high-risk patients with gram-positive bacteremia. *J Nucl Med* 2011;52 1673-1678.
39. Liu C, Bayer A, Cosgrove SE, Daum RS, Fridkin SK, Gorwitz RJ, et al. Clinical practice guidelines by the infectious diseases society of america for the treatment of methicillin-resistant *Staphylococcus aureus* infections in adults and children: executive summary. *Clin Infect Dis* 2011;52:285-292.
40. Mermel LA, Allon M, Bouza E, Craven DE, Flynn P, O'Grady NP, et al. Clinical practice guidelines for the diagnosis and management of intravascular catheter-related infection: 2009 Update by the Infectious Diseases Society of America. *Clin Infect Dis* 2009;49:1-45.
41. Li JS, Sexton DJ, Mick N, Nettles R, Fowler VG, Jr., Ryan T, et al. Proposed modifications to the Duke criteria for the diagnosis of infective endocarditis. *Clin Infect Dis* 2000;30:633-638.
42. Vieira ML, Grinberg M, Pomerantzeff PM, Andrade JL, Mansur AJ. Repeated echocardiographic examinations of patients with suspected infective endocarditis. *Heart* 2004;90:1020-1024.
43. Kouijzer IJ, Vos FJ, Janssen MJ, van Dijk AP, Oyen WJ, Bleeker-Rovers CP. The value of 18F-FDG PET/CT in diagnosing infectious endocarditis. *Eur J Nucl Med Mol Imaging* 2013;40:1102-1107.
44. Saby L, Laas O, Habib G, Cammilleri S, Mancini J, Tessonnier L, et al. Positron emission tomography/computed tomography for diagnosis of prosthetic valve endocarditis: increased valvular 18F-fluorodeoxyglucose uptake as a novel major criterion. *J Am Coll Cardiol* 2013;61:2374-2382.
45. Bensimhon L, Lavergne T, Hugonnet F, Mainardi JL, Latremouille C, Maunoury C, et al. Whole body [(18) F]fluorodeoxyglucose positron emission tomography imaging for the diagnosis of pacemaker or implantable cardioverter defibrillator infection: a preliminary prospective study. *Clin Microbiol Infect* 2011;17:836-844.
46. Sarrazin JF, Philippon F, Tessier M, Guimond J, Molin F, Champagne J, et al. Usefulness of fluorine-18 positron emission tomography/computed tomography for identification of cardiovascular implantable electronic device infections. *J Am Coll Cardiol* 2012;59:1616-1625.

47. Keidar Z, Engel A, Hoffman A, Israel O, Nitecki S. Prosthetic vascular graft infection: the role of 18F-FDG PET/CT. *J Nucl Med* 2007;48:1230-1236.
48. Fukuchi K, Ishida Y, Higashi M, Tsunekawa T, Ogino H, Minatoya K, et al. Detection of aortic graft infection by fluorodeoxyglucose positron emission tomography: comparison with computed tomographic findings. *J Vasc Surg* 2005;42:919-925.
49. Spacek M, Belohlavek O, Votrubova J, Sebesta P, Stadler P. Diagnostics of "non-acute" vascular prosthesis infection using 18F-FDG PET/CT: our experience with 96 prostheses. *Eur J Nucl Med Mol Imaging* 2009;36:850-858.
50. Martinez V, Castilla-Lievre MA, Guillet-Caruba C, Grenier G, Fior R, Desarnaud S, et al. (18)F-FDG PET/CT in tuberculosis: an early non-invasive marker of therapeutic response. *Int J Tuberc Lung Dis* 2012;16:1180-1185.
51. Heysell SK, Thomas TA, Sifri CD, Rehm PK, Hout ER. 18-Fluorodeoxyglucose positron emission tomography for tuberculosis diagnosis and management: a case series. *BMC Pulm Med* 2013;13:14.
52. Simons KS, Pickkers P, Bleeker-Rovers CP, Oyen WJ, van der Hoeven JG. F-18-fluorodeoxyglucose positron emission tomography combined with CT in critically ill patients with suspected infection. *Intensive Care Med* 2010;36:504-511.
53. Scharko AM, Perlman SB, Pyzalski RW, Graziano FM, Sosman J, Pauza CD. Whole-body positron emission tomography in patients with HIV-1 infection. *Lancet* 2003;362:959-961.
54. Heald AE, Hoffman JM, Bartlett JA, Waskin HA. Differentiation of central nervous system lesions in AIDS patients using positron emission tomography (PET). *Int J STD AIDS* 1996;7:337-346.