



New insights into genotype-phenotype correlation for GLI3 mutations

Florence Démurger, Amale Ichkou, Soumaya Mougou-Zerelli, Martine Le Merrer, Géraldine Goudefroye, Anne-Lise Delezoide, Chloé Quélin, Sylvie Manouvrier, Geneviève Baujat, Mélanie Fradin, et al.

► To cite this version:

Florence Démurger, Amale Ichkou, Soumaya Mougou-Zerelli, Martine Le Merrer, Géraldine Goudefroye, et al.. New insights into genotype-phenotype correlation for GLI3 mutations. European Journal of Human Genetics, 2015, 23 (1), pp.92-102. 10.1038/ejhg.2014.62 . hal-01064583

HAL Id: hal-01064583

<https://hal.science/hal-01064583>

Submitted on 10 Apr 2019

HAL is a multi-disciplinary open access archive for the deposit and dissemination of scientific research documents, whether they are published or not. The documents may come from teaching and research institutions in France or abroad, or from public or private research centers.

L'archive ouverte pluridisciplinaire **HAL**, est destinée au dépôt et à la diffusion de documents scientifiques de niveau recherche, publiés ou non, émanant des établissements d'enseignement et de recherche français ou étrangers, des laboratoires publics ou privés.

ARTICLE

New insights into genotype–phenotype correlation for *GLI3* mutations

Florence Démurger¹, Amale Ichkou², Soumaya Mougou-Zerelli^{3,4}, Martine Le Merrer³, Géraldine Goudefroye², Anne-Lise Delezoide⁵, Chloé Quélin¹, Sylvie Manouvrier⁶, Geneviève Baujat^{2,3,7}, Mélanie Fradin¹, Laurent Pasquier¹, André Megarbané⁸, Laurence Faivre⁹, Clarisse Baumann¹⁰, Sheela Nampoothiri¹¹, Joëlle Roume¹², Bertrand Isidor¹³, Didier Lacombe¹⁴, Marie-Ange Delrue¹⁴, Sandra Mercier¹³, Nicole Philip¹⁵, Elise Schaefer¹⁶, Muriel Holder⁶, Amanda Krause¹⁷, Fanny Laffargue¹⁸, Martine Sinico¹⁹, Daniel Amram²⁰, Gwenaelle André²¹, Alain Liquier²², Massimiliano Rossi²³, Jeanne Amiel^{2,3,7}, Fabienne Giuliano²⁴, Odile Boute⁶, Anne Dieux-Coeslier⁶, Marie-Line Jacquemont²⁵, Alexandra Afenjar^{26,27}, Lionel Van Maldergem²⁸, Marylin Lackmy-Port-Lis²⁹, Catherine Vincent-Delorme³⁰, Marie-Liesse Chauvet^{2,3}, Valérie Cormier-Daire^{2,3,7}, Louise Devisme³¹, David Geneviève³², Arnold Munnich^{2,3,7}, Géraldine Viot³³, Odile Raoul², Serge Romana^{2,3,7}, Marie Gonzales³⁴, Ferechte Encha-Razavi^{2,7}, Sylvie Odent¹, Michel Vekemans^{2,3,7} and Tania Attie-Bitach^{*,2,3,7}

The phenotypic spectrum of *GLI3* mutations includes autosomal dominant Greig cephalopolysyndactyly syndrome (GCPS) and Pallister–Hall syndrome (PHS). PHS was first described as a lethal condition associating hypothalamic hamartoma, postaxial or central polydactyly, anal atresia and bifid epiglottis. Typical GCPS combines polysyndactyly of hands and feet and craniofacial features. Genotype–phenotype correlations have been found both for the location and the nature of *GLI3* mutations, highlighting the bifunctional nature of *GLI3* during development. Here we report on the molecular and clinical study of 76 cases from 55 families with either a *GLI3* mutation (49 GCPS and 21 PHS), or a large deletion encompassing the *GLI3* gene (6 GCPS cases). Most of mutations are novel and consistent with the previously reported genotype–phenotype correlation. Our results also show a correlation between the location of the mutation and abnormal corpus callosum observed in some patients with GCPS. Fetal PHS observations emphasize on the possible lethality of *GLI3* mutations and extend the phenotypic spectrum of malformations such as agnathia and reductional limbs defects. *GLI3* expression studied by *in situ* hybridization during human development confirms its early expression in target tissues.

European Journal of Human Genetics (2015) 23, 92–102; doi:10.1038/ejhg.2014.62; published online 16 April 2014

INTRODUCTION

Mutations in the *GLI3* gene lead to several clinical phenotypes including Greig cephalopolysyndactyly syndrome (GCPS; MIM# 175700)¹ and Pallister–Hall syndrome (PHS; MIM# 146510).² PHS first described in 1980 by Hall as a lethal condition in neonatal period^{3,4} associates mainly hypothalamic hamartoma (HH), postaxial polydactyly (PD), bifid epiglottis and imperforate anus (IA). PHS forms a spectrum from very mild cases with subtle insertional PD to severe cases.⁵ Typical GCPS is characterized by polysyndactyly in

hands and/or feet, craniofacial abnormalities, such as macrocephaly and hypertelorism,⁶ and developmental delay in individuals with large deletions encompassing *GLI3*.⁷

GCPS and PHS are distinct entities both caused by mutations in the transcription factor *GLI3*, a modulator of *Sonic hedgehog* (SHH) pathway with a bifunctional nature, either activator or repressor. In the presence of SHH, full-length *GLI3* functions as a transcriptional activator (*GLI3A*), whereas in the absence of SHH, *GLI3* is cleaved to produce a repressor (*GLI3R*).⁸

¹Service de Génétique Clinique, CLAD-Ouest, Hôpital Sud, Rennes, France; ²Département de Génétique, Hôpital Necker-Enfants Malades, Assistance Publique –Hôpitaux de Paris (AP-HP), Paris, France; ³INSERM U1163, Hôpital Necker-Enfants Malades, Paris, France; ⁴Service de Cytogénétique et Biologie de la Reproduction, CHU Farhat Hached, Sousse, Tunisia; ⁵Service de Fœtopathologie, Hôpital Robert Debré, AP-HP, Paris, France; ⁶Service de Génétique Clinique, CLAD-NdF, CHRU de Lille, Lille, France; ⁷Université Paris Descartes – Sorbonne Paris Cité, Institut Imagine, Paris, France; ⁸Unité de Génétique Médicale, Faculté de Médecine, Université St Joseph, Beirut, Lebanon; ⁹Centre de Génétique, Hôpital d'enfants, CHU de Dijon, Dijon, France; ¹⁰Département de Génétique, Hôpital Robert Debré, AP-HP, Paris, France; ¹¹Department of Pediatric Genetics, Amrita Institute of Medical Sciences, Kerala, India; ¹²Unité de Génétique Médicale, CH Poissy St-Germain-en-Laye, Poissy, France; ¹³Service de Génétique Médicale, Unité de Génétique Clinique, CLAD-Ouest, CHU de Nantes, Nantes, France; ¹⁴Service de Génétique Médicale, CHU de Bordeaux, Bordeaux, France; ¹⁵Département de Génétique Médicale, Hôpital d'Enfants de La Timone, Marseille, France; ¹⁶Service de Génétique Médicale, CHU de Strasbourg, Strasbourg, France; ¹⁷Division de Génétique Humaine, Hôpital St Hillbrow, Johannesburg, South Africa; ¹⁸Service de Génétique Médicale, CHU Estaing, Clermont-Ferrand, France; ¹⁹Service d'Anatomie Pathologique, CH Intercommunal de Créteil, Créteil, France; ²⁰Unité de Génétique Clinique, CH Intercommunal de Créteil, Créteil, France; ²¹Service d'Anatomie Pathologique, CHU Pellegrin, Bordeaux, France; ²²Laboratoire de Cytogénétique Biofiche, Bordeaux, France; ²³Service de Génétique, Hospices Civils de Lyon, CHU de Lyon, France; ²⁴Service de Génétique Médicale, Hôpital de l'Archet II, CHU de Nice, France; ²⁵Unité de Génétique Médicale, CHU la Réunion, France; ²⁶Service de Génétique, Hôpital Pitié Salpêtrière, Paris, France; ²⁷Centre de Référence des Malformations et Maladies Congénitales du Cervelet, Hôpital Trousseau, AP-HP, Paris, France; ²⁸Centre de Génétique Humaine, Université de Franche-Comté, Besançon, France; ²⁹Unité de Génétique Clinique, CHU de Pointe à Pitre, France; ³⁰Service de Génétique, CH d'Arras, France; ³¹Institut de Pathologie, Centre de Biologie-Pathologie, CHRU de Lille, France; ³²Département de Génétique Médicale, CHU de Montpellier, France; ³³Unité de Génétique, Maternité Port-Royal, Hôpital Cochin, AP-HP, Paris, France; ³⁴Service de Génétique et d'Embryologie Médicales, Hôpital Armand Trousseau, AP-HP, Paris, France

*Correspondence: Professor T Attie-Bitach, Département de Génétique et INSERM U781 Hôpital, Necker-Enfants Malades 149 rue de Sèvres, Paris 75743, Cedex 15, France. Tel: +33 (0) 144495144; Fax: +33 (0) 171196420; E-mail: tania.attie@inserm.fr

Received 27 October 2013; revised 20 January 2014; accepted 13 March 2014; published online 16 April 2014

Previous reports demonstrate a robust genotype–phenotype correlation of *GLI3* mutations.^{9,10} Truncating mutations in the middle third of the gene generally cause PHS, resulting in a constitutive repressor protein. By contrast, haploinsufficiency resulting from chromosomal rearrangements, but also missense, splicing or truncating mutations elsewhere in the gene cause GCPS by loss of the DNA-binding capacity¹¹ or activation of nonsense-mediated mRNA decay,¹² or by the formation of an unstable or mislocalized protein.^{13,14}

In this study, we report on the clinical and molecular data of a French cohort of 76 individuals from 55 families carrying a *GLI3* molecular defect. Most of mutations are novel and consistent with the previously reported genotype–phenotype correlation. In addition, our results also show a correlation between the location of the mutation and corpus callosum dysgenesis observed in some GCPS individuals. Fetal observations emphasize on the possible lethality of *GLI3* mutations, extend the phenotypic spectrum of malformations to severe craniofacial and reductional limb defects. *GLI3* expression studied by *in situ* hybridization during human development confirms its early expression in target tissues including in pharyngeal arches, and later in mandible.

PATIENTS AND METHODS

Patients

Index cases were tested for mutations in the *GLI3* gene because of the presence of clinical findings compatible with the diagnosis of GCPS or PHS and 76 cases from 55 families are included in this upon identification of a *GLI3* molecular defect.

A total of 55 patients from 38 families with features compatible with GCPS (polysyndactyly in hands and/or in feet and/or dysmorphic features associating high forehead, macrocephaly or widely spaced eyes and/or corpus callosum anomalies) were identified with a *GLI3* mutation or rearrangement, 39 cases were familial and 16 sporadic.

Also, 21 PHS individuals from 17 families with postaxial or insertional PD and/or HH with pathogenic *GLI3* mutations have been included. Among them, 13 were sporadic, 7 familial and 1 of unknown inheritance. Antenatal cases were selected for either HH or IA plus at least 2/5 features belonging to the PHS spectrum namely intrauterine growth retardation (IUGR), limb malformation, heart disease, micropenis and renal anomaly. In all seven fetuses with *GLI3* mutation, pregnancy was terminated because of severe clinical findings, in accordance with French legislation. A written informed consent for genetic analysis was obtained from each family before testing, and for autopsy in all fetal cases.

Molecular genetic studies

***GLI3* mutation screening.** Genomic DNA was extracted from frozen fetal tissue or amniocytes for the fetal cases and from peripheral blood samples in the postnatal cases. The 14 coding exons and the adjacent intronic regions of the *GLI3* gene were amplified using *GLI3*-specific primers pairs (available on request). Direct sequencing of PCR products was performed using the Big Dye Terminator Cycle Sequencing Kit v3 (Applied Biosystems, Courtaboeuf, France) and analyzed on an ABI3130 automated sequencer (Applied Biosystems). Sequences were analyzed with Seqscape software v2.5 (Applied Biosystems). Sequence data were compared with the *GLI3* reference sequence NM_000168.5, and mutation named according to the HGVS nomenclature and checked by the *Mutalyzer* programme.¹⁵ Mutations have been submitted to the public database LOVD.

All missense variants identified were investigated by *in silico* analysis using SIFT and PolyPhen2. Parental studies were done in sporadic cases to confirm a *de novo* occurrence of the alterations when parental DNA was available. We classified novel variants as pathogenic mutations the nonsense, frameshift and splice variants, and the missense variant, which affected conserved nucleotide or amino acid, segregating with the disease in familial cases, and/or apparently *de novo* in sporadic cases. Confirmation of biological parentage was performed for the *de novo* missense mutation only.

***GLI3* rearrangement analysis.** Individuals without *GLI3* coding sequence mutations underwent fluorescent *in situ* hybridization (FISH), Multiplex

Ligation-dependent Probe Amplification (SALSA MLPA KIT P179 Limb Malformations-1—MRC-Holland, Amsterdam, The Netherlands) or Array comparative genomic hybridization (Array CGH Agilent 244 or 180K oligonucleotide microarrays, Agilent Technologies, Santa Clara, CA, USA).

Gene expression analyses using *in situ* hybridization

Human embryos and fetal tissues were obtained from legally terminated pregnancies in agreement with French law (94–654 of 29 July 1994), following National Ethics Committee recommendations and with approval from the Necker Hospital ethics committee. Five developmental stages using Carnegie staging (CS)¹⁶ were studied: C14, C16, C18, C19 and 8.5 weeks of development. Tissues were fixed in 4% phosphate-buffered paraformaldehyde, dehydrated and embedded in paraffin blocks, and 5 µm-thick serial sections were cut. Exon 3 primers were selected for PCR amplification (3F-TACTTCTTTTCCGGGAGAGG and 3R-CCATAGCTC CTGAACAAGTG). Sense and antisense riboprobes were generated using either T7 or T3 RNA polymerase. Riboprobe labeling, tissue fixation, hybridization and developing were carried out according to standard protocols as described previously.¹⁷ No hybridization signal was detected with the labeled sense probe, confirming that the expression pattern obtained with the antisense probe was specific. Adjacent slides were hematoxylin/eosin stained for morphological studies.

RESULTS

Detailed clinical phenotypes and molecular results are described in Table 1 (GCPS) and Table 2 (PHS). Frequencies reported in Tables 3 and 4 are represented as the ratio between the number of patients with a particular finding and the total number of patients for which the information was available.

GLI3 mutations and deletions

Greig cephalopolysyndactyly syndrome. We identified 32 causative mutations and 6 large deletions in 38 GCPS index cases. Among the 16 sporadic cases, the *de novo* occurrence in the proband was confirmed for 6 patients after analysis of both parents. Three mutations were recurrent (c.1874G>A, c.4463del and c.444C>A identified each in two families). Overall, 8/38 (21%) were nonsense mutations, 17/38 (45%) were frameshift mutations predicting a premature stop codon, 6/38 (16%) were missense mutations, 1/38 (3%) was a splice mutation and 6/38 (16%) were complete deletions of the gene. Nine of them were located in the N-terminal part of *GLI3* before the zinc-finger domain predicting a prematurely terminated protein lacking the DNA-binding domain. Interestingly, all 6 missense mutations were within DNA-binding domain extending from amino-acid 462 to 645 encoded by exons 10 to 13 of the *GLI3* gene (Figure 1). All six missense mutations are predicted to be probably damaging to the protein function *in silico* by both PolyPhen-2 and SIFT softwares, involving conserved amino acids. Ten truncating mutations are located in the 1/3 end of the protein, within the transactivation domains TA2 and TA1.¹¹ Interestingly, two truncating mutations (c.2082_2083delinsAGAGAAGCC and c.3427_3443del) were in the previously defined PHS region (between cDNA positions 1998 and 3481).⁹ Among the 29 different mutations found in this series, two (c.868C>T and c.1874G>A) were previously described in other patients⁹ and 27 are novel mutations. Of note, a frameshift mutation (c.1543_1544dup) found in two affected sibs, was present at low level in DNA extracted from blood of their father (Family G068), suggesting a somatic mosaicism. Along the same line, a FISH analysis revealed a *GLI3* deletion in only 56% of blood cells of a patient (G059) with bilateral preaxial PD of the feet and developmental delay. At least two patients (G005 and G019) had Greig cephalopolysyndactyly contiguous gene syndrome (GCPS-CGS)

Table 1 Clinical features and GLI3 molecular results in GCPS cases

N° (#)	cDNA alteration (c.)	Predicted protein alteration (p.)	Postaxial			Broad thumbs or halluces		Synd-actyl	Widely spaced eyes		MRI Findings	Developmental delay	Additional findings
			Inheritance	PD	Preaxial PD	halluces	Macro-cephaly						
G029	327del	Phe109Leufs*50	F	-	FB		+	-	-	-	-	-	Precocious puberty, scaphocephaly
G070 Mother	427G>T	Glu143*	F	HB	FL		-	+				-	
	427G>T	Glu143*	F	-	-		-	-	-	-		-	
G118	444C>A	Tyr148*	F	-	FB	BT	+	+	+	+		-	
G13684	444C>A	Tyr148*	F	-	FB		+	+	+	+		-	
Brother	444C>A	Tyr148*	F	-	FL		+	-	+	+		-	
Mother	444C>A	Tyr148*	F	-	FB		+	+	+	+		-	
G099	518dup	Ile174Hisfs*2	F	-	FB		+	+	+	-		-	
G048	679 + 1G>T	Splice	De novo	HB	FB, HB		+	+	+		VD		Delta phalanx
G15198	833_843del	Arg278Thrfs*22	F	HB, FB	FB, HB	BT	+	+	+	+	-	-	
G079	868C>T	Arg290*	De novo	HB	FB		+	+	+	+		-	Atrial septal defect
G088	997_998dup	Tyr334Profs*14	De novo	-	FB	BT	+	+	+	+		-	Umbilical hernia
G14083	1063_1067dup	Leu357Serfs*10	De novo	-	FB, HB	BT	+	-		-			Bifid distal phalanx, BW = 4150
G033	1378del	Val461Serfs*41	F	-	FB	BT	+	+	+	+		-	Cerebral prematurity sequelae
G076	1498C>T	His500Tyr	F	-	FB		+	+	+	-	+	+	
Mother	1498C>T	His500Tyr	F	-	FB		+	-		-		-	
Brother	1498C>T	His500Tyr	F	HB	FB		+	-		-		-	
G068	1543_1544dup	Arg516Alafs*20	F	-	FB		+	-		-		-	Delta metacarpal, BW = 4880
Brother	1543_1544dup	Arg516Alafs*20	F	-	FB		+	-		-		-	BW = 4740
Father	[= /1543_1544dup]	[= /Arg516Alafs*20]	F	-	-		-	-		-		-	
A018	1733G>C	Cys578Ser	S	HB	FB	BT	+	+	+	+	CCH, VD		Hypoplastic cerebellum, microretrognathism
G094	1745del	Gly582Valfs*47	F	HB, FB	-			+	+	-		-	Bilateral keratoconus, umbilical and bilateral inguinal
G16012	1767 del	Asn589Lysfs*40	F	-	FB		+	-		-		-	hernia
Daughter	1767del	Asn589Lysfs*40	F	-	-	BT	+	-		-		-	Umbilical hernia
G109	1786C>T	His596Tyr	F	HB	FB		-	-	+	+		-	Macrosomia
Father	1786C>T	His596Tyr	F	-	-	BH	-	-		-		-	
Sister	1786C>T	His596Tyr	F	-	FB		+	-	+	+		+	Neurofibromatosis type 1
G056	1787A>C	His596Pro	F	-	FB		+	+	+	+		+	
Father	1787A>C	His596Pro	F	-	FB		+	+	+	+		-	
G026	1874G>A	Arg625Gln	S	-	FB, HB		+	-	+	+		-	Brachydactyly, delta phalanx
G14331	1874G>A	Arg625Gln	De novo	-	FB	BT, BH	+	+	+	+		-	Brachydactyly, speech delay
G111	2082_2083delinsAGAGAAGCC	Val695Glufs*45	F	HB	FB		-	-		+		-	
G063	3427_3443del	Phe1143Alafs*98	F	-	FB		-	-		+	VD	+	Speech delay, exomphalos
G003	3559C>T	Gln1187*	F	HB	-		-	+	+	+		MD	
Brother	3559C>T	Gln1187*	F	HB, FB	-	BT	-	+	+	+		-	
Mother	3559C>T	Gln1187*	F	HB	-		-	+		+		-	

Table 1 (Continued)

N° (#)	cDNA alteration (c.)	Predicted protein alteration (p.)	Broad			Widely spaced			MRI Findings	Developmental delay	Additional findings
			Inheritance	Postaxial PD	Preaxial PD	thumbs or halluces	Synd-actily	Macro-cephaly			
G051	3950del	Pro1317Glnfs*102	F	HB	–	–	–	+	pCCA	Mild	
Mother	3950del	Pro1317Glnfs*102	F	HB	FB	–	–	+			
A019 F*	4099dup	Ala1367Glyfs*45	S	HB, FB	–	–	–	+	pCCA		
G004	4324C>T	Gln1442*	S	HB, FB	–	BT	–	+	pCCA	+	Umbilical hernia, anterior anus
G002	4408C>T	Gln1470*	F	HB, FB	–	–	–	+	CCH, VD	–	Laryngomalacia
G006	4431dup	Glu1478*	F	HB, FB	–	–	–	+	CCH		BW = 4440
A017	4456C>T	Gln1486*	S	HB, FB	–	–	–	+	CCH	–	
G016	4463del	Thr1488Lysfs*23	<i>De novo</i>	–	FB	–	–	+	CCA, VD	Fine	
G043	4463del	Thr1488Lysfs*23	F	HB, FB	FB	–	–	+		Mild	Supernumerary nipples
Father	4463del	Thr1488Lysfs*23	F	HB, FB	FB	–	–	+			
Brother	4463del	Thr1488Lysfs*23	F	HB, FB	FR	–	–	+		Mild	
G114	4615_4624del	Thr1539Glyfs*11	F	HB	–	BH	–	+		–	
Sister	4615_4624del	Thr1539Glyfs*11	F	HB	FB	–	–	+		–	
G019	chr7 hg19:g(35 674 000_37 280 000)_ (46 116 000_46 598 000)del	<i>De novo</i>	–	FB	–	+	+	+	Thin CC	Bilateral inguinal hernia, strabismus	
G005	chr7 hg19:g(38 521 704_45 810 267)del	<i>De novo</i>	–	FB	BT	+	–	+	DD	Cataract, strabismus, vermis dysgenesis	
G028	rsa7p14.1(kit P179)x1	S	–	FB	BT	+	+	+	DD	Seizures, strabismus, horseshoe kidney, BW = 4280	
G115	46.XY,ish del(7)(p14.1)(RP11-816F16-) F	HB	HB	FB	–	+	+	–	–		
G038	46.XX,ish del(7)(p14.1p14.1)(GLI3-) S	–	–	FB	–	+	+	–	MD		
G059	46.XY,ish del(7)(p14.1)(GLI3-)[56]/ 7p14.1(GLI3x2)[44]	S	–	FB	–	–	–	–	DD	Trigonocephaly, macrosomia	

Abbreviations: BH, broad halluces; BT, broad thumb; BW, birth weight; CCA, corpus callosum agenesis; CCH, corpus callosum hypoplasia; DD, developmental delay; F, familial; FB, feet bilateral; FR, foot right; FL, foot left; F*, fetal case; HB, hand bilateral; MD, motor delay; pCCA, partial CCA; PD, polydactyly; S, sporadic; VD, ventricular dilatation. #: Index cases are indicated in bold and related are below.

Table 2 Clinical features and GLI3 molecular results in PHS cases

N°	cDNA alteration (c.)	Predicted protein alteration (p.)	Growth		Insertional/		Y-shaped					Genital	Renal	Cardiac	Bifid	Anal	Craniofacial	Hypothalamic	Lung	Intellectual	Nail	Other findings
			delay/GH	deficiency	postaxial	PD	dactyly	metatarsal	metacarpal/	hamartoma	anomalies											
P15112	1995del	Gly666Alafs*27	-	-	-	-	+	+	+	+	+	+	-	-	+	+	+	+	-	-	+	Overlapping toes; preauricular tag Micropenis, thin CC
G097	2072del	Gln691Argfs*2	+	+	+	+	+	+	+	+	+	+	+	+	-	-	-	-	-	-	+	Micropenis
G085	2123_2126del	Gly708Valfs*24	-	+	+	+	+	+	+	+	+	+	+	+	-	-	-	-	-	-	+	
Father	Gly708Valfs*24	Gly708Valfs*24	+	+	+	+	+	+	+	+	+	+	+	+	-	-	-	-	-	-	+	
Aunt	Gly708Valfs*24	Gly708Valfs*24	+	+	+	+	+	+	+	+	+	+	+	+	-	-	-	-	-	-	+	
Grand-mother	Gly708Valfs*24	Gly708Valfs*24	+	+	+	+	+	+	+	+	+	+	+	+	-	-	-	-	-	-	+	
G121	2149_2150insT	Gln717Leufs*21	-	+	+	+	+	+	+	+	+	+	+	+	-	-	-	-	-	-	-	
G001	2149C>T	Gln717*	+	+	+	+	+	+	+	+	+	+	+	+	+	+	+	+	+	-	-	Sacroccygeal teratoma, conical teeth, cryptorchidism, micropenis, syndactyly, unilateral renal agenesis, fine motor delay
G083	2385del	Ile796fs*13	-	+	+	+	+	+	+	+	+	+	+	+	-	-	-	-	-	-	-	Micropenis, choanal atresia, IVC, fine DD
Father	2385del	Ile796fs*13	-	+	+	+	+	+	+	+	+	+	+	+	-	-	-	-	-	-	-	Scoliosis, dental malposition
G082	2641_2642dup	Gln881Hisfs*10	+	+	+	+	+	+	+	+	+	+	+	+	+	+	+	+	+	+	+	Oligohydramnios, syndactyly
G044	2647G>T	Glu883*	+	+	+	+	+	+	+	+	+	+	+	+	-	-	-	-	-	-	+	Seizures, panhypopituitar-
G072 F*	2685C>G	Tyr895*	-	+	+	+	+	+	+	+	+	+	+	+	-	-	-	-	-	-	+	ism, DSD (karyotype 46XY, testis with an undeveloped genital tubercle), renal hypoplasia
GBUL	2799del	Tyr933*	+	+	+	+	+	+	+	+	+	+	+	+	+	+	+	+	+	+	+	Syndactyly
G040	2875_2902del	Leu959Trpfs*35	-	+	+	+	+	+	+	+	+	+	+	+	-	-	-	-	-	-	+	Agnathia, hypoplastic maxil-
G012 F*	2941dup	Asp981Glyfs*103	+	-	-	-	-	+	+	+	+	+	+	+	+	+	+	+	+	NA	-	lary, absence of oral orifice, bilateral choanal atresia, oli-
G024 F*	3006_3007insT	Arg1003*	+	+	+	+	+	+	+	+	+	+	+	+	+	+	+	+	+	NA	-	gosyndactyly, arthrogryposis, mesomelia bilateral radio-
G013 F*	3040G>T	Glu1014*	+	+	+	+	+	+	+	+	+	+	+	+	+	+	+	+	+	NA	-	ulnar bowing, absence of tibia and fibula, bilateral renal agenesis, pituitary gland agenesis, adrenal agenesis, uterovaginal apla-
																					-	sia, AVC, CCA, microcephaly
																					+	Posterior cleft palate, micro-
																					-	gnathia, micromelia, oligo-
																					-	syndactyly, club feet, adrenal
																					-	gland hypoplasia, bilateral
																					-	renal agenesis, anteposed
																					-	anus
																					+	Bilateral choanal atresia, retrognathia, posterior cleft
																					-	palate, ear dysplasia, cervi-
																					-	cal chondroma, syndactyly,
																					-	adrenal and pituitary gland
																					-	agenesis, micropenis, unilat-
																					-	eral renal agenesis, abnormal aortic arch

Table 2 (Continued)

N°	cDNA alteration (c.)	Predicted protein alteration (p.)	Inheritance	Growth		Insertional/ postaxial PD	Brachytelephalangism/ dactyly	Y-shaped metacarpal/ metatarsal	Hypothalamic hamartoma	Craniofacial anomalies	Anal	Bifid epiglottis	Cardiac anomalies	Renal anomalies	Genital anomalies	Lung dysplasia	Intellectual deficiency	Nail dysplasia	Other findings
				delay/GH	deficiency														
G080 F*	3098dup	Ala1034Glyfs*50	Sporadic	+	-	-	-	+	+	+	+	+	+	+	+	+	NA		Preaxillary agenesis, microretrognathism, arhinencephaly, hygroma colli, intestinal malrotation, micropenis, bilateral renal agenesis, IAC, IVC, adrenal gland agenesis
G104 F*	3324C>G	Tyr1108*	De novo	-	-	+	+	+	+	+	+	-	+	+	+	+	NA		Hypertelorism, retrognathism, cleft palate, oligosyndactyly, abnormal metacarpals, uni- lateral renal agenesis, micropenis, IAC
G081	3386_3387del	Phe1129*	De novo	-	-	-	+	-	+	-	+	+	-	-	+	+	+	+	Limited ankle mobility, syndactyly, hypopituitarism, micropenis, hypospadias, speech delay, gelastic seizures

Abbreviations: AVC, atrioventricular communication; CC, corpus callosum; CCA, corpus callosum agenesis; DSD, developmental sexual disorder; F*, Fetal case; IAC, interauricular communication; IVC, interventricular communication; NA, non applicable; PD, polydactyly. #, Index cases are indicated in bold and related are below.

Table 3 Frequencies of clinical features in GCPS individuals

Features	Frequency
<i>Facial anomalies</i>	
Widely spaced eyes	43% (20/47)
Macrocephaly	60% (32/53)
Craniosynostosis	4% (2/55)
<i>Hand anomalies</i>	
Preaxial polydactyly	7% (4/55)
Postaxial polydactyly	45% (25/55)
Broad thumbs	22% (12/55)
<i>Foot anomalies</i>	
Preaxial polydactyly	73% (40/55)
Postaxial polydactyly	20% (11/55)
Syndactyly	64% (34/53)
<i>Cerebral anomalies</i>	
Corpus callosum anomalies	50% (9/18)
Ventricular dilatation	39% (7/18)
<i>Developmental delay</i>	
Severe	11% (5/45)
Mild	20% (9/45)
Birth weight > 4000 g	12% (7/55)
Inguinal or umbilical hernia	11% (6/54)

caused by haploinsufficiency of *GLI3* and adjacent genes confirmed by array-CGH with a deletion of 7 and 9 Mb, respectively. Both presented preaxial PD of the feet, developmental delay and ophthalmologic findings (strabismus, cataract). The mutations segregated with the disease in all familial cases. In one apparently sporadic case (G070), the mutation was inherited from a healthy mother with no sign of GCPS.

Pallister–Hall syndrome. We identified heterozygous *GLI3* mutations in 21 patients from 17 families with features of PHS (HH and/or insertional or postaxial PD and/or Y-shaped metacarpal) and all were truncating (12 frameshift and 5 nonsense). Among the 13 sporadic cases, the *de novo* occurrence was confirmed in 13. Three mutations were previously reported in other patients (c.2149C>T, c.3040G>T and c.3386_3387del)^{9,18} and 14 mutations were novel. All mutations identified in probands with PHS were 3' of the DNA-binding domain and predicted the formation of a truncated protein. All were located in the previously described PHS region stretching from aa 667 to 1161, one starting just one amino-acid upstream, which predicts a premature termination codon 27 triplets downstream (P15112). All mutations found in fetuses with severe phenotypes affect a delineated region of the middle third of *GLI3* in the transactivation/CBP-binding region (Figure 1).

Clinical and radiological findings

GCPS

Limb anomalies. Preaxial PD of the feet was the most frequent finding (40/55) (Figures 2a, b and d), but broad halluces were also observed (Figure 2c). Complete preaxial PD of the hands was seen only in 1 case (Figure 2f) and broad thumbs in 12 cases (Figure 2g) with the presence in 2 cases of a delta phalanx or a bifid terminal phalanx on X-rays (Figure 2e). Postaxial PD was observed in 25/55 cases (45%) in feet (20%) or hands (45%). The severity of the PD

Table 4 Frequencies of clinical features in PHS individuals

Clinical features	Frequency
Growth delay/GH deficiency	53% (10/19)
Limb anomalies	
Y-shaped metacarpal	83% (15/18)
Postaxial polydactyly	48% (10/21)
Insertional polydactyly	48% (10/21)
Preaxial polydactyly	0% (0/21)
Oligodactyly	14% (3/21)
Syndactyly	38% (8/21)
Brachydactyly/brachytelephalangism	52% (13/21)
Mesomelia	19% (4/21)
Nail hypoplasia	69% (9/13)
Overlapping toes	9% (2/21)
Cerebral anomalies	
Hypothalamic hamartoma	100% (12/12)
Corpus callosum anomalies	17% (2/12)
Craniofacial anomalies	
Micro/retro/agnathia	24% (5/21)
Choanal atresia	14% (3/21)
Cleft palate	14% (3/21)
Chondroma	9% (2/21)
Bifid epiglottis	44% (4/9)
Anal anomalies	
Anal imperforation	43% (9/21)
Anteposed anus	5% (1/21)
Cardiac anomalies	
Interauricular communication	9% (2/21)
Interventricular communication	9% (2/21)
Atrioventricular communication	5% (1/21)
Aortic arch anomaly	5% (1/21)
Renal anomalies	41% (7/17)
Genital anomalies	48% (10/21)
Lung dysplasia	50% (4/8)
Developmental delay	21% (3/14)
Seizures	13% (2/15)

extended from a pedunculated postminimus (Figure 2h) to a fully formed supernumerary digit (Figure 2f). Syndactyly present in 64% (34/53) may occur in any limb and varied from partial to complete cutaneous syndactyly of the digits. Metacarpals were not affected except the first metacarpal, sometimes shorter and squatter (Figure 2b).

Craniofacial dysmorphism. In our series, 43% of patients had widely spaced eyes and 60% had macrocephaly. Scaphocephaly and trigonocephaly were noted both in one case.

Cerebral anomalies. A brain MRI was performed in 18 patients. A ventricular dilatation was found in seven cases. Surprisingly, corpus callosum dysgenesis (hypoplasia or agenesis) were not found in patients with large deletion except one but mainly in those bearing a truncating mutation in the C-terminal region of *GLI3* (7/9). In one family (G006), corpus callosum abnormalities were present in all affected individuals. Hypoplastic cerebellum was found in two patients (G005, A018) without molar tooth sign. Among patients with a large deletion encompassing *GLI3*, 5/6 manifested developmental delay and 4 had abnormal brain MRI findings. Apart from these deleted cases, a mild developmental delay (fine motor delay) was

observed in nine cases. Among them, seven had a C-terminal mutation, the two others had neurofibromatosis type 1 and prematurity complications.

Other occasional signs. Other less common anomalies in GCPS included umbilical and inguinal hernias (six patients). Birth weight was indicated for 15 patients and macrosomia was noted for 7.

Pallister–Hall syndrome

Limb anomalies. Limb anomalies were present in all 21 PHS individuals of our cohort. The most common feature was postaxial (48%) or insertional PD (48%) (Figures 3a and c). No patient with preaxial PD was recorded. Interestingly, Y-shaped metacarpal/metatarsal was visualized on X-rays in 83% of cases and in all other cases, numeric or morphologic anomalies of metacarpal/metatarsal were noted (Figures 3c and d). Only one patient (P15112) had bilateral and symmetrical Y-shaped metacarpals without PD (Figure 3d). Brachydactyly with brachytelephalangism was observed in at least 52% of PHS cases and nail hypoplasia in 69%.

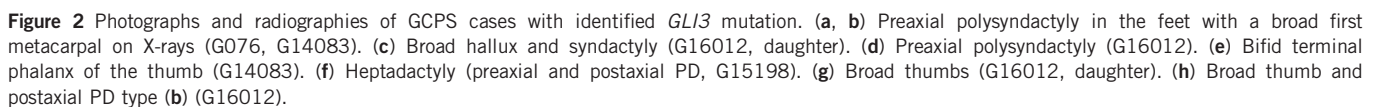
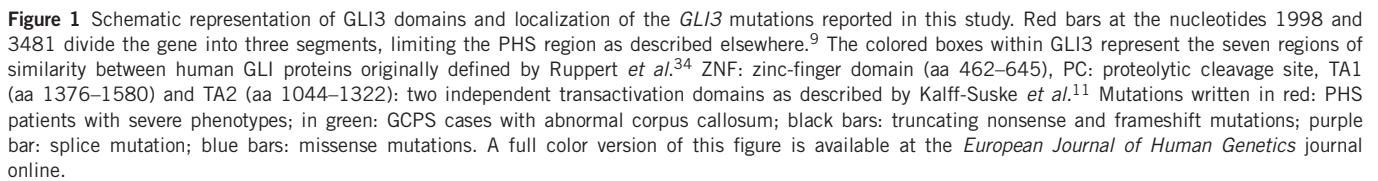
Syndactyly (38%) and overlapping toes (9%) were frequently reported. Four fetuses with severe phenotypes exhibited mesomelia or micromelia and three of them presented oligodactyly, club feet and arthrogryposis (Figures 3b, g–j).

Neurological findings. A HH was present in 12 patients, all with mutations falling in the ‘PHS’ domain (Figures 3e and f). In one fetus, neuropathological examination of the hypothalamic region found histological lesions of hamartoma, although a macroscopic mass was not visualized in the infundibular region (G024). Two cases displayed corpus callosum dysgenesis. Most patients had a normal intellectual efficiency, only three were slightly delayed. Seizures were reported in two cases as gelastic epilepsy.

Other findings. IUGR was found in 4/5 fetuses and growth was delayed in 6 patients. Besides, the endocrine manifestations of a HH ranged from isolated growth hormone deficiency (4/13) to panhypopituitarism (1 case); 4/5 fetuses displayed adrenal hypoplasia. Oral anomalies were reported in all prenatal cases: cleft palate in three fetuses, micro/retrognathia in four and unexpectedly, a complete agnathia with absence of oral orifice in one (Figure 3c). Laryngeal examination revealed bifid epiglottis in half cases, always asymptomatic in postnatal cases. Choanal atresia was present in three patients and two displayed cervical or preauricular chondroma. Moreover, imperforate or anteposed anus was present in half PHS cases including all fetuses. Congenital heart defects were diagnosed in six patients: interauricular septal defect in two, interventricular communication in two, atrioventricular septal defect in one and an aortic arch anomaly in one. Renal anomalies were present in 41% ranging from kidney hypoplasia to agenesis and resulting in oligoamnios in prenatal cases with bilateral agenesis (three cases). Genitourinary anomalies including micropenis (nine cases), hypospadias (one case) and uterovaginal aplasia (one case) were present in half of the individuals. A severe developmental sexual disorder was present in a girl with a male karyotype exhibiting an undeveloped genital tubercle. Lung anomalies including abnormal lobulation or hypoplastic lungs were present in four individuals.

In situ hybridization of GLI3

GLI3 expression pattern was studied during early human development using *in situ* hybridization on human embryo sections at CSs 14 (day 32), 16 (day 40), 18 (day 44), and 19 (day 47) and at 8.5 weeks of



day 49 in maxillary and mandible. At the same time, *GLI3* was also expressed in distal limb buds, floor plate of the telencephalon, diencephalon and mesencephalon, neural tube and strongly in kidney (Figure 4).

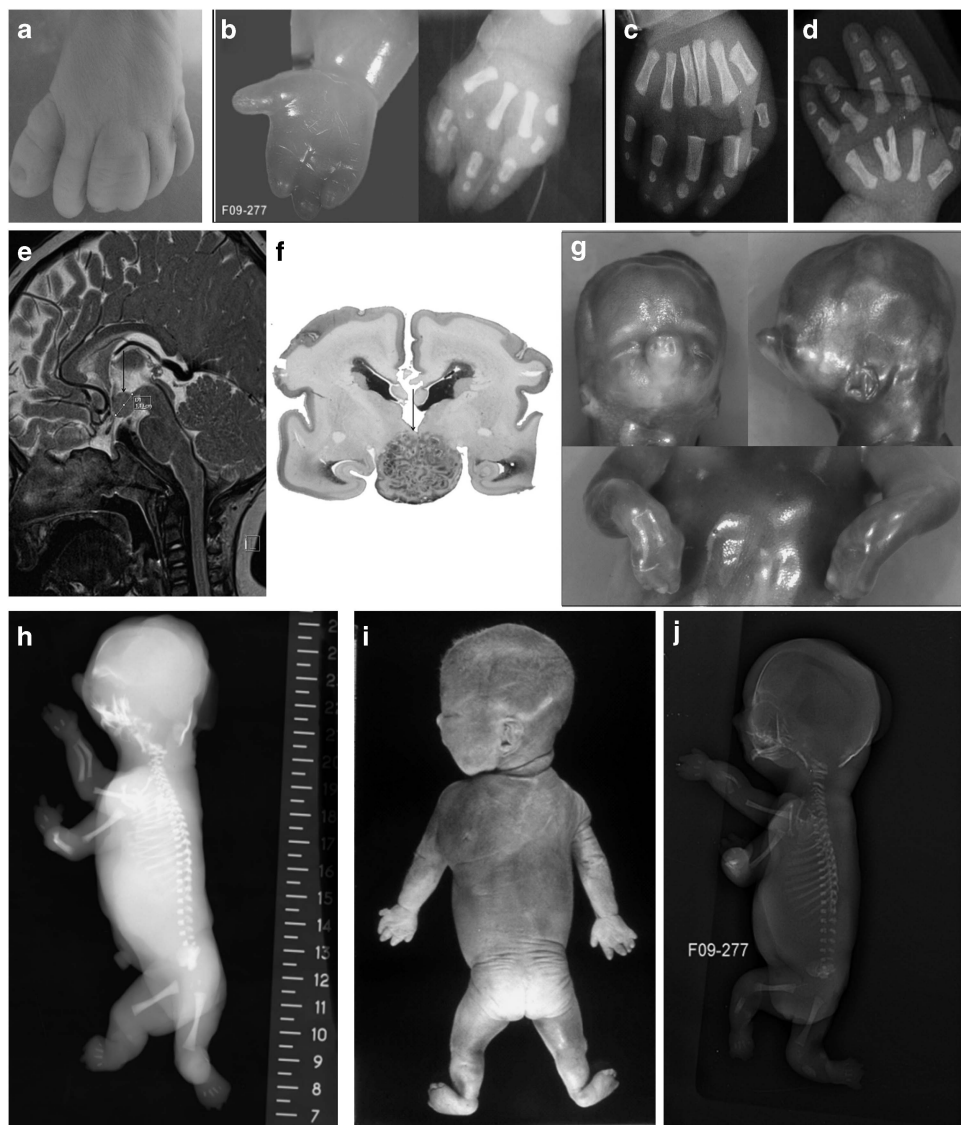


Figure 3 Photographs, radiographies and histological findings of PHS cases with identified *GLI3* mutation. (a) Insertional PD and syndactyly (G072). (b) Oligodactyly (G080). (c) Insertional PD with a supernumerary metacarpal (G072). (d) Y-shaped metacarpal without PD (P15112). (e) Brain MRI showing a HH (P15112). (f) HH on neuropathological examination (G013). (g) Agnathia, hypoplastic maxillary, absence of oral orifice and oligosyndactyly (G012). (h) X-rays of G012 showing oligosyndactyly of hands and feet, arthrogyrosis, mesomelia, bilateral radio-ulnar bowing, absence of tibia and fibula (G012). (i) (G024) and (j) (G080) showing micrognathia, micromelia, oligosyndactyly and club feet.

DISCUSSION

We present in this report molecular and clinical data of the second largest series of patients with *GLI3* mutations. Molecular results of our series support previous genotype–phenotype correlations, showing that exonic deletions, missense mutations, as well as truncating variants localized outside the middle third of the *GLI3* gene result in GCPS, while truncating mutations in the middle third result in PHS. Two truncating mutations in patients with preaxial PD mapped within the PHS region. Previous known exceptions to these correlations were described, for example, the recurrent c.2374C>T associated with a typical GCPS phenotype.^{9,11,19,20} These exceptions may be explained by a variable contribution of nonsense-mediated decay¹² or by the formation of unstable proteins with a very short half-life, effective nulls.

Only 10 GCPS probands of our series did fulfill all criteria suggested by Biesecker *et al*⁶ namely preaxial PD, cutaneous

syndactyly, widely spaced eyes and macrocephaly. Craniofacial features were absent or very subtle in 17 patients. Craniosynostosis was found in only two patients confirming the low-frequency association with GCPS.²¹ Along the same line, the diagnosis of PHS was confirmed in four individuals despite the absence of PD, whereas the clinical diagnostic criteria for PHS classically require the presence of insertional PD and a HH in the proband.²²

Interestingly, corpus callosum anomalies were found in nine patients, including seven patients with a truncating mutation located in the third end of *GLI3*. In the two previous series reported by Johnston *et al*,^{9,10} four GCPS patients with corpus callosum dysgenesis were also carrying a *GLI3* truncating mutation lying in the C-terminal domain of the protein further confirming our finding that corpus callosum dysgenesis is fully part of GCPS spectrum and is mainly caused by terminal truncating mutations. Overlapping features with acrocallosal syndrome (ACLS, MIM# 200990) associating callosal

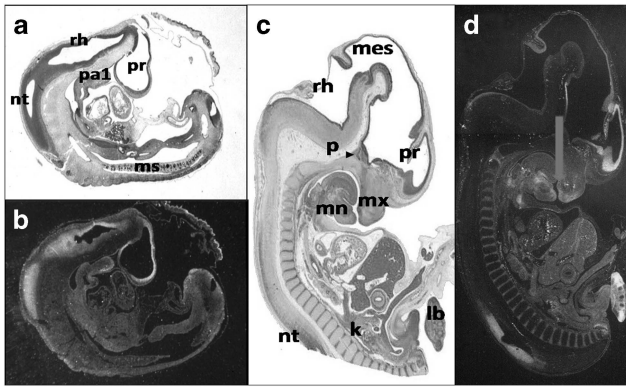


Figure 4 *In situ* hybridization of *GLI3* during human development. (a, b) CS 15; (c, d) CS 19. (b, d) Slides hybridized with an antisense *GLI3* probe. (a, c) Adjacent slides respectively to (b) and (d) stained with HES. In addition to the expression in central nervous system (prosencephalon (pr), rhombencephalon (rh) neural tube (nt)), limb bud (lb), pituitary gland (p, arrowhead) and kidney (K), a signal was observed in human pharyngeal arches (pa1) then in mandible (mn) and maxillary (mx) (red arrows). A full color version of this figure is available at the *European Journal of Human Genetics* journal online.

dysgenesis, hypertelorism, intellectual disability and PD²³ are explained by an impaired *GLI3* processing in patients with *KIF7* mutations.²⁴ Facial dysmorphism, as well as vermis dysgenesis with brainstem anomalies (molar tooth sign), strongly indicated the diagnosis of ACLS. Conversely, two *GLI3* mutated cases with corpus callosum dysgenesis have been reported as ACLS^{25,26} and a third similar patient has been reported by Johnston *et al.*¹⁰ All three mutations were missense and clustered in the same region between aa 903 and 934 suggesting a potential severe phenotype associated with alterations of this region. Whatever, mutation analysis in both genes is therefore essential as the distinction between these two syndromes is of obvious significance for genetic counseling considering the difference in heredity and neurodevelopmental outcome and patients with a *GLI3* mutation may be diagnosed as GCPS.

Interestingly, macrosomia was observed in at least 13% of GCPS cases in our series. Macrosomia and PD are also observed in Simpson–Golabi–Behmel syndrome type 1 (MIM# 312870), a X-linked mental retardation syndrome ascribed to *Glypican3* (*GPC3*) mutation, which was suspected in family G068, with two brothers displaying macrosomia and PD at birth. The frameshift *GLI3* mutation was inherited from their asymptomatic father carrying a somatic mosaic mutation. Along the same way, we identified a mosaic large deletion in a GCPS patient with developmental delay (G059). To our knowledge, only one instance of *GLI3* germline mosaicism has been already described in two PHS sibs,¹⁸ which is therefore a rare event.

Cerebral MRI may be useful to detect HH that was found in all PHS individuals of our series. Abnormal metacarpals in particular Y-shaped metacarpals appear to be a more significant criterion than insertional PD. At least three PHS patients without PD were already reported.^{10,18,27} All of them presented fused or hypoplastic metacarpal. The mouse model for PHS *Gli3*^{A699/A699} displays abnormal metacarpal morphology with PD or oligodactyly at a lower frequency.²⁸ Central poly/syndactyly and Y-shaped metacarpals are extremely uncommon in other syndromes. Although associated to a good neurodevelopmental outcome, PHS

displays a wide range of severity varying from mild to lethal phenotypes depending on the severity of malformations present in the individuals, in particular bilateral kidney agenesis, craniofacial features (agnathia, absence of oral orifice, cleft palate or premaxillary agenesis in one case), heart defects and/or reductional limb defects. Interestingly, skeletal dysplasia with ulna bowing, tibia and fibula hypoplasia was already reported in other cases described as PHS,^{10,29,30} further suggesting that acromesomelic limb shortening with radio-ulnar bowing, tibial and fibular hypoplasia/agenesis are part of the phenotypic spectrum of PHS. Interestingly, all mutations found in severe fetal phenotypes of our series were clustered in the middle third of the gene, between c.2941 and c.3324. To assess whether the severe craniofacial features observed (agnathia, absence of oral orifice) were a direct effect of the *GLI3* mutation, we undertook the expression analysis of *GLI3* during human development. Indeed, in addition to the early expression of *GLI3* in pharyngeal and then later in mandible and maxillary, *GLI3* was highly expressed in all target tissues of the disease.

Besides PHS cases, Y-shaped metacarpal is also observed in orofacio-digital syndrome type VI (OFD VI; MIM# 277170).³¹ Overlap of PHS with OFD has been previously discussed as oral anomalies (oral frenula, hamartoma, cleft palate) and/or skeletal dysplasia are often associated to *GLI3* mutations.¹⁰ Avila *et al.*³² screened eight patients with OFD associated with midline abnormalities but no mutation was found. They suggested that *GLI3* should be screened in patients with OFD only when associated to one of the pathognomonic sign of PHS (HH, mesoaxial PD, bifid epiglottis and IA).

In one case (G013), the association of IUGR, PD, bilateral renal agenesis and anal anteversion without macroscopic HH first led to the suspicion of Smith–Lemli–Opitz (SLO; MIM# 270400). After exclusion of a cholesterol biosynthesis defect, a *GLI3* screening identified a *de novo* frameshift mutation in exon 15. Retrospective analysis of the brain identified microscopic changes suggestive of hamartoma. This observation underlines the phenotypic overlap of PHS and SLO that was suggested previously,²² both disorders associating IUGR, PD and possible renal agenesis but IA, insertional PD and HH are exceptional in SLO.³³

CONCLUSION

Here we report on clinical and molecular data of a large series of 76 individuals from 55 families carrying a heterozygous *GLI3* mutation or rearrangement, 55 GCPS and 21 PHS, 41 being novel mutations. Our results render more precisely the genotype–phenotype correlation of *GLI3* mutations proposed by Johnston *et al.*, and further highlight the clinical overlap between GCPS and ACS and between PHS, SLO and OFD. Interestingly, our series including fetal cases enlarge the phenotypic spectrum of PHS to severe craniofacial and reductional limb defects, emphasize on the possible lethality of PHS with a clustering of truncating mutation in a subdomain of the ‘PHS’ *GLI3* domain. In addition, we add CCA among frequent signs of GCPS with a strong genotype–phenotype correlation of corpus callosum dysgenesis with truncating C terminal mutations, and macrosomia as a new clinical feature of GCPS.

CONFLICT OF INTEREST

The authors declare no conflict of interest.

ACKNOWLEDGEMENTS

We are grateful to the patients and their parents participating in this study.

WEB SOURCES

OMIM: <http://www.ncbi.nlm.nih.gov/omim>

PolyPhen2: <http://genetics.bwh.harvard.edu/pph2>

SIFT: <http://blocks.fhcrc.org/sift/SIFT.html>

Mutalyzer: <http://www.humgen.nl/mutalyzer/1.0.1>

LOVD: <http://www.lovd.nl/3.0>

- 1 Vortkamp A, Franz T, Gessler M, Grzeschik KH: Deletion of GLI3 supports the homology of the human Greig cephalopolysyndactyly syndrome (GCPS) and the mouse mutant extra toes (Xt). *Mamm Genome Off J Int Mamm Genome Soc* 1992; **3**: 461–463.
- 2 Kang S, Rosenberg M, Ko VD, Biesecker LG: Gene structure and allelic expression assay of the human GLI3 gene. *Hum Genet* 1997; **101**: 154–157.
- 3 Hall JG, Pallister PD, Clarren SK *et al*: Congenital hypothalamic hamartoblastoma, hypopituitarism, imperforate anus and postaxial polydactyly—a new syndrome? Part I: clinical, causal, and pathogenetic considerations. *Am J Med Genet* 1980; **7**: 47–74.
- 4 Clarren SK, Alvord Jr EC, Hall JG: Congenital hypothalamic hamartoblastoma, 68(3):hypopituitarism, imperforate anus, and postaxial polydactyly—a new syndrome? Part II: neuropathological considerations. *Am J Med Genet* 1980; **7**: 75–83.
- 5 Biesecker L, Johnston J: Syndromic and non-syndromic GLI3 phenotypes. *Clin Genet* 2005; **68**: 284–284.
- 6 Biesecker LG: The Greig cephalopolysyndactyly syndrome. *Orphanet J Rare Dis* 2008; **3**: 10.
- 7 Johnston JJ, Walker RL, Davis S *et al*: Zoom-in comparative genomic hybridisation arrays for the characterisation of variable breakpoint contiguous gene syndromes. *J Med Genet* 2007; **44**: e59.
- 8 Aza-Blanc P, Lin HY, Ruiz i Altaba A, Kornberg TB: Expression of the vertebrate Gli proteins in *Drosophila* reveals a distribution of activator and repressor activities. *Development (Cambridge, England)* 2000; **127**: 4293–4301.
- 9 Johnston JJ, Olivos-Glander I, Killoran C *et al*: Molecular and clinical analyses of Greig cephalopolysyndactyly and Pallister-Hall syndromes: robust phenotype prediction from the type and position of GLI3 mutations. *Am J Hum Genet* 2005; **76**: 609–622.
- 10 Johnston JJ, Sapp JC, Turner JT *et al*: Molecular analysis expands the spectrum of phenotypes associated with GLI3 mutations. *Hum Mutat* 2010; **31**: 1142–1154.
- 11 Kalfs-Suske M, Wild A, Topp J *et al*: Point mutations throughout the GLI3 gene cause Greig cephalopolysyndactyly syndrome. *Hum Mol Genet* 1999; **8**: 1769–1777.
- 12 Furniss D, Critchley P, Giele H, Wilkie AOM: Nonsense-mediated decay and the molecular pathogenesis of mutations in SALL1 and GLI3. *Am J Med Genet A* 2007; **143A**: 3150–3160.
- 13 Shin SH, Kogerman P, Lindström E, Toftgård R, Biesecker LG: GLI3 mutations in human disorders mimic *Drosophila* cubitus interruptus protein functions and localization. *Proc Natl Acad Sci USA* 1999; **96**: 2880–2884.
- 14 Krauss S, So J, Hambrock M *et al*: Point mutations in GLI3 lead to misregulation of its subcellular localization. *PLoS One* 2009; **4**: e7471.
- 15 Wildeman M, van Ophuizen E, den Dunnen JT, Taschner PEM: Improving sequence variant descriptions in mutation databases and literature using the Mutalyzer sequence variation nomenclature checker. *Hum Mutat* 2008; **29**: 6–13.
- 16 O'Rahilly R: Human embryo. *Nature* 1987; **329**: 385.
- 17 Crosnier C, Attié-Bitach T, Encha-Razavi F *et al*: JAGGED1 gene expression during human embryogenesis elucidates the wide phenotypic spectrum of Alagille syndrome. *Hepatology (Baltimore, MD)* 2000; **32**: 574–581.
- 18 Ng D, Johnston JJ, Turner JT *et al*: Gonadal mosaicism in severe Pallister-Hall syndrome. *Am J Med Genet A* 2004; **124A**: 296–302.
- 19 Debeer P, Peeters H, Driess S *et al*: Variable phenotype in Greig cephalopolysyndactyly syndrome: clinical and radiological findings in 4 independent families and 3 sporadic cases with identified GLI3 mutations. *Am J Med Genet A* 2003; **120A**: 49–58.
- 20 Furniss D, Kan S-H, Taylor IB *et al*: Genetic screening of 202 individuals with congenital limb malformations and requiring reconstructive surgery. *J Med Genet* 2009; **46**: 730–735.
- 21 Hurst JA, Jenkins D, Vasudevan PC *et al*: Metopic and sagittal synostosis in Greig cephalopolysyndactyly syndrome: five cases with intragenic mutations or complete deletions of GLI3. *Eur J Hum Genet* 2011; **19**: 757–762.
- 22 Biesecker LG, Graham Jr JM: Pallister-Hall syndrome. *J Med Genet* 1996; **33**: 585–589.
- 23 Putoux A, Nampoothiri S, Laurent N *et al*: Novel KIF7 mutations extend the phenotypic spectrum of acrocallosal syndrome. *J Med Genet* 2012; **49**: 713–720.
- 24 Putoux A, Thomas S, Coene KLM *et al*: KIF7 mutations cause fetal hydrocephalus and acrocallosal syndromes. *Nat Genet* 2011; **43**: 601–606.
- 25 Elson E, Perveen R, Donnai D, Wall S, Black GCM: De novo GLI3 mutation in acrocallosal syndrome: broadening the phenotypic spectrum of GLI3 defects and overlap with murine models. *J Med Genet* 2002; **39**: 804–806.
- 26 Speksnijder L, Cohen-Overbeek TE, MFCM Knapen *et al*: A de novo GLI3 mutation in a patient with acrocallosal syndrome. *Am J Med Genet A* 2013; **161**: 1394–1400.
- 27 Verloes A, David A, Ngô L, Bottani A: Stringent delineation of Pallister-Hall syndrome in two long surviving patients: importance of radiological anomalies of the hands. *J Med Genet* 1995; **32**: 605–611.
- 28 Hill P, Wang B, Rütter U: The molecular basis of Pallister-Hall associated polydactyly. *Hum Mol Genet* 2007; **16**: 2089–2096.
- 29 Encha-Razavi F, Larroche JC, Roume J *et al*: Congenital hypothalamic hamartoma syndrome: nosological discussion and minimum diagnostic criteria of a possibly familial form. *Am J Med Genet* 1992; **42**: 44–50.
- 30 Roscioli T, Kennedy D, Cui J *et al*: Pallister-Hall syndrome: unreported skeletal features of a GLI3 mutation. *Am J Med Genet A* 2005; **136A**: 390–394.
- 31 Poretti A, Vitiello G, Hennekam RCM *et al*: Delineation and diagnostic criteria of Oral-Facial-Digital Syndrome type VI. *Orphanet J Rare Dis* 2012; **7**: 4.
- 32 Avila M, Gigot N, Aral B *et al*: GLI3 is rarely implicated in OFD syndromes with midline abnormalities. *Hum Mutat* 2011; **32**: 1332–1333.
- 33 Quélin C, Loget P, Verloes A *et al*: Phenotypic spectrum of fetal Smith-Lemli-Opitz syndrome. *Eur J Med Genet* 2012; **55**: 81–90.
- 34 Ruppert JM, Vogelstein B, Arheden K, Kinzler KW: GLI3 encodes a 190-kilodalton protein with multiple regions of GLI similarity. *Mol Cell Biol* 1990; **10**: 5408–5415.