



HAL
open science

A Case-report of Unpredictable and Massive Voriconazole Intoxication in a Patient with Extensive CYP2C19 and CYP2C9 Polymorphisms.

Florian Lemaitre, Mathilde Barbaz, Lucie-Marie Scailteux, Fabrice Uhel, Jean-Marc Tadié, Marie-Clémence Verdier, Eric Bellissant

► **To cite this version:**

Florian Lemaitre, Mathilde Barbaz, Lucie-Marie Scailteux, Fabrice Uhel, Jean-Marc Tadié, et al.. A Case-report of Unpredictable and Massive Voriconazole Intoxication in a Patient with Extensive CYP2C19 and CYP2C9 Polymorphisms.. *Drug Metabolism and Pharmacokinetics*, 2013, 28 (5), pp.439-41. 10.2133/dmpk.DMPK-13-NT-007 . hal-00910224

HAL Id: hal-00910224

<https://univ-rennes.hal.science/hal-00910224>

Submitted on 27 Nov 2013

HAL is a multi-disciplinary open access archive for the deposit and dissemination of scientific research documents, whether they are published or not. The documents may come from teaching and research institutions in France or abroad, or from public or private research centers.

L'archive ouverte pluridisciplinaire **HAL**, est destinée au dépôt et à la diffusion de documents scientifiques de niveau recherche, publiés ou non, émanant des établissements d'enseignement et de recherche français ou étrangers, des laboratoires publics ou privés.

Note

A Case-report of Unpredictable and Massive Voriconazole Intoxication in a Patient with Extensive CYP2C19 and CYP2C9 Polymorphisms

Florian LEMAITRE^{1,2,3,4,*}, Mathilde BARBAZ⁵, Lucie-Marie SCAILTEUX¹, Fabrice UHEL^{3,5},
Jean-Marc TADIE^{3,5}, Marie-Clémence VERDIER^{1,2,3} and Eric BELLISSANT^{1,2,3}

¹Department of Clinical and Biological Pharmacology and Pharmacovigilance, Pharmacoepidemiology and Drug Information Center, Rennes University Hospital, Rennes, France

²Laboratory of Experimental and Clinical Pharmacology, Faculty of Medicine, Rennes 1 University, Rennes, France

³Clinical Investigation Center, CIC-P 0203, INSERM, Rennes, France

⁴EA4123 Barrières Physiologiques et Réponses Thérapeutiques, Faculty of Pharmacy, Paris XI University, Châtenay-Malabry, France

⁵Department of Infectious Diseases and Medical Intensive Care, Rennes University Hospital, Rennes, France

Full text of this paper is available at <http://www.jstage.jst.go.jp/browse/dmpk>

Summary: This case-report describes a massive voriconazole (VRZ) intoxication in a patient with a poor metabolizer profile, highlighted by low plasma main metabolite concentrations (N-oxide voriconazole), despite an extensive genetic profile for CYP2C19 and CYP2C9. The patient was treated with a therapeutic dose of VRZ but developed a neurotoxicity leading to hallucinations and coma while the plasma concentration of VRZ reached an exceptional level (20.0 µg/mL on day 10 of the treatment). Since neurological disorders diminished in parallel with the decrease of VRZ plasma concentrations, the coma was likely due to VRZ. The VRZ half-life, calculated to 58 h in this patient, was by far higher than the values reported in the literature. While VRZ concentrations slowly decreased, the N-oxide voriconazole concentrations slowly increased from day 15. Hypotheses for this lack of metabolism of VRZ are an inhibition of the metabolism by esomeprazole, a saturation of the metabolism or an enzymatic auto-inhibition of VRZ metabolism but none of these hypotheses have yet been explored. This case-report of unpredictable accumulation of VRZ in a patient without any genetic risk factor is an advocacy for systematic therapeutic drug monitoring of VRZ.

Keywords: voriconazole; N-oxide voriconazole; toxicology; pharmacokinetics; pharmacogenetics; therapeutic drug monitoring; neurotoxicity

Introduction

Voriconazole (VRZ) is a leading drug of the azole antifungal class used in the treatment of invasive aspergillosis and candidosis. Its pharmacokinetic variability is well-known and depends on numerous factors such as patient bodyweight, protein binding, or food and drug interactions.¹⁾ Low VRZ plasma levels have been associated with treatment failures whereas high VRZ plasma levels could lead to hepatotoxicity and neurotoxicity.²⁻⁵⁾ Therapeutic drug monitoring (TDM) is of interest (a therapeutic range from 1 to 5.5 µg/mL is usually recommended) for ensuring efficacy and safety.⁶⁾

VRZ is extensively metabolized in the liver and less than 2% of VRZ is excreted unchanged in the urine.¹⁾ VRZ is mainly metabolized by cytochrome P450 2C19 (CYP2C19) and to a lesser extent by CYP2C9 and CYP3A4 into inactive metabolites.⁷⁾

Among these metabolites, N-oxide voriconazole (N-oxide VRZ) is the main one. Genetic polymorphism of cytochrome enzymes has therefore a crucial impact on VRZ pharmacokinetics. The activity of the CYP2C19 is related to the different polymorphisms of the CYP2C19 gene. While CYP2C19*2 and CYP2C19*3 alleles lead to deficient proteins, the CYP2C19*1 allele leads to the functional protein.⁸⁾ Recently, another isoenzyme, CYP2C19*17, was reported to enhance CYP2C19 functionality.⁹⁾ Concretely, CYP2C19 polymorphisms could lead to a large variability in VRZ apparent clearance with a reduction of 66% in poor metabolizer (PM) patients.¹⁰⁾

Case-report: We describe herein a massive VRZ intoxication in a patient treated with therapeutic doses of VRZ, who had a PM profile highlighted by low plasma N-oxide VRZ concentrations despite normal CYP2C19 and CYP2C9 polymorphisms.

Received January 18, 2013; Accepted March 7, 2013

J-STAGE Advance Published Date: April 2, 2013, doi:10.2133/dmpk.DMPK-13-NT-007

*To whom correspondence should be addressed: Florian LEMAITRE, Pharm.D., Department of Clinical and Biological Pharmacology and Pharmacovigilance, Pharmacoepidemiology and Drug Information Center, Rennes University Hospital, 2, Rue Henri Le Guilloux, 35000 Rennes, France. Tel. +33-223234713, Fax. +33-299284184, E-mail: florian.lemaitre@chu-rennes.fr

This 36 year-old Caucasian male patient, with acute myeloblastic leukemia, was hospitalized in the hematological unit of our hospital. He had no particular medical history. His bodyweight was 60 kg. Upon hospital arrival, the patient presented a creatininemia of 65 $\mu\text{mol/L}$ [normal range (n) = 64–104 $\mu\text{mol/L}$] and an urea of 3.3 mmol/L (n = 2.5–7.5 mmol/L), a total bilirubinemia of 7 $\mu\text{mol/L}$ (n = 5–18 $\mu\text{mol/L}$), an aspartate aminotransferase (ASAT) of 32 UI/L (n = 0–35 UI/L) and an alanine aminotransferase (ALAT) of 47 UI/L (n = 0–45 UI/L). The patient was hemodynamically stable. He had received chemotherapy treatment (hydroxycarbamide 3,000 mg, cytarabine 200 $\text{mg/m}^2/24$ h, daunorubicine 60 $\text{mg/m}^2/24$ h, dexamethasone 40 mg and intrathecal methotrexate 15 mg) with rasburicase. Six days after treatment initiation, confusion and behavioral disorders led to a cerebral MRI being performed, which revealed a left frontal ischemic lesion (later attributed to leukostasis). Simultaneously, the patient presented a fever and a biological inflammatory syndrome. Treatment with antibiotics was then initiated [ceftriaxone 2 g plus spiramycin 3 million units thrice a day (TID) initially, then, because a translocation of the intestinal flora was suspected, the antibiotic treatment was modified to piperacillin-tazobactam 4 g TID and metronidazole 500 mg TID and finally vancomycin 2 g was introduced followed by meropenem 2 g TID for a positive culture of coagulase negative staphylococcus]. An increase in *Aspergillus* antigen, associated with nodular lung lesions on a chest CT-scan, led to the start of an intravenous treatment with VRZ 280 mg (4.4 mg/kg/12 h) BID without any loading dose. The patient was also treated with esomeprazole 40 mg daily until day 10. No other substrate, inhibitor or inducer of CYP2C19, CYP2C9 or CYP3A4 was administered to the patient. The patient was intubated and received no oral food which could have influenced the pharmacokinetics of VRZ. During the hospitalization, the patient presented a mild degradation of liver function with an increase of bilirubinemia up to 3N associated with liver cytolysis (ASAT and ALAT increased to 2N on day 11). Important visual and auditory hallucinations appeared on day 1 of VRZ treatment. VRZ treatment was discontinued for 24 h on day 3 and then resumed at the dose of 200 mg (3.1 mg/kg/12 h) BID. Consciousness troubles with a rapid evolution to coma appeared on day 4. The patient was intubated (Glasgow score of 5/15) and transferred to our medical Intensive Care Unit (ICU). Meningeal leukemic infiltration or intracranial aspergilloma was suspected.

Samples for the determination of VRZ plasma concentrations were drawn on day 5 and day 9, and TDM of VRZ was started on day 11 with a fully validated liquid chromatography-tandem mass spectrometry method.¹¹⁾ Concentrations were dramatically elevated with VRZ troughs of 12.3 $\mu\text{g/mL}$ and 15.1 $\mu\text{g/mL}$ on day 5 and day 8, respectively. Because of these results and of the onset of a dermatological lesion, VRZ was discontinued on day 11 and replaced by amphotericin B. The day before treatment discontinuation, the VRZ trough concentration reached 20.0 $\mu\text{g/mL}$. Concentrations slowly decreased to 8.5 $\mu\text{g/mL}$ on day 15 and to 0.7 $\mu\text{g/mL}$ on day 18. The VRZ trough concentration reached an undetectable level on day 21. We also investigated N-oxide VRZ concentrations on days 10, 15, 18 and 21 (Fig. 1). N-oxide VRZ trough concentrations were respectively 0.3 $\mu\text{g/mL}$, 2.0 $\mu\text{g/mL}$, 1.2 $\mu\text{g/mL}$ and undetectable and the ratio N-oxide VRZ over VRZ were 0.015 (day 10), 0.235 (day 15), 1.714 (day 18), meaning that almost no metabolization occurred in this patient during the first days of treatment.

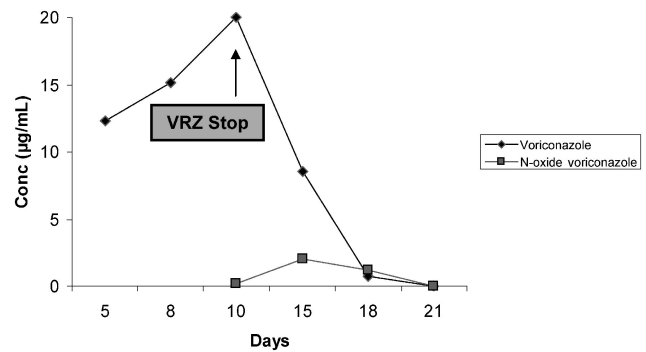


Fig. 1. Voriconazole (VRZ) and N-oxide voriconazole trough concentrations in $\mu\text{g/mL}$ according to days of treatment

The patient improved gradually and awakened on day 16 in parallel with the drug concentration decrease. He was then discharged from the ICU. The patient presented a complete remission of his acute myeloblastic leukemia three months after his discharge from the ICU.

Discussion

Although the correlation between VRZ trough concentrations and hepatic disturbances appears controversial, a link between elevated VRZ trough concentrations and neurological adverse events (mainly visual disturbance and hallucinations) has already been reported.^{4,12–15)} No adverse event is usually attributed to the metabolites of VRZ. Imhof *et al.* reported 6 cases of encephalopathy among 26 patients (23.1%) treated with VRZ.⁴⁾ Patients with neurological adverse events had significantly higher VRZ trough concentrations. Pascual *et al.* described an incidence of 31.2% in a cohort of 16 patients treated with VRZ and whose plasma concentrations were above 5.5 $\mu\text{g/mL}$ (range 5.6–11.2 $\mu\text{g/mL}$).¹⁴⁾ Boyd *et al.* reported two cases of patients who displayed neurological disorders after high exposure to VRZ (VRZ trough concentrations ranged from 9.0 to 17.5 $\mu\text{g/mL}$).¹⁵⁾ One of these patients presented confusion and hallucination (VRZ troughs were 9 $\mu\text{g/mL}$ on day 10 and 9.4 $\mu\text{g/mL}$ on day 13). The second patient with an extremely high VRZ trough concentration (17.5 $\mu\text{g/mL}$) became hypotensive and unresponsive after 13 days of treatment (Glasgow score 11/15). Weiler *et al.* also reported the case of an extremely high VRZ trough concentration associated with unconsciousness in a patient with liver cirrhosis, but the maximum VRZ trough concentration was reached on day 30 and was lower than in our patient (13.9 $\mu\text{g/mL}$).¹⁶⁾ Finally, a case of poisoning attempt with VRZ was reported by Rozé *et al.* The patient absorbed 9.8 g and VRZ trough concentrations reached levels above 30 $\mu\text{g/mL}$.¹⁷⁾

Since neurological disorders diminished in parallel to the decrease of VRZ plasma concentrations, the coma was likely due to VRZ.

The VRZ half-life, calculated as 58 h in our patient, was by far higher than the values reported in the literature (6 h).¹⁾ This finding is in favor of an important decrease in VRZ clearance. A medication administration error was investigated and not evidenced. The patient was treated with esomeprazole, a well-known CYP2C19 inhibitor, but this kind of drug-drug interaction has been found to be associated with a mild (15%) increase in VRZ exposition, judged as not clinically relevant by Wood *et al.*¹⁸⁾ This could have

led to a decrease in VRZ clearance but is unlikely to have resulted in such an accumulation. The patient presented as well a mild decrease in hepatic function which could have decreased VRZ clearance. Jeu *et al.* reported indeed, only a half-decrease of VRZ clearance in a patient with moderate liver dysfunction.¹⁹⁾

Taken together, all these findings could hardly explain the rapid and massive accumulation of VRZ in this patient treated with a therapeutic dose of VRZ. Thus, we made the hypothesis of a PM profile and investigated the different polymorphisms which could explain VRZ intoxication by sequencing the gene. PMs for CYP2C19 and CYP2C9 are rare among the Caucasian population (3% and 0.2–1.0% respectively).^{14,15)} CYP2C19 and CYP2C9 genotypes have been determined by direct sequencing of the promoter-region, exons and 3'UTR-region. The patient was shown to be homozygous for a normal sequence of CYP2C19 and heterozygous *2/*1 for the CYP2C9 gene. This genetic profile is likely to lead to an extensive metabolizing profile. On day 5 of treatment and in spite of the discontinuation of the therapy for 24 h during this period, the patient presented a VRZ plasma concentration by far higher (12.6 µg/mL) than the plasma concentration depicted to be neurotoxic. The plasma level reached on day 10 was exceptional (20.0 µg/mL). On this day, by determining a low N-oxide VRZ trough concentration and a high N-oxide VRZ over VRZ ratio, we found a lack of VRZ metabolism into his major metabolite. Thereafter, the VRZ concentrations decreased while the N-oxide VRZ concentrations increased slowly. The resumption of the metabolism on day 15 could be attributed either to the discontinuation of the esomeprazole treatment on day 10, to a saturation of the metabolism or to an enzymatic auto-inhibition of VRZ metabolism, but none of these hypothesis have yet been explored.

In conclusion, the present case depicted a massive accumulation in a patient with hallucinations and coma during a VRZ treatment at a therapeutic dose. While no evidence for VRZ accumulation could be highlighted, the high VRZ trough concentrations reported in our patient are likely responsible for the neurological toxicity. The patient presented a clear metabolism dysfunction reflected by low VRZ metabolite levels. Clinicians should be extremely cautious when initiating treatments in patients with drugs whose elimination is mediated by polymorphic drug metabolizing enzymes such as CYP2C19 (voriconazole, phenytoine, fludione, valproic acid, fluoxetine, ...) and repeated TDM should be considered. This case-report of an unpredictable and massive accumulation of VRZ in a patient without any genetic risk factor is an advocacy for a systematic and prompt TDM of this drug.

Acknowledgment: The authors would like to thank Dr. Céline Eiden, Dr. Olivier Mathieu, Dr. Nicolas Pottier and Prof. Franck Broly for their help with this work.

References

- 1) Theuretzbacher, U., Ihle, F. and Derendorf, H.: Pharmacokinetic/pharmacodynamic profile of voriconazole. *Clin. Pharmacokinet.*, **45**(7): 649–663 (2006).
- 2) Mitsani, D., Nguyen, M. H., Shields, R. K., Toyoda, Y., Kwak, E. J.,

- Silveira, F. P., Pilewski, J. M., Crespo, M. M., Bermudez, C., *et al.*: Prospective, observational study of voriconazole therapeutic drug monitoring among lung transplant recipients receiving prophylaxis: Factors impacting levels and associations between serum troughs, efficacy and toxicity. *Antimicrob. Agents Chemother.*, **56**(5): 2371–2377 (2012).
- 3) Smith, J., Safdar, N., Knasinski, V., Simmons, W., Bhavnani, S. M., Ambrose, P. G. and Andes, D.: Voriconazole therapeutic drug monitoring. *Antimicrob. Agents Chemother.*, **50**(4): 1570–1572 (2006).
- 4) Imhof, A., Schaer, D. J., Schanz, U. and Schwartz, U.: Neurological adverse events to voriconazole: evidence for therapeutic drug monitoring. *Swiss Med. Wkly.*, **136**: 739–742 (2006).
- 5) Denning, D. W., Ribaud, P., Milpied, N., Caillot, D., Herbrecht, R., Thiel, E., Haas, A., Ruhnke, M. and Lode, H.: Efficacy and safety of voriconazole in the treatment of acute invasive aspergillosis. *Clin. Infect. Dis.*, **34**(5): 563–571 (2002).
- 6) Park, W. B., Kim, N. H., Kim, K. H., Lee, S. H., Nam, W. S., Yoon, S. H., Song, K. H., Choe, P. G., Kim, N. J., *et al.*: The effect of therapeutic drug monitoring on safety and efficacy of voriconazole in invasive fungal infections: A randomized controlled trial. *Clin. Infect. Dis.*, **55**(8): 1080–1087 (2012).
- 7) Hyland, R., Jones, B. C. and Smith, D. A.: Identification of the cytochrome P450 enzymes involved in the N-oxidation of voriconazole. *Drug Metab. Dispos.*, **31**(5): 540–547 (2003).
- 8) Desta, Z., Zhao, X., Shin, J. G. and Flockhart, D. A.: Clinical significance of the cytochrome P450 2C19 genetic polymorphism. *Clin. Pharmacokinet.*, **41**(12): 913–958 (2002).
- 9) Li-Wan-Po, A., Girard, T., Farndon, P., Cooley, C. and Lithgow, J.: Pharmacogenetics of CYP2C19: functional and clinical implications of a new variant CYP2C19*17. *Br. J. Clin. Pharmacol.*, **69**(3): 222–230 (2010).
- 10) Mikus, G., Schöwel, V., Drzewinska, M., Rengelshausen, J., Ding, R., Riedel, K. D., Burhenne, J., Weiss, J., Thomsen, T., *et al.*: Potent cytochrome P450 2C19 genotype-related interaction between voriconazole and the cytochrome P450 3A4 inhibitor ritonavir. *Clin. Pharmacol. Ther.*, **80**(2): 126–135 (2006).
- 11) Verdier, M. C., Bentué-Ferrer, D., Tribut, O. and Bellissant, E.: Liquid chromatography-tandem mass spectrometry method for simultaneous quantification of four triazole antifungal agents in human plasma. *Clin. Chem. Lab. Med.*, **48**(10): 1515–1522 (2010).
- 12) Matsumoto, K., Ikawa, K., Abematsu, K., Fukunaga, N., Nishida, K., Fukamizu, T., Shimodono, Y., Morikawa, N., Takeda, Y., *et al.*: Correlation between voriconazole trough plasma concentration and hepatotoxicity in patients with different CYP2C19 genotypes. *Int. J. Antimicrob. Agents*, **34**(1): 91–94 (2009).
- 13) Kim, S. H., Yim, D. S., Choi, S. M., Kwon, J. C., Han, S., Lee, D. G., Park, C., Kwon, E. Y., Park, S. H., *et al.*: Voriconazole-related severe adverse events: clinical application of therapeutic drug monitoring in Korean patients. *Int. J. Infect. Dis.*, **15**(11): e753–e758 (2011).
- 14) Pascual, A., Calandra, T., Bolay, S., Bille, J., Calandra, T. and Marchetti, O.: Voriconazole therapeutic drug monitoring in patients with invasive mycoses improves efficacy and safety outcomes. *Clin. Infect. Dis.*, **46**(2): 201–211 (2008).
- 15) Boyd, A. E., Modi, S., Howard, S. J., Moore, C. B., Keevil, B. G. and Denning, D. W.: Adverse reactions to voriconazole. *Clin. Infect. Dis.*, **39**(8): 1241–1244 (2004).
- 16) Weiler, S., Zoller, H., Graziadei, I., Vogel, W., Bellmann-Weiler, R., Joannidis, M. and Bellmann, R.: Altered pharmacokinetics of voriconazole in a patient with liver cirrhosis. *Antimicrob. Agents Chemother.*, **51**(9): 3459–3460 (2007).
- 17) Rozé, H., Lafargue, M., Joannes-Boyau, O., Batoz, H., Dromer, C., Breilh, D. and Janvier, G.: Toxicokinetics of voriconazole during massive intentional poisoning. *J. Antimicrob. Chemother.*, **64**(3): 662–663 (2009).
- 18) Wood, N., Tan, K., Purkins, L., Layton, G., Hamlin, J., Kleinermans, D. and Nichols, D.: Effect of omeprazole on the steady-state pharmacokinetics of voriconazole. *Br. J. Clin. Pharmacol.*, **56** Suppl 1: 56–61 (2003).
- 19) Jeu, L., Piacenti, F. J., Lyakhovetskiy, A. G. and Fung, H. B.: Voriconazole. *Clin. Ther.*, **25**(5): 1321–1381 (2003).