



## Biceps femoris flap for closure of ischial pressure ulcers

Nicolas Bertheuil, Vincent Huguier, Sylvie Aillet, Marion Beuzeboc, Eric Watier

### ► To cite this version:

Nicolas Bertheuil, Vincent Huguier, Sylvie Aillet, Marion Beuzeboc, Eric Watier. Biceps femoris flap for closure of ischial pressure ulcers. *European Journal of Plastic Surgery*, 2013, 6 (10), pp.639-644. 10.1007/s00238-013-0862-z . hal-00875785

**HAL Id: hal-00875785**

**<https://univ-rennes.hal.science/hal-00875785>**

Submitted on 22 Oct 2013

**HAL** is a multi-disciplinary open access archive for the deposit and dissemination of scientific research documents, whether they are published or not. The documents may come from teaching and research institutions in France or abroad, or from public or private research centers.

L'archive ouverte pluridisciplinaire **HAL**, est destinée au dépôt et à la diffusion de documents scientifiques de niveau recherche, publiés ou non, émanant des établissements d'enseignement et de recherche français ou étrangers, des laboratoires publics ou privés.

## **Biceps femoris flap for closure of ischial pressure ulcers.**

Nicolas Bertheuil<sup>1,2</sup>, Vincent Huguier<sup>3</sup>, Sylvie Aillet<sup>1</sup>, Marion Beuzeboc<sup>1</sup>, Eric Watier<sup>1</sup>.

*1 - Department of Plastic, Reconstructive and Aesthetic Surgery, Hospital Sud, University of Rennes 1, Rennes, France.*

*2 - INSERM U917, University of Rennes 1, Rennes, France.*

*3 - Department of Plastic and Reconstructive Surgery, Poitiers University Hospital, Poitiers, France.*

### **Abstract**

Background : The surgical management of stages III and IV pressure ulcers in spinal cord injury patients is usually based on a large debridement of necrotic tissue before performing a cover of the defect by a flap. The purpose of our study is to analyze our results in terms of morbidity and recurrence of pressure ulcers covered by biceps femoris musculocutaneous flap and compares it with literature data.

Methods : A retrospective clinical study of 23 consecutive patients operated for stage IV ischial pressure ulcers by biceps femoris flap was carried out. Other surgical techniques coverage of pressure ulcers as well as all patients with pressure ulcers on another anatomical location were excluded from this study. An analytical statistics in search of a risk factor for recurrence by log rank test was also performed.

Results : The mean follow-up was 68.4 months. Primary healing was obtained without complications in 30.8 and 38.4 % had a recurrence of the ulcer. Seroma was statistically correlated to a significant risk of recurrence of pressure ulcers ( $p = 0.0284$ , log rank test), as well as to drains removal before the eighth day ( $p = 0.0114$ ).

Conclusions : Surgical management of ischial pressure ulcers remains as a difficult procedure with significant postoperative complications and a high recurrence rate.

Level of Evidence: Level IV, therapeutic study.

## **Introduction**

Despite improvement in therapeutic education of spinal cord injury (SCI) patients, ulcers remain a dreaded complication responsible for a high rate of rehospitalisation [1] and have a significant socio-economic impact. Eighty-five percent of patients with spinal cord injury will have at least one pressure ulcer during their lifetime and 70% will suffer multiple pressure ulcers [2]. While therapeutic education was an integral part of treatment, the surgical management of stage III and IV pressure sores is based on a large debridement of necrotic tissue before covering the defect by a flap. Among pelvic pressure ulcers, the ischial location is associated with the highest rate of complications and recurrences (up to 40%[3,4]). The principle of surgical treatment of pelvic pressure ulcers, and more particularly ischial pressure ulcers, must always consider the risk of recurrence and select a treatment option that offers the best results while preserving the maximum skin capital and therefore the possibility of a second flap in case of reoperation. The myocutaneous flaps meet these criteria well. We regularly perform a musculo-cutaneous biceps femoris flap after surgical debridement of

ischial pressure sores. The aim of our clinical retrospective study, regarding 23 patients with 26 ischial pressure ulcers, was to analyze our results in terms of morbidity and recurrence of pressure ulcers and compare it with literature data.

## **Patients and methods**

We report the experience of the Department of Plastic Surgery of Rennes University Hospital through a retrospective clinical study of 23 consecutive patients operated for stage IV ischial pressure ulcers according to National Pressure Ulcer Advisory Panel Scale operated between February 1996 and July 2008 by biceps femoris flap. Other surgical techniques than biceps femoris flap as well as all patients with pressure ulcers in other anatomical locations were excluded from this study. This study have been performed in accordance with the ethical standards laid down in the 1964 Declaration of Helsinki and was in agreement with French bioethics laws of 7 july 2011.

Data collection was done through analysis of medical records and also by telephone call with referring physicians and / or patients.

For each patient, we collected age, sex, weight and height, body mass index and active tobacco smoking in the month before the operation. Data on the pressure ulcers included if the ulcer was the first episode or a recurrence. Data concerning surgery included postoperative complications, duration of drainage, time of hospital stay, the period before passing to wheelchair and the presence or absence of postoperative recurrence.

### ***Preoperative period***

All patients underwent at least two preoperative surgical consultations. The modalities of treatment were clearly explained to patients as for postoperative care in the rehabilitation medicine center and requirement for the three-to-four weeks of bed rest, before passing to wheelchair. The evaluation of nutritional status and correction of anemia were systematically undertaken preoperatively. Patients who refused this management were not operated.

### ***Operative procedure***

All procedures were performed in the prone position under general anesthesia. Urinary catheter was systematically installed before starting the procedure to avoid urinary contamination of dressings. Surgical treatment consisted of two operative steps and began with radical surgical debridement (preceded by an injection of methylene blue) for resection the bursa and devitalized soft tissues associated with systematic partial ischiectomy. In all cases bacteriological samples of the soft tissues and bone were obtained. The Reconstruction was achieved by a Biceps Femoris Flap combining a fasciocutaneous flap from the posterior surface of the thigh and a hamstring muscle flap turned in 180 degree initially as described by Conway and Griffith [5] (Figure 1). In all cases, skin closure was achieved without tension after placement of two drains, one in contact with the ischium and the other in the subcutaneous plane. We closed with an adhesive occlusive dressing (OpSite ®) to prevent bacterial contamination.

### *Postoperative care*

Patients were maintained in supine position on an air-fluidized bed for a period of 3 to 4 weeks. Truncal flexion of about 40 degree was only permitted during meals. The nursing was done daily by placing the patient in the lateral decubitus position which allowed the monitoring of pressure points. In addition, a low-residue fiber diet was instituted during the first days. Antibiotic therapy was initiated only in case of appearance of local signs of infection and/or positive bone samples and this was always discussed with our colleagues of the infectious diseases department (for type and duration of antibiotic treatment).

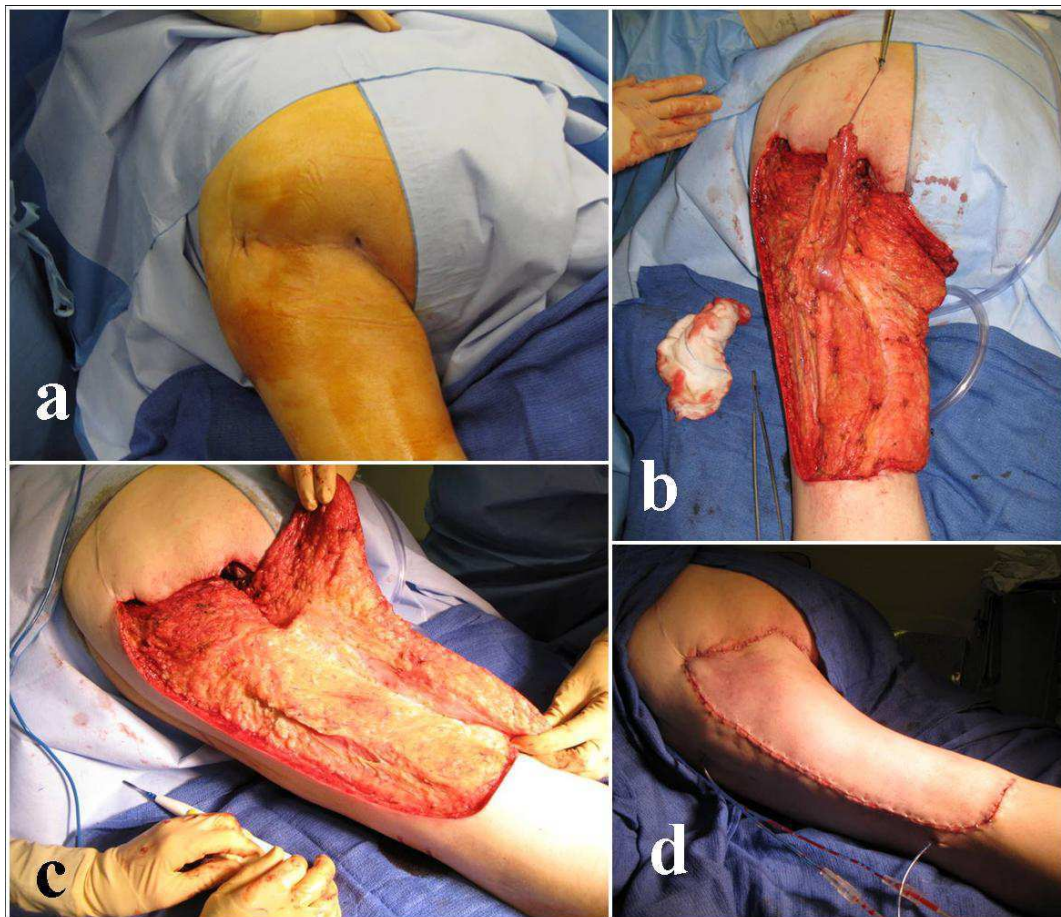


Fig. 1 Surgical technique of biceps femoris flap.

a Preoperative view.

b Intraoperative view of the fasciocutaneous flap from the posterior surface of the thigh.

c The distal tendon of the long head of biceps is cut, then we realize 180° reversal of the biceps femoris muscle and the suture on the ischium.

d Postoperative result

### ***Statistical analysis***

A descriptive analysis of all data was first carried out. Then, we performed statistical analysis in search of a risk factor of recurrence by log rank test and a flap survival curve using the Kaplan-Meier method (Figure 2). Significance was set at  $P < 0.05$ .

### **Results**

Our series included 23 spinal cord injury patients with a total of 26 pressure ulcers who underwent surgery for stages IV ischial pressure ulcer and who received identical surgical management. The data is summarized in Tables 1 and 2. Our series included 23 patients (20 males, 3 females) with 19 paraplegic patients (82.6%) and 4 tetraplegic patients (17.4%). Out of these 23 patients, 20 had a trauma (87%) and 3 had a neurological etiology (13%). The mean age was 40.4 years (range 24 to 79), the mean weight was 68.2 kg (45 to 110), the mean height was 169 centimeters (155 to 184 centimeters), the mean body mass index was 23.5 (15.1 to 36.8). Twelve patients were smokers during the month before operation. The mean follow up was 68.42 months ranging from 29 to 179 months. This was the first ulcer in 19 cases and the second ulcer in 7 cases.

In the post-operative course, of the 26 operations, healing was obtained in 16 procedures (61.5%) including 8 times without any complications (30.8%), 7 procedures resulted in a recurrence of the ulcer (27.9%) after a mean time of 26.8 months [range 8 to 84 months] after the initial operation and 3 procedures failed (no primary healing). We had 10 cases of wound dehiscence (38.4%) including 7 cases healed by secondary intention, 3 cases of seroma (11.5%), 2 cases of partial flap necrosis (Table 3). Furthermore, a urinary tract infection secondary to catheterization was found in 5 cases (19.2%) and was treated by catheter

removal and antibiotics. We performed 12 reoperations (out of 10 patients) for wound dehiscence, necrosis and recurrence of the ulcer with 9 remobilization of the biceps femoris muscle (with two patients operated two times). Two remobilizations were associated with an additional gluteus maximus flap for complete coverage of the defect, and one case was reconstructed with a gluteus maximus flap alone.

The average length of stay was 14.26 days. The access to wheelchair sitting was allowed after a mean period of 41.66 days in the rehabilitation medicine department.

Seroma was statistically correlated to a significant risk of recurrence of pressure ulcers ( $p = 0.0284$ , log rank test), as well as to drains removal before eighth day ( $p = 0.0114$ ) (Table 4).

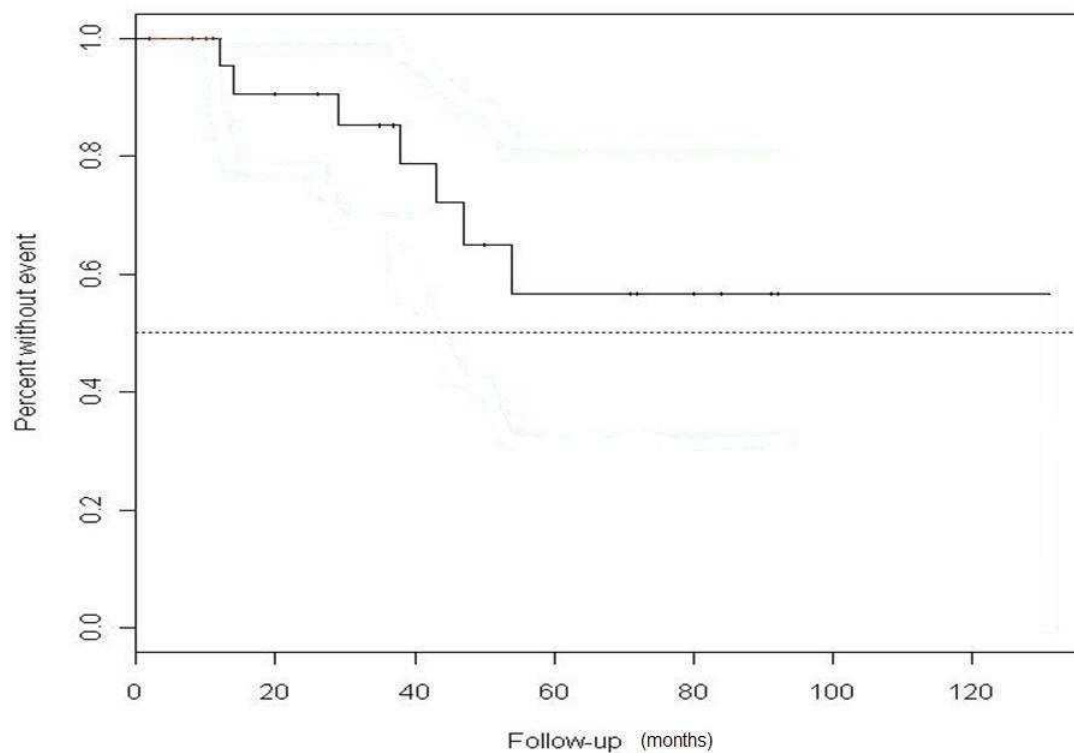


Fig. 2 Survival curve of biceps femoris flap by Kaplan–Meier

Table 1 - Pre-operative data of our series about 26 ischial pressure ulcer

	n	means	%
Age	23	40,4	
Size (in cm)	23	169	
Weight (in kilograms)	23	68,2	
Body mass index	23	23,5	
Body mass index <18,5	4		17,4
Body mass index >25	4		17,4
Gender (male)	20		87
Gender (female)	3		13
Paraplegic	19		82,6
Tetraplegic	4		17,4
Aetiology traumatic	20		87
Aetiology non-traumatic	3		13
First Ulcer	19		73
Recurrent ulcer	7		27
Chronic ulcer (> 6 months)	17		65,4
Smoking one month before surgery	12		44,4

Table II - post-operative data by surgical procedure (n=26)

	n	%	means	SD
Hospital stay (in days)			14,26	6,42
Days of drainage			9,64	2,96
the period before passing to wheelchair (in days)			41,66	16,49
Time between surgery and recurrence (in months)			26,83	28,77
Follow-up (in months)			68,42	41,49
Reoperation by readvancement of biceps	9	75		
Reoperation by readvancement of biceps + gluteus maximus	2	16,7		
Reoperation by gluteus maximus	1	8,3		
Antibiotic therapy	yes	14	53,8	
	no	12	46,2	

Table 3 - Complications of our patients (in a total of 26 operations)

Type	n	%
Wound dehiscence	10	38,4
Partial flap necrosis	2	7,7
Wound infection	2	7,7
Seroma	3	11,5
Recurrence	7	27,9
Reoperation	12	46,2
Hematoma	0	0
Urinary infection	5	19,2
Healing without complications	8	30,8

Table 4 - Statistical analysis of risk factors for recurrence

	n	p (log rank test)
male	23	0,1559
Body mass index < 18,5	4	0,5231
Body mass index < 18,5 and > 25	8	0,6628
Smoking one months before surgery	12	0,0782
First ulcer	19	0,3483
Paraplegia	18	0,8728
Wound dehiscence	10	0,4398
Seroma	3	0,0284 ★
Urinary infection	5	0,3043
Drainage < 8 (in days)	5	0,0114 ★

The level of significance for all statistical tests was set at  $p \leq 0.05$ .

★ is added after a significant result.

## Discussion

Surgical management of patients with pressure ulcers may be difficult, justifying a therapeutic strategy involving multidisciplinary collaboration. Patients which are considered for a surgical therapy are mostly spinal cord injury patients with stages III and IV pressure sores. It is known that early surgery provides better results than secondary healing [1]. However, to date there has been no evidence in the literature demonstrating the superiority of one technique of

flap coverage compared to another [6]. This treatment is for the only purpose of restoring padding's quality on a support area that is devoid of any sensitivity protection. It must be followed by a more comprehensive management of the patient in term of rehabilitation.

Ischial localization was the most difficult to treat with the highest immediate complication rate and long-term recurrence ranging from 19% to 41% depending on the series [4,7]. This situation is caused by the close proximity to the perineum, that promotes local maceration, and mechanical stresses such as shear in the sitting position, that be more important than for other locations.

Surgical treatment of ischial pressure sores has been known for many years [5,8-9]. It consists partly of a wide debridement of infected necrotic tissue associated with a partial ischiectomy of exposed bones that is macroscopically infected [10-12] and subsequent to the closure of the defect by a flap. Therefore, the choice of flap should take into account the quality of the padding and surgical history (including history of other flap). Moreover, we must preserve therapeutic options in case of failure or recurrence. Overall, the purpose of the surgical treatment is to obtain a stable result in time, to preserves reconstructive options in the event of ischial pressure ulcer recurrence and to avoid having scar in areas of support.

In our study, we realized twenty six biceps femoris flap dissociated skin / muscle according to Conway et al [5] for covering ischial pressure ulcer in twenty three patients with 61.5% success rate (with 30.8% of healing without complications). The recurrence rate in our serie was 38.4% with a follow-up ranged from 29 to 179 months (average 68.4 months) which was comparable to other series in the literature [3-4,7,13-14]. Recurrences could be treated each time by a remobilization of the flap which was done 2 times in two of our patients without having recourse to another flap. Recurrences could be explained by the fact that we use a

dissociated flap skin and muscle with a large fasciocutaneous detachment that can foster seromas and wound dehiscence.

Furthermore in our study, when the drains were removed too early, it increased the risk of seroma occurrence, indeed statistical analysis showed that seroma ( $p=0.0284$ ) and postoperative drainage period of less than eight days ( $p=0.0114$ ) were significant risk factors for ulcer recurrence for this operation. Indeed, drains were left in active drainage until ablation, which was carried out when the volume was less than 20 ml a day.

Another aspect related to this technique may be the compulsory sacrifice of arterial perforators (one or two of the three main pedicles from the deep femoral artery [15]) required to allow flap rotation (Type II according to Mathes and Nahai classification [16]) and that could induce vascular damage.

There are several variations of the musculo-cutaneous biceps femoris flaps for ischial pressure ulcer treatment like as a VY advancement [17], as a island flap [18], an advancement flap [19] or rotated as in our center.

Our results were comparable to authors using a VY advancement flap, however we prefer this technique because in case of wound dehiscence and / or recurrence, the flap is more easily remobilised. In our opinion, it also provides better padding of the ischium in terms of thickness [20].

For ischial pressure ulcer coverage, skin grafts found no operative indication because they do not provide coverage quality. Conventional fasciocutaneous flaps seem inadvisable because they do not provide results as good as myocutaneous flap for stage III and IV. Indeed they are associated with a greater recurrence rate [21]. The gluteus maximus myocutaneous flap is the surgical alternative to the hamstring flap. It has the advantage of being in the same anatomical

region, having the scar outside the areas of support, with lesser disposition to potential contractures, and it seems to be less prone to excessive tension in the sitting position.

The perforator flaps have emerged in recent years like, for example the inferior gluteal artery perforator (IGAP) flap [22]. These flaps have the advantage of saving muscle function which makes them interesting for ambulatory patients. Nevertheless, the scars are in the support area and they can sometimes provide inadequate thickness cover. Free flaps are for exceptional indications and reserved of pan-pelvic pressure sores when local and regional flaps were inadequate to obtain adequate coverage.

The success of pressure ulcer surgery depends not only on the appropriate flap choice but also on patient education and compliance [23]. Furthermore, the postoperative period requires great care in nursing and in maintaining supine position. Sitting position should not reasonably be allowed before the fourth week with a gradual passage to wheelchair if local wound conditions permitted. In our department, patients were clearly informed preoperatively of surgical procedures. Moreover, anti-bedsore measures and equipment, self-monitoring (with mirror) and routine decompression maneuvers (for paraplegic patients) were performed in rehabilitation medicine center.

*Conflict of interest and funding: none.*

## **Acknowledgements**

The authors wish to thank Dr Cédric Ménard for this English corrections of the manuscript and Dr Boris Campillo-gimenez for these statistical analysis.

## **References**

- [1] Le Chapelain L, Fyad JP, Beis JM, Thisse MO, Andre JM (2001) Early surgery management of pelvic region pressure ulcers versus directed cicatrization in a population of spinal cord injured patients. *Ann Readapt Med Phys* 44: 608-12.
- [2] Byrne DW, Salzberg CA (1996) Major risk factors for pressure ulcers in the spinal cord disabled: a literature review. *Spinal Cord* 34: 255-63.
- [3] Keys KA, Daniali LN, Warner KJ, Mathes DW (2010) Multivariate predictors of failure after flap coverage of pressure ulcers. *Plast Reconstr Surg* 125: 1725-34.
- [4] Tavakoli K, Rutkowski S, Cope C, et al (1999) Recurrence rates of ischial sores in para- and tetraplegics treated with hamstring flaps: an 8-year study. *Br J Plast Surg* 52: 476-9.
- [5] Conway H, Griffith BH 1956 Plastic surgery for closure of decubitus ulcers in patients with paraplegia; based on experience with 1,000 cases. *Am J Surg* 91: 946-75.
- [6] Tchanque-Fossuo CN, Kuzon WM, Jr (2011) An evidence-based approach to pressure sores. *Plast Reconstr Surg* 127: 932-9.
- [7] Voulliaume D, Grecea M, Viard R, Brun A, Comparin JP, Foyatier JL (2011) Surgical issues and outcomes in ischial pressure sores treatment. *Ann Chir Plast Esthet* 56: 528-39.
- [8] Dansereau JG, Conway H. Closure of Decubiti in Paraplegics (1964) Report of 2000 Cases. *Plast Reconstr Surg* 33: 474-80.
- [9] Sanchez S, Eamegdool S, Conway H (1969) Surgical treatment of decubitus ulcers in paraplegics. *Plast Reconstr Surg* 43: 25-8.
- [10] Dhami LD, Gopalakrishna A, Thatte RL (1985) An objective study of the dimensions of the ischial pressure point and its correlation to the occurrence of a pressure sore. *Br J Plast Surg* 38: 243-51.
- [11] Karaca AR, Binns JH, Blumenthal FS (1978) Complications of total ischiectomy for the treatment of ischial pressure sores. *Plast Reconstr Surg* 62: 96-9.

- [12] Kauer C (1985) Ischiatic pressure sores: reconstruction of the gluteal fold. *Ann Chir Plast Esthet* 30: 171-4.
- [13] Foster RD, Anthony JP, Mathes SJ, Hoffman WY (1997) Ischial pressure sore coverage: a rationale for flap selection. *Br J Plast Surg* 50: 374-9.
- [14] Yamamoto Y, Tsutsumida A, Murazumi M, Sugihara T (1997) Long-term outcome of pressure sores treated with flap coverage. *Plast Reconstr Surg* 100: 1212-7.
- [15] Quaba AA, Chapman R, Hackett ME (1988) Extended application of the biceps femoris musculocutaneous flap. *Plast Reconstr Surg* 81: 94-105.
- [16] Mathes SJ, Nahai F (1981) Classification of the vascular anatomy of muscles: experimental and clinical correlation. *Plast Reconstr Surg* 67: 177-87.
- [17] Hurteau JE, Bostwick J, Nahai F, Hester R, Jurkiewicz MJ (1981) V-Y advancement of hamstring musculocutaneous flap for coverage of ischial pressure sores. *Plast Reconstr Surg* 68:539-42.
- [18] James JH, Moir IH (1980) The biceps femoris musculocutaneous flap in the repair of pressure sores around the hip. *Plast Reconstr Surg* 66:736-9.
- [19] Tobin GR, Sanders BP, Man D, Weiner LJ (1981) The biceps femoris myocutaneous advancement flap: a useful modification for ischial pressure ulcer reconstruction. *Ann Plast Surg* 6:396-401.
- [20] Mateu J, Laurent B, Rouif M, Ballon G, Greco JM (1991) Covering of ischial pressure sores using a fasciocutaneous flap from the posterior surface of thigh (modified Griffith method) after mattressing with the biceps femoris. About 11 cases. *Ann Chir Plast Esthet* 36: 337-46
- [21] Watier E, Chevrier S, Georgieu N, Pardo A, Schück S, Pailheret JP (2000) Our experience with ischial pressure sores in a series of 34 patients. *Eur J Plast Surg* 23: 32-523.

[22] Thiessen FE, Andrades P, Blondeel PN, et al (2011) Flap surgery for pressure sores: should the underlying muscle be transferred or not? J Plast Reconstr Aesthet Surg 64: 84-90.

[23] Kierney PC, Engrav LH, Isik FF, Esselman PC, Cardenas DD, Rand RP (1998) Results of 268 pressure sores in 158 patients managed jointly by plastic surgery and rehabilitation medicine. Plast Reconstr Surg 102: 765-72.

**Legend's figure:**

Figure 1. Surgical technique of Biceps femoris flap. a- Preoperative view. b- Intraoperative view of the fasciocutaneous flap from the posterior surface of the thigh. c- The distal tendon of the long head of biceps is cut, then we realize 180 degree reversal of the biceps femoris muscle and the suture on the ischium. d- Postoperative result.

Figure 2. Survival curve of biceps femoris flap by Kaplan-Meier.