



HAL
open science

Biological therapy of strontium-substituted bioglass for soft tissue wound-healing: Responses to oxidative stress in ovariectomised rats.

Samira Jebahi, Hassane Oudadesse, N. Jardak, Ines Khayat, Hassib Keskes, Abdelmajid Khabir, Tarek Rebai, Hafed El Feki, Abdelfattah El Feki

► To cite this version:

Samira Jebahi, Hassane Oudadesse, N. Jardak, Ines Khayat, Hassib Keskes, et al.. Biological therapy of strontium-substituted bioglass for soft tissue wound-healing: Responses to oxidative stress in ovariectomised rats.. *Annales Pharmaceutiques Françaises*, 2013, 71 (4), pp.234-42. 10.1016/j.pharma.2013.05.003 . hal-00845712

HAL Id: hal-00845712

<https://univ-rennes.hal.science/hal-00845712v1>

Submitted on 5 Dec 2013

HAL is a multi-disciplinary open access archive for the deposit and dissemination of scientific research documents, whether they are published or not. The documents may come from teaching and research institutions in France or abroad, or from public or private research centers.

L'archive ouverte pluridisciplinaire **HAL**, est destinée au dépôt et à la diffusion de documents scientifiques de niveau recherche, publiés ou non, émanant des établissements d'enseignement et de recherche français ou étrangers, des laboratoires publics ou privés.

Biological therapy of strontium-substituted bioglass for soft tissue wound-healing: Responses to oxidative stress in ovariectomised rats

La thérapie biologique de verre bioactif substitué au strontium pour
laticatrisation de tissu mou : les réponses au stress oxydatif chez la
rateovariectomisée

**S. Jebahia^{*,b,d}, H. Oudadesse^{a,e}, N. Jardak^{d,e}, I. Khayata^a, H. Keskes^{d,e},
A. Khabire^e, T. Rebaï^d, H. El Feki^{c,e}, A. El Feki**

^aUniversity of Rennes-1, UMR CNRS 6226, campus de Beaulieu, 263, avenue du Général-Leclerc,
35042 Rennes, France

^bAnimal Ecophysiology Laboratory, Sfax Faculty of Science, Department of Life Sciences, Sfax,
Tunisia

^cScience Materials and Environment laboratory, Sfax Faculty of Science, Sfax, Tunisia

^dHistology and Orthopaedic and Traumatology laboratory, Sfax Faculty of Medicine,
Sfax, Tunisia
^eAnatomy and Cytology Laboratory, CHU Habib Bourguiba, 3029 Sfax, Tunisia

Corresponding author. E-mail address: jbahisamira@yahoo.fr.

Summary

New synthetic biomaterials are constantly being developed for wound repair and regeneration. Bioactive glasses (BG) containing strontium have shown successful applications in tissue engineering account of their biocompatibility and the positive biological effects after implantation. This study aimed to assess whether BG-Sr was accepted by the host tissue and to characterize oxidative stress biomarker and antioxidant enzyme profiles during muscle and skin healing. Wistar rats were divided into five groups (six animals per group): the group (I) was used as negative control (T), after ovariectomy, groups II, III, IV and V were used respectively as positive control (OVX), implanted tissue with BG (OVX-BG), BG-Sr (OVX-BG-Sr) and presented empty defects (OVX-NI). Soft tissues surrounding biomaterials were used to estimate superox-ide dismutase (SOD), catalase (CAT), glutathione peroxidase (GPx) and malondialdehyde (MDA) concentration. Our results show that 60 days after operation, treatment of rats with BG-Sr significantly increased MDA concentration and caused an increase of SOD, CAT and GPx activities in both skin and muscular tissues. BG-Sr revealed maturation of myotubes followed anormal appearance of muscle regenerated with high density and mature capillary vessels. High wound recovery with complete re-epithelialization and regeneration of skin was observed. The results demonstrate that the protective action against reactive oxygen species (ROS) was clearly observed in soft tissue surrounding BG-Sr. Moreover, the potential use of BG-Sr rapidly restores the wound skin and muscle structural and functional properties. The BG advantages such as ion release might make BG-Sr an effective biomaterial choice for antioxidative activity.

Oxidative stress; Bioglass; Strontium; Soft tissue regeneration; Antioxidative activity

Résumé

Des nouveaux biomatériaux sont synthétisés pour la régénération de tissus. Les verres bioactifs (BG) contenant du strontium ont montré des effets biologiques positifs au niveau de l'ingénierie tissulaire. Cette étude vise à évaluer la tolérance de BG par le tissu hôte et de caractériser les biomarqueurs du stress oxydatif et les profils des enzymes antioxydantes au cours de la guérison des muscles et de la peau. Des rates Wistar ont été divisées en cinq groupes (six rates par groupe): le groupe (I) était utilisé comme témoin négatif (T), après une ovariectomie, les groupes II, III, IV et V étaient respectivement utilisés comme contrôle positif (OVX), tissu implanté avec BG (OVX-BG), BG-Sr (OVX-BG-Sr) et présenté des défauts vides (OVX-NI). Les tissus environnants les biomatériaux ont été utilisés pour estimer la superoxyde dismutase (SOD), la catalase (CAT), glutathion peroxydase (GPx) et le malondialdéhyde (MDA). Nos résultats montrent que 60 jours après l'opération, le traitement des rates avec BG-Sr a entraîné une augmentation de malondialdéhyde (MDA) et les activités de SOD, CAT et GPx au niveau de muscle et de la peau. Le BG-Sr a révélé au niveau de muscle une maturation et une vascularisation de tissu. Au niveau de la peau, une complète ré-épithélialisation a été observée. Les résultats démontrent des effets protecteurs de BG-Sr contre les espèces réactives de l'oxygène (ERO). En outre, son utilisation permet de rétablir les propriétés structurelles et fonctionnelles musculaires et la régénération de la peau. La relargage des ions par le BG pourrait faire un choix efficace pour l'activité antioxydante.

MOTS CLÉS

Le stress oxydatif; Verre bioactif ; Strontium ; La régénération des tissus mous; Des activités antioxydantes

Introduction

The beneficial effect of strontium (Sr) as a potential antio-osteoporotic factor at a low dose has been well documented [1]. Current studies have taken the benefits of Sr on bone regeneration by incorporating it into various bone graft bio-materials [2]. Among these biomaterials, bioactive glasses (BG) have been widely used thanks to their biological properties. In fact, they have the ability to bond to hard tissue and to form a carbonated hydroxyapatite layer (HCA) when exposed to a biological fluid [3]. Furthermore, the ionic dissolution products from bioglass (e.g. Si, Ca, and P) stimulate expression of several osteoblastic cell genes [4]. The substitution of Sr with bioglass enhances bone healing; moreover, it is believed to favourably affect the cell proliferation and differentiation and to develop both osteogenesis and angiogenesis properties. Interestingly, many previous studies have indicated that the release of degradation products from these materials affects the tissue responses. Within these responses, reactive oxygen species (ROS) are generated by activated phagocytes. Current studies have demonstrated that ROS could exert positive as well as negative effects in many tissues [5]. As regards the positive effects, ROS play an important role after injury when adequate amounts of reactive ions or molecules including hydrogen peroxide (H_2O_2), superoxide (O_2^-), hydroxyl radicals ($OH\cdot$) are produced by damaged endothelial and smooth muscle cells. Thus, ROS contribute to angiogenic signalling [6]. The negative ROS effects consist in the contribution to the disease pathology and complication [7]. After implantation, the skeletal muscles surrounding the biomaterials are affected by different particle sizes and morphologies. They exhibited differences in their behavioral, physiological, and cellular responses. The effects of implants on bony tissue have been investigated [8]. However, only few studies have directly addressed the effect upon the adjacent skeletal muscle and skin tissue. Our hypothesis is that Sr may contribute to the ROS imbalance control during hormonal insufficiency in the soft tissue surrounding BG-Sr. In the present study, we aimed to investigate the antioxidant activity of BG with 0.1 wt% Sr. The particle size ranged between 40 and 63 μm against the free radicals induced by estrogen deficiency and correlated with the tissue biocompatibility during the osteoporosis development.

Material and methods

Bioactive glass synthesis

The first material studied was pure 46S6 possessing compositions close to that of Hench's 45S5 [9] and used as a reference to validate our experimental procedure. Then, 0.1% wt of Sr

was introduced into the 46S6 bio-glass. Appropriate amounts of calcium metasilicate, sodiummetasilicate, sodium metaphosphate, and magnesium oxide were weighed and mixed for 45 min using a planetary mixer. The powdered mixture was heated in a platinum crucible at 1300°C for 3 h. The molten material was then poured into preheated brass molds to form cylinders of 13 mm in diameter and 10 mm in height. The prepared samples were annealed for 4 h at the appropriate temperature, corresponding to the phase transition temperature of the glass composition (about 560°C), in a regulated muffle furnace, which was left to cool to room temperature at a rate of 1°C min⁻¹. After elaboration, the powder particles sized between 40—63 µm were compressed in a perfectly isostatic manner. The prepared implants were sterilized by γ -irradiation from a 60Co Source gamma irradiation at a dose of 25 Gy (Theratron external beam teletherapy, Equinox, Ottawa, ON, Canada) using standard procedures for medical devices.

Animal model

Female Wistar rats (16—19 weeks of age), obtained from the central pharmacy, Tunisia, and bred in the central animal house were used in this study. The rats were acclimatized to their new environment for 7 days before the beginning of the study. The animals were fed on a pellet diet (Sicco, Sfax, Tunisia) and water ad *libitum*. All the animals were kept under climate-controlled conditions (25°C; 55% humidity; 12 h of light alternating with 12 h of darkness). The handling of the animals was approved by the Tunisian ethical committee for the care and use of laboratory animals. All rats were randomly divided into five groups (six animals per group): the first group (I) was used as negative control (T). Sixty days after bilateral ovariectomy, groups II, III, IV and V were used respectively as positive control (OVX), implanted tissues with BG (OVX-BG), BG-Sr (OVX-BG-Sr) and the last one presented empty defects (OVX-NI). Surgical and postoperative protocol. All surgical interventions were performed under general anaesthesia in aseptic conditions. Anaesthesia was induced with xylazine (7 to 10 mg/kg (i.P) Rompun®2%) and ketamine (70 to 100 mg/kg (i.m) Imalgene®) depending on the bodyweight. Animals were shaved and prepared for surgery. BG and BG-Sr in a similar disc form were placed into 1-cm muscular and subcutaneous pouches in ovariectomised rats. On days 4, 7, 15, 30 and 60 after implant insertion, all rats were sacrificed and specimens were harvested for biological evaluation.

Tissue preparation

The muscular and skin tissues surrounding the biomaterials were carefully removed, cleaned, dried and processed for antioxidant enzyme analysis. The homogenates were pre-prepared on ice in the ratio 2 g tissue for 8 ml of phosphate buffer saline, centrifuged at 9000 rpm for 15 min at 4°C and frozen at —70°C until analysis.

Oxidative stress measurements

The lipid peroxidation in the muscular and skin tissues of control and all treated animal groups was measured by the quantification of thiobarbituric acid-reactive substances (TBARS) determined by the method of Buege and Aust [10]. The activity of superoxide dismutase (SOD) was assayed by the spectrophotometric method of Marklund and Marklund [11]. The glutathione peroxidase (GPx) activity was measured by the method described by Pagila and Valentine [12]. Catalase (CAT) was assayed calorimetrically at 240 nm and expressed as moles of H₂O₂ consumed per minute per milligram of protein, as described by Aebi [13]. The level of total protein was determined by the method of Lowry *et al.* using bovine serum albumin as the standard at 660 nm [14].

Histological study

Both muscular and skin tissue of control and all treated groups were fixed in 10% formalin and embedded in paraffin. Thereafter, 4—5 µm paraffin sections were stained with hematoxylin—eosin and subjected to microscopic examination.

Statistical analysis

The statistical analysis of the data was made using Student's *t* test. All values were expressed as means ± SE. Differences are considered significant at the 95% confidence level ($P < 0.05$).

Results

Antioxidant status during skeletal muscle healing

As illustrated in Fig. 1a—c, the data on the SOD, CAT, and GPx activities in the skeletal muscle of OVX rats showed a highly significant decrease when compared to those of control rats. Also ovariectomy significantly elevated the malondialdehyde (MDA) levels ($P < 0.001$) (Fig. 2). The results showed that after 4 and 7 days, the CAT, SOD and GPx activities in OVX-BG-Sr, OVX-BG groups decreased significantly ($P < 0.001$) as compared to those of

OVX rats. In addition, an enhancement increase in MDA levels ($P < 0.001$) was observed. The results clarified that implantation of both BG-Sr and BG showed a pronounced release in the free radical content. These activities were more pronounced than those of OVX-NI group. However, 15 days after operation, the SOD, CAT and GPx activities showed a significant enhancement and the maximum was administered after 60 days. In fact, the SOD, CAT and GPx activities in OVX-BG were increased by 12%, 22.5% and 12%, respectively when compared to those of OVX rats. Besides, we noted a decrease in MDA levels by 43.4%. Similarly, a significant increase by 16%, 26% and 19.5% was shown in OVX—BG-Sr rats as compared to those of OVX groups. We also observed a decrease of MDA by 44.5%. Antioxidant status during cutaneous wound healing. The data on the SOD, CAT, and GPx activities in the cutaneous tissue of OVX rats showed a significant decrease when compared to those of controls rats (Fig. 3a—c). More-over, ovariectomy significantly elevated the MDA levels.

Muscle histopathology

After 4 days of BG and BG-Sr implantation, we noted the presence of numerous necrotic myofibrils with different caliber sizes. They were mildly swollen. Their cytoplasm was paler than that of control and had a homogenized appearance without striations (Fig. 5a—c). Moreover, we noted that leukocyte infiltration was more accentuated in BG than that of BG-Sr- treated rat muscles (Fig. 5d, e). This damage paralleled the significant enhancements of MDA level detected in skeletal muscle tissue implanted with BG and BG-Sr in the same period of 4 days. After 7 days, the various events typical of regeneration were observed in BG treated muscle. The BG individual myofibers had a thin pericellular endomysium with groups of myofibers surrounded by a thicker perimysium than those of BG-Sr treated groups (Fig. 5f, g). The BG treated rat myofibers were smaller in size than those of BG-Sr treated rats, but like the normal muscle, they were polygonal and possessed peripheral nuclei.

After 15 days, the myofiber size in BG-Sr group matched that of normal muscle and was considerably large. BG-Sr regenerating regenerate muscle exhibited three morphologically distinguishable zones: an outer zone of original surviving myofibers, a middle myogenic zone composed of proliferated myoblasts and small myotubes, and an inner zone of degenerated myofibers (Fig. 5h). Many nerves and blood vessels restoration between fiber muscle in BG-Sr and BG treated rat muscles was seen (Fig. 5i, j). After 60 days, the entire muscle was filled with polygonal myofibers. Moreover, we noted the uniformity of muscle fibers appearing in

both BG and BG-Sr with longitudinal striations. This regeneration paralleled the significant decrease of MDA level detected in skeletal muscle tissue surrounding BG and BG-Sr in the same period (Fig. 3k, l).

Skin histopathology

The histological examination revealed that skin of BG-Sr and BG treated ovariectomised rats showed inflammatory patterns on day 4 (Fig. 6a, b). The inflammatory cells were particularly abundant in the dermal compartment. However, neither BG-Sr nor BG treated group induced prolonged or exaggerated inflammatory responses. In fact, the inflammatory cells and microvessels in the regenerated tissues were gradually degraded and substituted by collagen fibers (Fig. 6c, d). After 15 days, the histological examination revealed that the growth of epidermal cells was retarded in BG treated group and epithelization was limited in the NI group in comparison with that of BG-Sr treated group. The restoration kinetics of cellular bases was significantly enhanced in BG-Sr treated group. The wound in group BG-Sr site was completely covered with epithelial cells and the thickness of the epidermis was comparable to that of a normal rat (Fig. 6e). After 8 weeks, the histological sections of BG-Sr skin treated group exhibited neovascularisation, many mature hair follicles, sebaceous gland cells and complete epithelialization (Fig. 6f—h).

Discussion

Bioglass is considered as a promising material in the context of tissue engineering applications. The ionic dissolution products from bioglass in vivo are key to understanding the behaviour of these materials. During biomaterial/tissue interaction, there is a possible imbalance in the oxidative status contributing to the complication of graft substitutes and tissue damages. When biomaterials are implanted, a series of biological events occur [15, 16]. Proteins adsorb on the biomaterial surface almost immediately. Moreover, inflammation leads to the chemo-attraction of activated phagocytes. The phagocytic activities of neutrophils and macrophages are an appropriate source that release pro-inflammatory cytokines, cytotoxic proteases, and free radicals, including reactive oxygen [17]. Here, as well as in the skin, the skeletal muscle tissues surrounding BG-Sr and BG indicated a significant rise in MDA concentration level and reduction in SOD, CAT, GPx activities during the first week in ovariectomised rats. These activities were very limited in ovariectomised rats. In fact, estrogen is a strong antioxidant having the ability to diminish cell membrane disruption. Moreover, estrogen showed to prevent the decrease in skin collagen in post-menopausal

women receiving hormone replacement therapy [17]. Hence, the decrease of the antioxidative activities in all treated rats can be partially explained by the fact that after ovariectomy, circulating estrogen levels is dropped and their positive effects on skeletal muscle thus decrease in all ovariectomised rats. However, the pronounced activity in the BG-Sr and BG treated group can be explained by the fact that the degradation products of matrix bioglass stimulate inflammatory reactions and leukocyte invasion that can be responsible for further collateral damage to healthy tissue. Current findings show that the reactions through neutrophils are capable of direct lysis of muscle cell membranes through a superoxide-dependent mechanism. Superoxide can be rapidly removed by reaction with other free radicals or by conversion to hydrogen peroxide by SOD [18]. Hydrogen peroxide is a stronger oxidant than superoxide and has the capacity to peroxidize lipids and damage cell membranes [19]. Hydrogen peroxide can also be converted to more highly reactive free radicals including hydroxyl radicals. Therefore, modified muscle and skin tissue used during and after surgical procedures can affect the level of SOD expression [20]. In general, the persistent formation of ROS can overcome antioxidant defenses, and thus result in the oxidative stress imbalance. In this study, after 8 weeks, BG-Sr materials with 0.1 wt% Sr treated muscular group showed a 16%, 26% and 19.5% increase in SOD, CAT and GPx activities and decrease of MDA by 44.5% compared with those of other groups. Moreover, the skin showed 31.1%, 26% and 45.5% increase in SOD, CAT, GPx activities and a decrease in MDA level by 44.6% as compared with those of other groups. A recent study showed that with biocompatible materials, an early resolution of the acute and chronic inflammatory responses occurred with the chronic inflammatory response usually lasting no longer than two weeks. Moreover, a current study shows a strong relationship between free radicals and inflammatory response. Therefore, free radicals could indeed be a useful tool in tissue engineering. In fact, muscle-derived free radicals can reduce neutrophil mediated lysis of muscle cells and decreases superoxide concentration in the media [21]. This protective effect could occur by free radicals scavenging of superoxide to prevent its conversion to a more cytotoxic oxidant [22]. Muscle and skin-derived free radicals may also serve to protect tissues from damage by inflammatory cells by inhibiting the expression of adhesion molecules that are necessary for leukocyte interactions with the vascular endothelium [23]. On the other hand, the imbalance in the oxidative situation can be associated with biomaterials properties such as surface chemistry, size and shape. These properties are responsible for modifying the inflammatory intensity, time duration and wound healing processes. Recently, there has been a study regarding data on SiO₂nanoparticle-induced oxidative stress and pro-inflammatory responses

in rodent and in different types of cultured mammalian cell lines [24]. In our study, bioglasses are largely the result of the uniformity of granules within a narrow size range from 40 to 63 μm . It has been shown that when the particle size is lower than 200 μm , biomaterial resorption occurs too rapidly [25]. Conversely, when the particle size is greater than 400 μm , the particles remain unreacted and are not resorbed, thus impeding the formation of new bone tissues throughout the particle-bone matrix [26]. The results suggest that ROS generated from BG-Sr biomaterial may be involved in creating appropriate conditions for healing tissues and affect positively angiogenesis, remodeling and proliferation in both skeletal muscle and skin tissues. In fact, a recent study has been performed to determine the ability of strontium-doped calcium polyphosphate (SCPP) to induce angiogenesis via researching its effect on the mRNA expressions and protein secretion of VEGF and bFGF in/from cultured cells [27]. Nowadays, there is a broad consensus that for most tissues and organs, vascularization is the key process for regeneration. It represents an attractive target cell source for therapeutic neovascularization and revascularization, which can provide nutrients for tissue regeneration, and create suitable conditions for tissue growth [28]. Sr affects angiogenesis, which is imperative in wound healing to maintain the cell activity for tissue repair. Here, in both muscular and skin tissues, the tissue healing as a function of implant time shows an enhanced angiogenesis. Accordingly to these results, bioglass containing 0.1% dose of strontium serve as a potential biomaterial for stimulating angiogenesis and tissue regeneration in the context of tissue engineering applications.

Conclusion

The present study indicated significant alterations in antioxidant profile during muscular and cutaneous wound healing in ovariectomised treated rats. All these alterations were observed mostly during the first week of healing. After 8 weeks of treatment, this study demonstrated that soft tissue surrounding BG materials with 0.1 wt% Sr had significantly decreased MDA concentration level and increased the activities of SOD, CAT and GPx. BG-Sr used as a substitute graft might be an effective strategy for soft tissue healing therapies as it might contribute to the control of ROS imbalance during hormonal insufficiency.

Disclosure of interest

The authors declare that they have no conflicts of interest concerning this article.

References

- [1] Marie PJ, Hott M, Modrowski D, De Pollak C, Guillemain J, Deloffre P, et al. An uncoupling agent containing strontium prevents bone loss by depressing bone-resorption and maintaining bone-formation in estrogen-deficient rats. *J Bone Miner Res* 1993;8:607—15.
- [2] Park JW, Kim HK, Kim YJ, Jang JH, Song H, Hanawa T. Osteoblast response and osseointegration of a Ti-6Al-4V alloy implant incorporating strontium. *Acta Biomater* 2010;6:2843—51.
- [3] Oudadesse H, Dietrich E, Gal YL, Pellen P, Bureau B, Mostafa AA, et al. Apatite forming ability and cytocompatibility of pure and Zn-doped bioactive glasses. *Biomed Mater* 2011;6:035006.
- [4] Isaac J, Nohra J, Lao J, Jallot E, Nedelec JM, Berda LA, et al. Effects of strontium-doped bioactive glass on the differentiation of cultured osteogenic cells. *Eur Cell Mater* 2011;8(21):130—43.
- [5] Estacio MAC, Tsukamura H, de Luna MCT, Maeda KI. Neural pathway of estrogen receptor α expression during stress-induced suppression of luteinizing hormone secretion. *Philipp J Vet Med* 2009;46:61—72.
- [6] Ushio-Fukai M, Alexander RW. Reactive oxygen species as mediators of angiogenesis signaling: role of NAD (P)H oxidase. *Mol Cell Biochem* 2004;64:85—97.
- [7] Morakinyo AO, Iranloye BO, Daramola AO, Adegoke OA. Antifertility effect of calcium channel blockers on male rats: association with oxidative stress. *Adv Med Sci* 2011;1(56):95—105.
- [8] Jebahi S, Oudadesse H, El Feki H, Rebai T, Keskes H, Pascal P, et al. Antioxidative/oxidative effects of strontium-doped bioactive glass as bone graft, in vivo assays in castrated rats. *J Appl Biomed* 2012;10:195—209.
- [9] Hench LL. Bioceramics. *J Am Ceram Soc* 1998;81:1705—28.
- [10] Buege JA, Aust SD. Microsomal lipid peroxidation. *Methods Enzymol* 1984;105:302—10.

- [11] Marklund S, Marklund G. Involvement of the superoxide anionradical in the autoxidation of pyrogallol and convenient assayfor superoxide dismutase. *Eur J Biochem* 1975;47:469—74.
- [12] Pagila DE, Valentine WN. Studies on the quantitative and quali-tative characterization of erythrocyte glutathione peroxidase.*J Lab Clin Med* 1967;70:158—69.
- [13] Aebi H. Catalase in vitro. *Methods Enzymol* 1984;105:121—6.[14] Lowry OH, Rosebrough NJ, Farr AL, Randall RJ. Proteinmeasurement with Folin phenol reagent. *J Biol Chem*1951;193:265—75.
- [15] Jebahi S, Nsiri R, Boujbiha M, Bouroga E, Rebai T, Keskes H,et al. The impact of orthopedic device associated with carbon-ated hydroxyapatite on the oxidative balance: experimentalstudy of bone healing rabbit model. *Eur J Orthop Surg Trauma-tol* 2012, <http://dx.doi.org/10.1007/s00590-012-1087-8> [Epubahead of print].
- [16] Wang LS, Wang XJ, Wang WJ, Yan YG, Yao NZ, Wang XD, et al.Design, biomechanical study, and clinical application of a newpterygo-shaped titanium mesh cage. *Eur J Orthop Surg Trau-matol* 2012;22:111—7.
- [17] Anderson JM, Rodriguez A, Chang DT. Foreign body reaction tobiomaterials. *Semin Immunol* 2008;20:86—100.
- [18] Shah MG, Maibach HI. Estrogen and skin. *Am J Clin Dermatol*2001;2:143—50.
- [19] Fukai T, Ushio-Fukai M. Superoxide dismutases: role in redoxsignaling, vascular function, and diseases. *Antioxid Redox Sig-nal* 2011;15:1583—606.
- [20] Aizzat O, Yap SW, SopiaH, Madiha MM, Hazreen M, ShailahA, et al. Modulation of oxidative stress by *Chlorella vulgaris*in streptozotocin (STZ) induced diabetic Sprague-Dawley rats.*Adv Med Sci* 2010;55:281—8.
- [21] Rubanyi GM, Ho EH, Cantor EH, Lumma WC, Botelho LH. Cyto-protective function of nitric oxide: inactivation of superoxideradicals produced by human leukocytes. *Biochem Biophys ResCommun* 1991;31:1392—7.
- [22] Tidball JG. Inflammatory processes in muscle injury and repair.*Am J Physiol Regul Integr Comp Physiol* 2005;288:345—53.

- [23] Clancy RM, Leszczynska-Piziak J, Abramson SB. Nitric oxide, an endothelial cell relaxation factor, inhibits neutrophil superoxide anion production via a direct action on the NADPH oxidase. *J Clin Invest* 1992;90:1116—21.
- [24] Mohebbi-Fani M, Mirzaei A, Nazifi S, Tabandeh MR. Oxidative status and antioxidant enzyme activities in erythrocytes from breeding and pregnant ewes grazing natural pastures in dry season. *Rev Med Vet* 2012;10:454—60.
- [25] Gorustovich AA, Sivak MG, Guglielmotti MB. A novel methodology for imaging new bone formation around bioceramic bone substitutes. *J Biomed Mater Res A* 2007;81:443—5.
- [26] Li ZY, Lam WM, Yang C, Xu B, Ni GX, Abbah SA, et al. Chemical composition, crystal size and lattice structural changes after incorporation of strontium into biomimetic apatite. *Biomaterials* 2007;28:1452—60.
- [27] Liu F, Zhang X, Yu X, Xu Y, Feng T, Ren D. In vitro study in stimulating the secretion of angiogenic growth factors of strontium-doped calcium polyphosphate for bone tissue engineering. *J Mater Sci Mater Med* 2011;22:683—92.
- [28] Pardue EL, Ibrahim S, Ramamurthi A. Role of hyaluronan in angiogenesis and its utility to angiogenic tissue engineering. *Organogenesis* 2008;4:203—14.

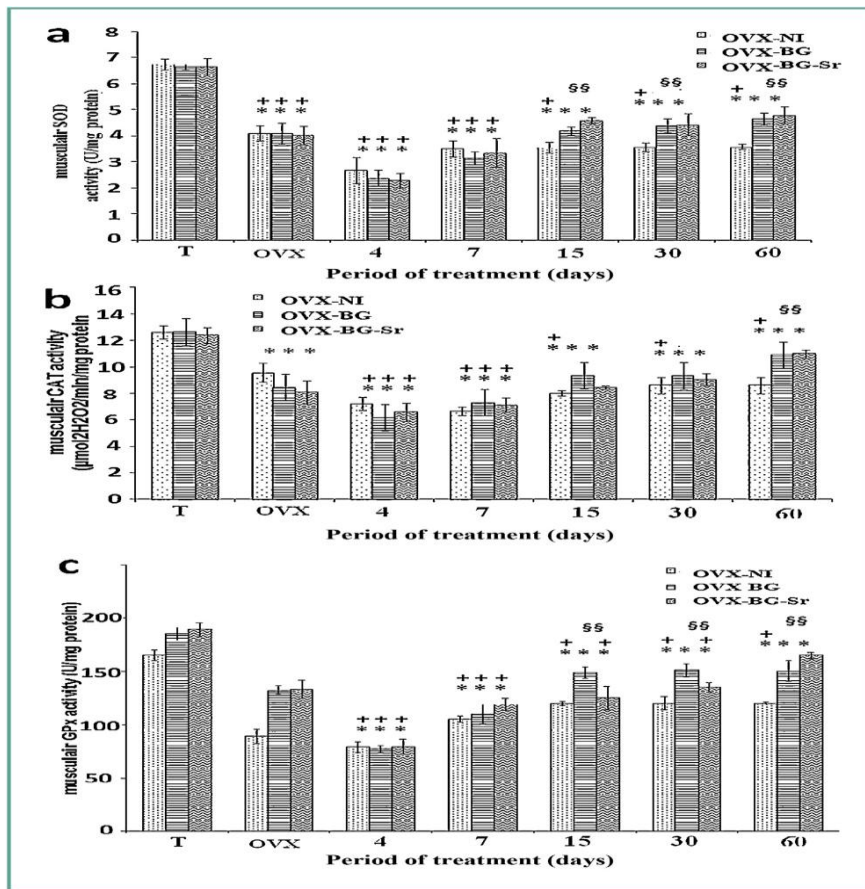


Figure 1. Effects of bioglass (BG) and strontium-doped bioglass(BG-Sr) on superoxide dismutase (SOD) (a), catalase (CAT) (b) and glutathione peroxidase (GPx) (c) activities in muscular tissue of ovariectomised female Wistar rats for 4, 7, 15, 30 and 60 days. Values are given as mean \pm SE. *: significantly less enzymatic activity in the indicated group than control group (T). +: less enzymatic activity compared to ovariectomised group (OVX). §: higher enzymatic activity than ovariectomised group with empty defects (OVX-NI). Les effets du bioverre (BG) et du bioverre dopé au strontium (BG-Sr) sur les activités de la superoxyde dismutase (SOD) (a), la catalase (CAT) (b) et la glutathion peroxydase (GPx) (c) au niveau du tissu musculaire des ratte ovarietomisées de souche Wistar ont été évalués durant quatre, sept, 15, 30 et 60 jours. Les valeurs sont exprimées en moyenne \pm SE. *: la valeur de l'activité enzymatique est significativement inférieure dans le groupe indiqué par rapport au témoin (T). +: la valeur de l'activité enzymatique est moins significative par rapport au groupe ovarietomisé (OVX). §: la valeur de l'activité enzymatique est plus élevée que celle du groupe ovarietomisé avec de perte de substance osseuse sans comblement (OVX-NI).

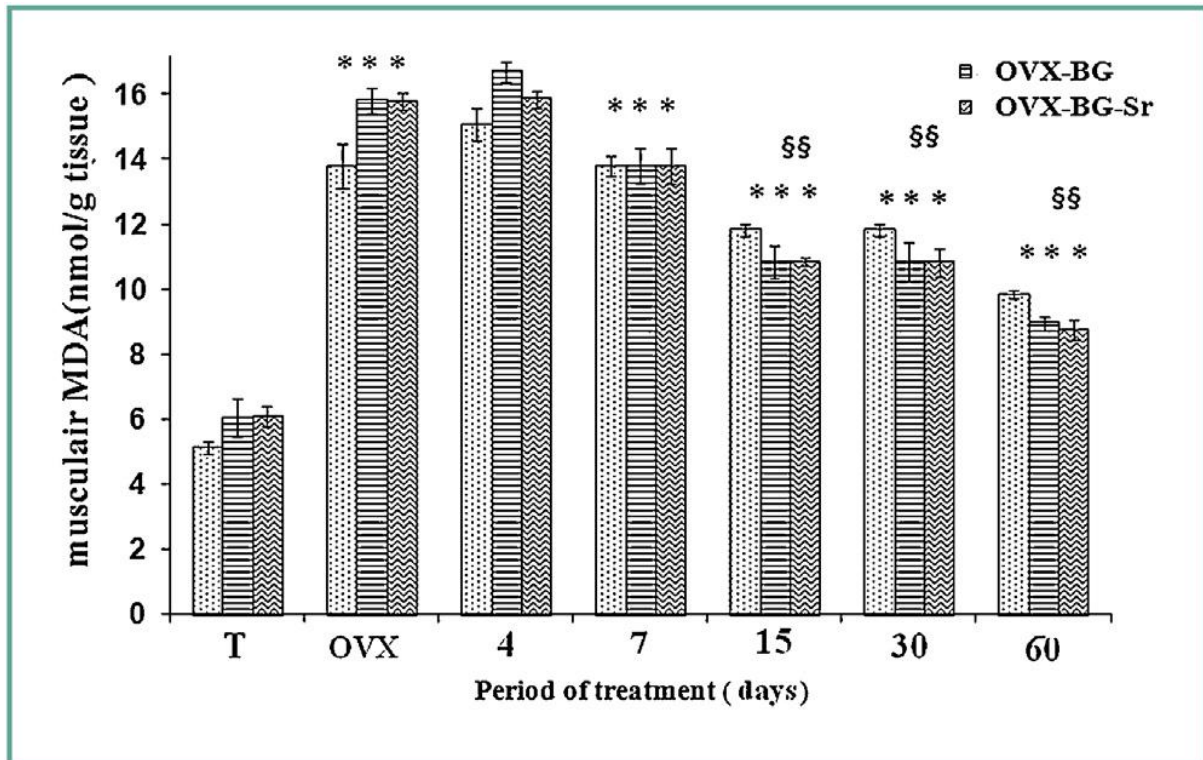


Figure 2. Effects of bioglass (BG) and strontium-doped bioglass (BG-Sr) on malondialdehyde (MDA) level. *: significantly higher level in the indicated group compared to the control group (T). §: lesser enzymatic activity than ovariectomised group with empty defects (OVX-NI). Les effets du bioverre (BG) et du bioverre dopé au strontium bioverre (BG-Sr) sur le taux de malondialdéhyde (MDA). * : le niveau est significativement plus élevé dans le groupe indiqué par rapport au groupe témoin (T). § : le niveau de l'activité enzymatique est inférieur à celui de groupe ovariectomisé avec de perte de substance osseuse sans comblement (OVX-NI).

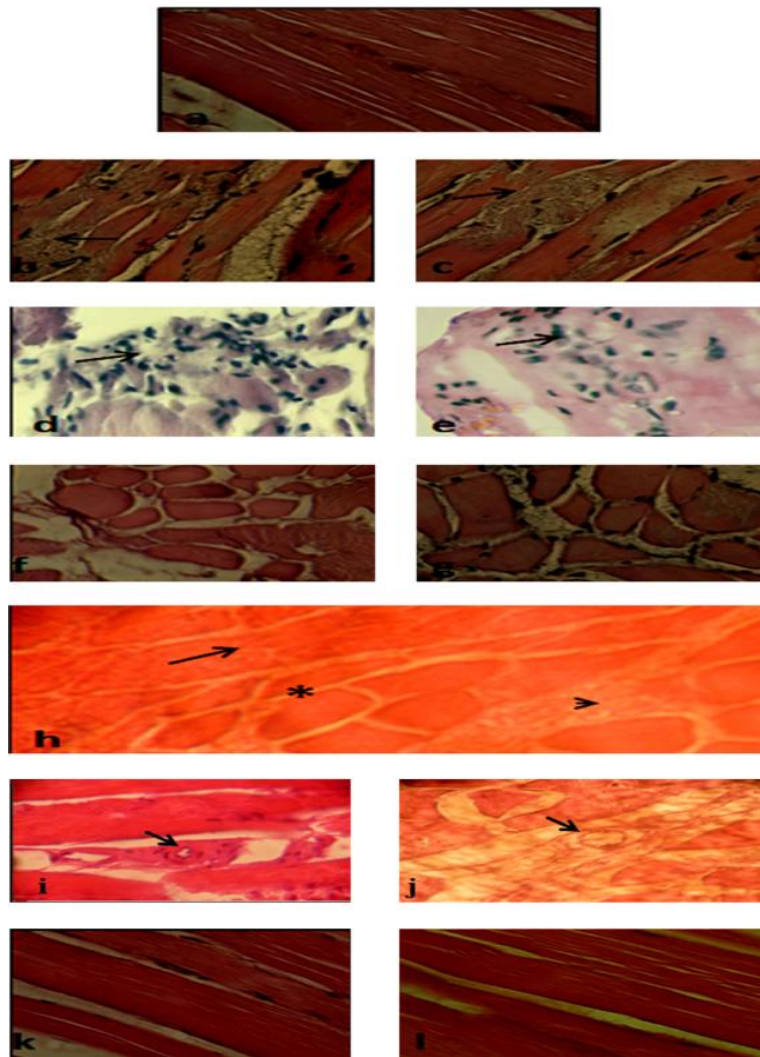


Figure 3. Histological sections of muscular tissue implanted with bioglass (BG) and strontium-doped bioglass (BG-Sr). Normal muscular tissue (a). Necrotic myofibrils in muscular tissue implanted with BG (b) and with BG-Sr (c), leukocyte infiltration in BG treated group (d) and with BG-Sr (e). A thin pericellular endomysium in BG (f) with groups of myofibers surrounded by a thicker perimysium than those of BG-Sr treated groups (g). Three morphologically distinguishable zones: an outer zone of original surviving myofibers, a middle myogenic zone composed of proliferated myoblasts and small myotubes, and an inner zone of degenerated myofibers (h). Nerves (head arrow) and blood vessels (arrow) restoration between fibre muscle in BG treated rat muscles (i) and in BG-Sr treated rat muscles (j). The entire muscle was filled with polygonal myofibers in BG treated rat muscles (k) and in BG-Sr treated rat muscles (l). Hematoxylin—eosin stain. Des coupes histologiques de tissu musculaire implantées par du bioverre pur (BG) et du bioverre dopé au strontium (BG-Sr),

tissumusculaire normal (a). Myofibrilles avec des foyers de nécrose au niveau de tissu musculaire implanté par du BG (b) et du BG-Sr (c), graftinfiltration des leucocytes dans le groupe traité par le BG (d) et le BG-Sr (e). Une mince couche de tissu conjonctif, l'endomysium chez le groupe implanté avec le BG (f), des groupes de fibres musculaires entourées d'une couche de périnysium comparé avec les groupes traités par les BG-Sr (g). Trois zones morphologiquement distinctes sont observées : une zone externe de fibres musculaires, une zone centrale composée des myoblastes et des petits myotubes, et une zone intérieure composée de fibres musculaires dégénérées (h). Nerfs (tête de flèche) et des vaisseaux sanguins (flèche) entre les fibres musculaires de ratte traitées par le BG (i) et les ratte traitées par le BG-Sr (j). La totalité de muscle est caractérisée par des fibres musculaires polygonales chez les ratte traitées par le BG (k) et par le BG-Sr (l). Coloration hématoxyline—éosine.

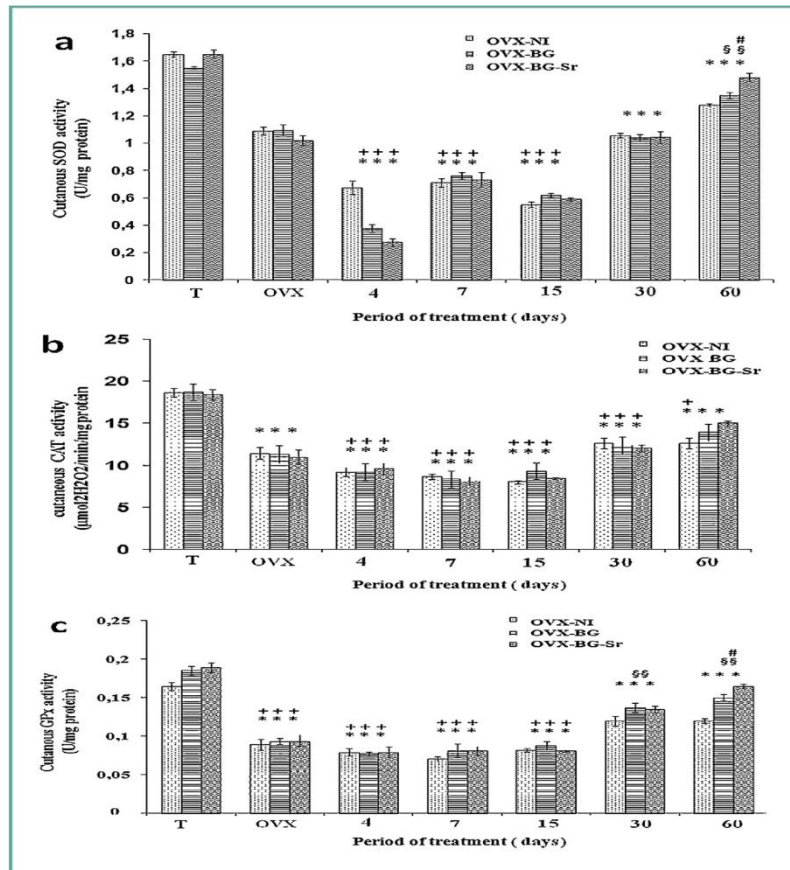


Figure 4. Effects of bioglass (BG) and strontium-doped bioglass (BG-Sr) on superoxide dismutase (SOD) (a), catalase (CAT) (b) and glutathione peroxidase (GPx) (c) activities in cutaneous tissue of ovariectomised female Wistar rats for 4, 7, 15, 30 and 60 days. Values are given as mean \pm SE. *: significantly less enzymatic activity in the indicated group than control group (T). +: compared to ovariectomised group (OVX). §: higher than ovariectomised group with empty defects (OVX-NI). #: higher than group implanted with bioglass (OVX-BG). Les effets du bioverre (BG) et du bioverre dopé au strontium (BG-Sr) sur les activités de la superoxyde dismutase (SOD) (a), la catalase (CAT) (b) et la glutathion peroxydase (GPx) (c) au niveau du tissu cutané des ratte ovariectomisées de souche Wistar ont été évalués durant quatre, sept, 15, 30 et 60 jours. Les valeurs sont exprimées en moyenne \pm SE. *: la valeur de l'activité enzymatique est significativement inférieure dans le groupe indiqué par rapport à témoin (T). +: la valeur de l'activité enzymatique est significativement inférieure par rapport au groupe ovariectomisé (OVX). §: la valeur de l'activité enzymatique est plus élevée que celle du groupe ovariectomisé avec de perte de substance osseuse sans comblement (OVX-NI). #: la valeur est supérieur chez les ratte implantées avec le bioverre pur (OVX-BG).

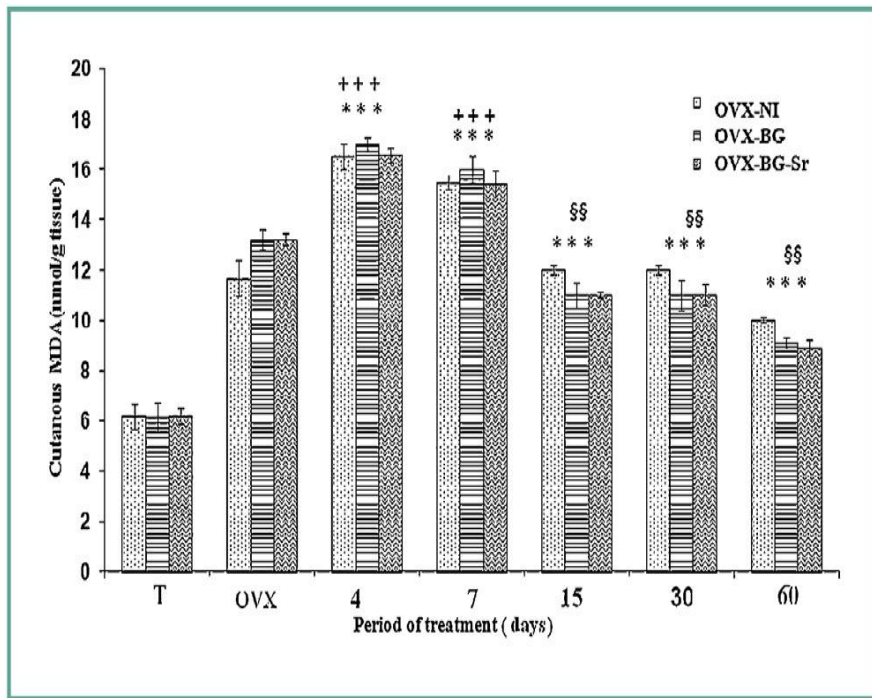


Figure 5. Effects of bioglass (BG) and strontium-doped bioglass(BG-Sr) on malondialdehyde (MDA) level. *: significantly higher level in the indicated group compared to the control group (T). +: compared to ovariectomised group (OVX). §: lesser than ovariectomised group with empty defects (OVX-NI). Les effets du bioverre (BG) et du bioverre dopé au strontium (BG-Sr) sur le taux de malondialdéhyde (MDA). * : le taux est significativement plus élevé dans le groupe indiqué par rapport au groupe témoin (T). § : le taux de l'activité enzymatique est inférieur à celui de groupe ovariectomisé avec de perte de substance osseuse sans complément (OVX-NI).

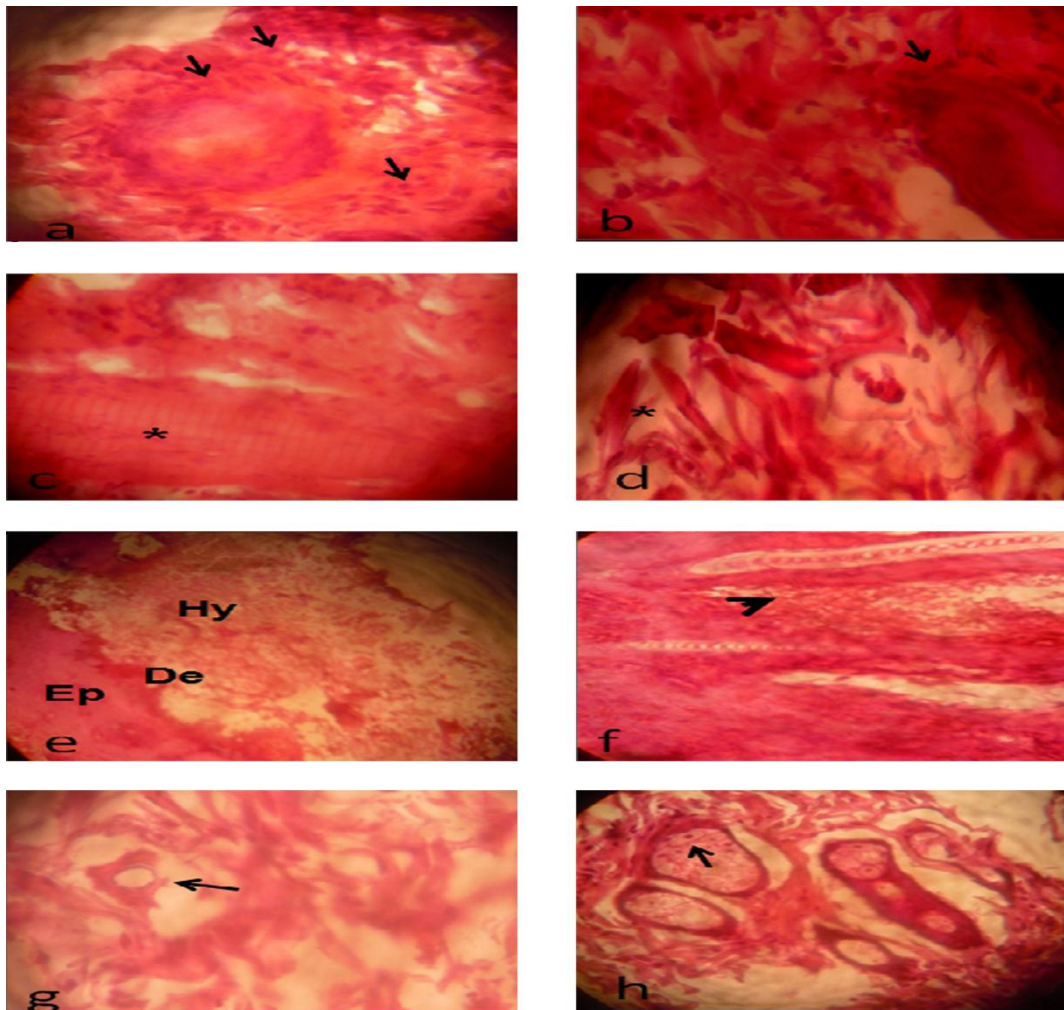


Figure 6. Histological sections of cutaneous tissue implanted with bioglass (BG) and strontium-doped bioglass (BG-Sr). Leukocyte infiltration in BG treated group (a) and BG-Sr (b). Collagen fibers in treated group with BG (c) and with BG-Sr (d). Complete re-epithelialization (Ep: epiderm, De: derme, Hy: hypoderm) (e). Many mature hair follicle cells (f) neovascularisation (g), sebaceous gland cells (h) in BG-Sr treated group. Hematoxylin—eosin stain. Des coupes histologiques du tissu cutané implanté avec le bioverre (BG) et le bioverre dopé au strontium (BG-Sr). L'infiltration de leucocytes dans le groupe traité avec le BG (a) et le BG-Sr (b). Observation des fibres de collagène dans le groupe traité par le BG (c) et avec le BG-Sr (d). La ré-épithélialisation est complète (Ep : épiderme, De : derme, Hy : hypoderm) (e). Observation des cellules matures du follicule pileux (f) des néovascularisation (g), des cellules des glandes sébacées (h) chez le groupe traité avec le BG-Sr. Coloration hématoxyline—éosine.

